

CASE CONFERENCE

**Resident Kyeong Sam Ok
Department of Internal Medicine
Seoul paik Hospital
InJe University College of Medicine**

Chief Complaints

Headache (F/50)

(onset : 2 hrs ago)

Present Illness

- 수년 전부터 가벼운 두통 있어 진통제 자가 복용하면서 지내오다 내원일 오후 갑자기 발생한 두통 및 구토 이후에 실신 있어 개인병원 방문함.
- 개인병원에서 시행한 뇌자기공명영상에서 종괴 보여 종교적 이유로 본원에서의 치료 원해 응급실 통해 입원함.

Review of System

Generalized weakness / Febrile sense /Chilling sense (- / - / -)

Weight loss/gain/ Poor oral intake (- / - / -)

Headache /Dizziness / Sore throat (+ / - / -)

Chest pain/Palpitation/ Chest discomfort (- / - / -)

Cough /Sputum /Rhinorrhea (- / - / -)

Dyspnea /Orthopnea /D.O.E (- / - / -)

Anorexia / Nausea / Vomiting / Constipation / Diarrhea (- / - / + / - / -)

Abdominal pain (-)

History

Past History

DM/HTN/Tbc/Hepatitis all denied by patient

Social history

Smoking (-)

Alcohol (-)

Jehovah's witness

Family history

Non specific

History

Obstetric history

2 - 0 - 0 - 2

Menstrual history

Menarche 13 yrs old

Menopause 45 yrs old

Physical Examination

Vital sign

BP - 159 / 82 mmHg HR - 75/min

RR - 18/min

BT - 36.6 °C

General appearance

Acute ill - looking appearance

Mental

Alert

HEENT

Anemic conjunctivae

Anicteric sclerae

Not dehydrated tongue

No palpable neck mass

Chest

Clear breath sound without rale

Regular heart beat without murmur

Abdomen

Soft & flat

Normoactive bowel sound

Tenderness (-)

Rebound tenderness (-)

Back & Extremities

No pretibial pitting edema

Grossly free

Cranial Nerve Function Test Non-specific

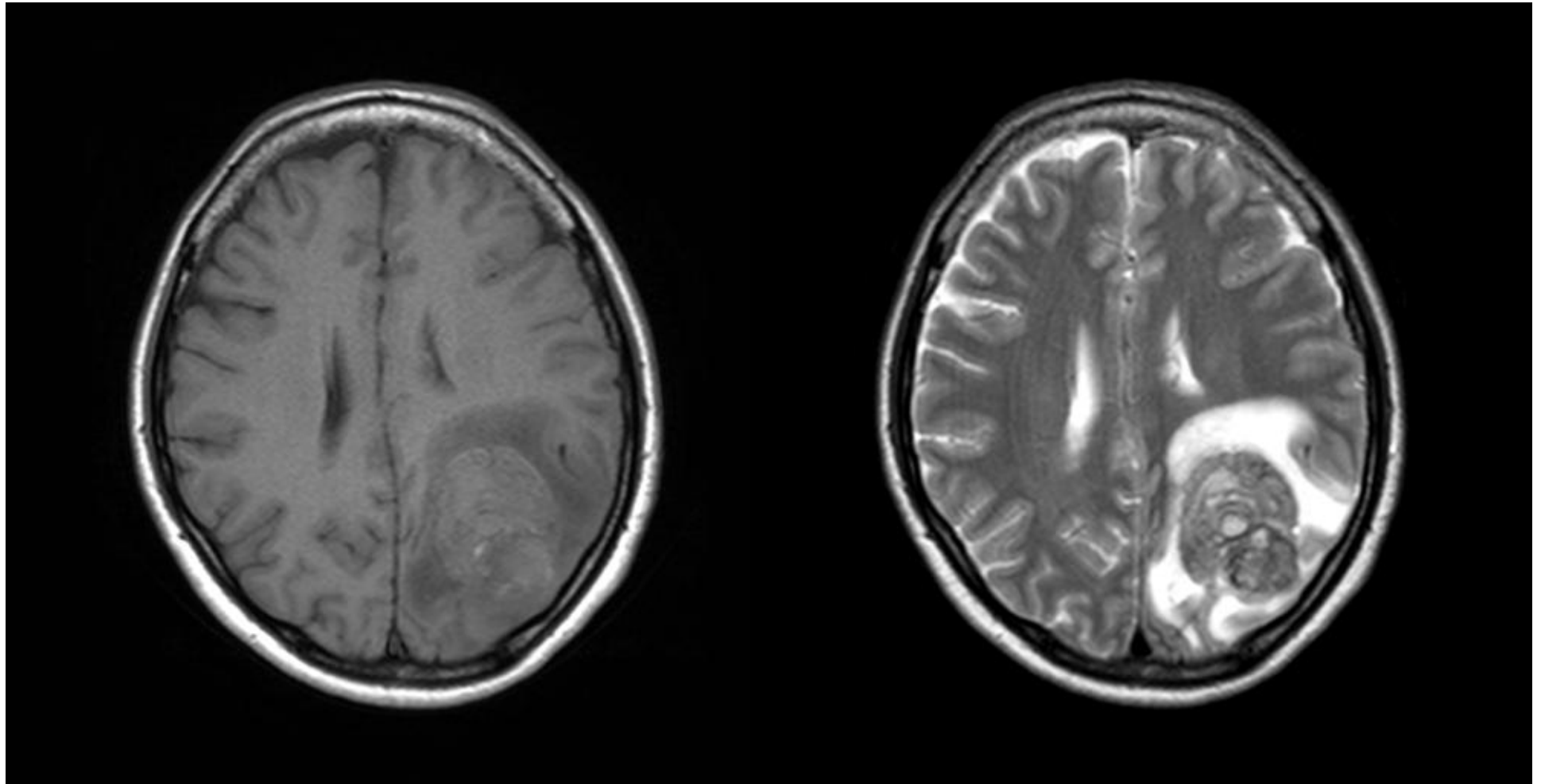
Initial laboratory finding

CBC with diff.	10.0 g/dL - 8,230 /mm ³ - 510,000/mm ³ (neutro : 83% / lympho: 13.5% / mono: 3.3% / eosino:0.1%)
BUN/Cr	12 / 1.0 mg/dL
AST/ALT, T.bil	22 / 36 IU/L, 0.44mg/dL
Protein/albumin	6.1/ 3.3 g/dl
PT/PTT	12.6 (INR 1.00) / 30 sec
ESR/CRP	18 mm/hr / 1.2 mg/dl
Serum beta-hCG	4,210 mIU/mL
Urine analysis	All negative

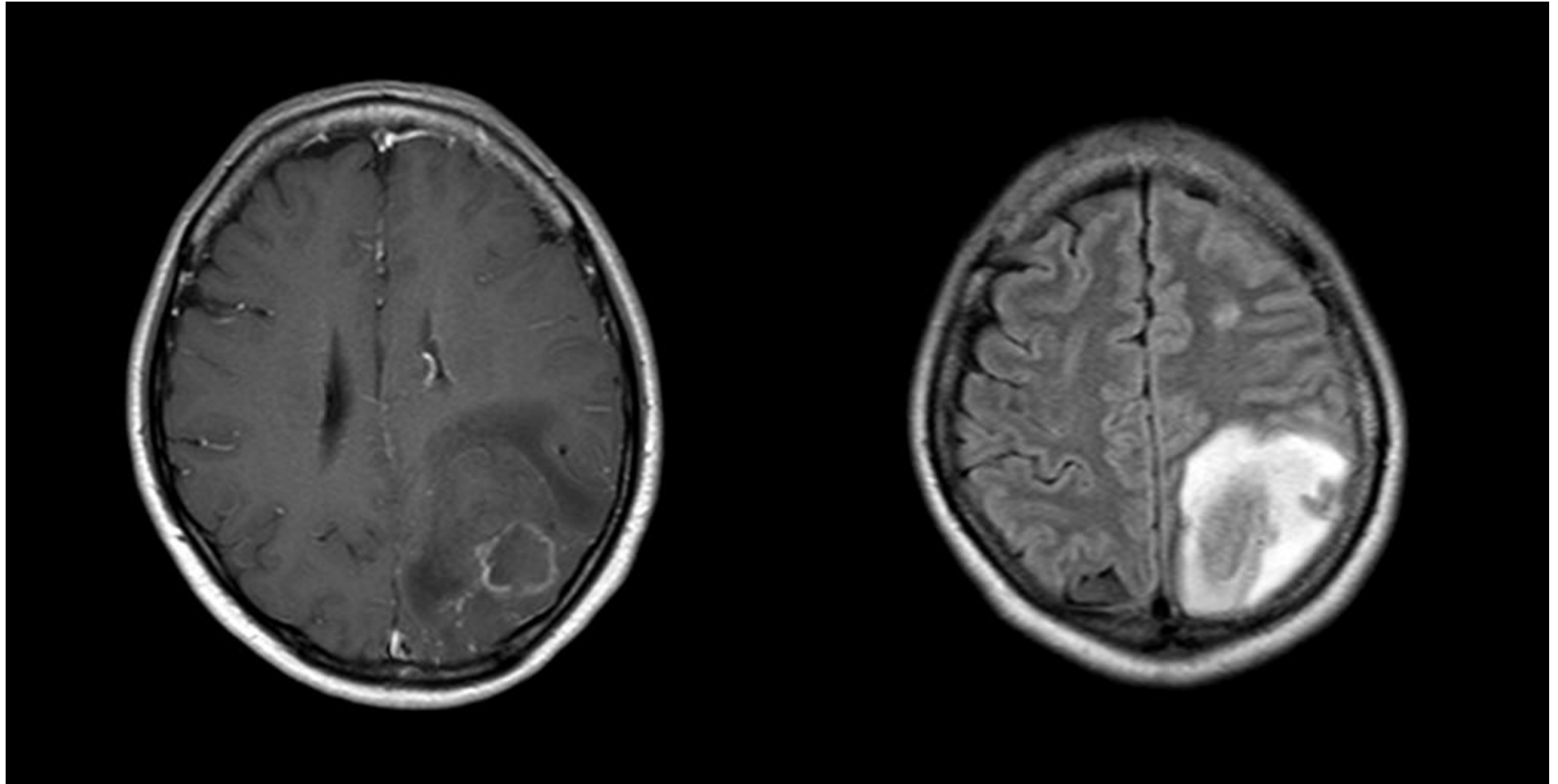
Work up

- Chest X-ray
- Chest CT
- Abd-pelvic CT
- Surgical biopsy

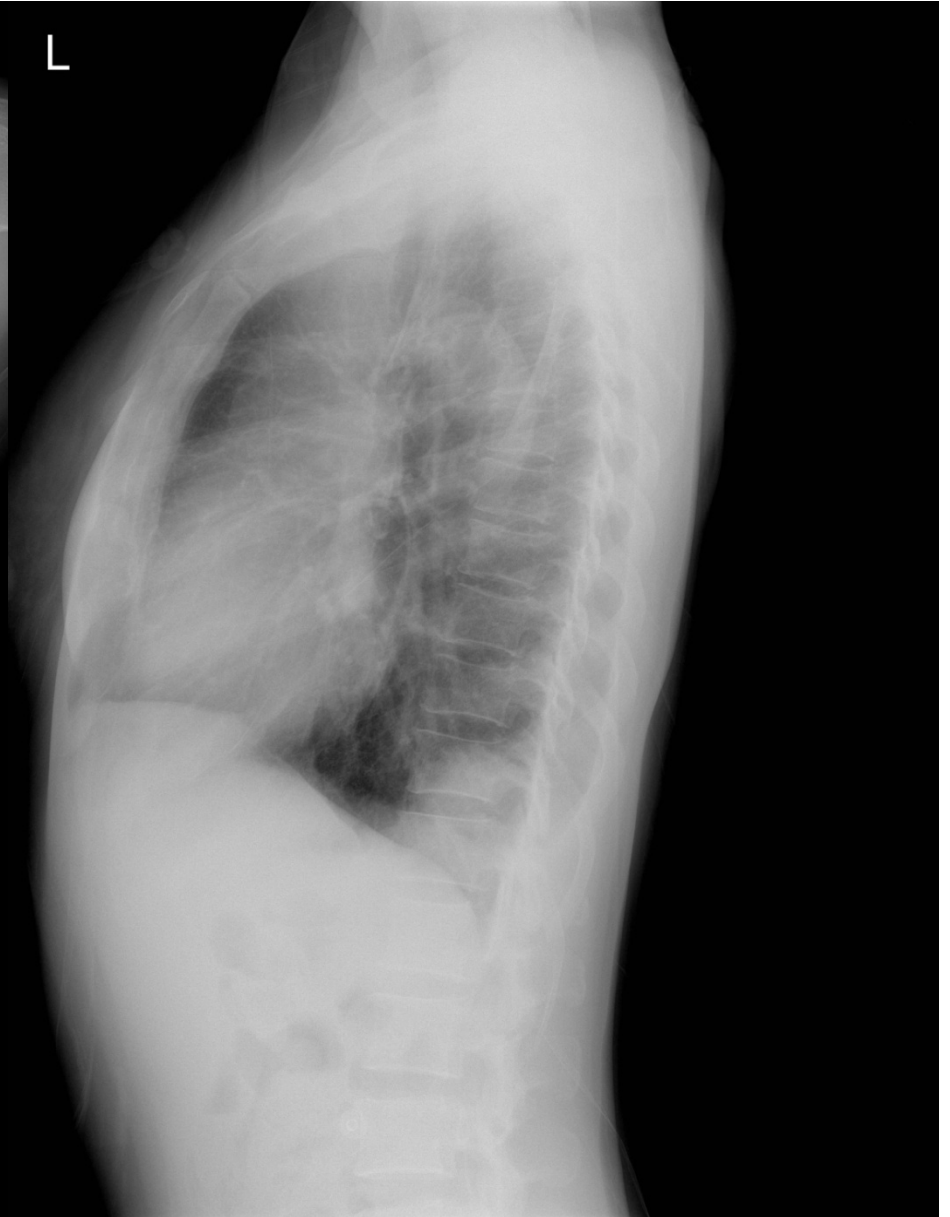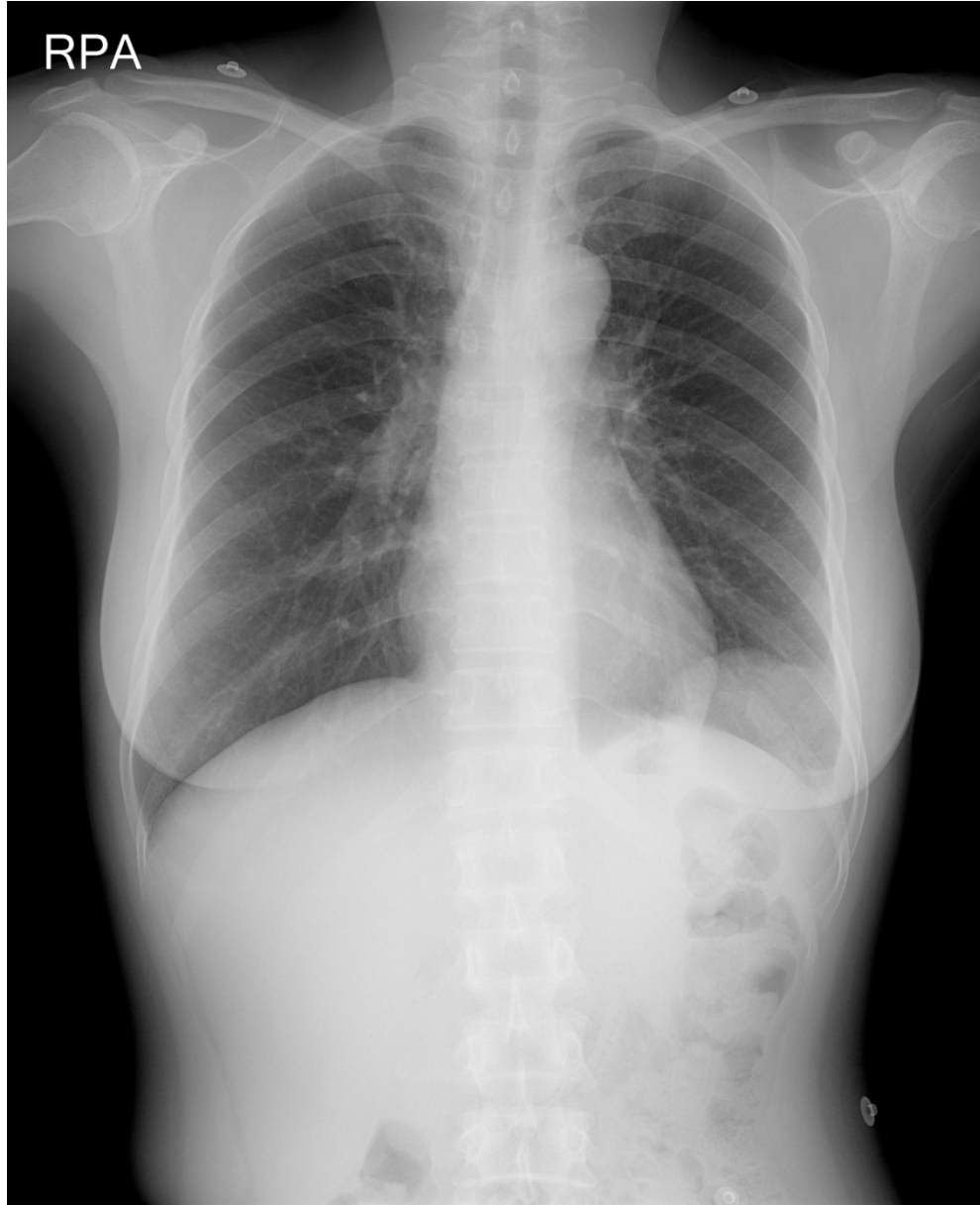
Brain MR



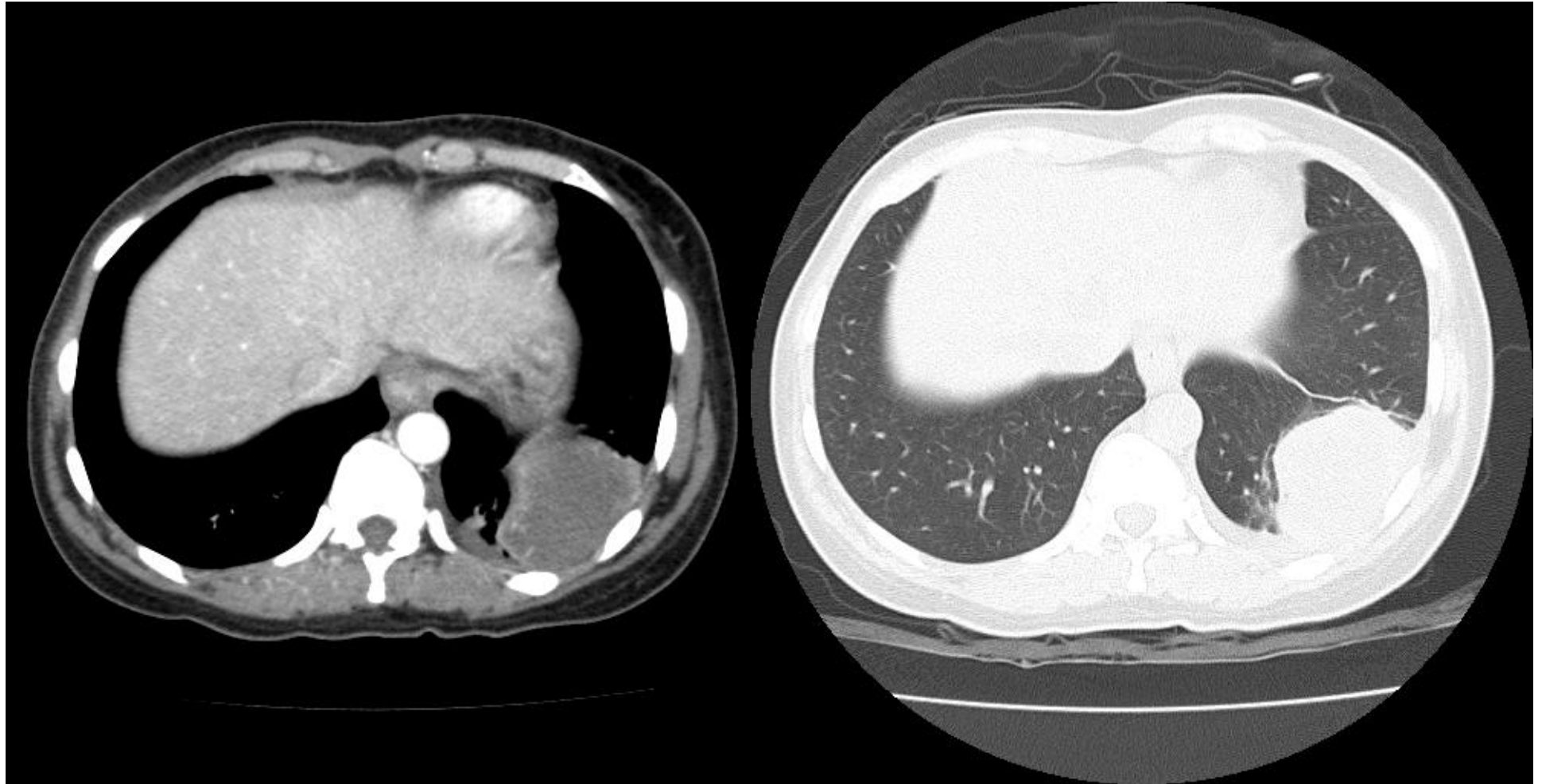
Brain MR



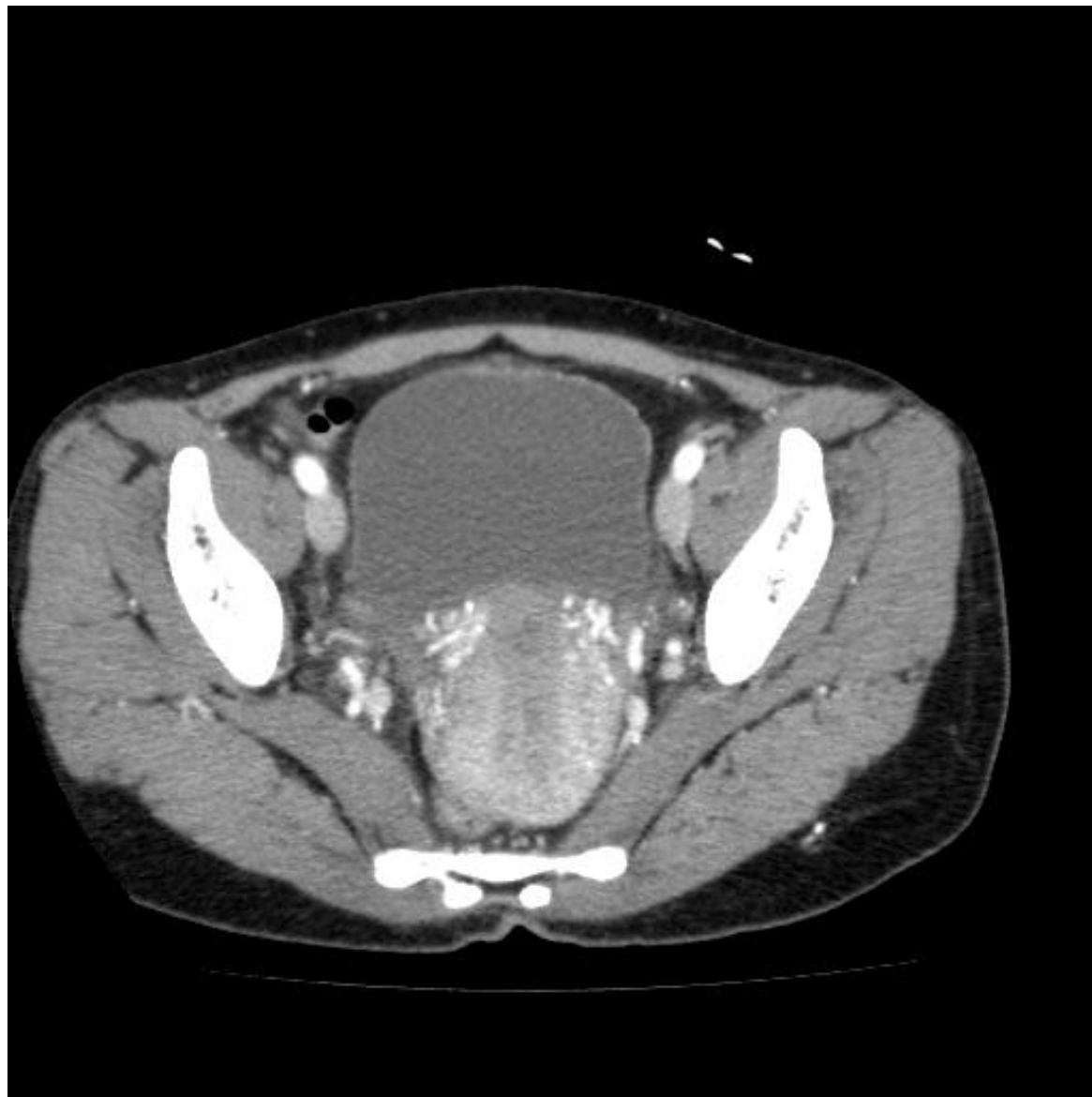Chest X-ray



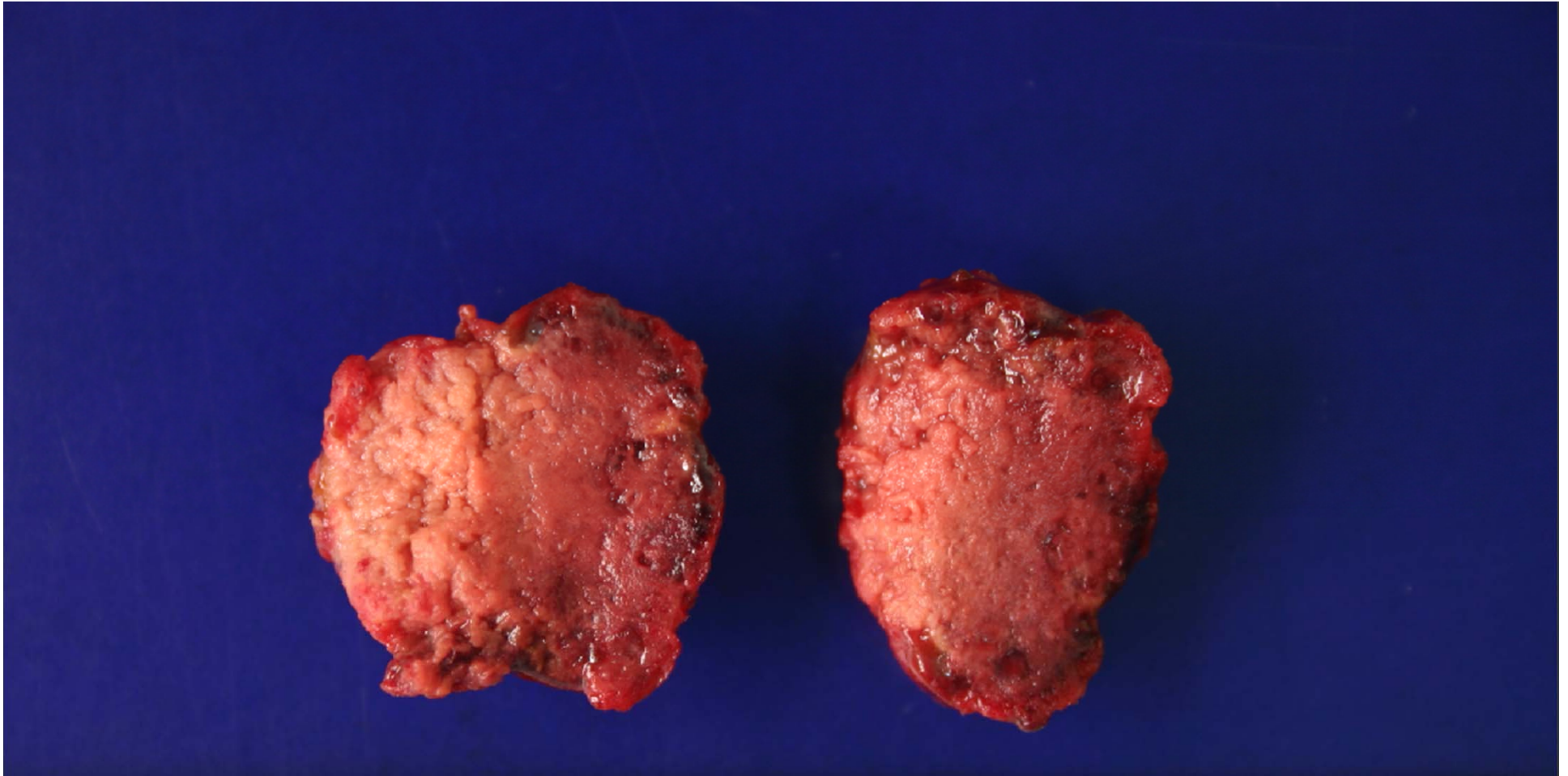
Chest CT

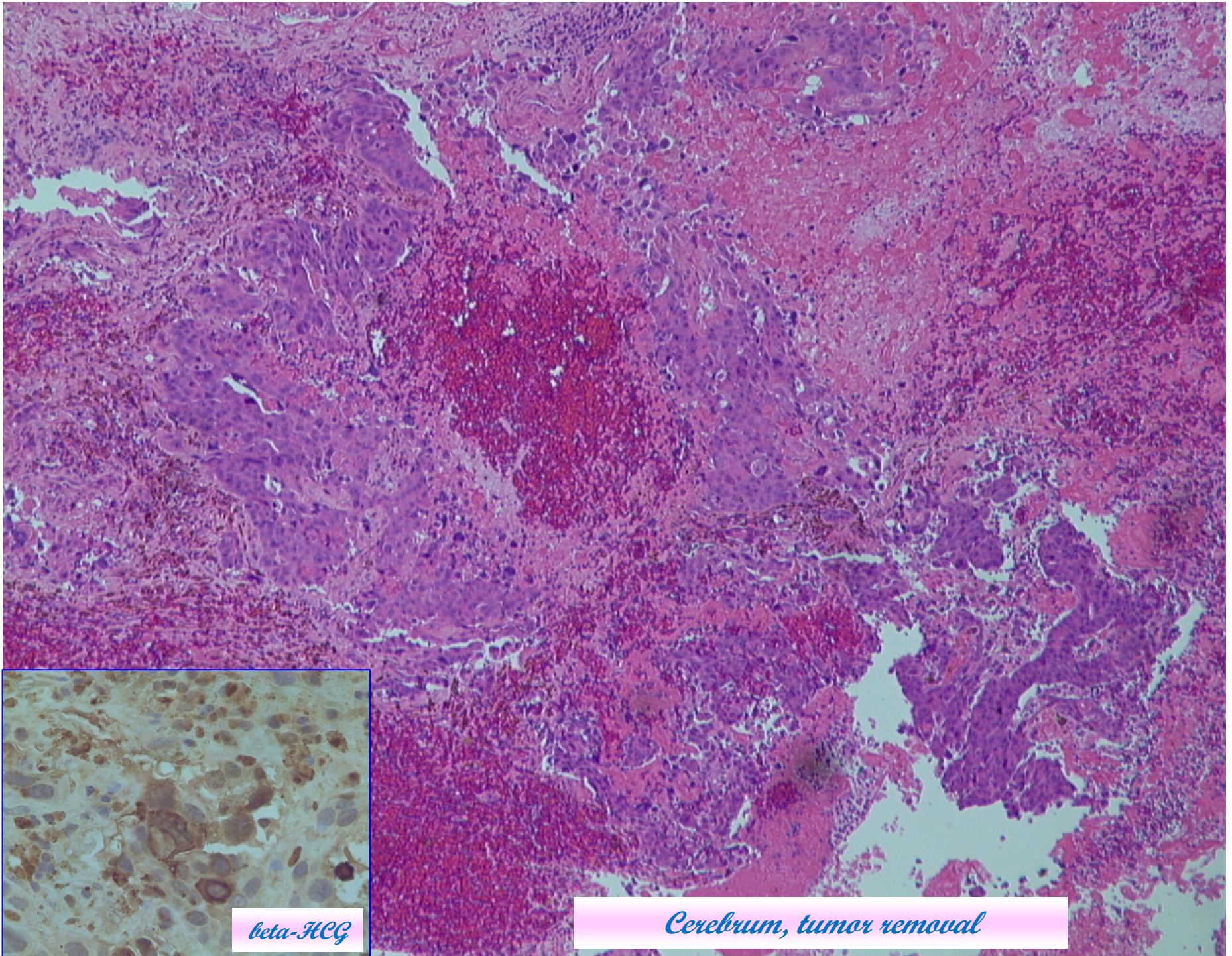


Abd-Pelvic CT



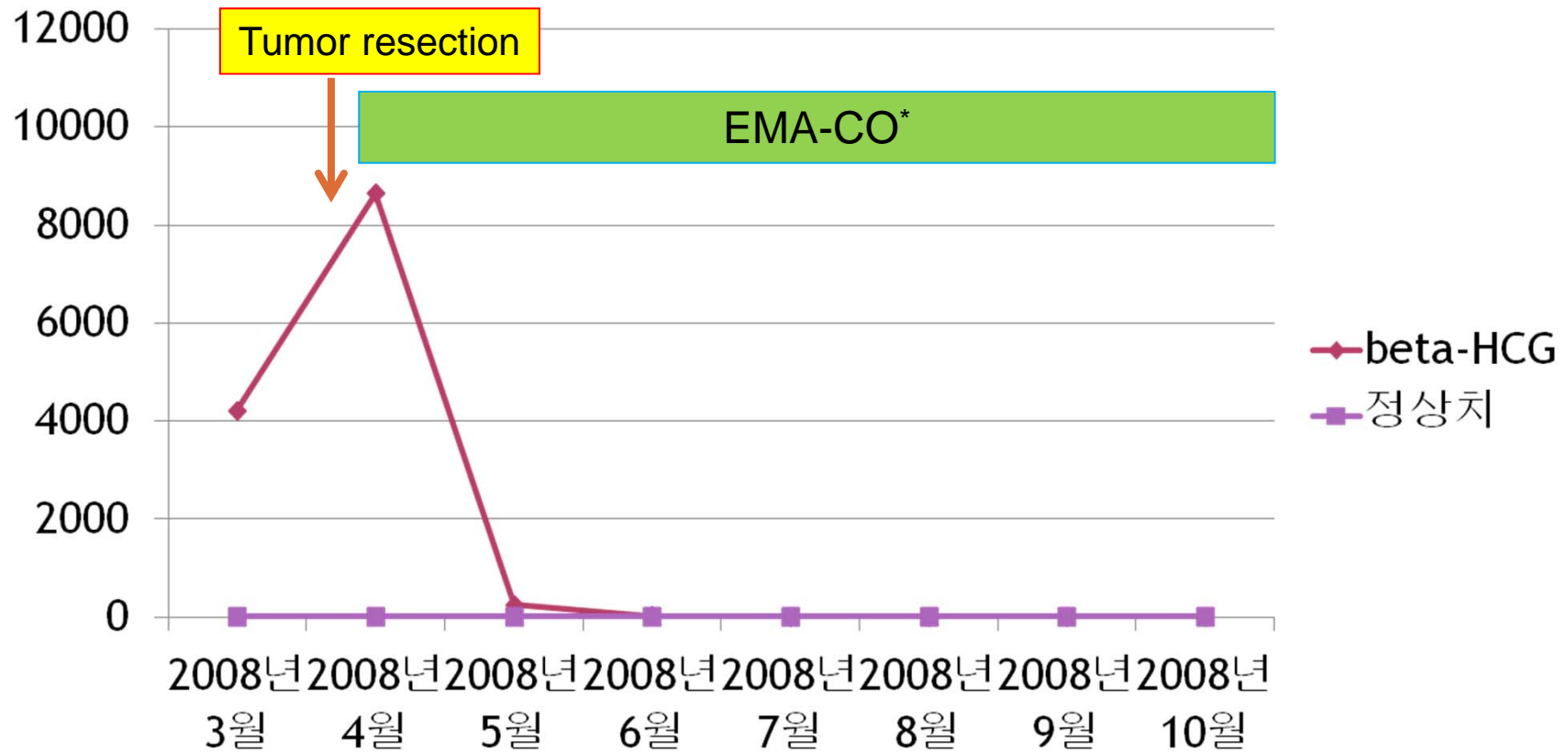
Tumor removal (Cerebrum)



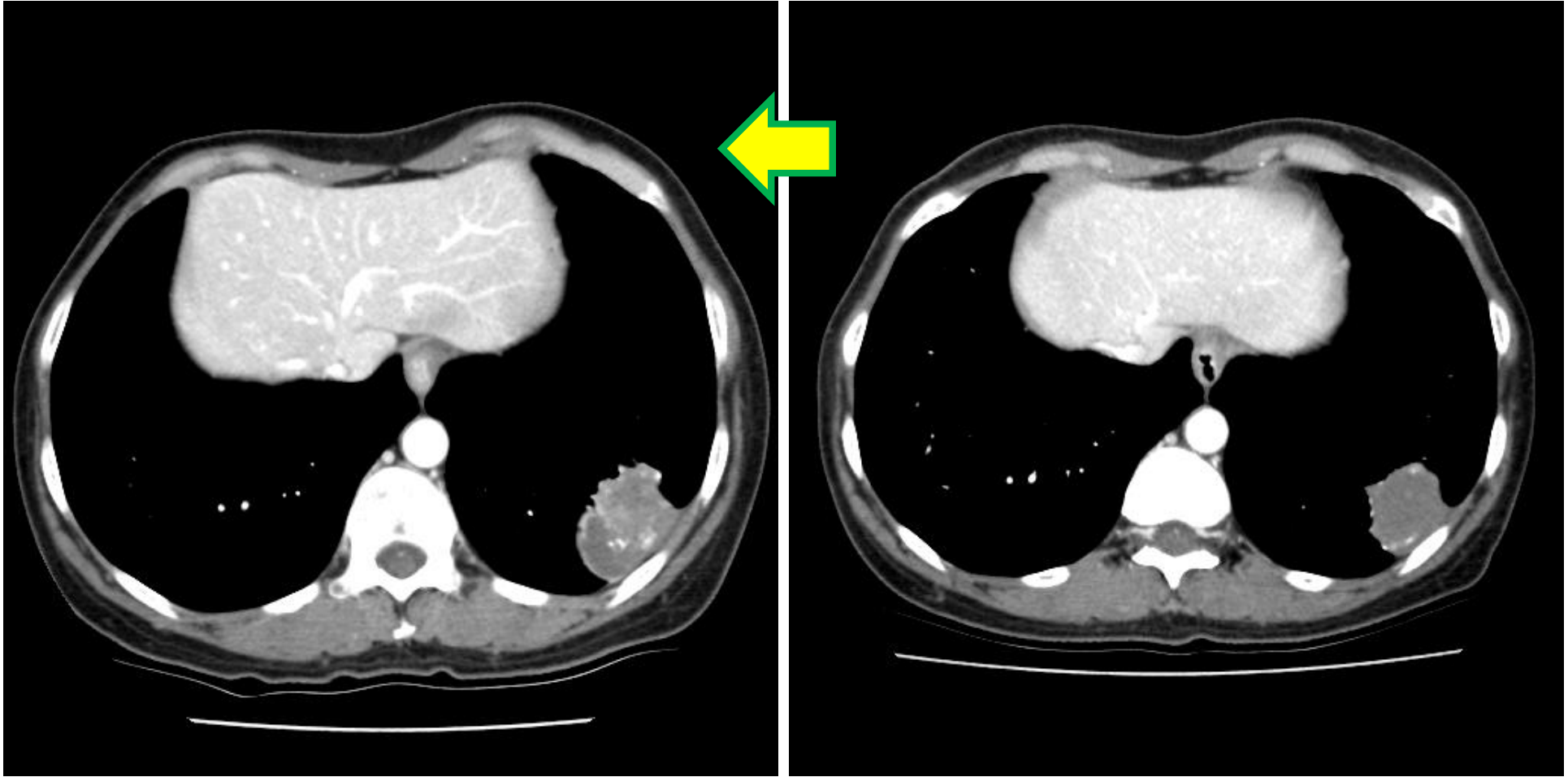


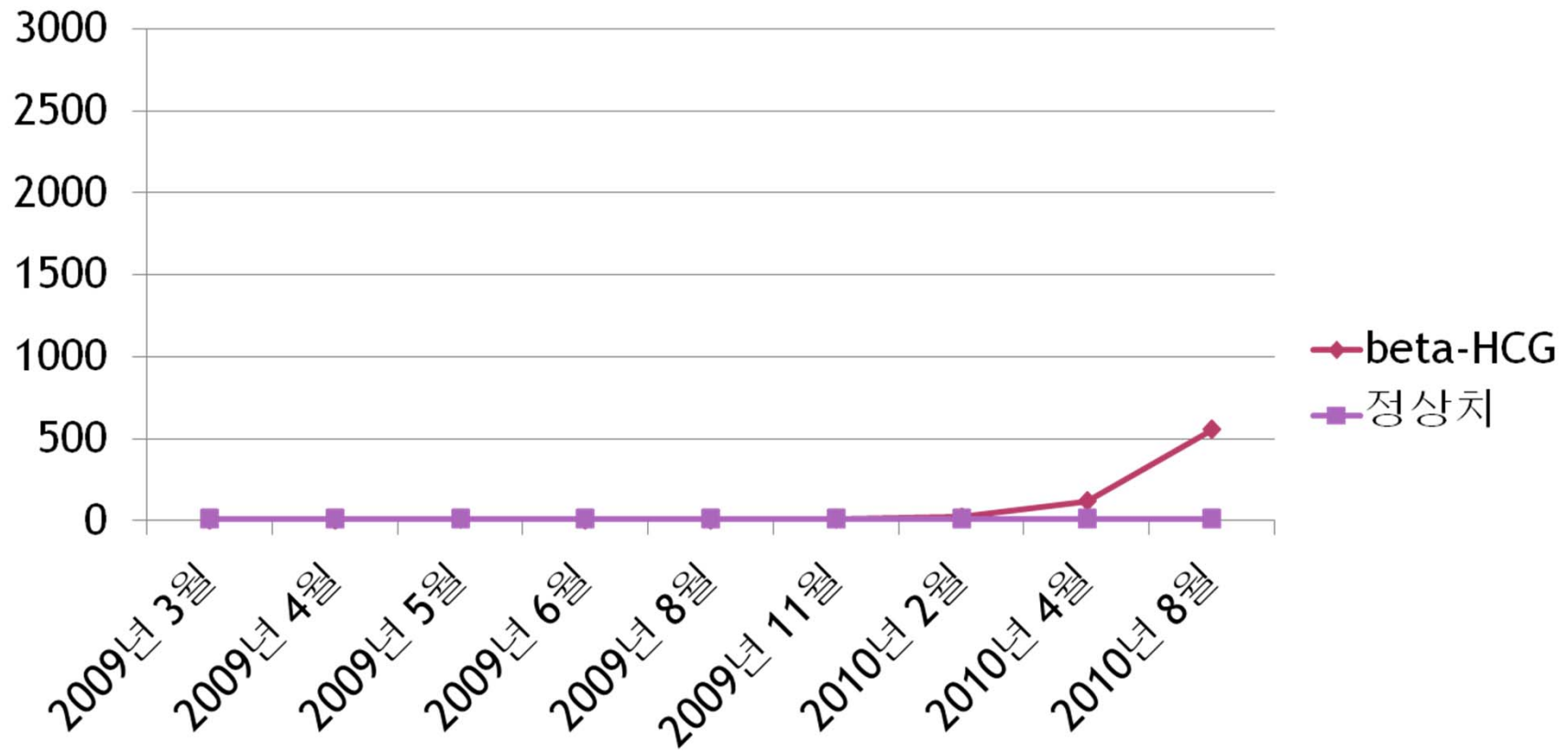
beta-HCG

Cerebrum, tumor removal

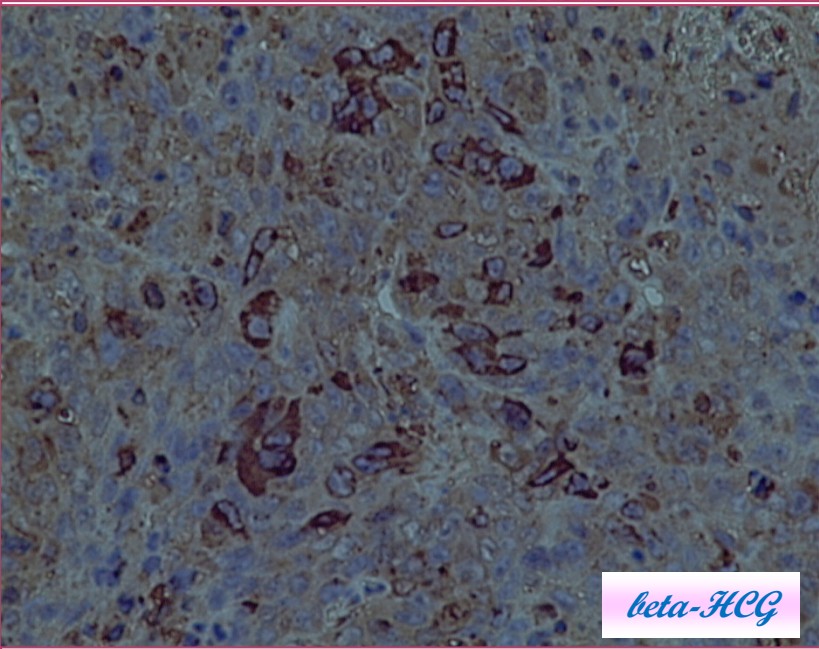
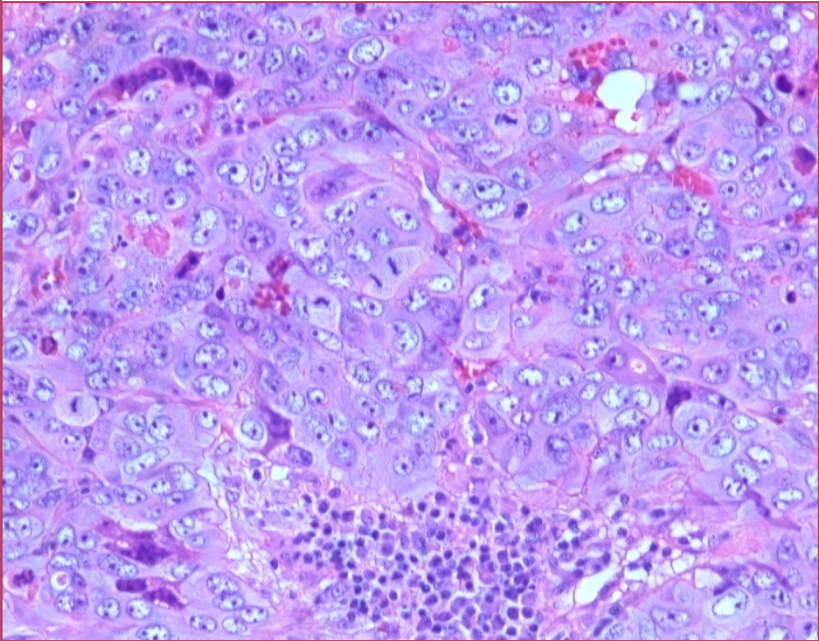
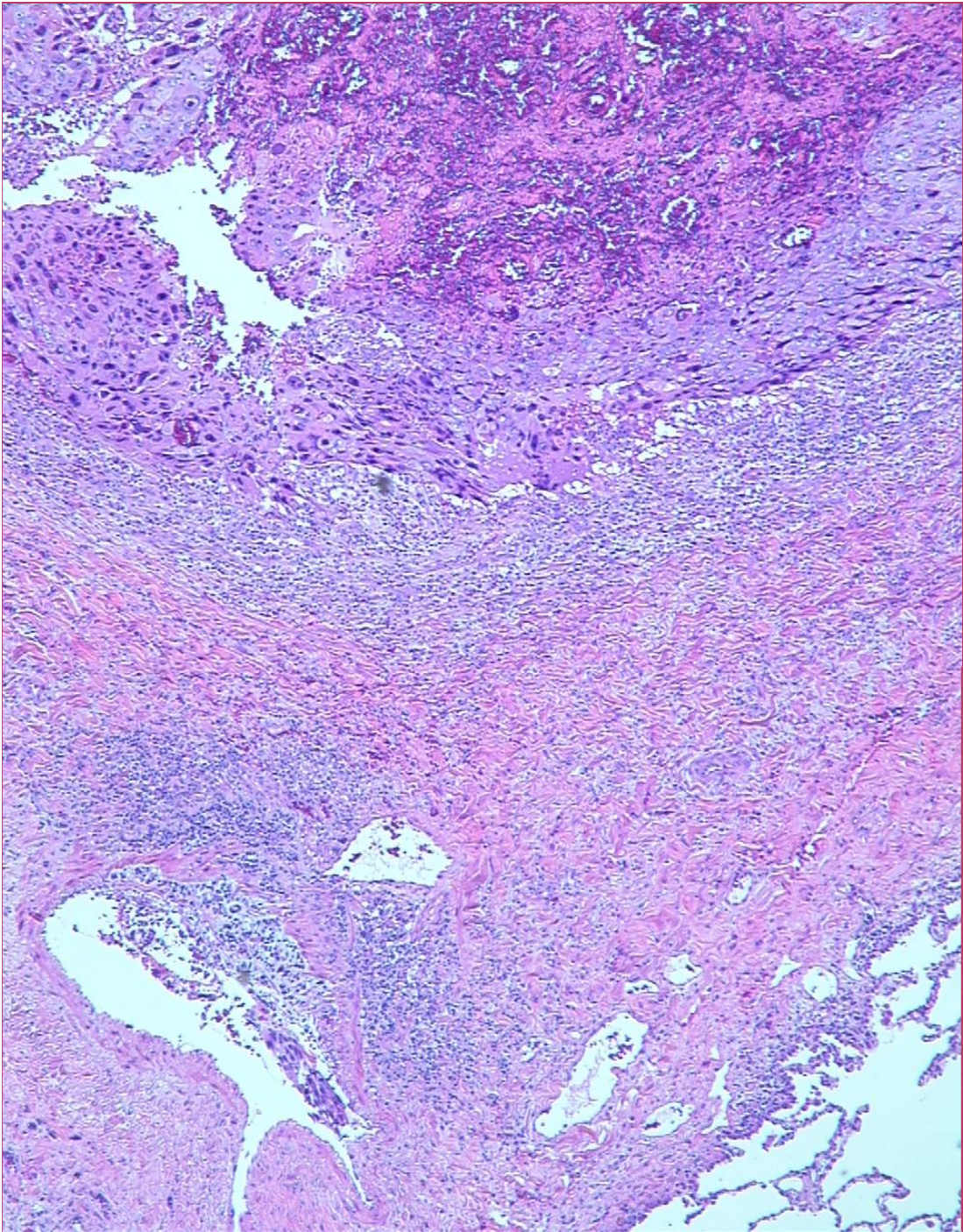


* etoposide, methotrexate, actinomycin D, cyclophosphamide, and vincristine

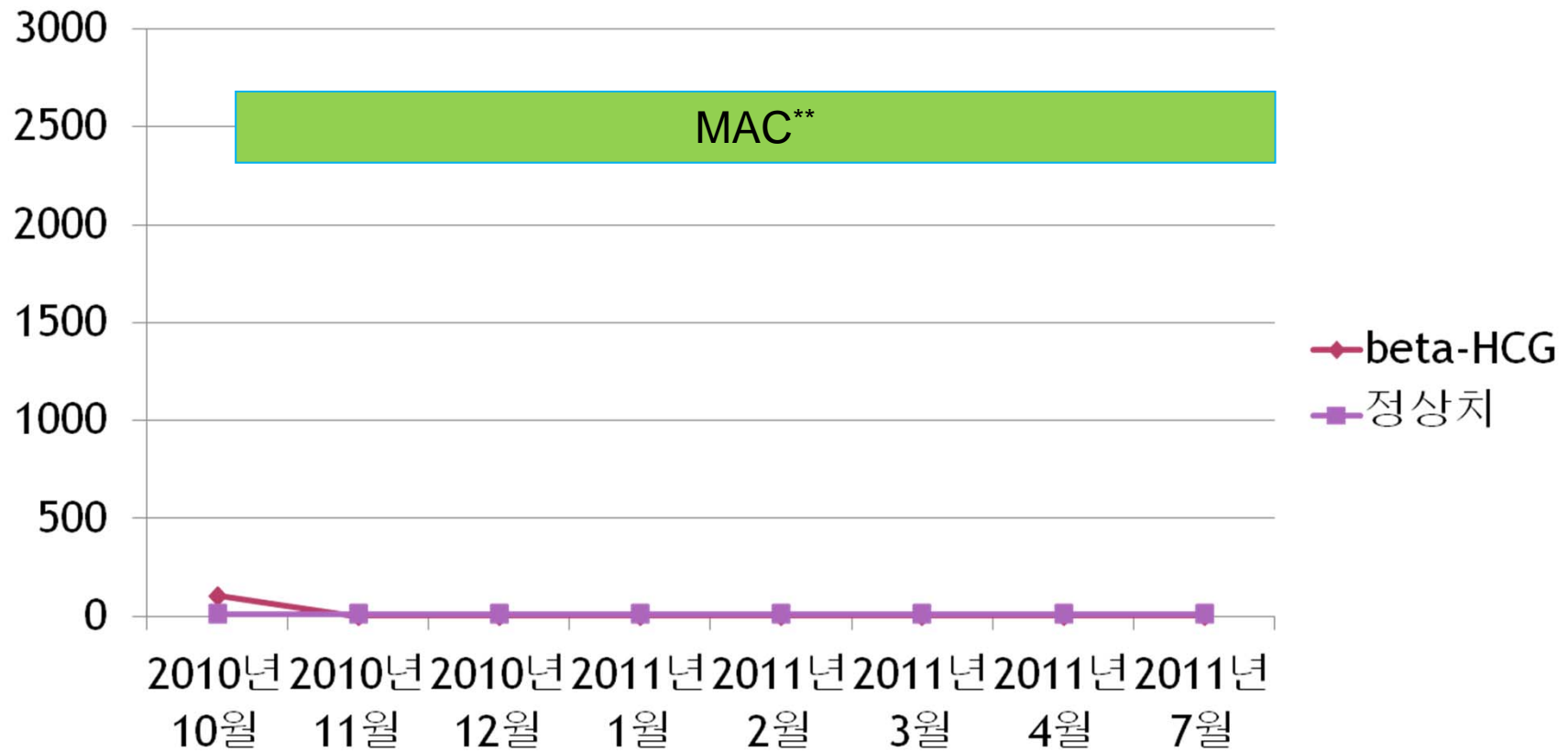




Lung, LLL, wedge resection



beta-HCG



** methotrexate, actinomycin D, cyclophosphamide

Presumptive diagnosis

Primary Choriocarcinoma of the Lung

THE END