

폐혈관 School 2018

Case Study (VTE)

황헌규

순천향대학교 구미병원, 호흡기내과

일시: 2018.4.21(토)

장소: 삼성서울병원

CASE 1

Case 1. Presentation & X-ray

27세 남자가 2개월 전부터 발생한 양측 흉통

최근 몸무게가 10kg 이 빠져 international clinic 에 내원

운동시 호흡곤란(+)

국적은 이디오피아로 한국에 온 지 5년

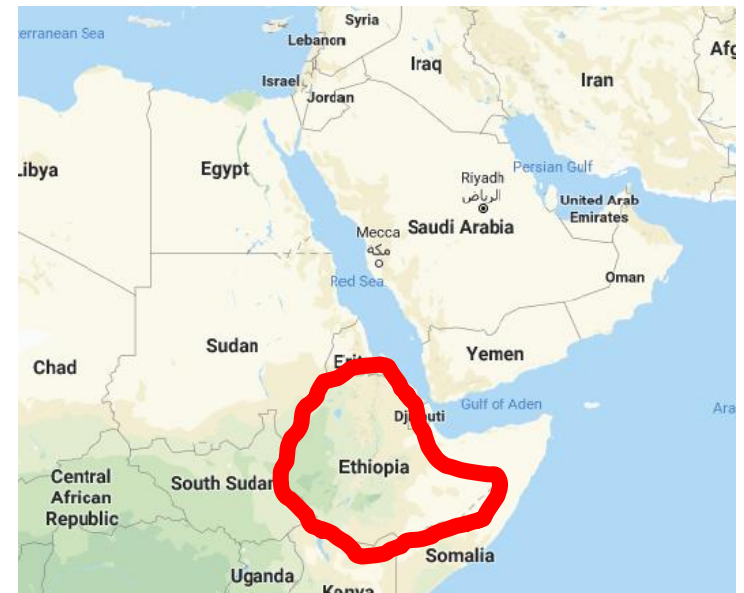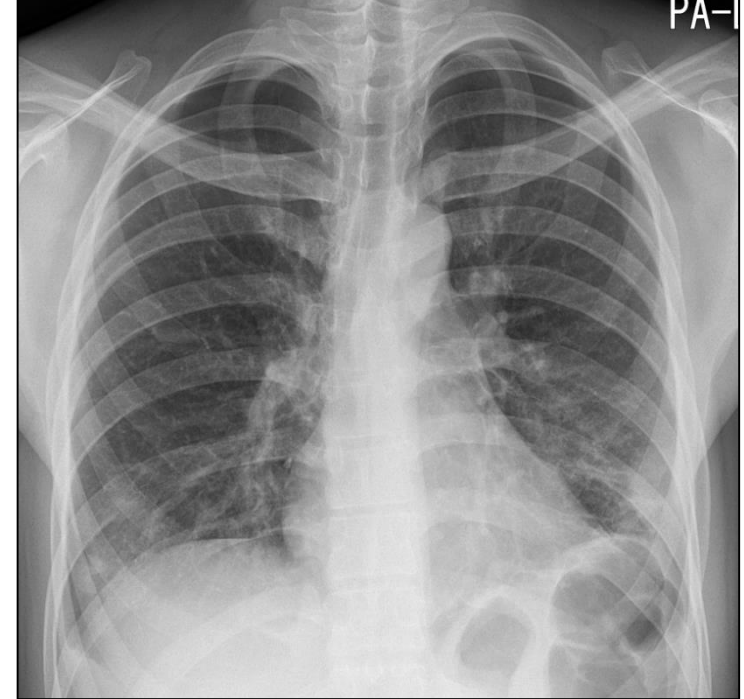
샤시 공장에서 일을 하였지만

지금은 몸이 좋지 않아 일을 쉬고 있는중임.

진통제 및 근이완제를 투여하였고

통증은 약간 호전되었다고 하고,

운동시 호흡곤란도 호전되었다고 하였다.



Case 1. Lab

- ❖ Vital sign : BP 124/74 mmHg, PR 108/min, RR 16/min, BT 38.1°C
- ❖ CBC : 16,900 – 9.2 – 29.2 – 749,000 [MCV 73.8 fL (87-104), MCH 23.2 pg (29-33), MCHC 31.4 g/dL (32-36)]
- ❖ PB morphology : microcytic normochromic RBC, Anisocytosis (++)
- ❖ Chemistry : BUN/Cr 23.9/0.89 mg/dL, T-protein 9.2 g/dL, Albumin 3.8 g/dL (3.5-5.2), Globulin 5.4 g/dL (1.2-2.5), Bilirubin 0.3 mg/dL (0-1.2), AST : 33 U/L (0-40), ALT : 50 U/L (0-41), γ -GT : 221 U/L (5-61), ALP : 324 U/L (35-130), LDH : 254 U/L (0-250), CRP (정량) : 10.32 mg/dL (0.0-0.5)
- ❖ D-dimer : 2,408 ng/mL (0 – 243)
- ❖ Malaria test : (-)
- ❖ RPR : 0.0 R.U. (0 – 0.9)
- ❖ HIV Ag/Ab combo : (-)
- ❖ HBs Ag/Ab : (-/-), Anti-HCV : (-),
- ❖ Anti-HAV IgG : (+)

Case 1. Lab

- ❖ Vital sign : BP 124/74 mmHg, PR 108/min, RR 16/min, BT 38.1°C
- ❖ CBC : 16,900 – 9.2 – 29.2 – 749,000 [MCV 73.8 fL (87-104), MCH 23.2 pg (29-33), MCHC 31.4 g/dL (32-36)]
- ❖ PB morphology : microcytic normochromic RBC, Anisocytosis (++)

❖ Chemistry : BUN/Cr 23/1.2
 Globulin 5.4 g/dL (1.2-4.5)
 (0-41), γ -GT : 221 U/L
 : 10.32 mg/dL (0.0-0.5)

❖ D-dimer : 2,408 ng/mL

❖ Malaria test : (-)

❖ RPR : 0.0 R.U. (0 – 0.9)

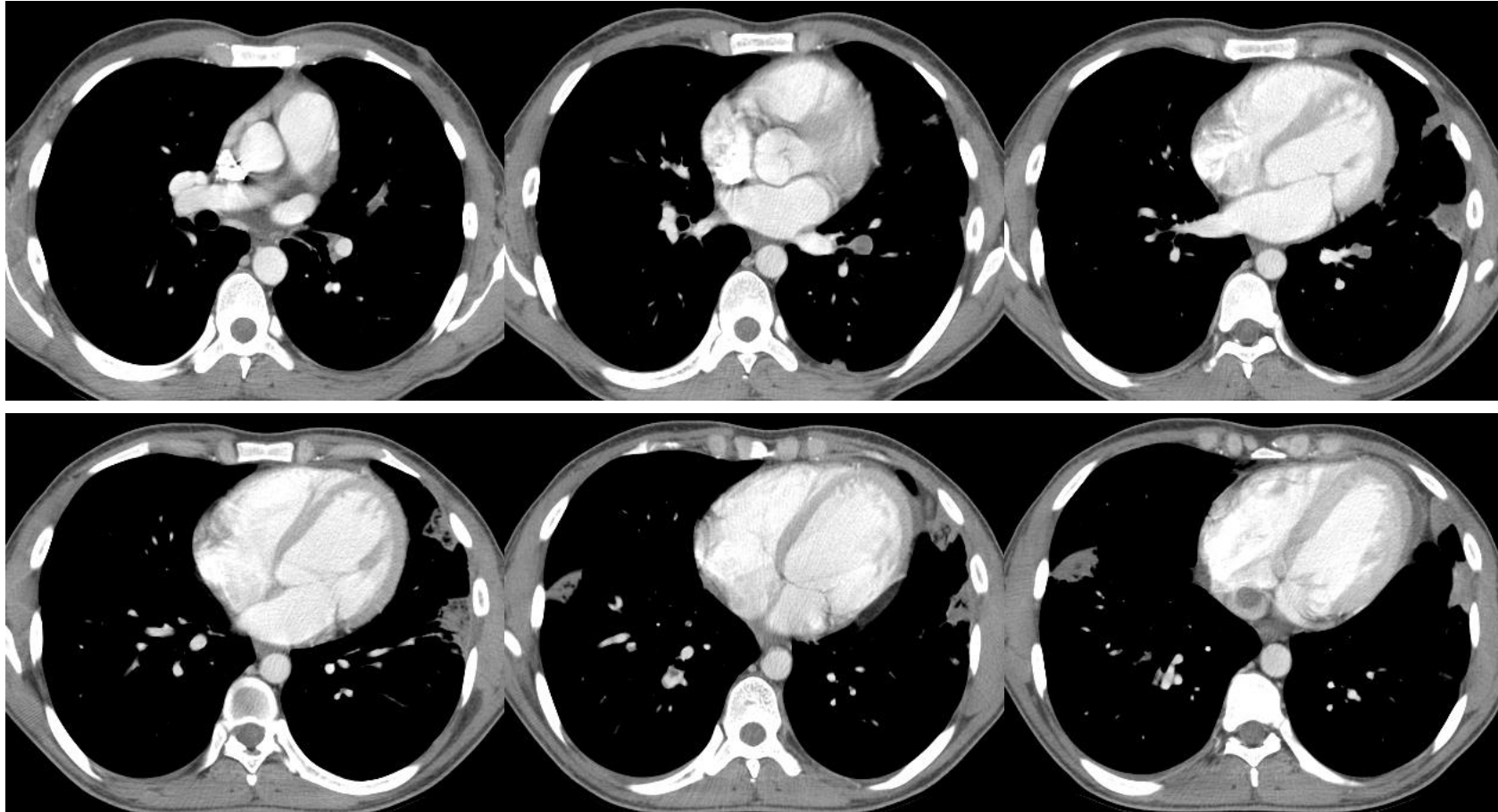
❖ HIV Ag/Ab combo : (-)

❖ HBs Ag/Ab : (-/-), Anti-

❖ Anti-HAV IgG : (+)

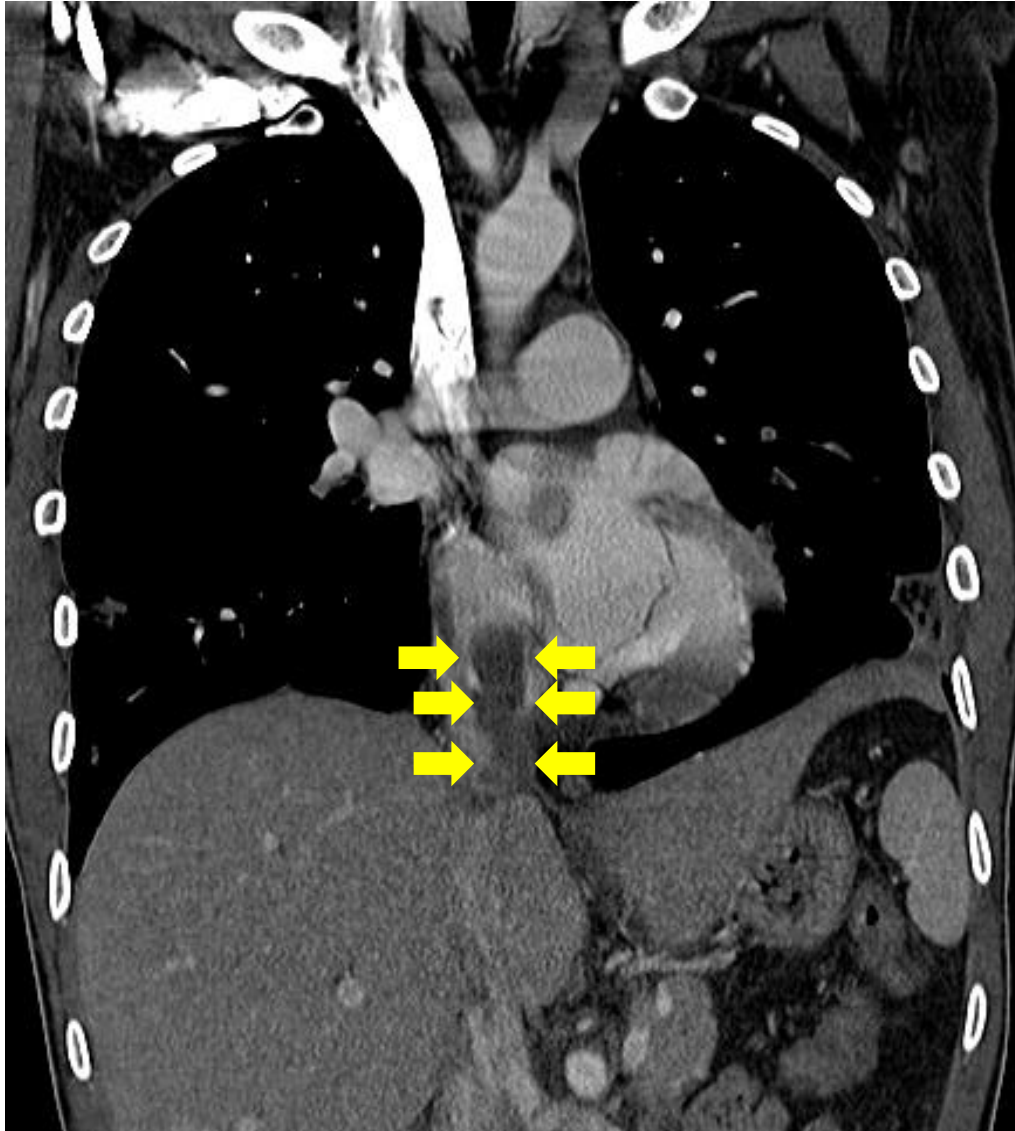임상적 특징	점수
심재정맥혈전증의 임상적 증상 및 징후	3.0
폐색전증을 우선적 진단으로 고려하는 경우 ✓	3.0
심박수가 분당 100회를 초과 ✓	1.5
지난 4주 이내에 수술을 받았거나, 거동이 안된 경우(>3일)	1.5
심재정맥혈전증이나 폐색전증의 과거력	1.5
객혈	1.0
활동중인 암 (6개월 이내에 치료를 받았거나 보존적 치료)	1.0
폐색전증의 가능성	점수
가능성 높지 않음	≤ 4

Case 1. CT (Axial View)



2017-12-01

Case 1. Coronal View



- 입원치료를 원치 않아 외래에서 thrombophilia test 를 시행하고 rivaroxaban 15mg bid를 시작하였다.
- 2일 후 입원하여 치료 및 정밀검사 시행함.
- 이러한 영상소견은 어떻게 생각하시나요?

Case 1. Lab

- ❖ **Anti-thrombin III** : 131% (65 - 129)
- ❖ **Factor VIII** : **252%** (60-140)
- ❖ **Protein C (functional)** : 135% (70 - 148)
- ❖ **Protein C (immunologic)** : 113.9% (72 - 160)
- ❖ **Protein S (functional)** : **58%** (77 - 143)
- ❖ **Free protein S (Immunologic)** : 73.9% (69.4 – 138.3)

- ❖ **Lupus Anticoagulant Ab** : screening (+), confirm (-)
- ❖ **Anti-Cardiolipin Ab (IgG, IgM)** : (-/-)
- ❖ **Anti- β_2 glycoprotein Ab (IgG, IgM)** : (-/-)
- ❖ **ANA** : (-)

Case 1. Lab

- ❖ **Troponin-T (hs)** : 0.005 ng/mL (0 - 0.1)
- ❖ **NT-pro-BNP** : 114 pg/mL (0 – 121)
- ❖ **Echocardiography** : normal LV systolic and diastolic function, mild MR, mild to moderate AR, mild TR
- ❖ **Venous USG for lower extremities** : Normal

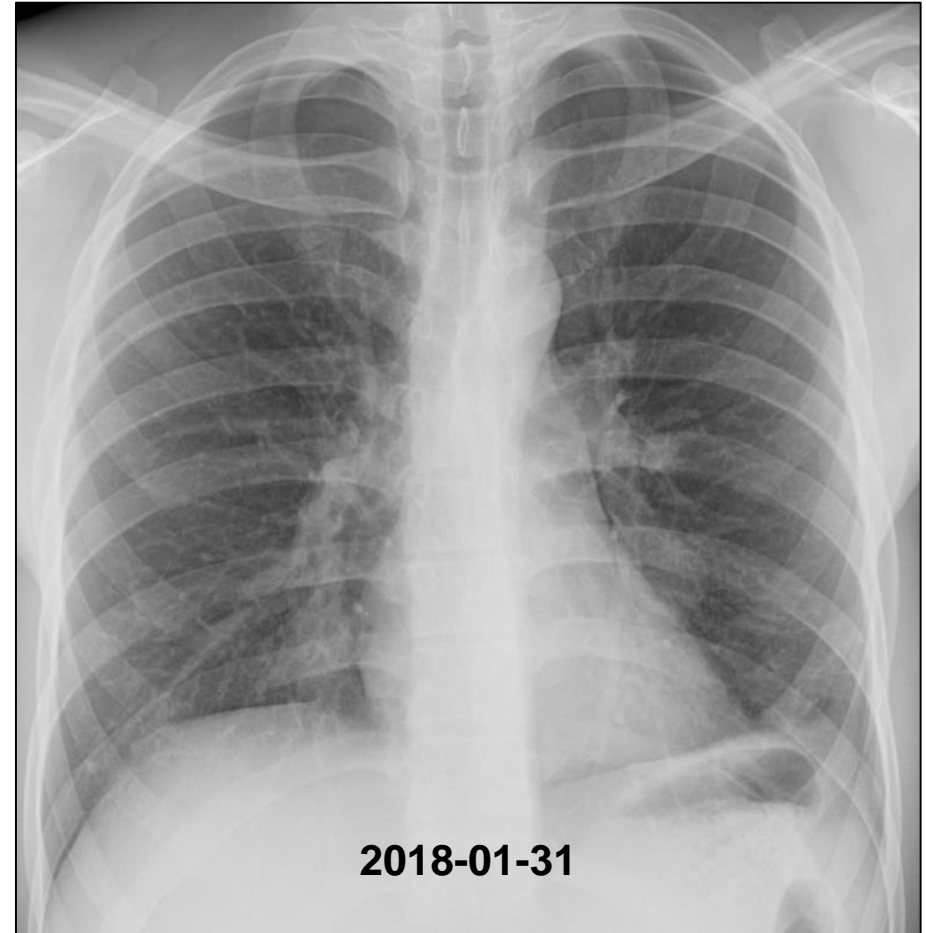
- ❖ **RF** (rheumatoid factor) : 10 IU/mL (0 – 14)
- ❖ **Anti-CCP** (anti-cyclic citrulinated peptide) : 0.5 U/ml (neg < 5)
- ❖ **C3** : 175mg/dL (90 – 180), **C4** : **50**mg/dL (10 – 40)
- ❖ **IgG** : **1,939**mg/dL (700–1,600), **IgA** : **526**mg/dL (70–400), **IgM** : 72mg/dL (40–230)
- ❖ **ANCA** (정성) : (-)

Case 1. Clinical Course

내원 9일째(12월 6일) 여전히 **흉통**으로 잠을 잘 수가 없어 본과 외래로 내원하였다. **운동시 호흡곤란**은 호전되었지만 남아 있다고 하였다.

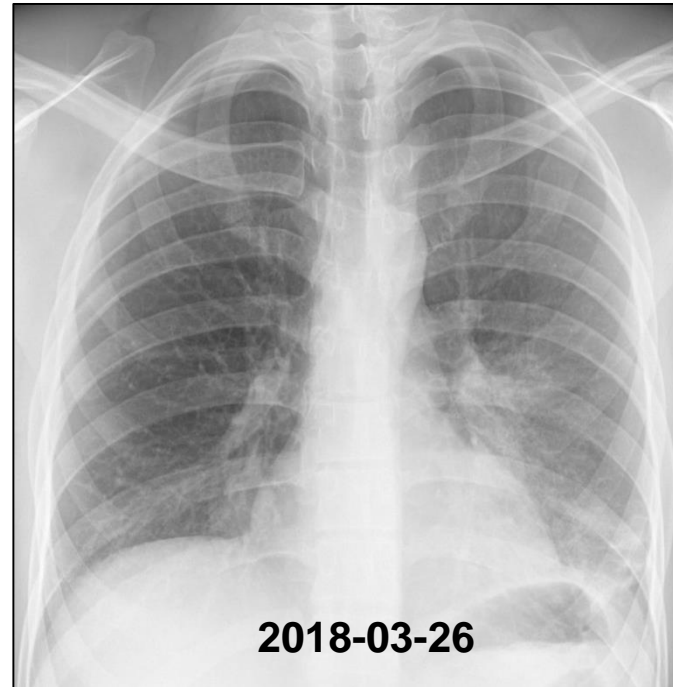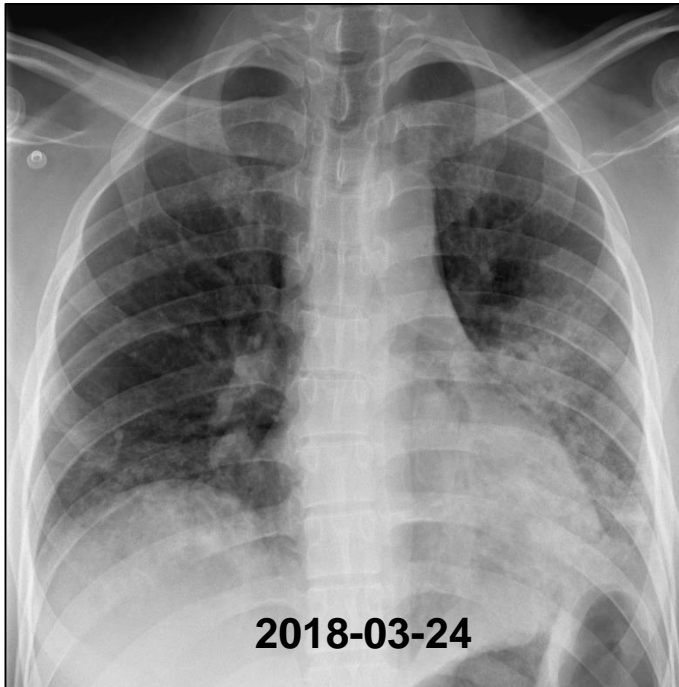
Case 1. 2개월째

- 환자는 항응고제 복용 후 호흡곤란도 없고 열도 없다고 하여 Rivaroxaban 20mg qd 를 지속 복용함.
- ❖ **D-dimer** : 219 ng/mL (0-243) <- 2,408
- ❖ **CBC** : 10,400 – 12.3 – 39.0 – 574,000
- ❖ **Chemistry** : **BUN/Cr** 8.5/0.63 mg/dL, **T-protein** 9.3 g/dL, **Albumin** 4.6 g/dL (3.5-5.2), **Globulin** 4.7 g/dL (1.2-2.5), **Bilirubin** 0.2 mg/dL (0-1.2), **AST** : 18 U/L (0-40), **ALT** : 25 U/L (0-41), **γ-GT** : 69 U/L (5-61), **ALP** : 123 U/L (35-130), **LDH** : 190 U/L (0-250),



Case 1. Hemoptysis (4개월째)

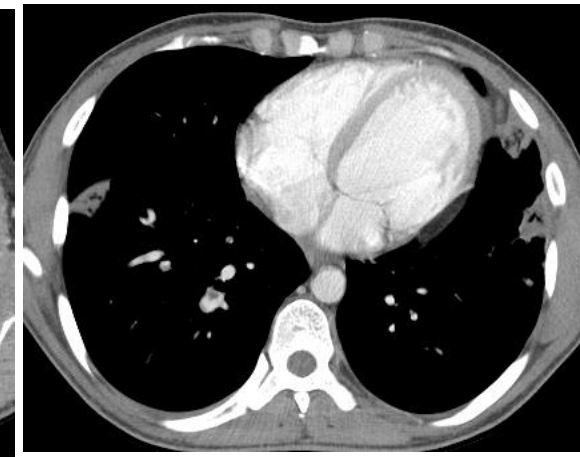
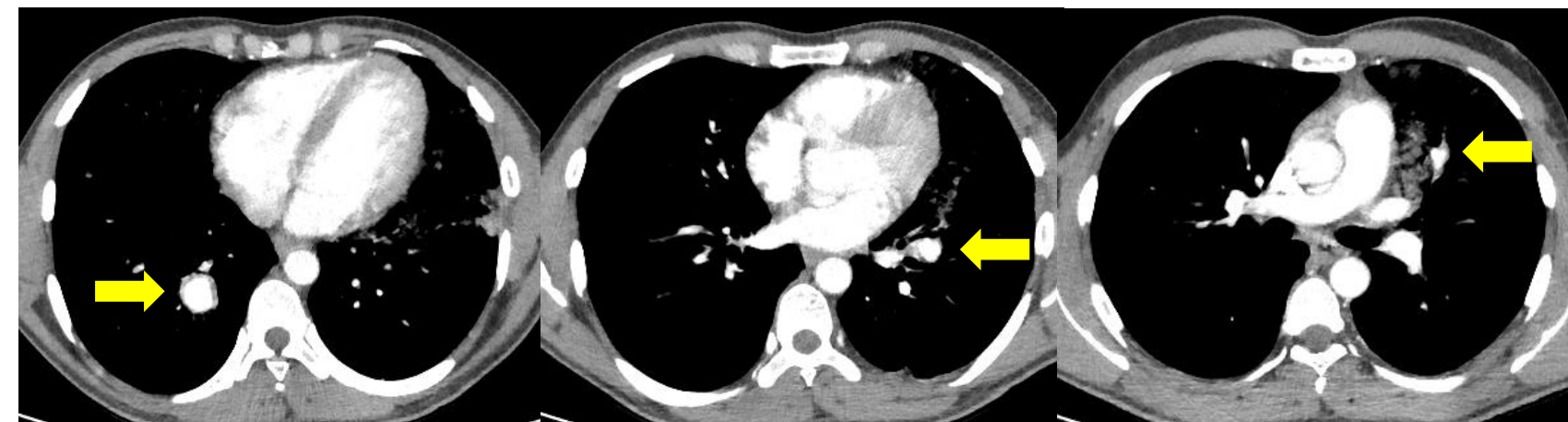
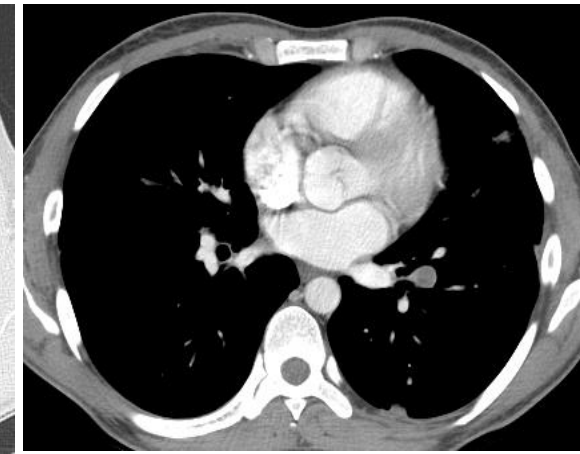
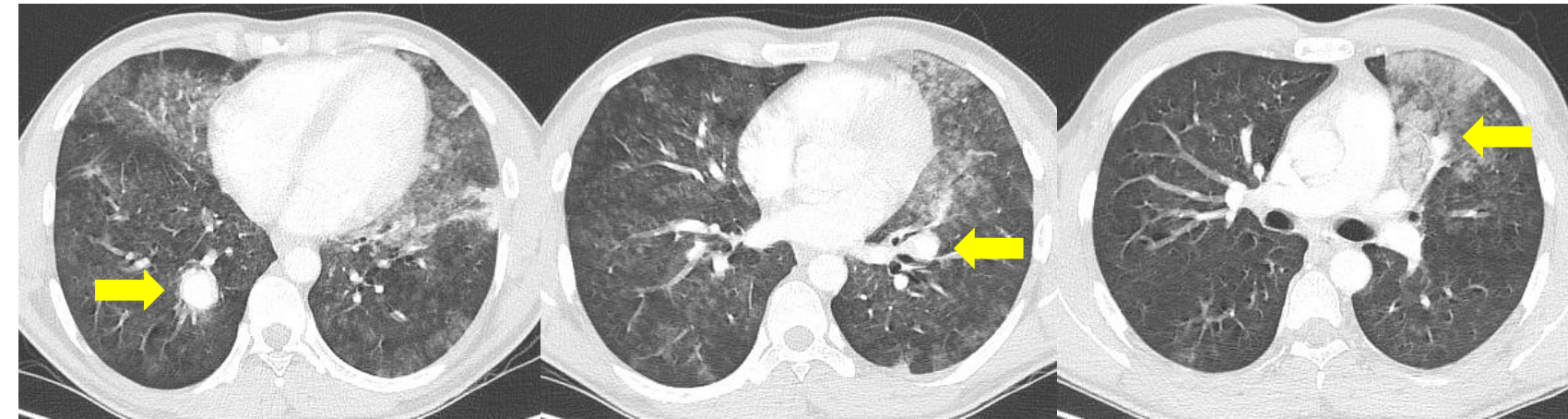
- 환자는 외상이나 다른 이상 없이 점심식사를 하던 중 갑자기 발생한 객혈이 발생하여 외부 병원 경유 후 본원으로 전원됨. 객혈의 총량은 500 cc 정도.
- Vital sign : BP 137/86 mmHg, PR 114/min, RR 20/min, BT 37.6°C



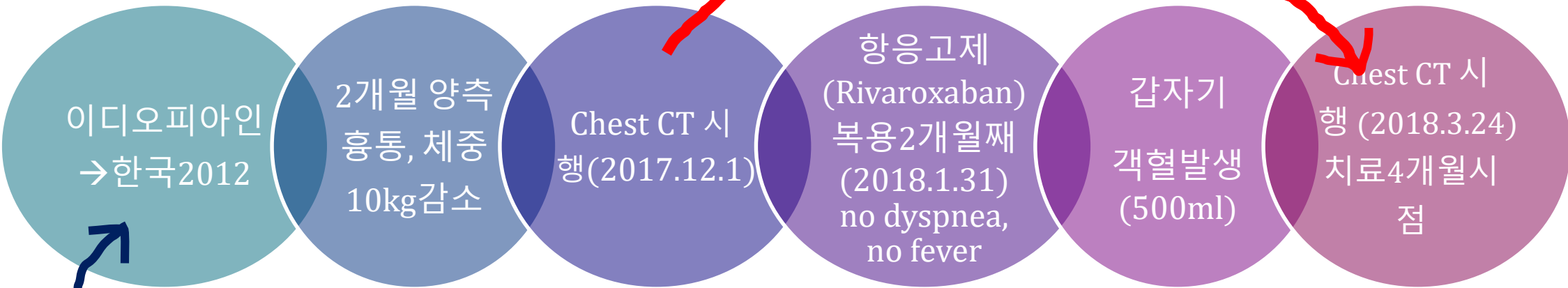
Case 1. Chest CT

2018-03-24

2017-12-01



Case 1. Course



- 치료 경과중 출혈(3.24)시 시행한 CT에서 처음 CT(12.1) 변화소견은?
- 이 환자(이디오피아인, 25세)에서 혈전의 원인은?
- 향후 항응고제의 처방 계획은?
- 재발 위험도 평가는?

Case 1. Course

이디오피아인 →
한국2012

2개월 양측 흉
통, 체중10kg
감소

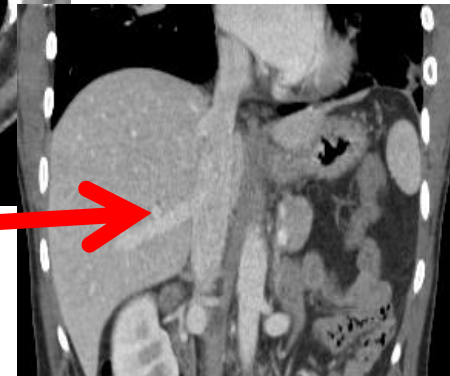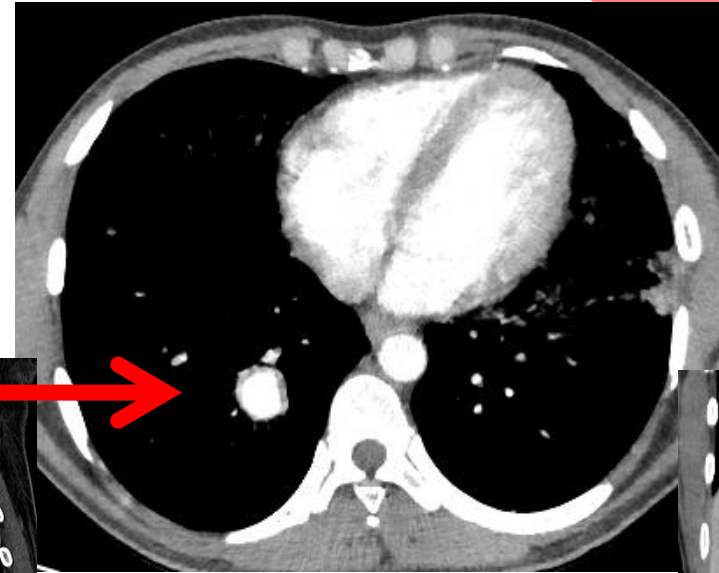
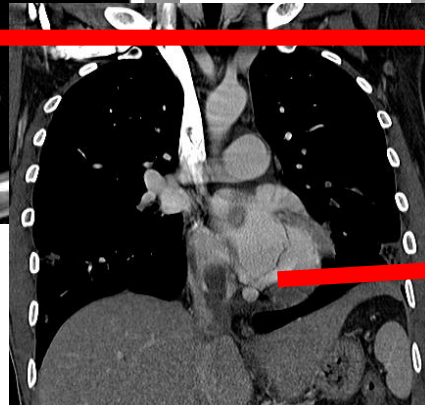
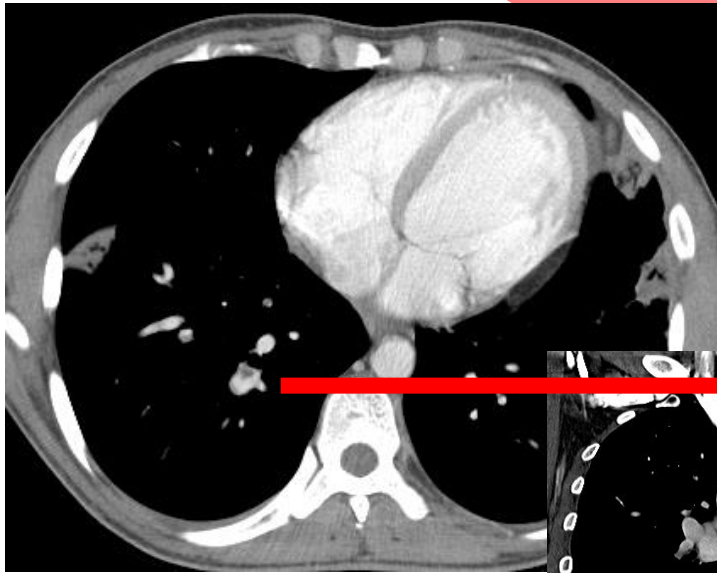
**Chest CT
(2017.12.1)**

항응고제
(Rivaroxaban) 복
용2개월째
(2018.1.31) no
dyspnea, no fever

갑자기
객혈발생
(500ml)

**Chest CT 시행
(2018.3.24)**

치료4개월째



Case 1. Course

이디오피아인 → 한국 2012

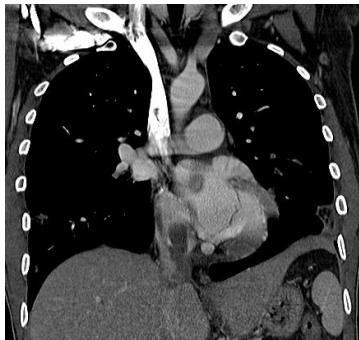
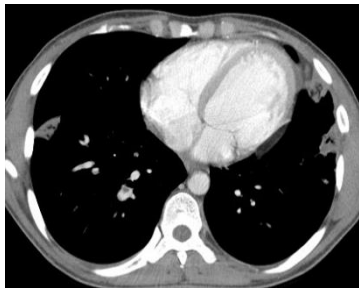2개월 양측 흉통, 체중 10kg 감소

Chest CT
(2017.12.1)

항응고제
(Rivaroxaban) 복용
2개월째 (2018.1.31)
no dyspnea, no fever

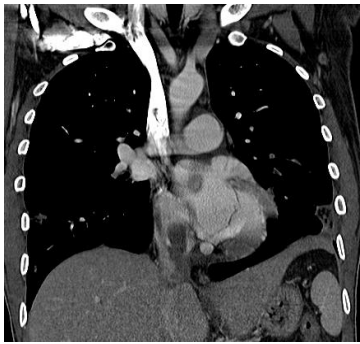
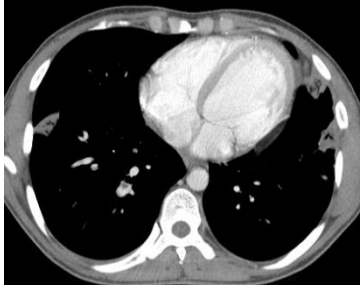갑자기
객혈 발생
(500ml)

Chest CT 시행
(2018.3.24)
치료 4개월째



- Thrombosis in Inferior Vena Cava
 - Congenital anomaly (0.5~1% of general population)
 - Unretrieved IVC filter
 - Proximal DVT
 - Renal cell carcinoma
 - **Primary Budd-Chiari syndrome** rather than secondary one
 - **Systemic vasculitis**

Case 1. Course



- Thrombosis in IVC ← Systemic vasculitis
 - Behcet's syndrome
 - ANCA-associated vasculitis
- Based on relationship between inflammation and thrombosis and between immune and coagulation system

- Behcet's syndrome
 - **Recurrent oral ulcer** at least three times in one year
 - And two of the following (**Uveitis, acne, genital ulcer, and Pathergy test**)
- ANCA-associated vasculitis
 - ANCA (negative)

Case 1. Course

이디오피아인 →
한국 2012

2개월 양측 흉통,
체중 10kg 감소

Chest CT
(2017.12.1)

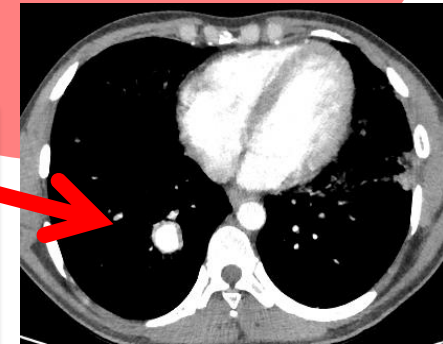
항응고제
(Rivaroxaban) 복용
2개월째 (2018.1.31)
no dyspnea, no
fever

갑자기
객혈 발생
(500ml)

Chest CT 시행
(2018.3.24)

치료 4개월째

- Pulmonary artery aneurysm
 - More than 50% of all cases: association with congenital heart disease (PDA, VSD, ASD)
 - Acquired cause (Untreated syphilis, tuberculosis)
 - Vasculitis (**Behcet's syndrome, Hughes-Stovin syndrome**)
 - Pulmonary artery hypertension



Case 1. Course

이디오피아인
→ 한국 2012

2개월 양
흉통, 체
10kg 감소

Chest CT
(2017.12.1)

항응고제
(Rivaroxaban) 복용
2개월째 (2018.1.31)
no dyspnea, no fever

갑자기
객혈 발생
(500ml)

Chest CT 시행
(2018.3.24)
치료 4개월째

- Antiphospholipid syndrome
 - Lupus Anticoagulant Ab : screening (+), confirm (-)
 - Anti-Cardiolipin Ab (IgG, IgM) : (-/-)
 - Anti- β_2 glycoprotein Ab (IgG, IgM) : (-/-)
- Thrombotic disorder
 - Prothrombin G20210A mutation : not detected
 - Factor V Leiden mutation : not detected
- ❖ JAK2 gene, p.V617F mutation : not detected
- ❖ JAK2 gene, Exon 12 mutation : not detected

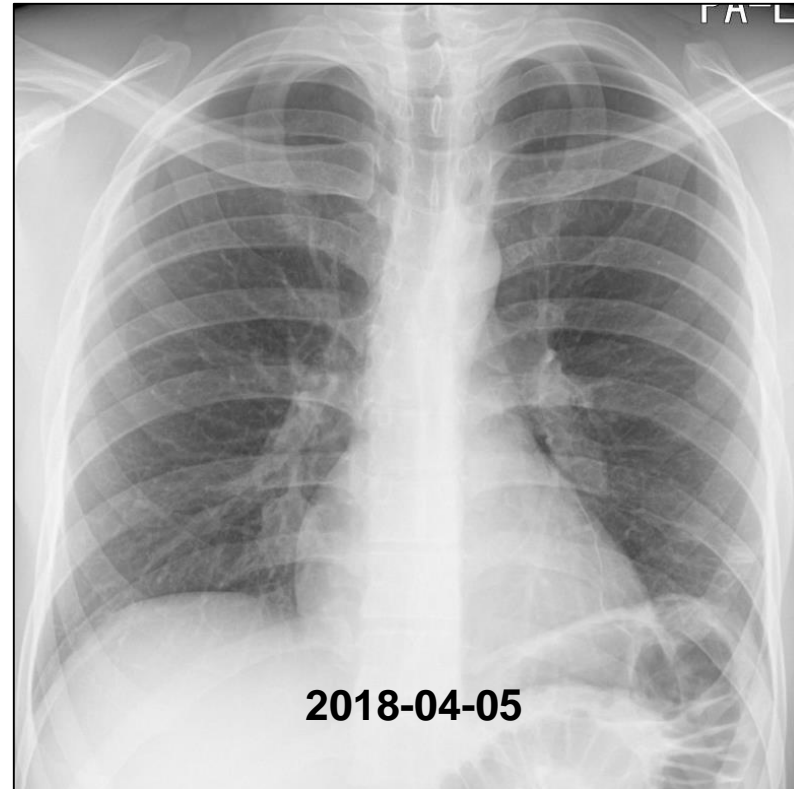
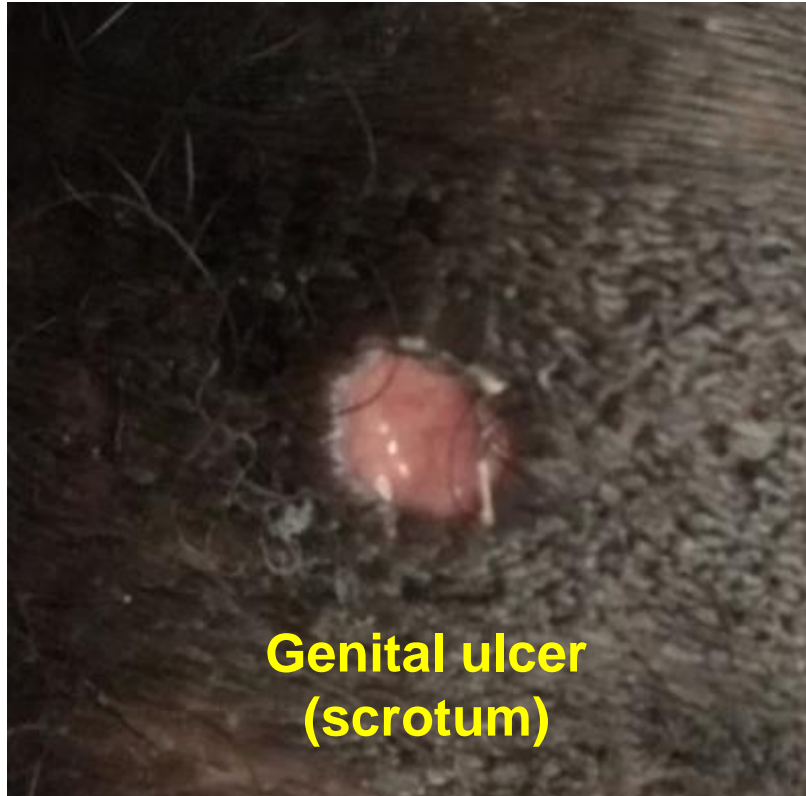Case 1. Question ?

무엇을 더 찾아보아야 할까요?

.....?

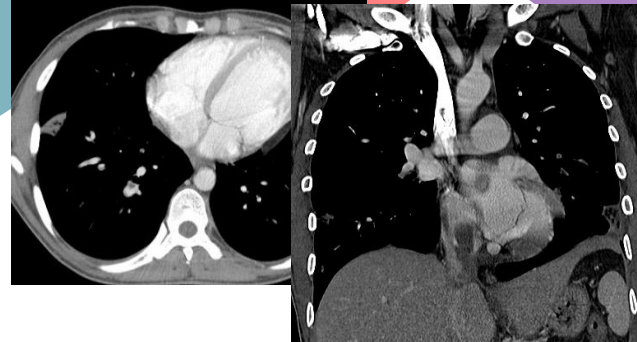
Case 1.

- 환자에게 oral ulcer 및 genital ulcer 에 대해 여러 번의 병력 청취를 하였으나 없다고 하였다. **또 다시 질문을 하였더니**, 지난 2년 동안 oral ulcer 및 genital ulcer 로 고생을 하였었다고 하며 여동생도 동일한 질병을 앓고 있다고 함.



Case 1. Course

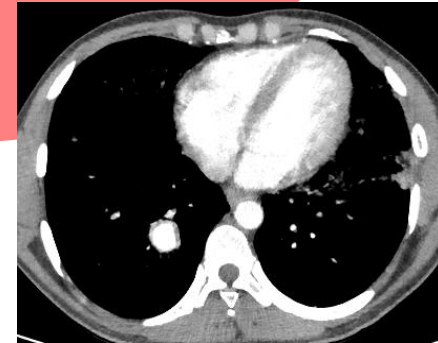
이디오피아인
Young adult
Behcet's disease
→ 한국 2012
→ 2017



CT 2017.12
IVC
thrombosis
Pulmonary
embolism

항응고제(복용2
개(2018.1.31) no
dyspnea, no fever

치료 4개월째
객혈(500ml)
CT 2018.3-
Aneurysm



Case 1. Treatment & long-term follow-up

사람이 온다는 건 실로 어마어마한 일이다.

그는 그의 과거와 현재와 그리고 **그의 미래**와 함께 오기 때문이다.

한 사람의 일생이 오기 때문이다.

- 정현종, 방문객-

- 본 case의 환자는 **steroid pulse therapy (1,000mg, 3days)** 시행하고, PDL 15mg 24일간 사용, **항응고제 10일간 중단**하였다가 재투여하면서 퇴원함. 외래 추적 관찰 중.
- 이 환자의 미래는? 어떻게 **follow-up** 해야 할까요?

Case 1. Vascular involvement in Behcet's disease

- 20 to 420/100,000 in Turkey
- 80/100,000 in Iran
- 0.64/100,000 in the UK.

- **Vascular involvement** in Behcet's disease: 30% of affected population
- **Second** highest cause of pulmonary artery aneurysm

Davatchi et al. Expert Rev Clin Immunol 2017;13(1):57-65

Balta et al. Curr Opin Cardiol 2016;31(4):451-457

Boutra et al. Clin Med Res 2018

Case 1. Treatment & long-term follow-up

- 이 환자의 미래는? 어떻게 follow-up 해야 할까요?
- formation of both **thrombosis and aneurysm** in Behçet's disease is caused by **inflammation** rather than **a hypercoagulable state**, **immunosuppression** is the cornerstone of treatment.
- The efficacy of **tumor-necrosis-factor- α inhibitors** in patients with **arterial aneurysms** related to Behçet's disease (**Infliximab**)

Adler et al. Arthritis Care Res 2012;64:607-611

Hamurhydan Semin Arthritis Rheum 2015;45:369-73

Case 1. Treatment & long-term follow-up

CASE RECORDS of the MASSACHUSETTS GENERAL HOSPITAL

Founded by Richard C. Cabot
Eric S. Rosenberg, M.D., *Editor*
Virginia M. Pierce, M.D., David M. Dudzinski, M.D., Meridale V. Baggett, M.D.,
Dennis C. Sgroi, M.D., Jo-Anne O. Shepard, M.D., *Associate Editors*
Allison R. Bond, M.D., *Case Records Editorial Fellow*
Emily K. McDonald, Sally H. Ebeling, *Production Editors*



Case 11-2018: A 48-Year-Old Woman
with Recurrent Venous Thromboembolism
and Pulmonary Artery Aneurysm

Harrison W. Farber, M.D., Shaunagh McDermott, M.D., Alison S. Witkin, M.D.,
Noreen P. Kelly, M.D., M.B.A., Eli M. Miloslavsky, M.D.,
and James R. Stone, M.D., Ph.D.

- The efficacy of **tumor-necrosis-factor- α inhibitors** in patients with **arterial aneurysms** related to Behçet's disease (**Infliximab**)
- PDL therapy for 6 weeks
- Cyclophosphamide added
- Repeat CT: increase in the size of aneurysm
- Tx of **infliximab** → improvement of inflammatory marker
- CT: slight decrease in the size of the aneurysm

Adler et al. Arthritis Care Res 2012;64:607-611

Hamurhydan Semin Arthritis Rheum 2015;45:369-73

Farber et al. NEJM 2018 April

Case 1. Treatment & long-term follow-up

How I Treat



How I treat recurrent venous thromboembolism in patients receiving anticoagulant therapy

Sam Schulman

39-year-old man from Syria with unprovoked VTE (popliteal vein)

After 2 month treatment, calf is more swollen.

Upon **further questioning**, he admits to having had some ulcer in his mouth

On physical exam, there is acne. (Five years ago, he had inflammation in 1 eye.

Anticoagulants have **not provided good protection** against recurrence.

In 2008 Recommendation of European League Against Rheumatism (EULAR), anticoagulation received weakest strength.

Sam Schulman Blood 2017;129(25):3285-3293

Celik Rheumatolo Int. 1996;16(1):43-44

Case 1. Answer

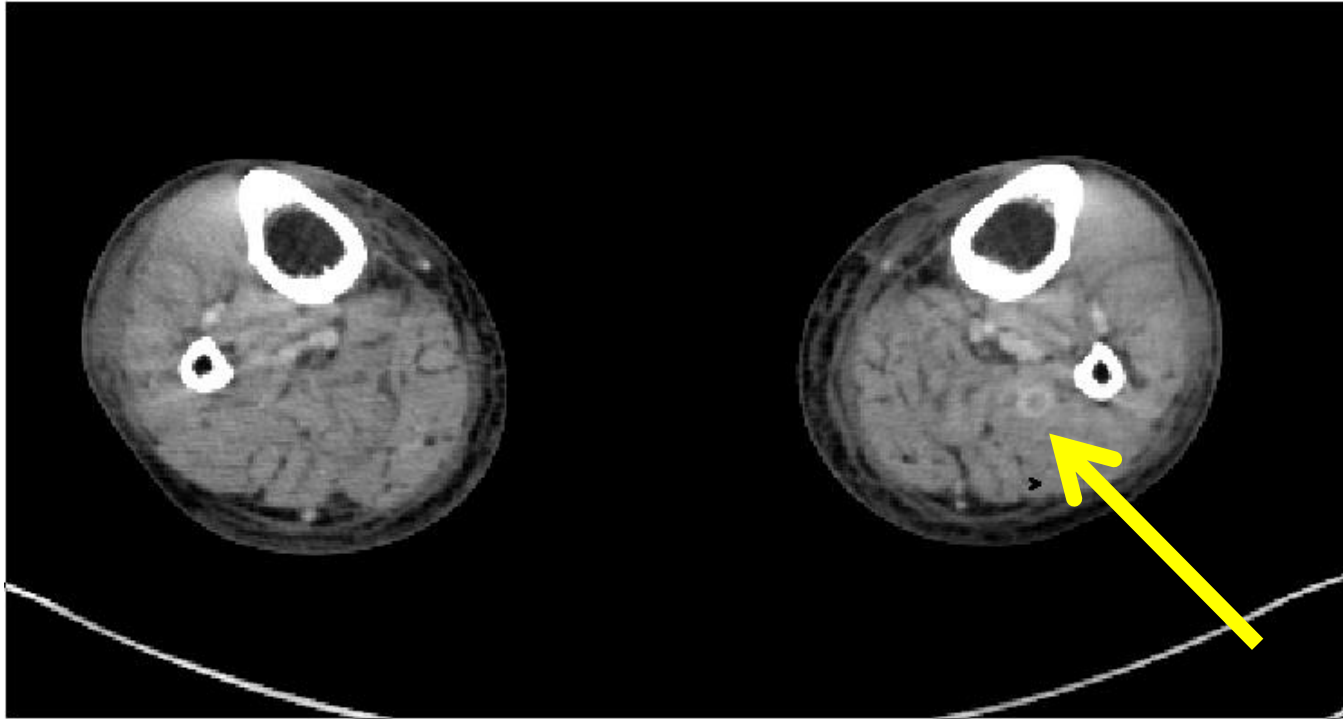
- 치료 경과중 출혈(3.24)시 시행한 CT에서 처음 CT(12.1) 변화소견은?
- 이 환자(이디오피아인, 25세)에서 혈전의 원인은?
- 향후 항응고제의 처방 계획은?
- 재발 위험도 평가는?

CASE 2

Case 2. Presentation

- 74세 남자가 복부 팽만을 주소로 소화기내과에 입원하여 검사에서 **D-dimer 15, 331로 증가한 소견**으로 검사 후 협진 의뢰 되었다.
과거에 무릎수술한 적이나 외상을 당한적은 없었고, 호흡곤란 없었고, 진찰에서 부종이나 압통은 호소하지 않았다.
- 혈압 120/80mmHg,
- Hemoptysis(-), VTE Hx(-),

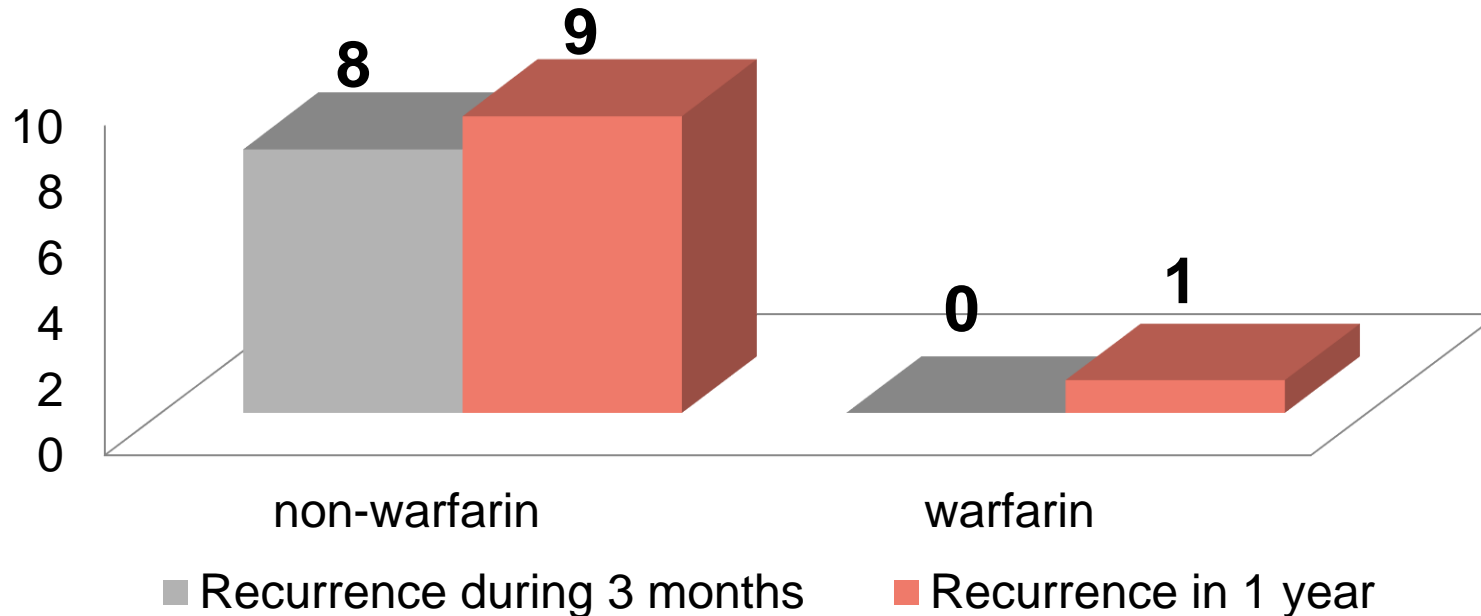
Case 2. CT



- 이 환자에서 치료는?

Comparison of outcomes between untreated(28) and treated(23) patients with calf-vein thrombosis

1985



- Both group received initial course of heparin and compression stocking in a randomized study of 51 patients
- Monitored by serial isotope test and physical examination.
- 5 patients had recurrence with proximal extension and 1 patient had a pulmonary embolus.
- Recurrence rates were 29% in 3 months and 32% in 1 year.

Comparison of outcomes between untreated and treated patients with distal DVT

Meta-analysis
2006

Estimated rate of extension to proximal site

In Untreated patients

10% (95% CI, 7-12%)

In Treated patients

4% (95% CI, 3%-6%)

2008

On the basis of single trial,
the 2008 ACCP consensus recommended
to treat all calf DVTs
with a 3-month course of anticoagulation treatment
(grade 2C)

Laquerstedt et al. Lancet 1985; 2(8454): 515-8
Kearon et al. Chest 2008; 133: 454S-545S

CACTUS trials

in 259 outpatients with low-risk★ Compression alone versus anticoagulation

2016



- Efficacy (5.4% vs 3.3%, risk diff, -2.1%; p=0.54)
- Safety (0% vs 4.1%, risk diff, 4.1%; p=0.03)

Symptomatic Distal DVT in low-risk patient diagnosed by USG
EC alone vs Anticoagulation

The only randomized, placebo-controlled study
259 outpatients without active cancer or previous VTE

LMWH nadroparin sc OD or placebo for 6 weeks
EC stockings for 6 weeks and followed for 90 days.

The primary efficacy outcome: the composite of extension of calf DVT to proximal veins, contralateral proximal DVT, or PE at 6 weeks.

The primary safety outcome : major or clinically relevant nonmajor bleeding at 6 weeks.

Righini et al. J Thromb Haemost 2015; 13: 50

Righini et al. Lancet Haematol 2016; 3(12): e556-e562

**The 2016 ACCP suggest
serial imaging of the deep veins for 2 weeks
over initial anticoagulation in patients
without severe symptoms or risk factors for extension.**

The risk factors for extension include

2016

extensive thrombosis

active cancer

history of VTE

inpatient status

and no reversible provoking factor for DVT

Take Home Message

1. Behcet's disease 병력은 반복질문이 필요함.
2. Recurrence를 막고 pulmonary artery rupture를 줄이기 위해 Immunotherapy 필요
3. Distal DVT에서 경과 관찰이 가능하다. 단, risk factors를 고려해야 한다.(CACTUS study)

감사 인사

Behcet 환자 Case를 공유해 주신 김양기 교수님께 감사드립니다.

경청해주셔서 감사합니다.