

A case of chronic cough with asthma

Chin Kook Rhee, MD, PhD

Associate Professor
Division of Pulmonary and Critical Care Medicine
Department of Internal Medicine
Seoul St. Mary's Hospital
The Catholic University of Korea

Chief complaint

▣ Cough

- Combined with intermittent dyspnea

▣ Onset : 3 months ago

Present illness

43 세 남환

15 년 전, Asthma 진단 받은 적 있는 자로,
이에 대해 약제 사용 없이 지내던 중,

내원 3개월 전부터 시작된 cough와 intermittent
dyspnea 있어 본원 내원.

Past history

▣ DM/HTN/Tuberculosis/Hepatitis (-/-/+/-)

- old TB history (2014)
- Allergy: 집먼지진드기, 꽃가루

▣ Operation history: none

▣ Social history

- Smoking: Ex-smoker (2003년 금연, 15 years x 1 pack)
- Alcohol: social

Past history

▣ Medication history

- Symbicort (budesonide, formoterol)
- Ventolin (salbutamol)
- Solondo (prednisolone) 30mg#2
- Singulair (montelukast) 10mg qd

Review of systems

General	Fever / Chilling / Dizziness (-/-/-) Generalized weakness / Fatigue (-/-) Generalized edema / Weight change (-/-) Headache / Poor oral intake (-/-)
HEENT	Headache / Vertigo / Dizziness / tinnitus (-/-/-/-) Vision / Glasses / Discharge (-/-/-) Globus sensation (+)
Respiratory	Cough / Sputum / Rhinorrhea / Dyspnea (+/-/-/+) Sore throat (-) / chest discomfort (-)
Cardiovascular	Chest pain / Palpitation / Cyanosis (-/-/-)
Gastrointestinal	Anorexia / Nausea / Vomiting (-/-/-) Diarrhea / Constipation (-/-) Abdominal pain (-) Dyspepsia (-) Hematemesis / Hematochezia / Melena (-/-/-) Bowel habit change (-)
Genitourinary	Dysuria / Frequency / Nocturia / Hematuria (-/-/-/-) Urgency / Incontinence / Remnant (-/-/-)
Extremities	Grossly free leg pretibial pitting edema (-/-)

Physical examination

Vital Sign	125/67mmHg - 84/min - 20/min - 37.3°C (96%)
Mental Status	Alert
General Appearance	Not so ill-looking appearance
HEENT	Normocephaly / No neck vein engorgement No carotid bruit / No cervical lymphadenopathy Isocoria with phasic pupillary light reflex (++) Not Anemic conjunctivae / Anicteric sclerae Pharyngeal injection / Tonsillar enlargement (-/-) Palpable mass (-) / Alopecia (-) / Oral ulcer (-)
Chest	Regular heart beat without murmur Coarse breathing sound without rale, expiratory wheezing on both lung
Abdomen	Soft and flat / Normoactive bowel sound / Organomegaly (-) Tenderness (-) / Rebound tenderness (-) / knocking tenderness (-)
Extremities	Both leg pretibial pitting edema (-/-)
Skin	Grossly free

Laboratory findings

Complete Blood Count	
WBC count ($10^9/L$)	9210
Hemoglobin (g/dL) / Hematocrit (%)	14.2 / 41.8
Platelet count ($10^9/L$)	297K
WBC Diff. Count	
Seg. Neutrophil (%)	57.8
Lymphocyte (%)	31.6
Monocyte (%)	8.8
Eosinophil (%)	1.3
Basophil (%)	0.5
ANC ($10^9/L$)	5320
Mean Corp Index	
MCV (fL)	91.1
MCH (pg)	30.9
MCHC (%)	34.0

Blood Chemistry	
Glucose (mg/dL)	89
Urea nitrogen (mg/dL)	12.0
Creatinine (mg/dL)	0.9
Total Protein (g/dL) / Albumin (g/dL)	7.1 / 4.5
AST (U/L) / ALT (U/L)	18 / 23
Total bilirubin / direct bilirubin (mg/dL)	0.49 / 0.10
Sodium / Potassium / Chloride (mEq/L)	141 / 4.2 / 109
Calcium / Phosphorus / Magnesium (mg/dL)	9.3 / 3.1 / 2.3
LDH (U/L) / CPK (U/L)	316 / 84
Amylase (U/L)	96
Osmolality (mOsm/kg)	290
ESR (mm/h) / hs-CRP (mg/dl)	24 / 0.1

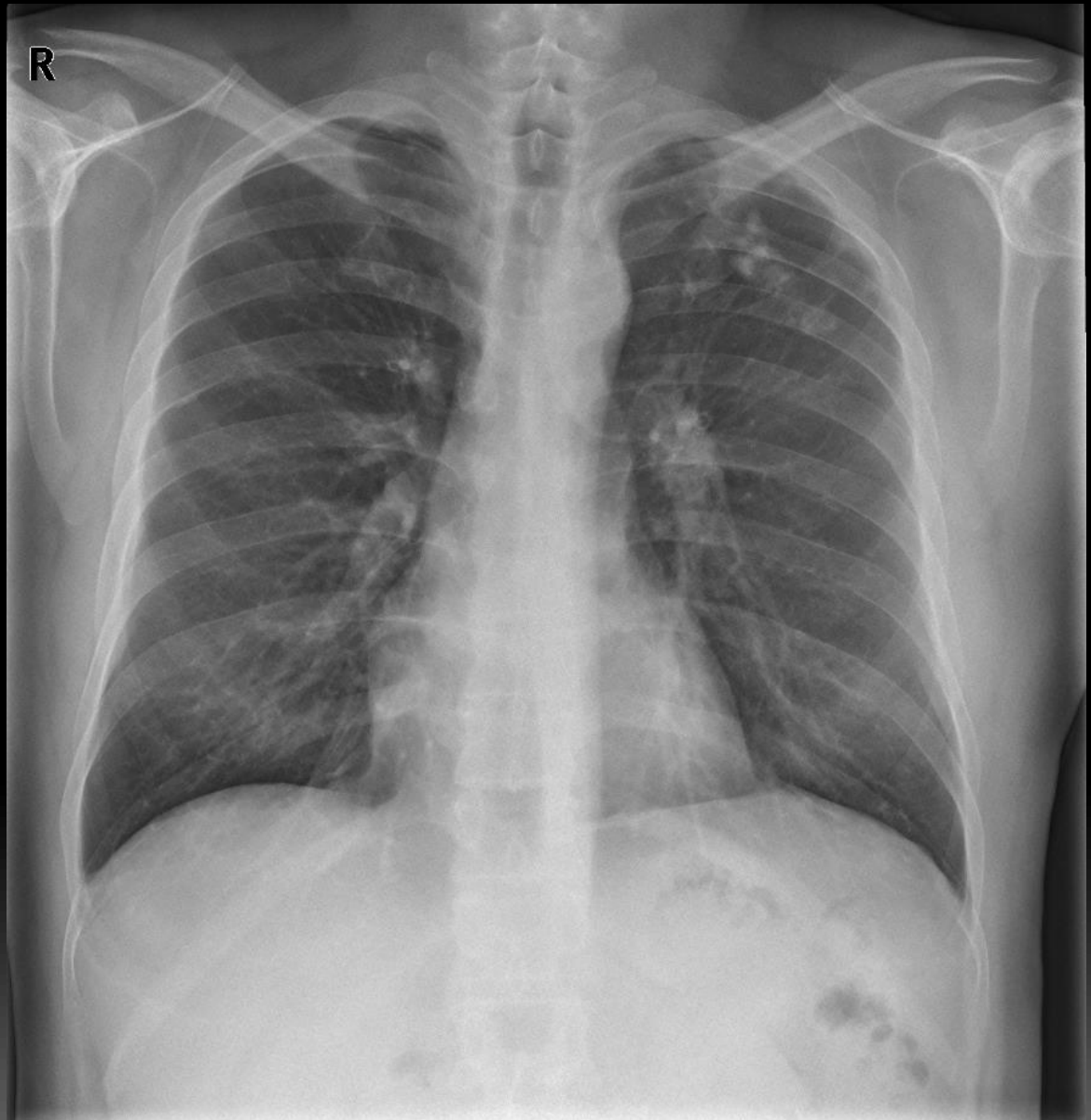
Laboratory findings

Arterial blood	
Lactic acid (mmol/L)	0.5
Blood Gas Panel	
ABGA-pH	7.454
ABGA-PCO2 (mmHg)	38.5
ABGA-PO2 (mmHg)	87.5
ABGA-HCO ₂ (mmol/L)	26.5
ABGA-O2 SAT (%)	96.7

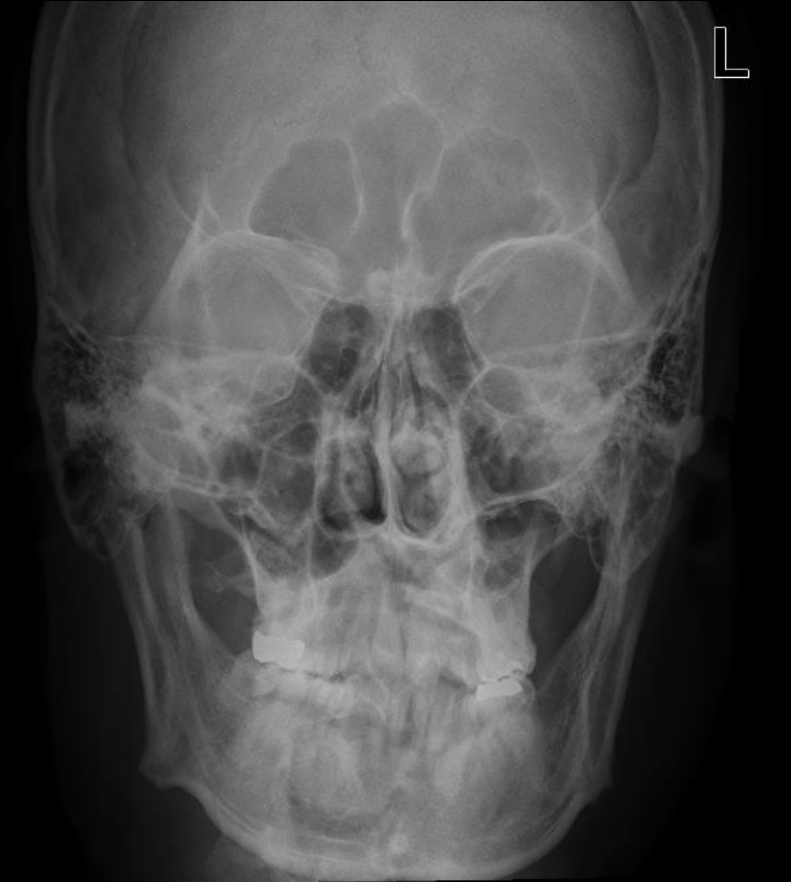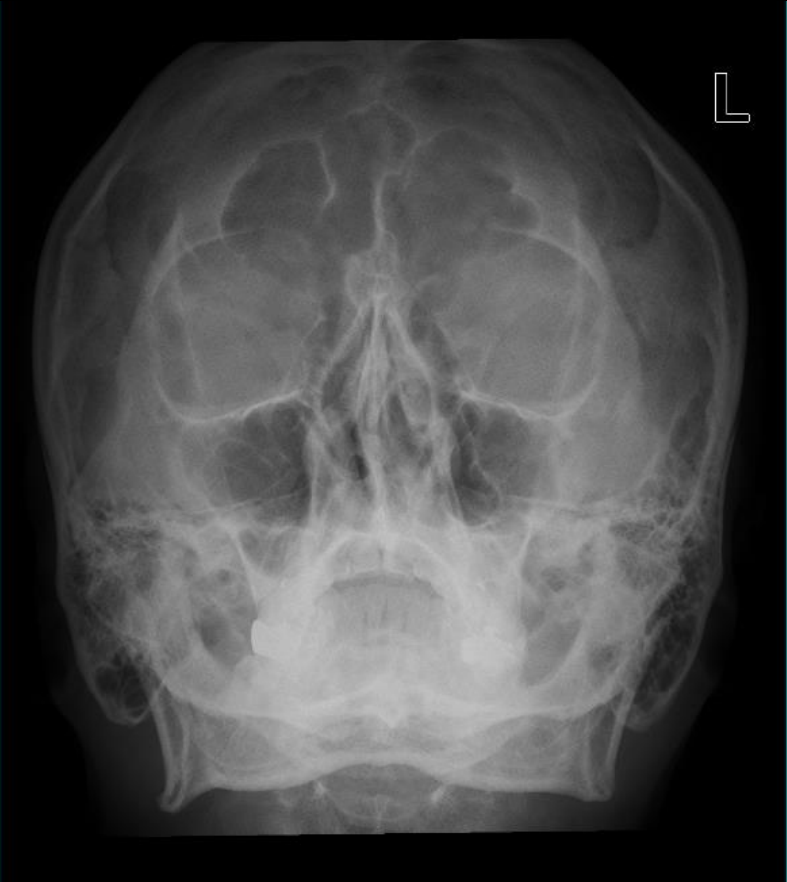Coagulation profile	
Prothrombin time	
PT ()% of normal	100.6
INR	1.00
PT Test (sec)	11.6
Activated PTT	
Activated PTT test (sec)	26.3

Urine analysis	
Routine Urine Analysis	
Glucose	-
Color	LT.Yellow
Leukocyte	-
Bilirubin	-
Ketone	-
Specific gravity	1.023
Occult blood	-
pH	5.5
Protein	-
Urobilinogen	Trace
Nitrate	-
Urine Sediment Examination	
WBC (HPF)	0-1
RBC (HPF)	1-3

Chest PA



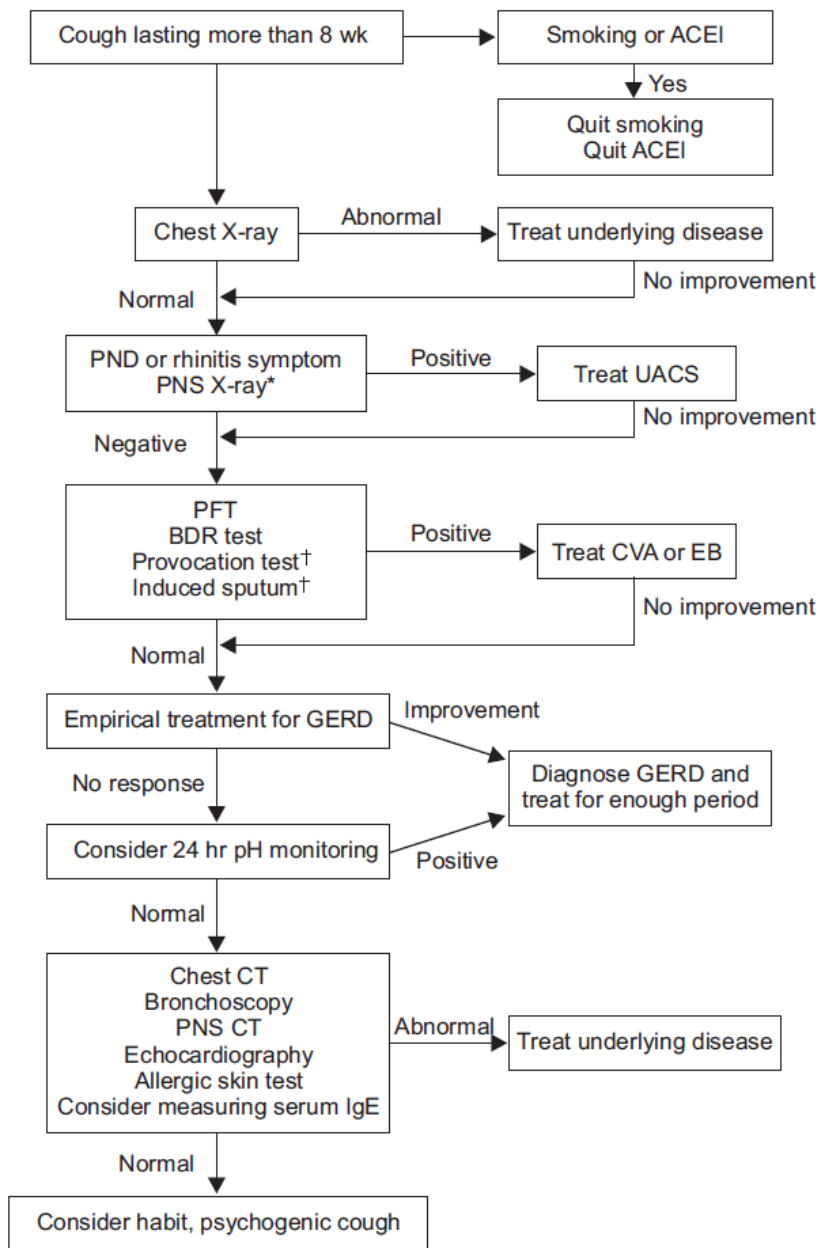
PNS series

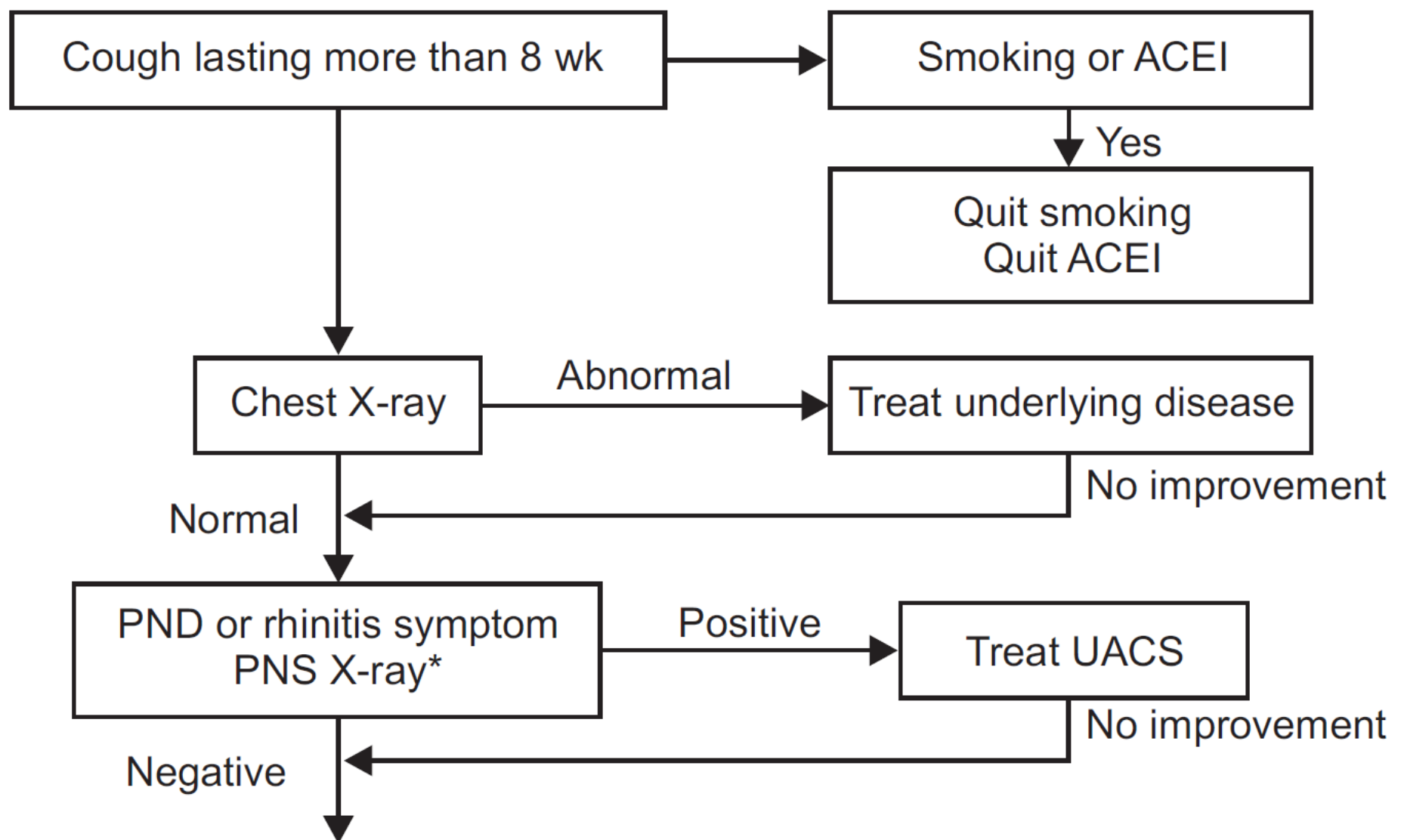


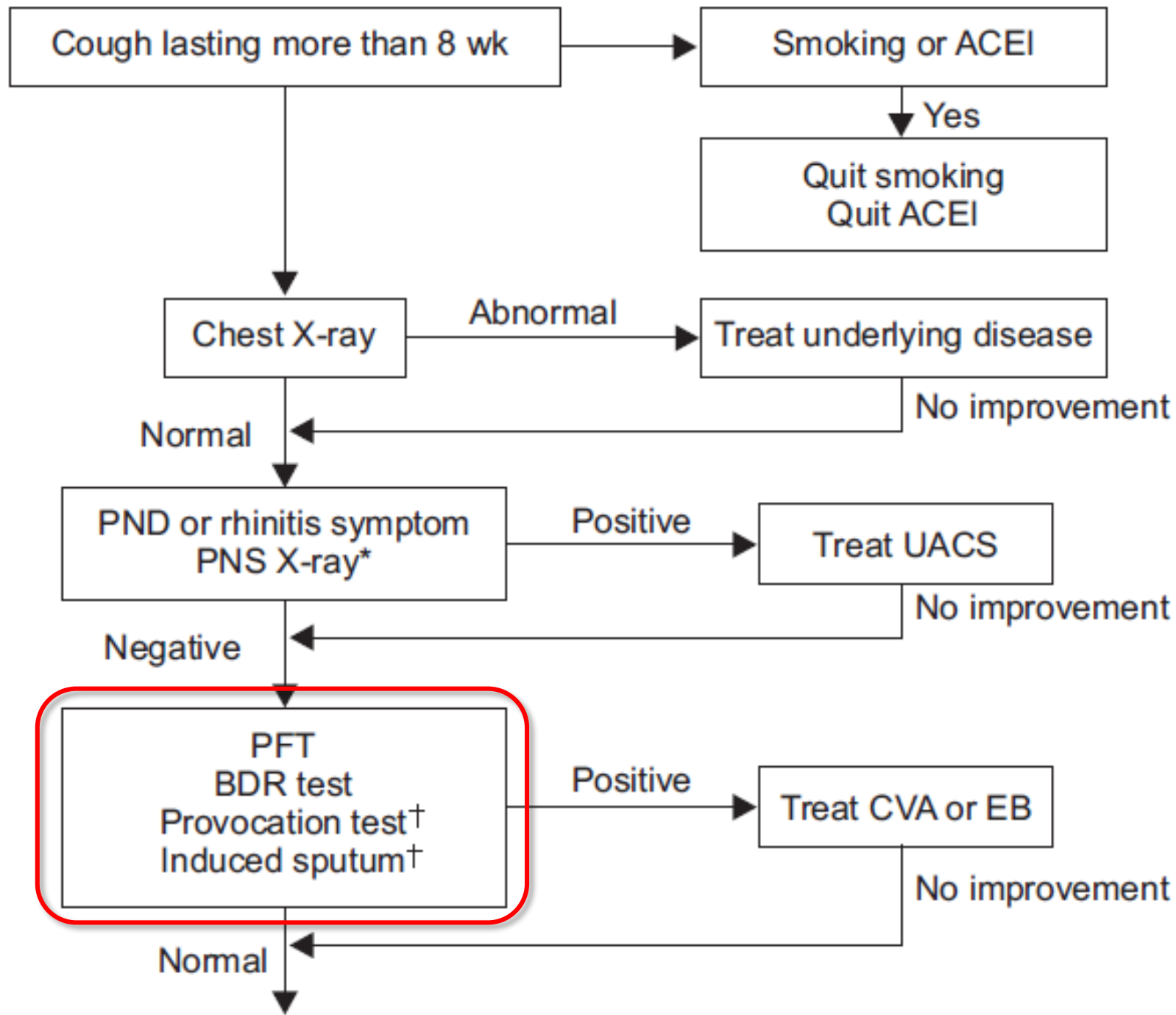


The Korean Cough Guideline: Recommendation and Summary Statement

Chin Kook Rhee, M.D., Ph.D.¹, Ji Ye Jung, M.D.², Sei Won Lee, M.D., Ph.D.³, Joo-Hee Kim, M.D., Ph.D.⁴, So Young Park, M.D.⁵, Kwang Ha Yoo, M.D., Ph.D.⁶, Dong Ah Park, M.P.H., Ph.D.⁷, Hyeon-Kyoung Koo, M.D.⁸, Yee Hyung Kim, M.D., Ph.D.⁹, Ina Jeong, M.D.¹⁰, Je Hyeong Kim, M.D., Ph.D.¹¹, Deog Kyeom Kim, M.D., Ph.D.¹², Sung-Kyoung Kim, M.D.¹³, Yong Hyun Kim, M.D., Ph.D.¹⁴, Jinkyong Park, M.D.¹⁵, Eun Young Choi, M.D., Ph.D.¹⁶, Ki-Suck Jung, M.D., Ph.D.⁴ and Hui Jung Kim, M.D., Ph.D.¹⁷







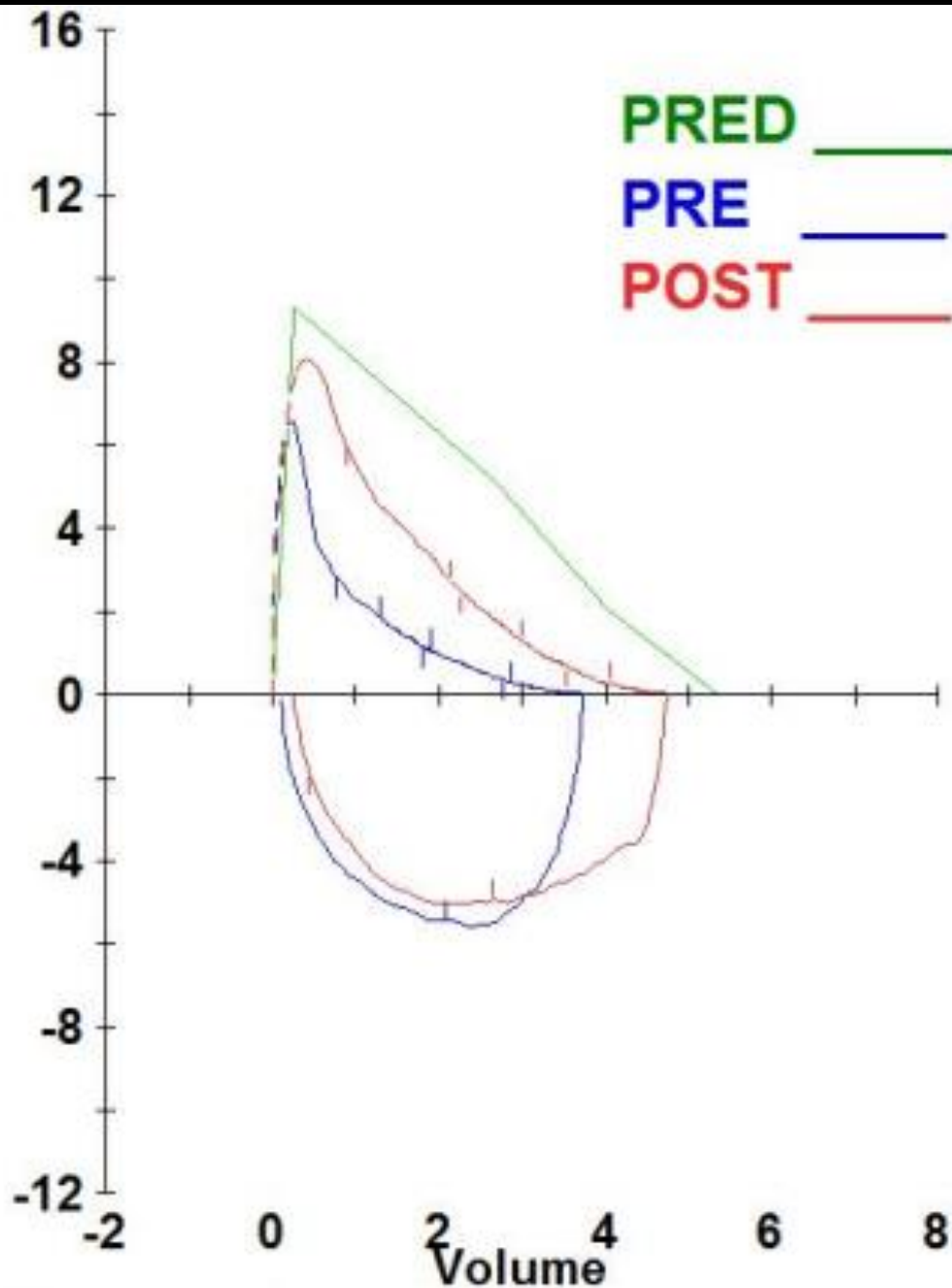
Pulmonary function test (2015/09/24)

Spirometry

		PRED	PRE-RX BEST %PRED		POST-RX BEST %PRED		% CHG
FVC	Liters (BTPS)	5.38	3.74	70	4.76	88	27
FEV1	Liters	4.31	1.94	45	3.05	71	57
FEV1/FVC	%	80	52		64		
FEF25-75%	L/sec	3.86	0.80	21	1.68	43	111
IsoFEF25-75	L/sec	3.86	0.80	21	2.88	74	261
FEF75-85%	L/sec	1.12	0.21	18	0.40	36	93
PEF	L/sec	9.31	6.55	70	8.05	87	23
FET100%	Sec		14.74		13.39		-9
FIVC	Liters	5.10	3.62	71	4.48	88	24
FEV1	Liters	4.31	1.94	45	3.05	71	57
FIV1	Liters				4.15		
FEF/FIF50		<1.00	0.18		0.46		153
Vol Extrap	Liters		-0.03		-0.02		
FVL ECode			110000		100000		

Spirometry

- FVC
- FEV1
- FEV1/FVC
- FEF25-75
- IsoFEF25
- FEF75-85
- PEF
- FET100%
- FIVC
- FEV1
- FIV1
- FEF/FIF50
- Vol Extra
- FVL ECoc



% CHG

27

57

111

261

93

23

-9

24

57

153

Bronchochallenge Report

Protocol: aridol

PD15 FEV1: 14.2mg

	Ref	Pre	Level 1	Level 2	Level 3	Level 4	Level 5	Level 6	Level 7	Level 8	Level 9	Post
		Meas	Meas	Meas	Meas	Meas	Meas	Meas	Meas	Meas	Meas	Meas
Dose			0	5	15							
FVC Liters	5.38	4.64	4.69	4.32	3.93							
% Ref		86	87	80	73							
% Chg			1	-7	-15							
Dose			0	5	15							
FEV1 Liters	4.31	2.70	2.60	2.41	2.08							
% Ref		63	60	56	48							
% Chg			-4	-11	-23							
Dose			0	5	15							
FEF25-75%	3.86	1.30	1.17	1.15	0.94							
% Ref		34	30	30	24							
% Chg			-10	-11	-28							
Dose			0	5	15							
PEF L/sec	9.31	7.64	6.59	6.31	7.18							
% Ref		82	71	68	77							
% Chg			-14	-17	-6							

Bronchochallenge Report

Proto

PD15 FEV1: 14.2mg

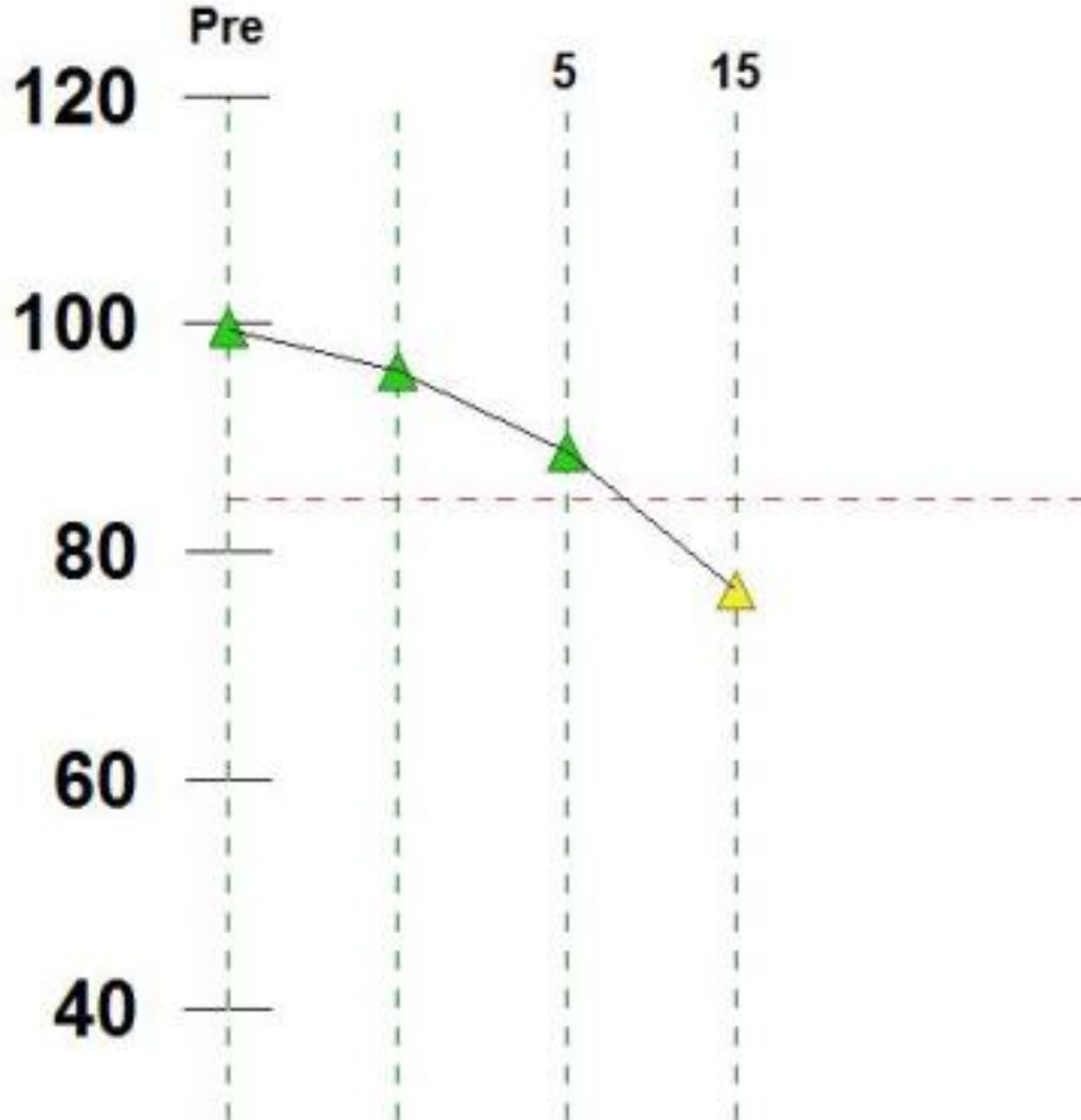
Dose
FVC Lit
% Ref
% Chg

Dose
FEV1 Lit
% Ref
% Chg

Dose
FEF25-75
% Ref
% Chg

Dose
PEF L
% Ref
% Chg

Level 8 Meas Level 9 Meas Post Meas



Cue lists

- ❑ From chief complaint, present illness, past history
 - Dyspnea, Chronic cough (>8weeks), Globus sensation
 - Previously diagnosed asthma
 - Ex smoker
 - Allergic history to 집먼지진드기, 꽃가루
- ❑ From Review of systems, physical examinations
 - Expiratory wheezing
- ❑ From radiologic imaging
 - LUL multiple calcified nodule
- ❑ From PFT
 - FEV₁/FVC 52%, FEV₁ 1.94L 45%, Bronchodilator response 57%,
 - Spirometry ; obstructive pattern and smooth concave curve at expiration
 - PD 15 at mannitol ; 14.2

Problem lists #1

Cue lists

- Dyspnea, duration of cough > 8weeks
- Expiratory wheezing and dyspnea
- No improvement on medication (ICS/LABA and steroid)
- PFT ; provocation positive results, bronchodilator response(+) PD₁₅ – 14.2

Impression

- #1. R/O Uncontrolled bronchial asthma
 - DDx. R/O Upper airway cough syndrome, R/O GERD, R/O Eosinophilic bronchitis etc.

Problem lists #1

Diagnostic plan

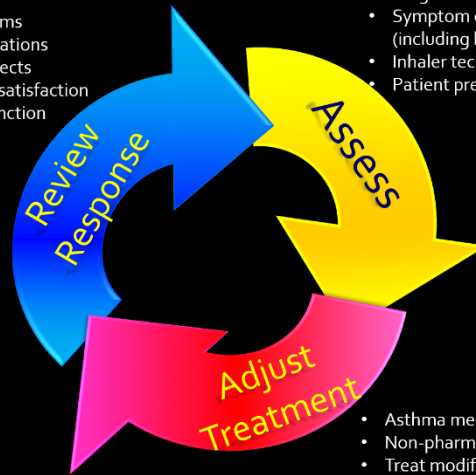
- 24 hr pH monitoring
- Sputum study
- Chest CT
- Laryngoscopy or Bronchoscopy

Therapeutic plan

- Median dose ICS/LABA for asthma (GINA guideline 2016)
- Anti-histamine or leukotriene receptor antagonist for R/O UACS

GINA 2015

- Symptoms
- Exacerbations
- Side-effects
- Patient satisfaction
- Lung function



- Diagnosis
- Symptom control & risk factors (including lung function)
- Inhaler technique & adherence
- Patient preference

- Asthma medications
- Non-pharmacologic strategies
- Treat modifiable risk factors

The control-based asthma management cycle

	Step 1	Step 2	Step 3	Step 4	Step 5
Preferred controller		Low dose ICS	Low dose ICSLABA	High dose ICSLABA	Refer for add on Tx (e.g. anti-IgE)
Other controller	Consider low dose ICS	LTRA Low dose theophylline	Medium/high dose ICS Low dose ICS+LTRA (or + theoph)	Add tiotropium High dose ICS+LTRA (or + theoph)	Add tiotropium Add low dose OCS
Reliever	prn SABA		prn SABA or low dose ICS/formoterol		

Progress note: 1m FU

S : "숨 들어 마실 때 힘들어요." "흡입기 써도 증상 계속 숨이 차요 "

O : ACT 3-1-1-5-2

Decreased breathing sound on both lung

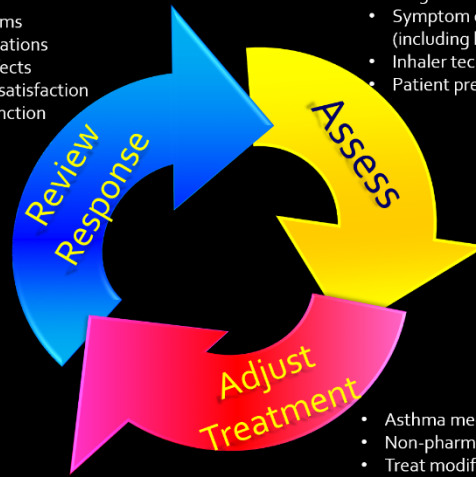
A : #1. R/O Uncontrolled bronchial asthma
#2. Allergic rhinitis
#3. Old tuberculosis scar

P : Asthma control step up : median dose ICS/LABA -> high dose ICS/LABA
(Budesonide/Formoterol fumarate 320mcg/9mcg 1 puff bid)

Inhaler education 의 적절성 평가

GINA 2015

- Symptoms
- Exacerbations
- Side-effects
- Patient satisfaction
- Lung function



- Diagnosis
- Symptom control & risk factors (including lung function)
- Inhaler technique & adherence
- Patient preference

- Asthma medications
- Non-pharmacologic strategies
- Treat modifiable risk factors

The control-based asthma management cycle

	Step 1	Step 2	Step 3	Step 4	Step 5
Preferred controller		Low dose ICS	Low dose ICSLABA	High dose ICSLABA	Refer for add on Tx (e.g. anti-IgE)
Other controller	Consider low dose ICS	LTRA Low dose theophylline	Medium/high dose ICS Low dose ICS+LTRA (or + theoph)	Add tiotropium High dose ICS+LTRA (or + theoph)	Add tiotropium Add low dose OCS
Reliever	prn SABA		prn SABA or low dose ICS/formoterol		

Progress note: 2m follow up

S : "목에 이물감이 계속 있고, 숨도 참니다. "

O : ACT 3-1-1-5-2 -> 2-1-1-1-1
Globus symptom, GERD symptom (+/+)

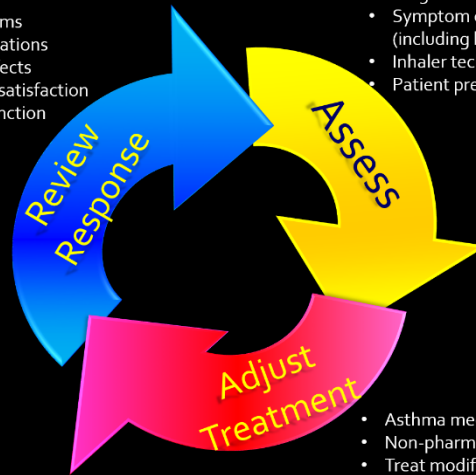
A : #1. R/O Uncontrolled bronchial asthma
#2. Allergic rhinitis
#3. Old tuberculosis scar
#4. R/O GERD

P : LAMA add on

R/O GERD 에 대해 proton pump inhibitor 추가

GINA 2015

- Symptoms
- Exacerbations
- Side-effects
- Patient satisfaction
- Lung function



- Diagnosis
- Symptom control & risk factors (including lung function)
- Inhaler technique & adherence
- Patient preference

- Asthma medications
- Non-pharmacologic strategies
- Treat modifiable risk factors

The control-based asthma management cycle

	Step 1	Step 2	Step 3	Step 4	Step 5
Preferred controller		Low dose ICS	Low dose ICSLABA	High dose ICSLABA	Refer for add on Tx (e.g. anti-IgE)
Other controller	Consider low dose ICS	LTRA Low dose theophylline	Medium/high dose ICS Low dose ICS+LTRA (or + theoph)	Add tiotropium High dose ICS+LTRA (or + theoph)	Add tiotropium Add low dose OCS
Reliever	prn SABA		prn SABA or low dose ICS/formoterol		

Progress note: 3m FU

S : "목에 이물감이 계속 있어요. 숨 들어 마실 때 증상이 느껴져요"

PFT 호전

O : ACT 3-1-1-5-2 -> 2-1-1-1-1 -> 2-1-1-1-1

Globus symptom(+), dyspnea on inspiration(+)

A : #1. R/O Uncontrolled bronchial asthma

#2. Allergic rhinitis

#3. Old tuberculosis scar

#4. R/O GERD

P : Step up consider (Anti IgE 고려)

Pulmonary function test

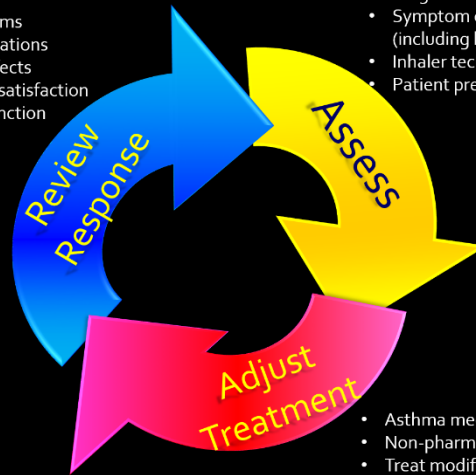
(2015/12/18)

Spirometry		(BTPS)	PRED	PRE-RX		POST-RX		% CHG
				BEST	%PRED	BEST	%PRED	
FVC	Liters		5.38	5.18	96	5.10	95	-1
FEV1	Liters		4.32	3.29	76	3.56	82	8
FEV1/FVC	%		80	64		70		
FEF25-75%	L/sec		3.86	1.71	44	2.50	64	46

Spirometry		(BTPS)	PRED	PRE-RX		POST-RX		% CHG
				BEST	%PRED	BEST	%PRED	
FVC	Liters		5.38	3.74	70	4.76	88	27
FEV1	Liters		4.31	1.94	45	3.05	71	57
FEV1/FVC	%		80	52		64		
FEF25-75%	L/sec		3.86	0.80	21	1.68	43	111
IsoFEF25-75	L/sec		3.86	0.80	21	2.88	74	261
FEF75-85%	L/sec		1.12	0.21	18	0.40	36	93
PEF	L/sec		9.31	6.55	70	8.05	87	23
FET100%	Sec			14.74		13.39		-9
FIVC	Liters		5.10	3.62	71	4.48	88	24

GINA 2015

- Symptoms
- Exacerbations
- Side-effects
- Patient satisfaction
- Lung function



- Diagnosis
- Symptom control & risk factors (including lung function)
- Inhaler technique & adherence
- Patient preference

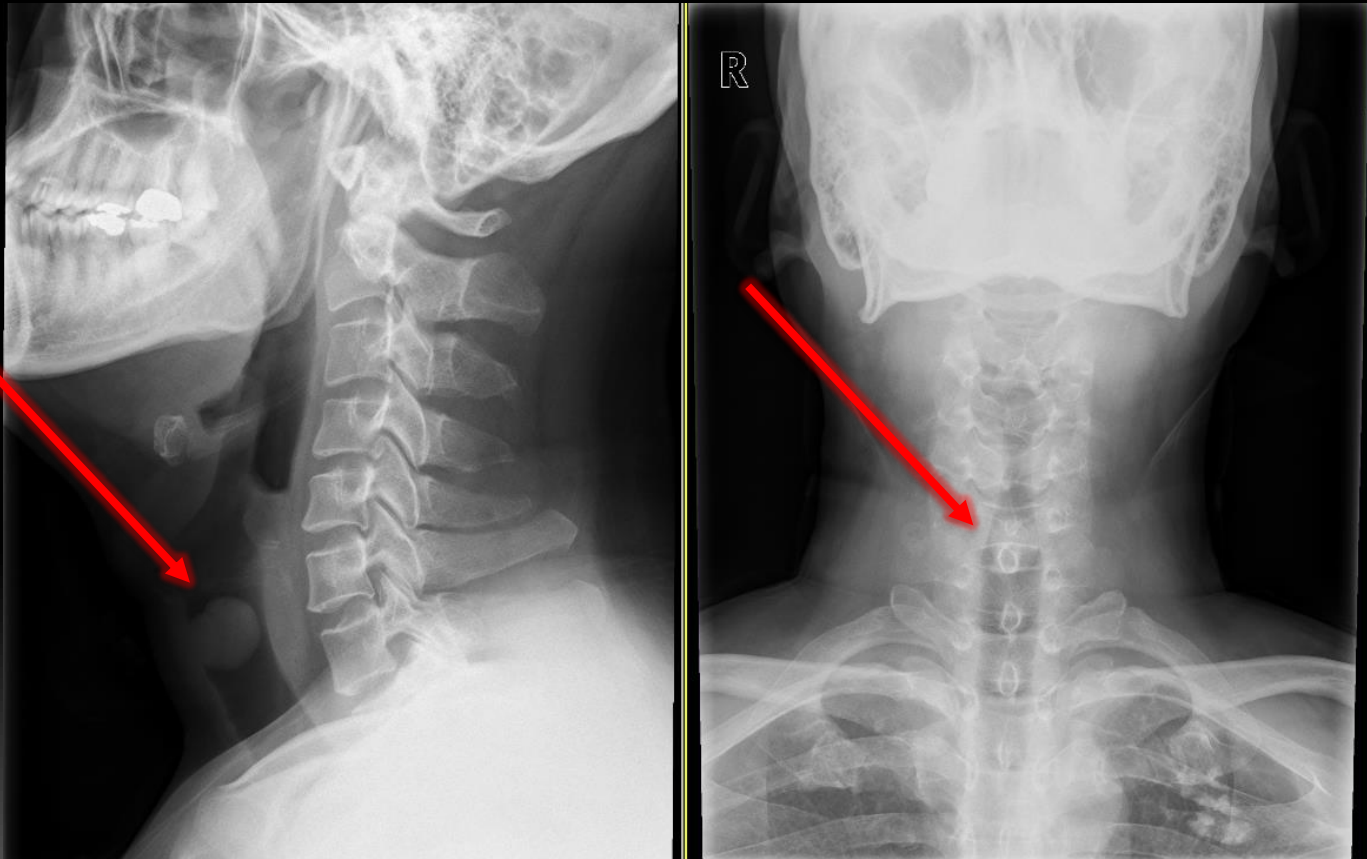
- Asthma medications
- Non-pharmacologic strategies
- Treat modifiable risk factors

The control-based asthma management cycle

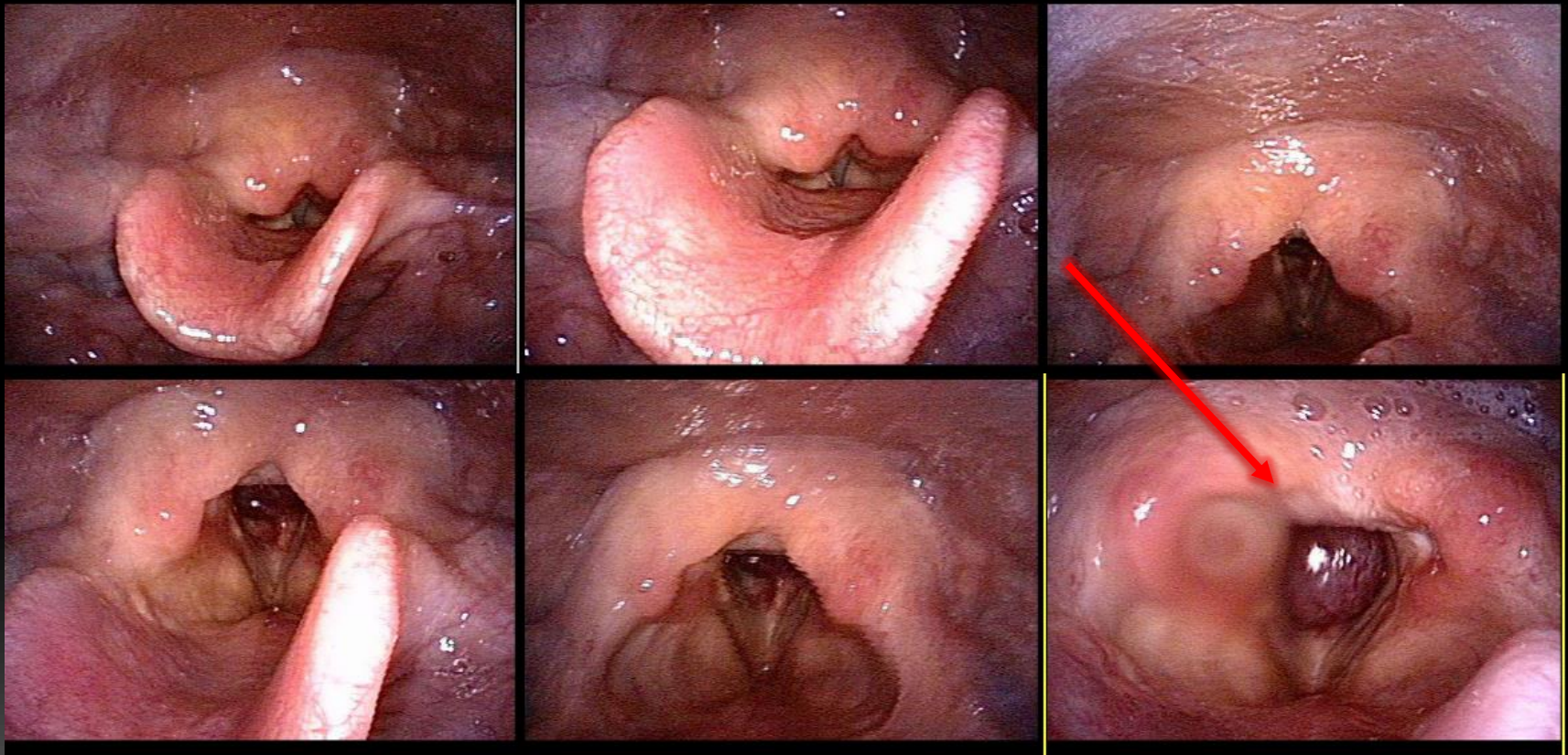
	Step 1	Step 2	Step 3	Step 4	Step 5
Preferred controller		Low dose ICS	Low dose ICSLABA	High dose ICSLABA	Refer for add on Tx (e.g. anti-IgE)
Other controller	Consider low dose ICS	LTRA Low dose theophylline	Medium/high dose ICS Low dose ICS+LTRA (or + theoph)	Add tiotropium High dose ICS+LTRA (or + theoph)	Add tiotropium Add low dose OCS
Reliever	prn SABA		prn SABA or low dose ICS/formoterol		

- Globus sensation
- Excellent turbuhaler technique
- Good compliance
- Good PFT response to ICSLABA
- Poor control in spite of improved PFT
- Dyspnea on inspiration

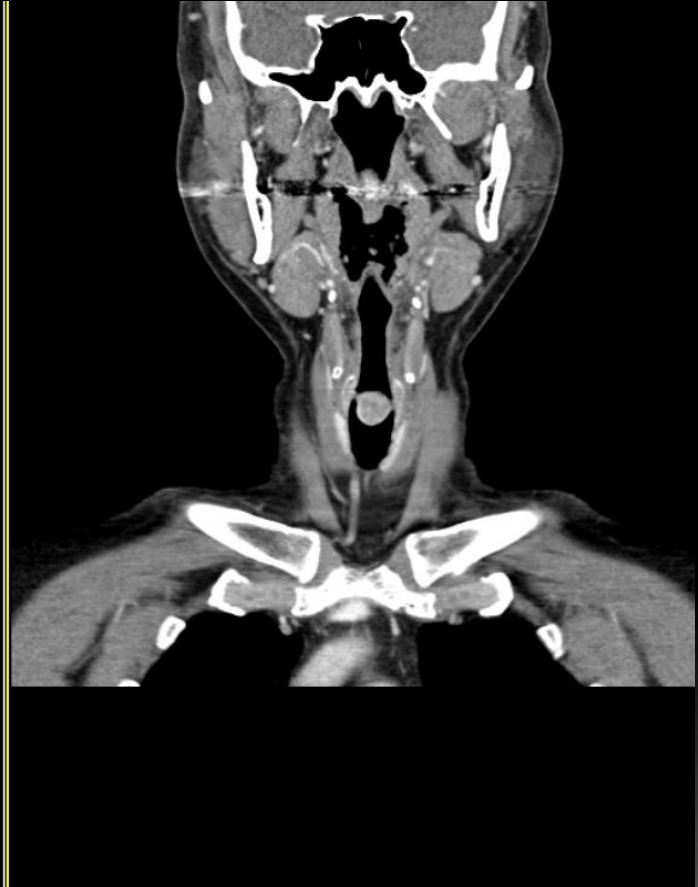
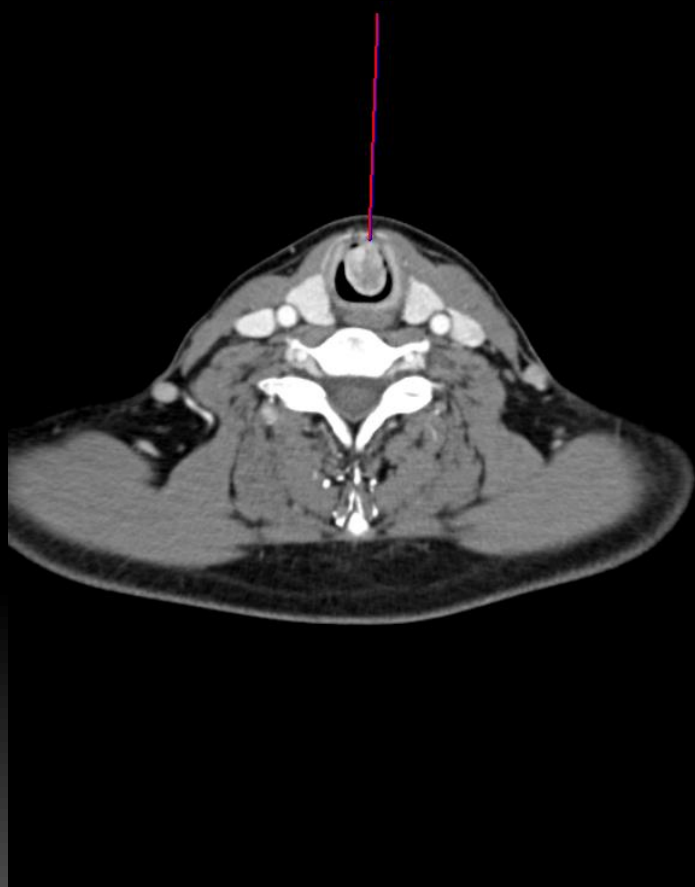Neck AP and lateral (2015/12/21)



Laryngoscopy (2015/12/21)

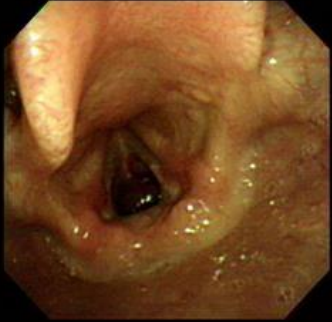

Neck CT (2015/12/21)



Bronchoscopy (2015/12/23)

LEE, G. S



17793916
M 43

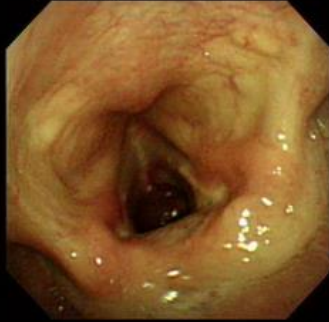12/23/2015
14:28:13

SCV: 81

Gr:N Et:A3

111
MSH

LEE, G. S



17793916
M 43

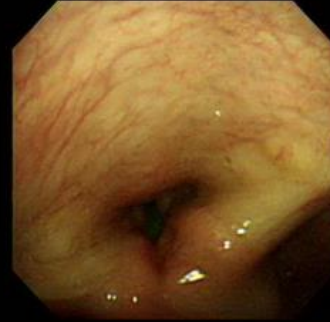12/23/2015
14:28:21

SCV: 81

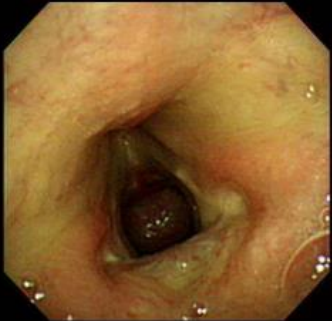
Gr:N Et:A3

11
MSH

LEE, G. S



LEE, G. S



17793916
M 43

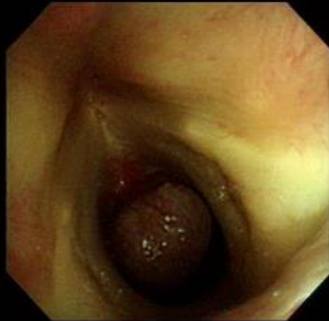
12/23/2015
14:29:28

SCV: 81

Gr:N Et:A3

11
MSH

LEE, G. S



17793916
M 43

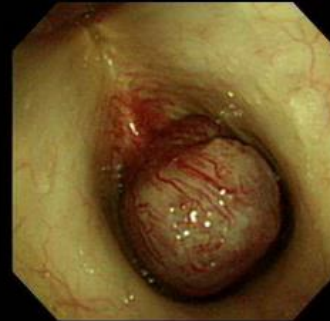
12/23/2015
14:30:10

SCV: 81

Gr:N Et:A3

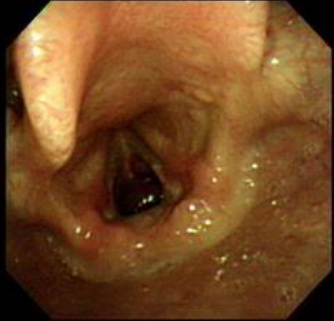111
MSH

LEE, G. S

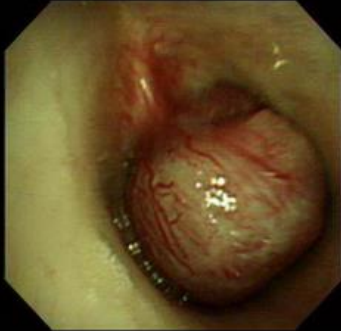

Bronchoscopy (2015/12/23)

LEE, G. S



LEE, G. S



17793916
M 43

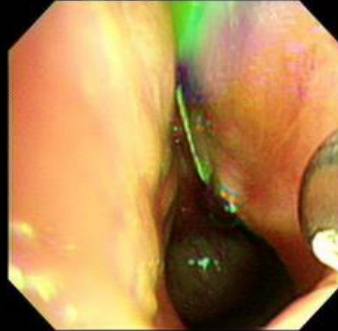
12/23/2015
14:45:37

SCV: 81

G:N E:A3

111
MSH

LEE, G. S



17793916
M 43

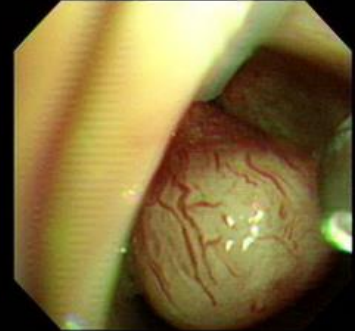
12/23/2015
14:45:38

SCV: 81

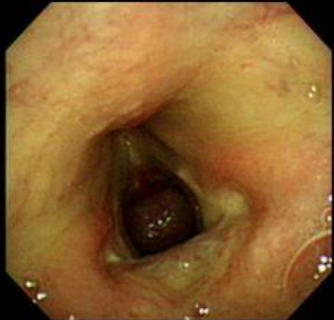
G:N E:A3

11
MSH

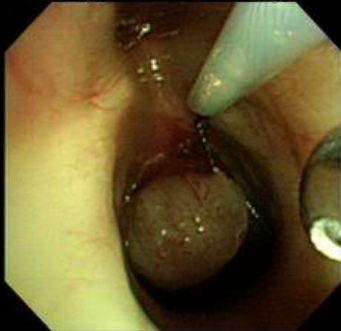LEE, G. S



LEE, G. S



LEE, G. S



17793916
M 43

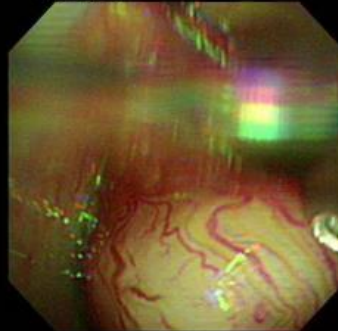
12/23/2015
14:45:46

SCV: 81

G:N E:A3

111
MSH

LEE, G. S



17793916
M 43

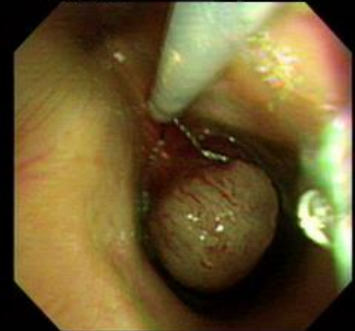
12/23/2015
14:46:24

SCV: 81

G:N E:A3

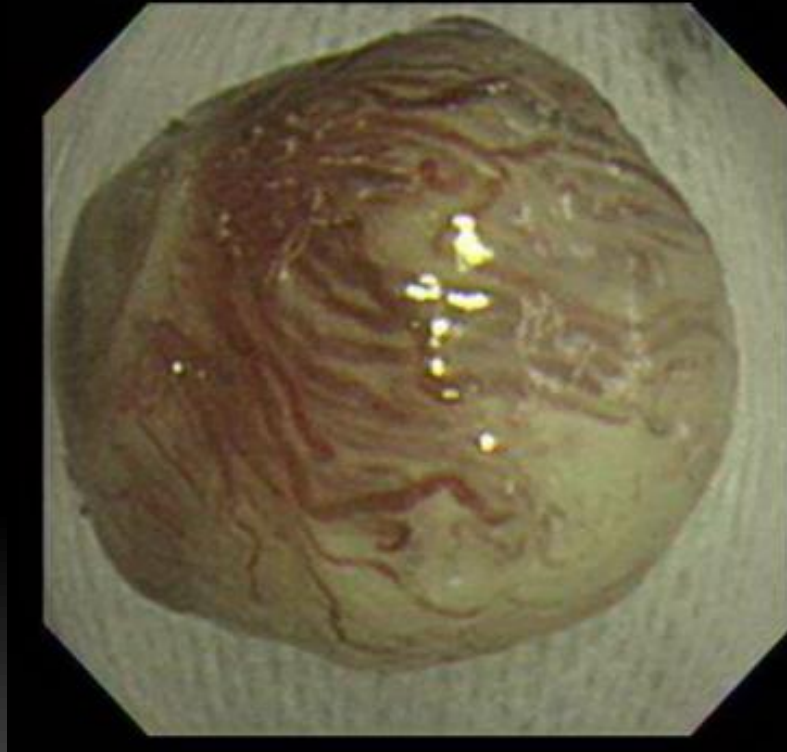11
MSH

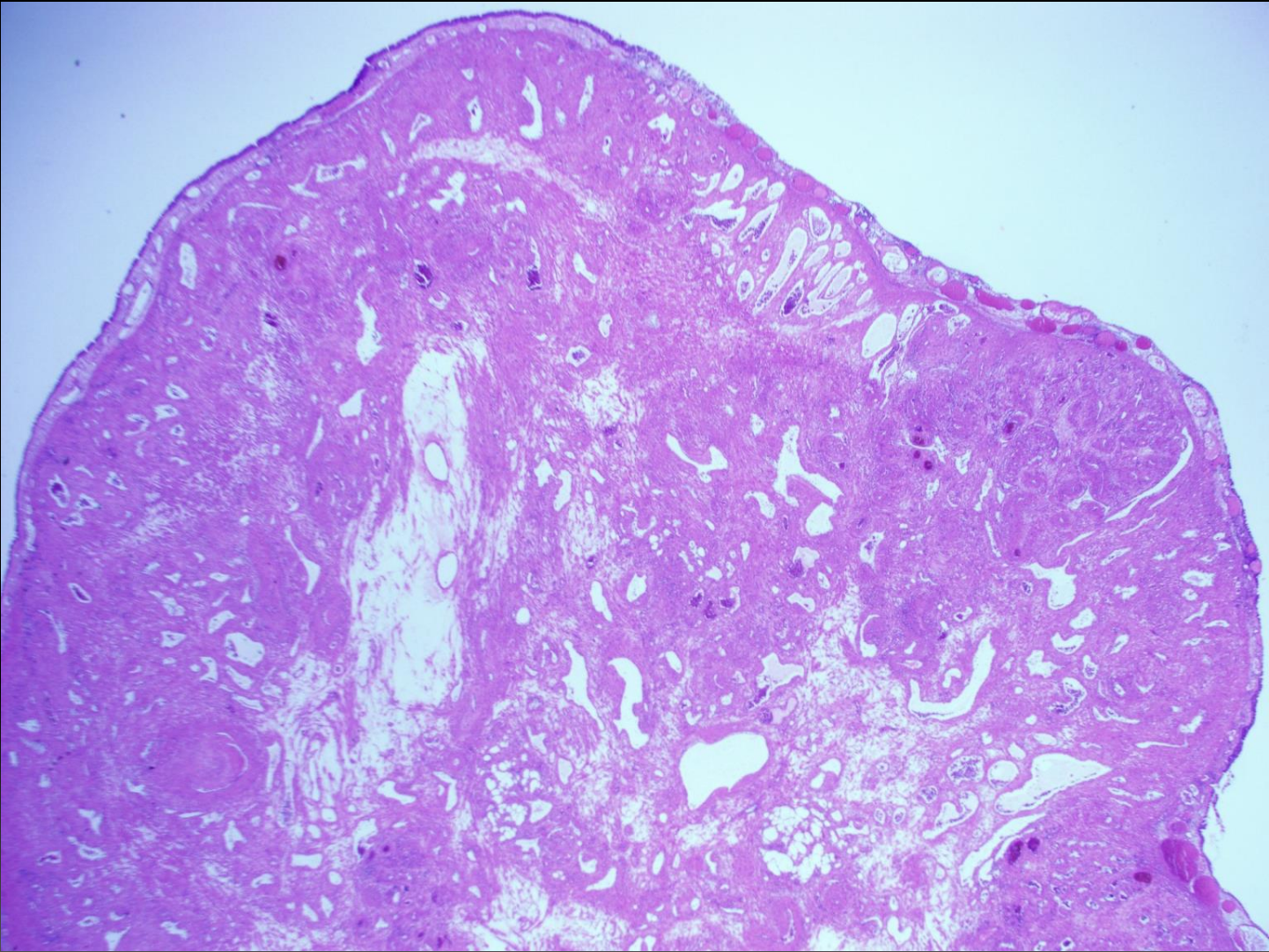
LEE, G. S

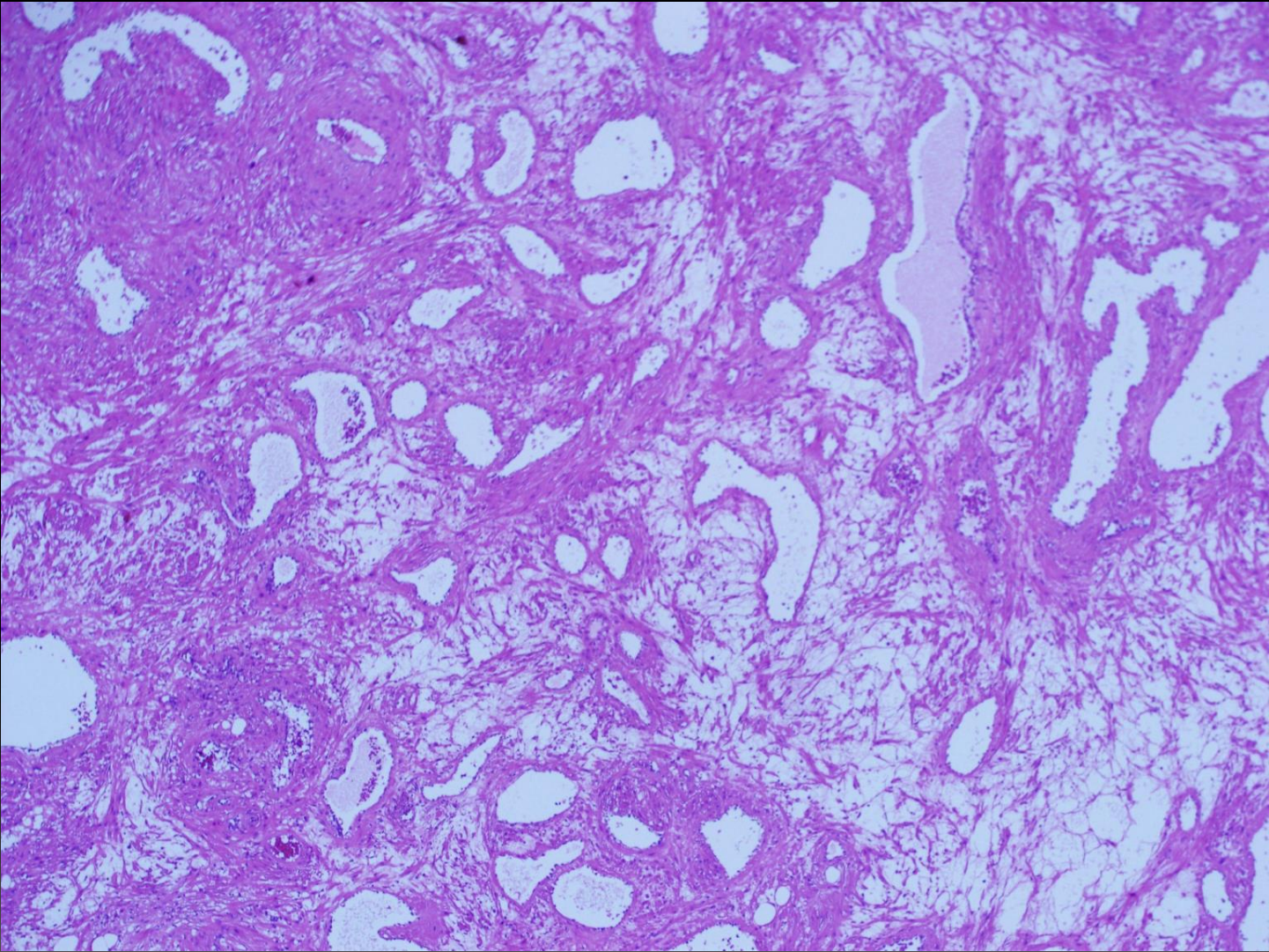


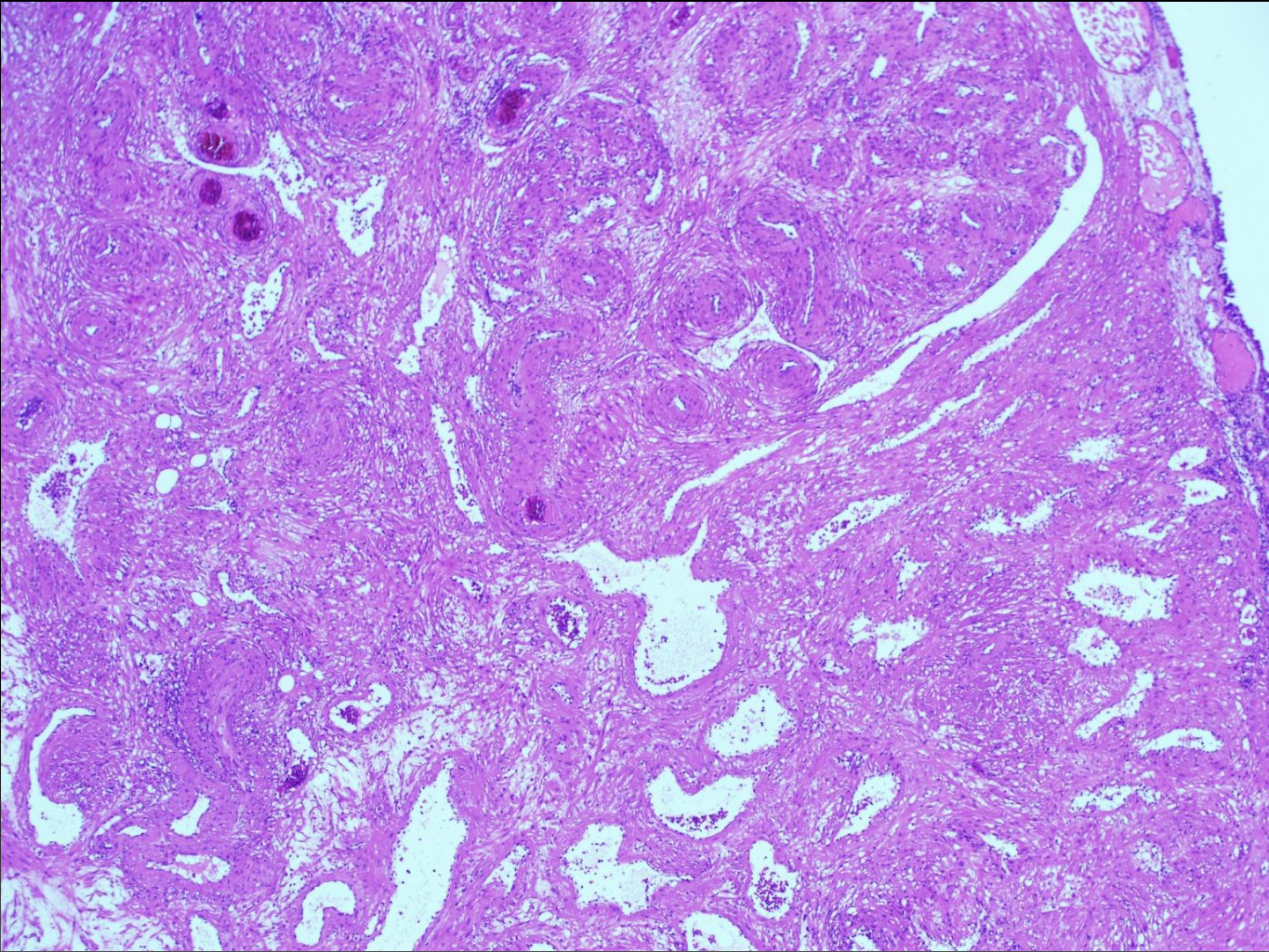
Pathophysiology

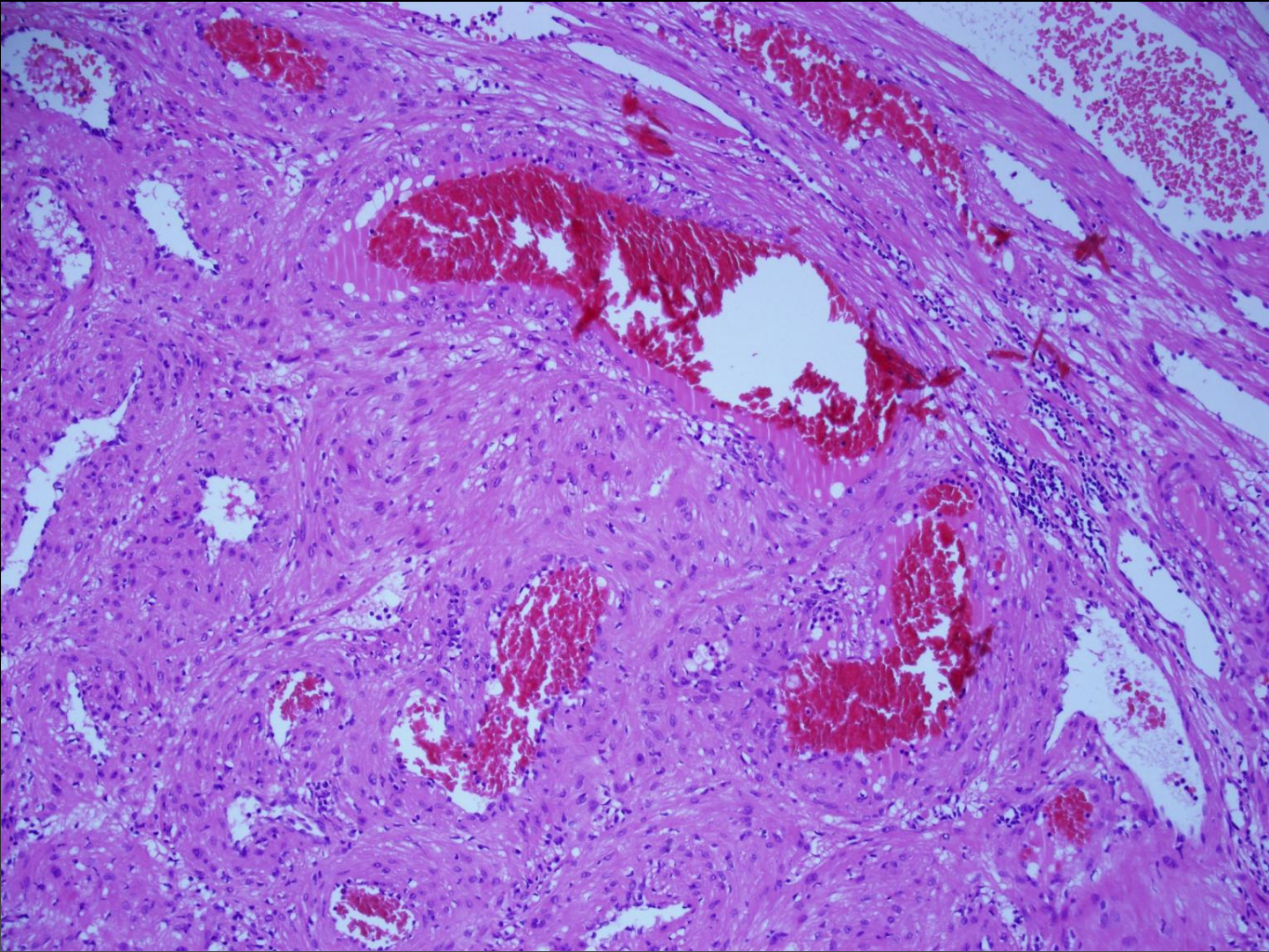
Gross findings

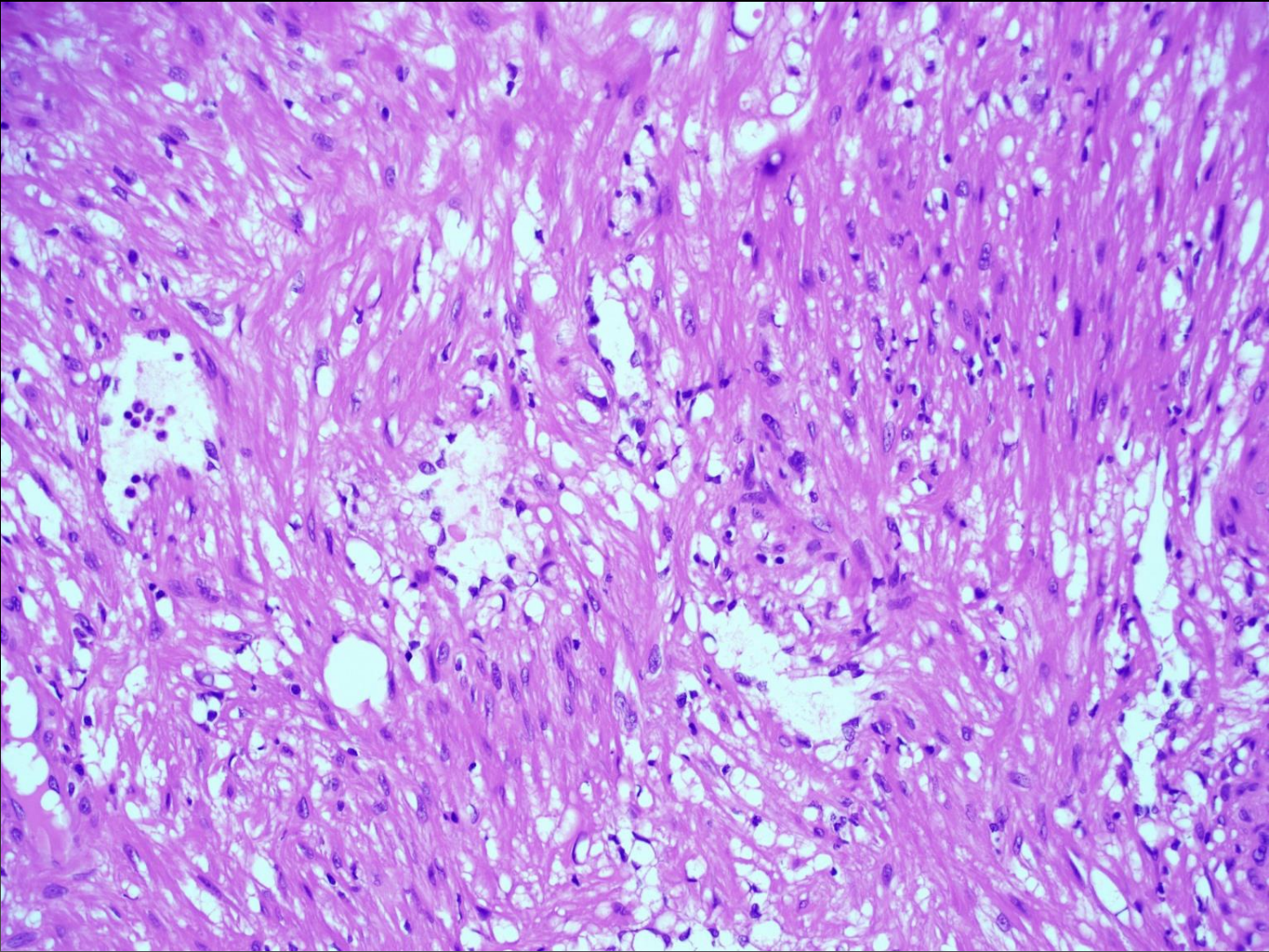


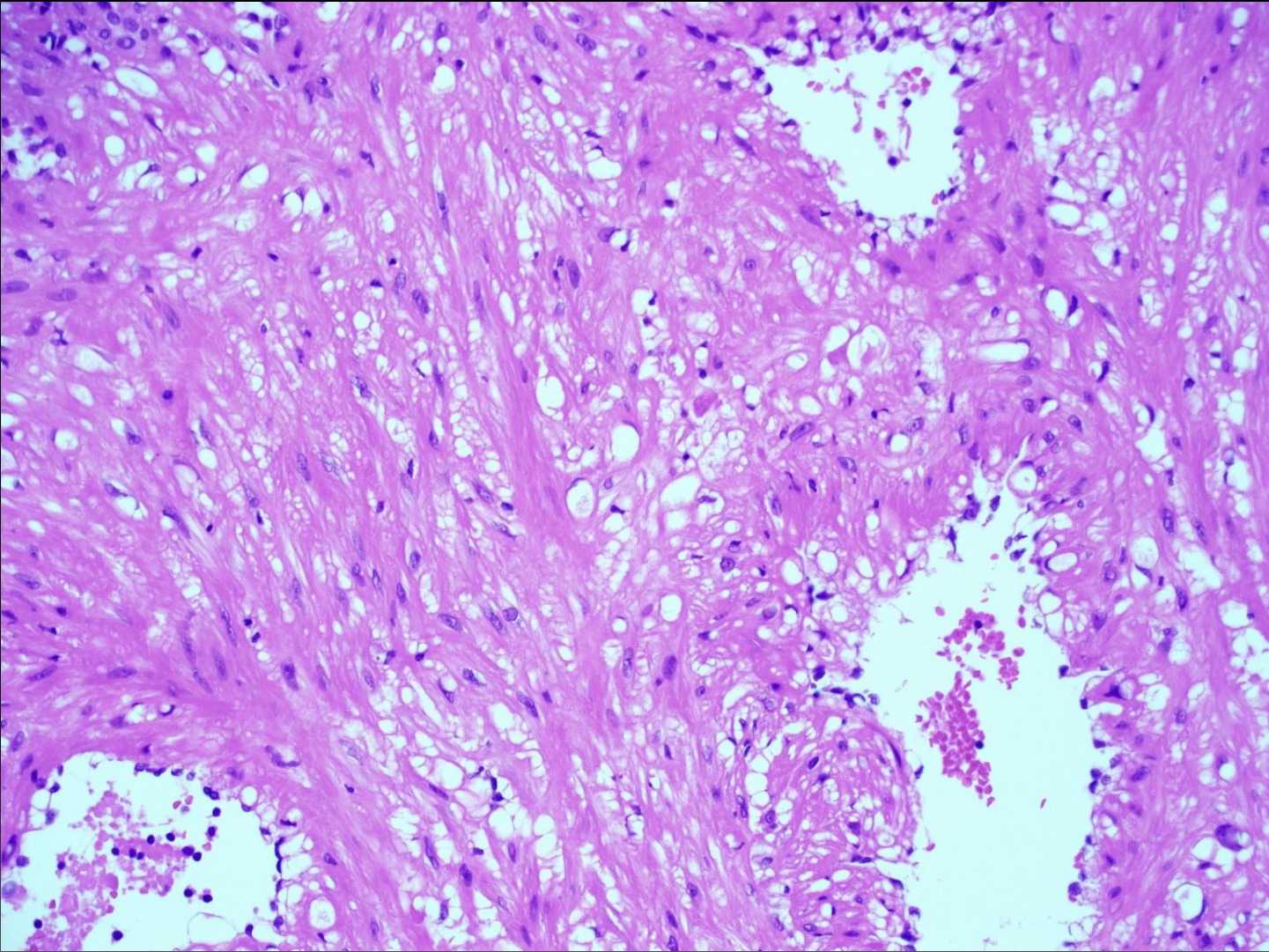












Pathophysiology

[Gross findings]

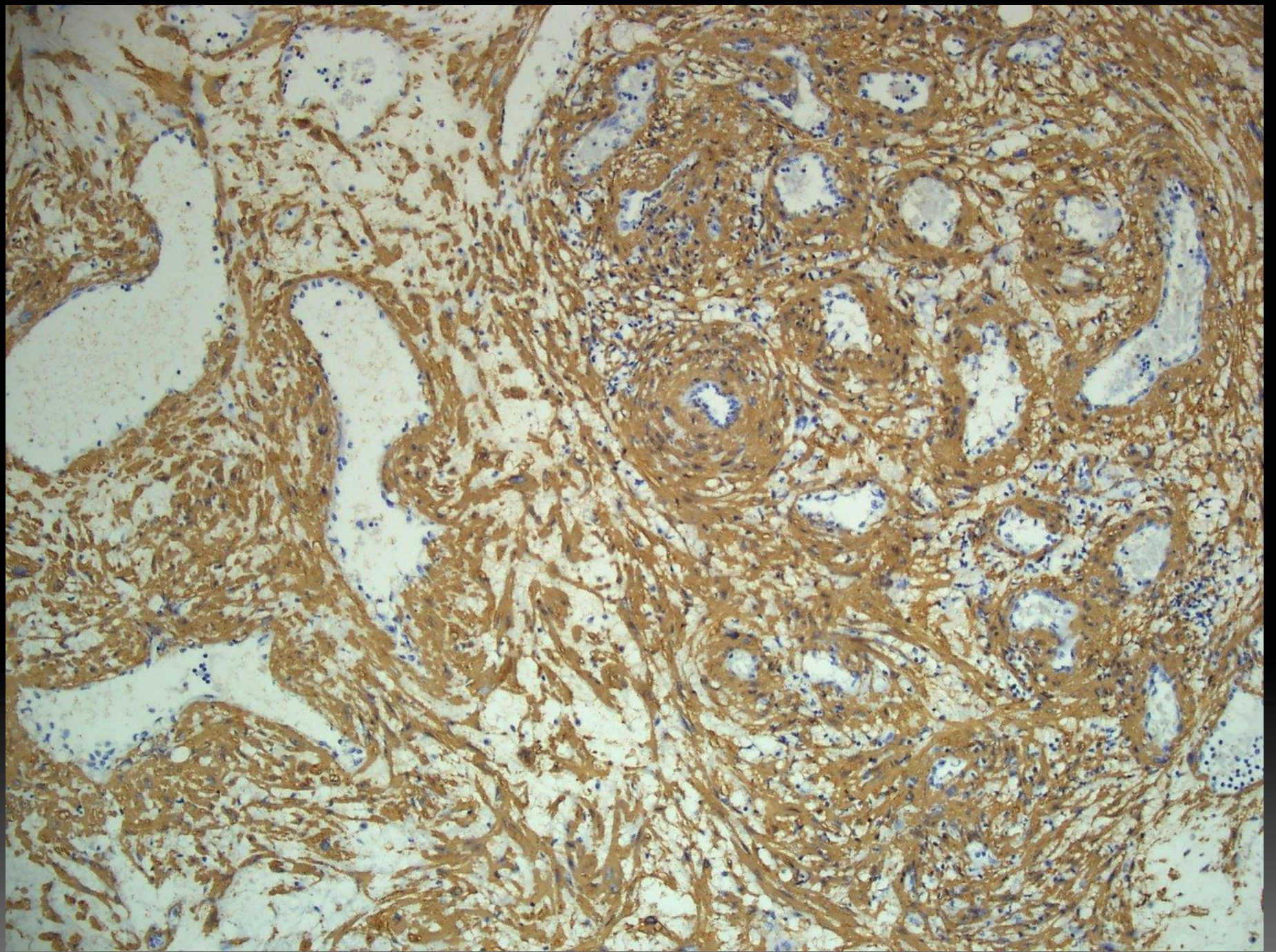
An irregularly shaped pale brown tissue fragment, measuring 1.6 x 1.4 x 1.0 cm, is totally embedded

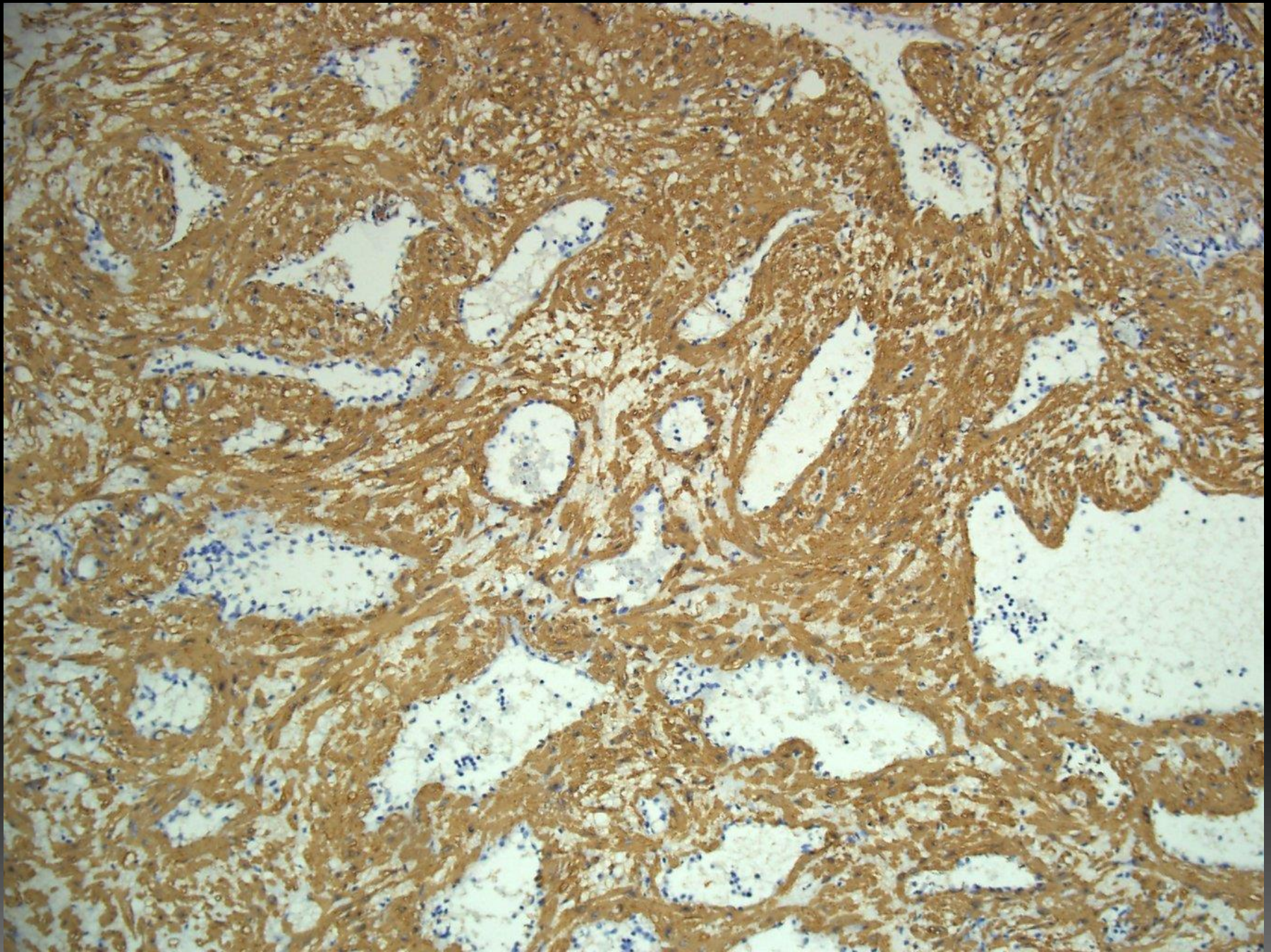
[DIAGNOSIS]

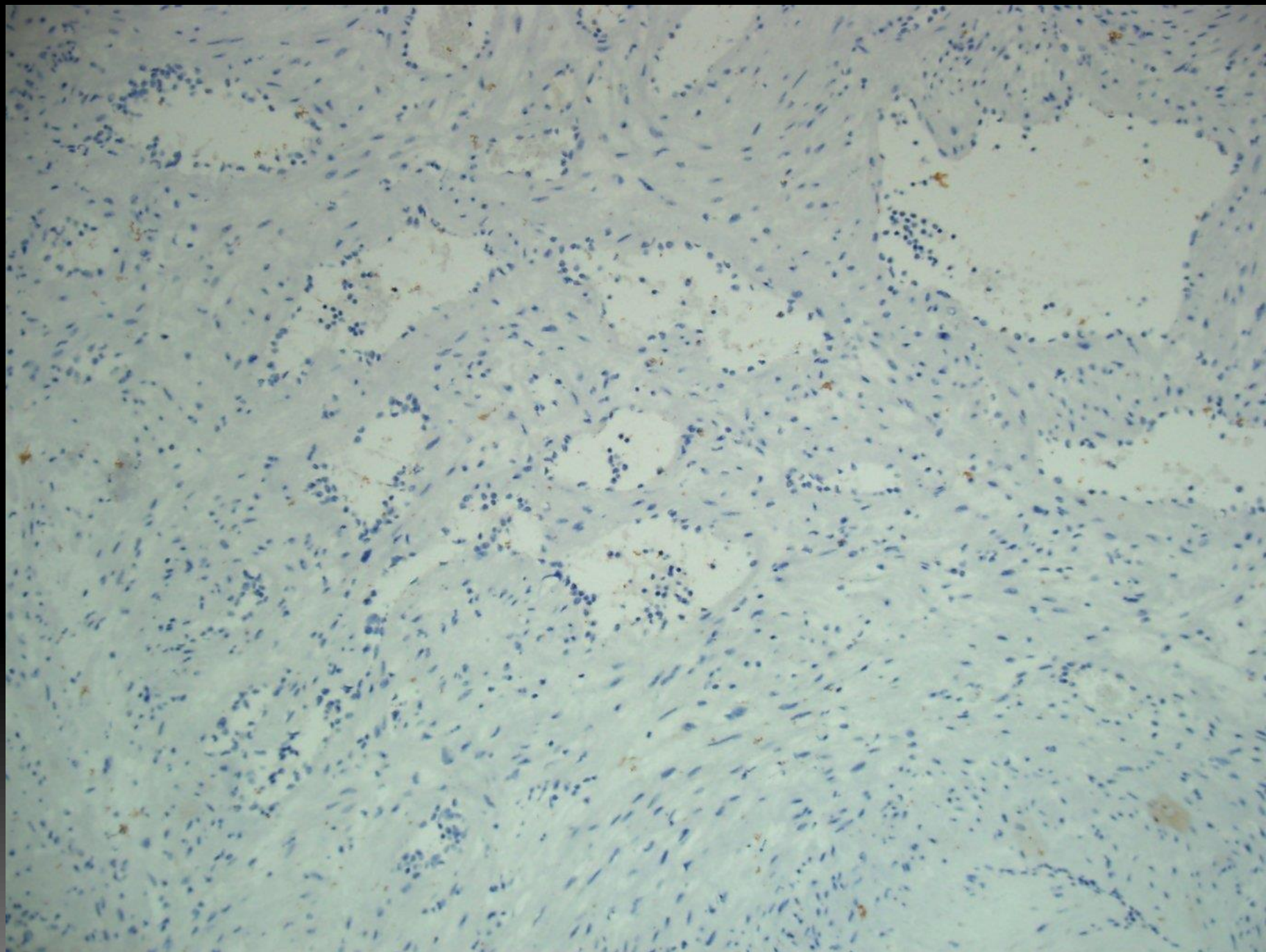
Trachea, excision; consistent with Angioleiomyoma.

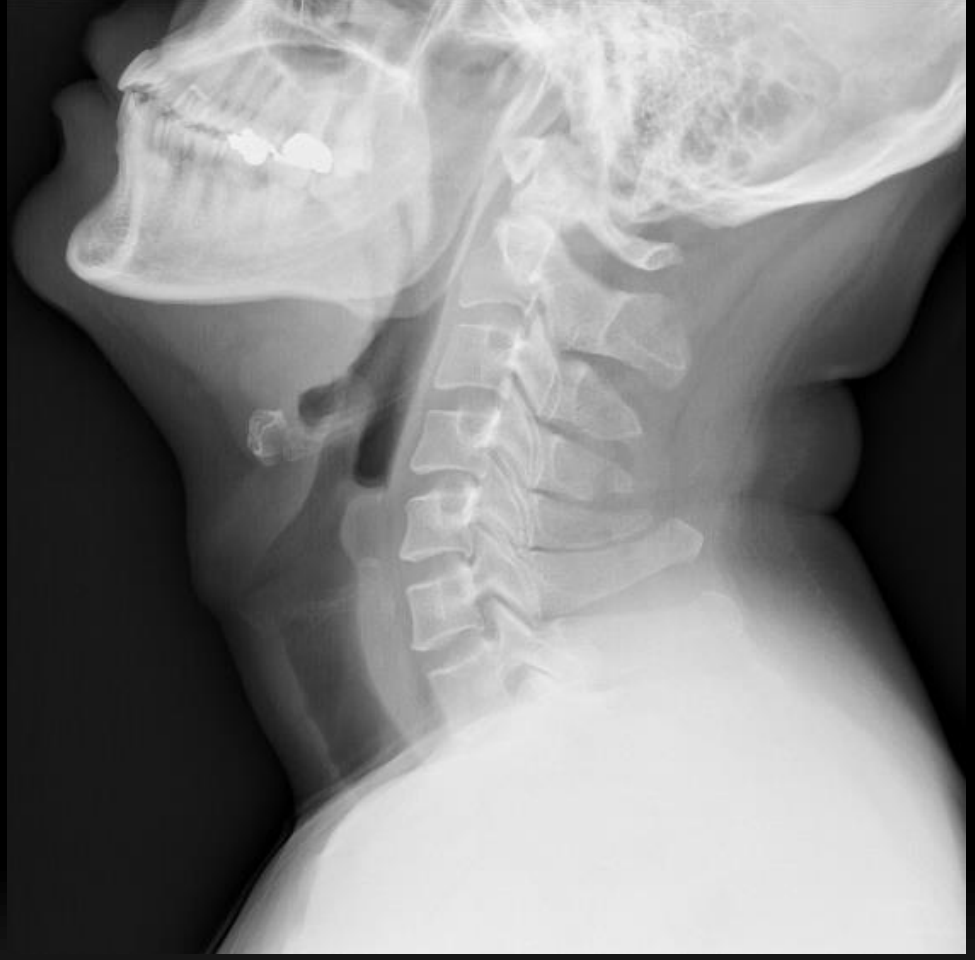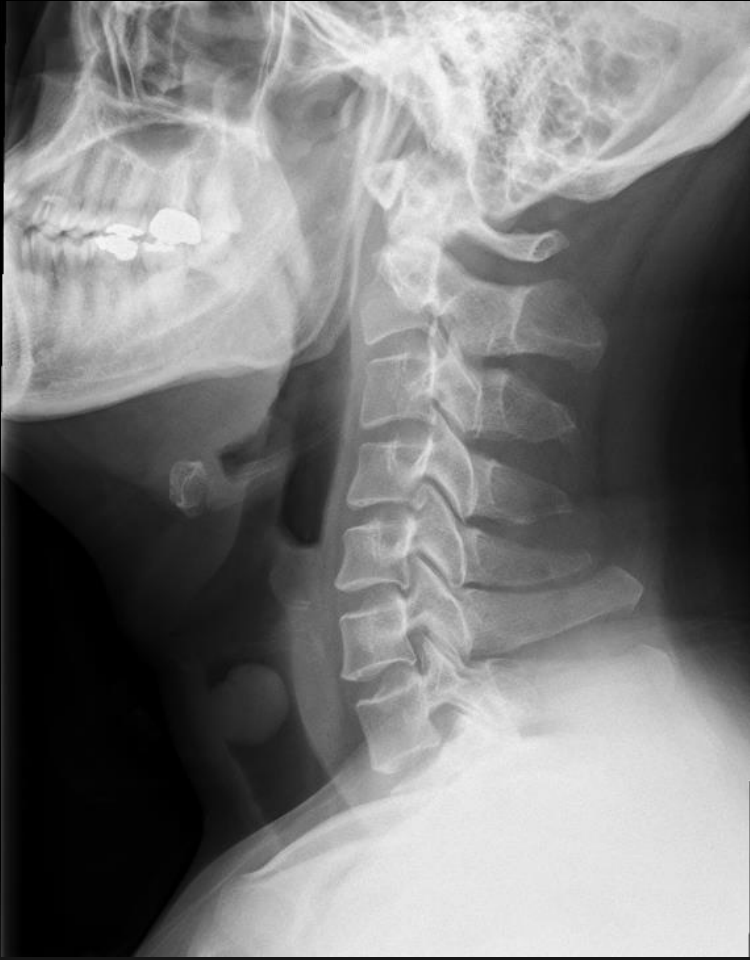[IMMUNOHISTOCHEMISTRY]

Actin / Desmin (positive / negative)









Progress note: 4m FU

S : "숨 차지 않고, 이물감도 안 느껴집니다."

PFT 호전

O : ACT 3-1-1-5-2 -> 2-1-1-1-1 -> 5-4-5-5-4
Globus symptom(-), dyspnea (-)

A : #1. Bronchial asthma
#2. Allergic rhinitis
#3. Old tuberculosis scar
#4. R/O GERD
#5. Angioleiomyoma, subglottic area

P : Step down

Review

- Vascular leiomyoma



Leiomyoma

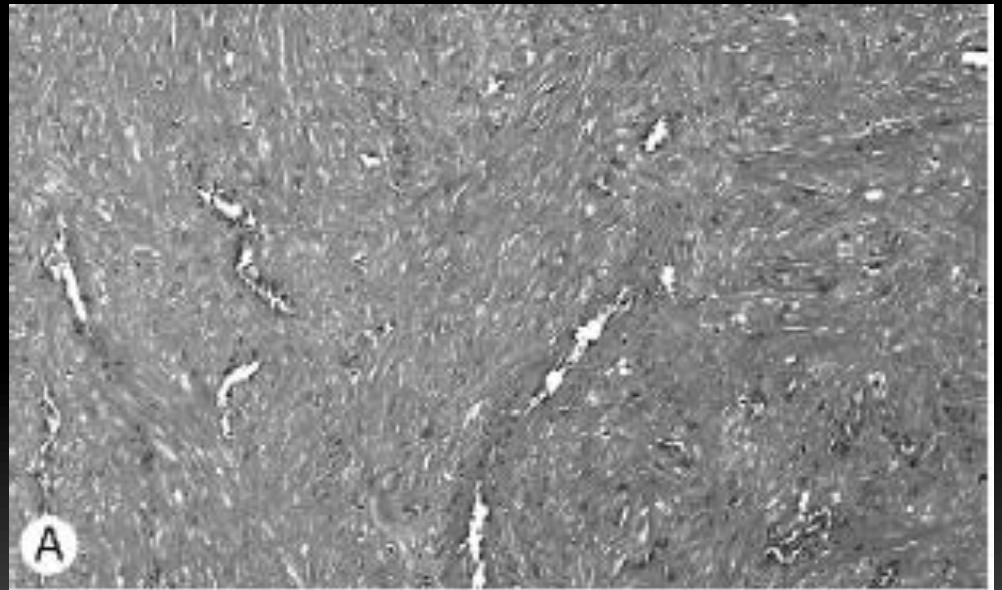
- ▣ Classification of Leiomyoma by WHO
 - Leiomyoma
 - Angiomyoma (vascular leiomyoma)
 - Epithelioid leiomyoma (leiomyoblastoma)

Vascular leiomyoma

- ▣ Arise from vascular smooth muscle cell(VSMC)
- ▣ Subset of leiomyoma
 - 1st described at 1937
(Solitary cutaneous and subcutaneous leiomyoma. Am J Cancer 1937)
- ▣ Female > Male
- ▣ 30-60 years
- ▣ Angiogenic tumor
- ▣ Classification by histology
 - Solid (A), venous (B), carvenous (C)

Vascular leiomyoma

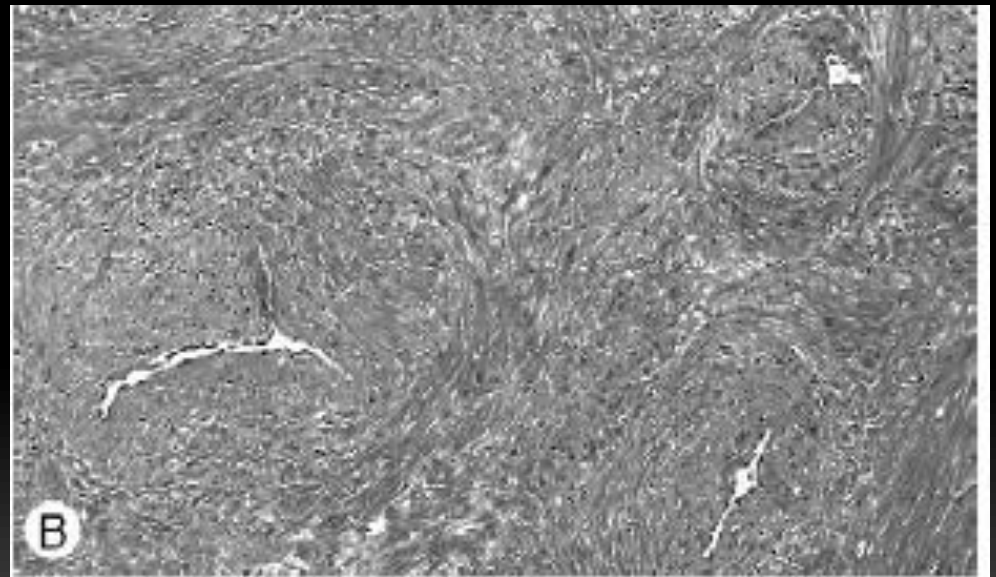
- Solid ; closely compacted bundles of smooth muscle cells and intervening small, thin-walled, slit-like vascular channels.



Human Pathology (2007) 38, 645– 651 ; Angioleiomyoma a clinicopathologic and immunohistochemical reappraisal

Vascular leiomyoma

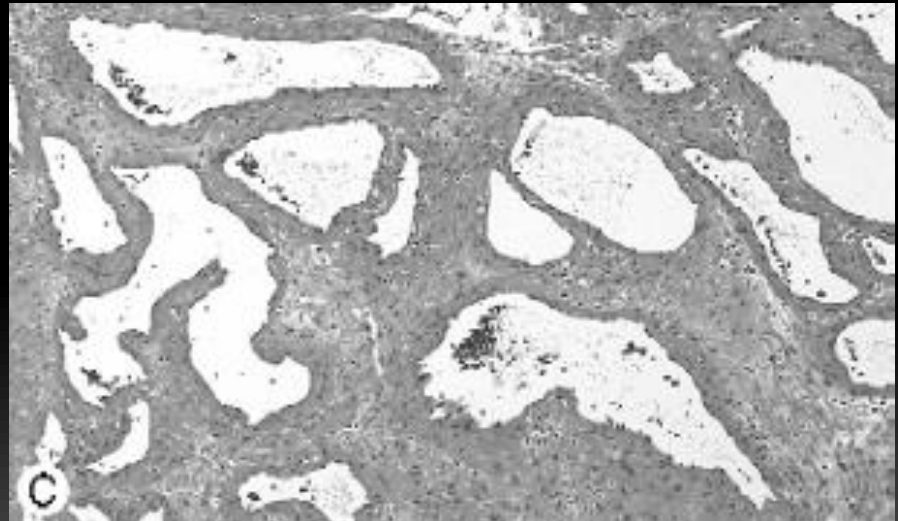- Venous-type ; tumors have thick muscle–coated vascular channels, and the smooth muscle of the vascular wall blends with intervascular smooth muscle bundles



Human Pathology (2007) 38, 645– 651 ; Angioleiomyoma a clinicopathologic and immunohistochemical reappraisal

Vascular leiomyoma

- Cavernous-type ; tumors are composed of dilated vascular channels with small amounts of smooth muscle, and the muscular walls of these vessels are difficult to distinguish from intervascular smooth muscle bundles



Human Pathology (2007) 38, 645– 651 ; Angioleiomyoma a clinicopathologic and immunohistochemical reappraisal

Vascular leiomyoma

Location	Male	Female	Total
Solid			
Upper extremity	21	36	57
Lower extremity	60	241 (83%)	301
Head	1	3	4
Trunk	2	10	12
Total	84	290	374
Cavernous			
Upper extremity	32 (65%)	8	40
Lower extremity	10	3	13
Head	7	1	8
Trunk	0	0	0
Total	49	12	61
Venous			
Upper extremity	17	11	28
Lower extremity	32	29	61
Head	22	14	36
Trunk	1	1	2
Total	72	55	127

Vascular leiomyoma

Location	Male	Female	Total
Location	Male	Female	Total
Lower extremity	102	273	375
Lower leg & ankle	51	178	229
Knee	28	42	70
Foot	18	29	47
Thigh	5	24	29
Upper extremity	70	55	125
Hand & finger	39	17	56
Forearm	13	26	39
Elbow	16	9	25
Upper arm	2	3	5
Head	30	18	48
Trunk	3	11	14
Total	205	357	562

Vascular leiomyoma

- Solid 74, venous 37, cavernous 11

	AL (n = 122)
Age (y)	
Range	30-80
Mean/median	54.1/55
Sex	
Male/female	51/71

Anatomic site	
Lower extremity	
Thigh	5
Knee	8
Popliteal fossa	4
Lower leg	25
Ankle	18
Foot	15
Sole	1
Toe	3
Upper extremity	
Upper arm	3
Elbow	7
Forearm	7
Finger	13
Hand	5
Head and neck	
Nasal cavity	4
External ear	2
Oral floor	
Scalp	
Trunk	
Back	1
Inguinal region	1
Pain	
Present	54
Absent	11
Unknown	57

Vascular leiomyoma

Table I. Characteristics of the 21-patient cohort.

Characteristic	Value (%)
Gender	
Male	13 (61.9)
Female	8 (38.1)
M/F ratio	1.625:1
Age, years	
Range	10-65
Mean	42.5
Males	42.4
Females	42.6
Site	
Buccal mucosa	6 (28.5)
Parotid gland	4 (19.0)
Palate	4 (19.0)
Nasolabial groove	2 (9.5)
Lip	1 (4.8)
Tongue	1 (4.8)
Gingiva	1 (4.8)
Mandible	1 (4.8)
Neck	1 (4.8)
Diameter, cm	
≤2	8 (38.1)
>2	13 (61.9)
Symptoms	
Painless	16 (76.2)
Tender	2 (9.5)
Spontaneously painful ^a	3 (14.3)

“The rarity of the tumor is likely due to the paucity of smooth muscle in the oral cavity, the primary source of smooth muscle being the tunica media of blood vessels”

Vascular leiomyoma

▣ VSMC proliferation

- Fibroblast growth factor (FGF)
- Vascular endothelial GF (VEGF)
- Tumor necrosis factor- α (TNF- α)
- PTHrP

->> Unknown etiology

▣ Lesion

- Common ; uterus, GI system, extremity, skin
- Rare ; cavernous sinus, auricular antihelix, turbinate, larynx

Vascular leiomyoma

■ Histopathology

- Special stain ; vimentin, desmin, actin, SMA, S-100, HHF35, CALP, CD34

	Desmin	SMA	HHF35	CALP	h-CD
Angioleiomyoma (n = 122)	77/24/21	122/0/0	122/0/0	122/0/0	100/22/0
Solid (n = 74)	56/9/9	74/0/0	74/0/0	74/0/0	59/15/0
Venous (n = 37)	19/10/8	37/0/0	37/0/0	37/0/0	30/7/0
Cavernous (n = 11)	2/5/4	11/0/0	11/0/0	11/0/0	11/0/0
Myopericytoma (n = 12)	0/3/9	12/0/0	12/0/0	12/0/0	11/0/1

Each case number is shown as ++/+/-.

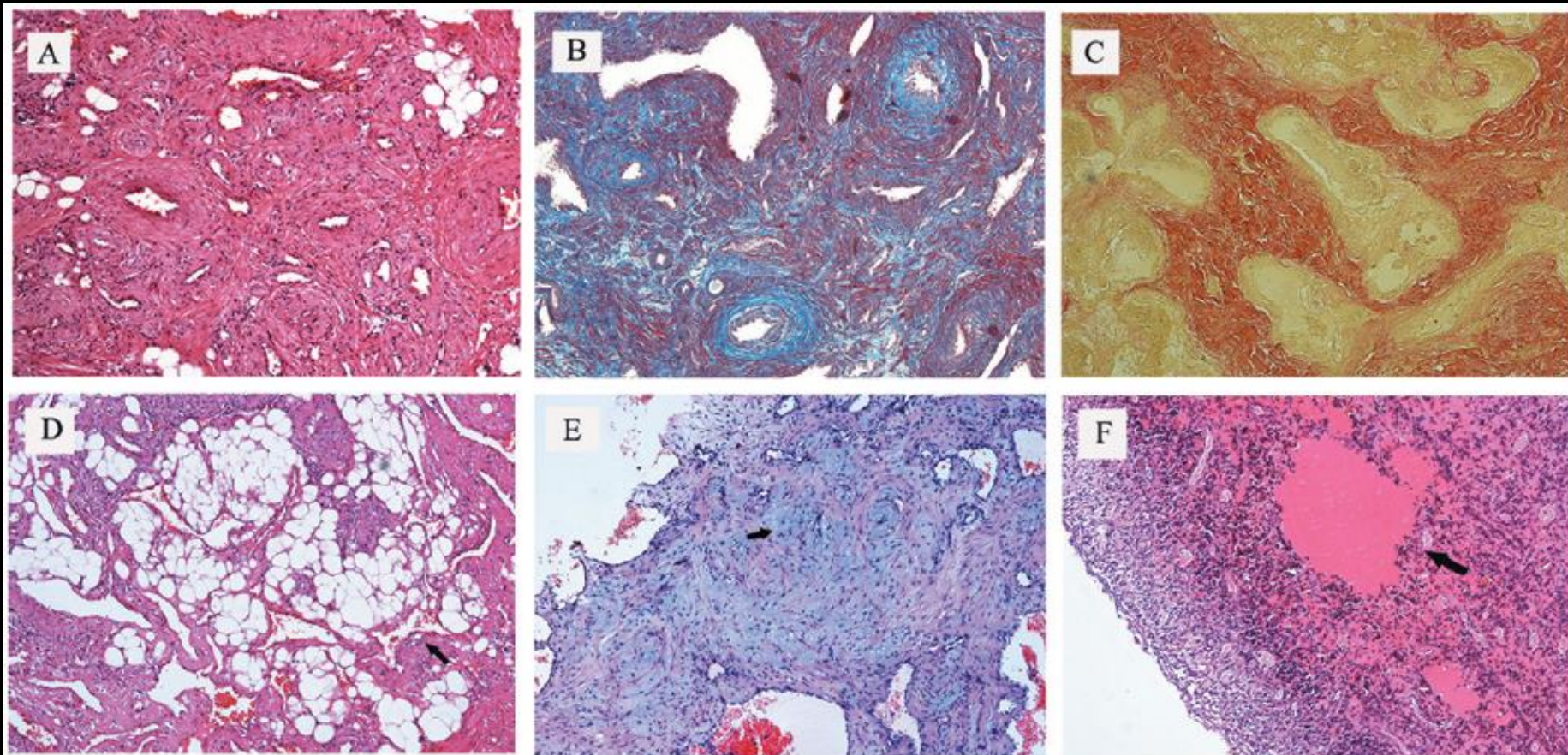


Figure 2. Angioleiomyoma tissue stained with H&E, Masson's trichrome and Van Gieson stains. (A) The angioleiomyoma comprised of rich vascular channels with thick vessel walls and smooth muscle bundles with elongated nuclei (magnification, x100). (B) Masson's stain showing smooth muscle fibers in red, erythrocytes in blue, collagen fibers in black and nuclei in black-blue (magnification, x100). (C) Van Gieson stain showing smooth muscle fibers in red and collagen fibers in yellow (magnification, x100). (D) Groups of mature fat cells observed by H&E staining (magnification, x100). (E) Focal myxoid change (black arrow) in the lesion, stained blue with H&E staining (magnification, x100). (F) Hyaline change (black arrow) observed by H&E staining (magnification, x100). H&E, hematoxylin and eosin.

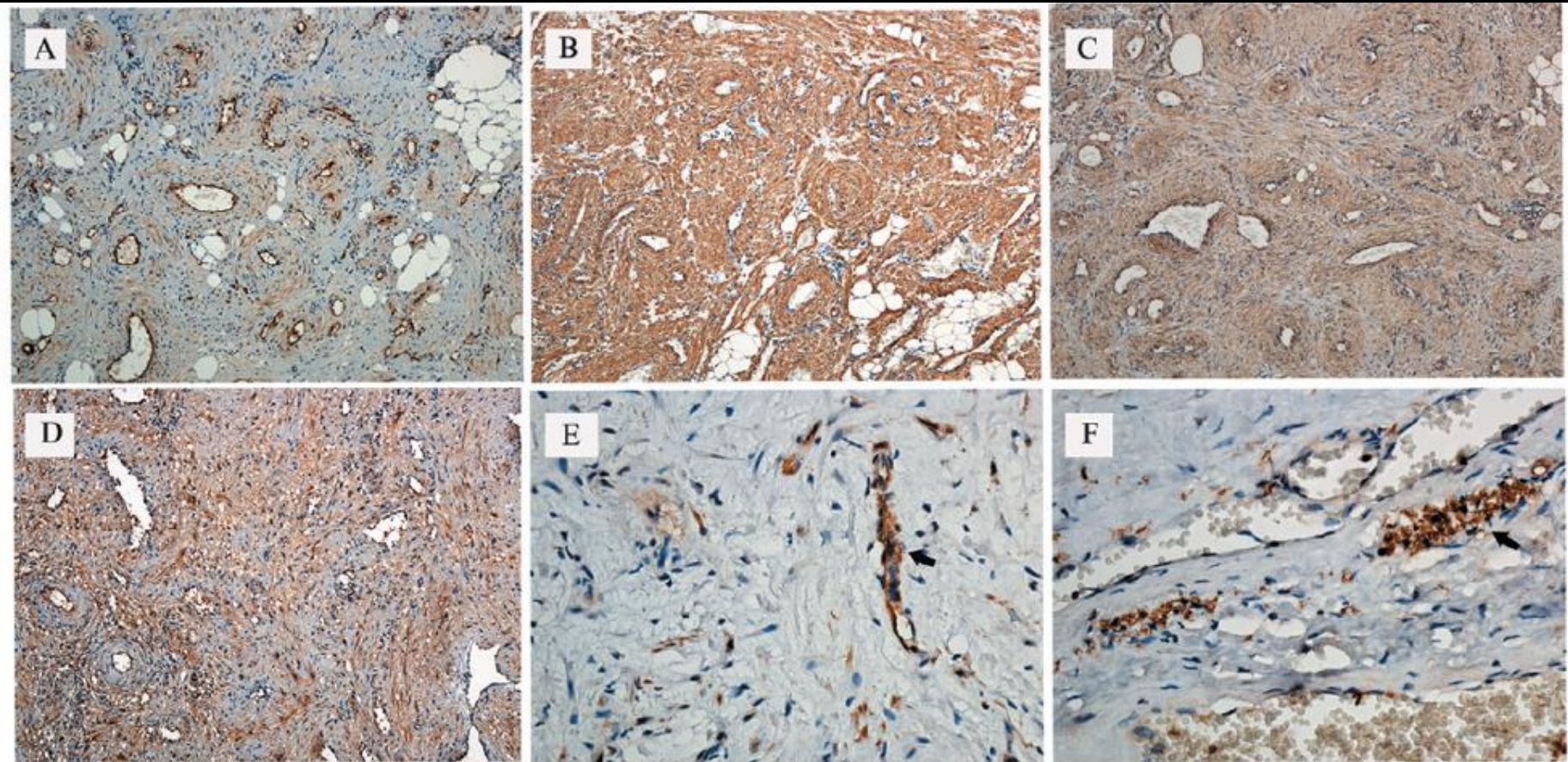


Figure 3. Immunohistochemical characteristics of head and neck angioleiomyoma. (A) Positive staining with anti-CD34 antibody exhibited by endothelial cells that lined the vascular spaces within the tumor (magnification, x100). (B) Diffuse positive staining with anti- α -actin smooth muscle antibody showing spindle-shaped cells in smooth muscle cell bundles in the tumor (magnification, x100). (C) Positive staining with anti-vimentin antibody showing expression in the cytoplasm of spindle-shaped cells (magnification, x100). (D) Positive staining with anti-desmin antibody showing expression in the cytoplasm of neoplastic cells in ALM (magnification, x100). (E) Positive staining with anti-S100 antibody showing nerve tissue near the capsule (black arrow; magnification, x400). (F) Positive staining with anti-S100 antibody showing occasional tiny neurofibrils, closely associated with vessels (black arrow; magnification, x400).

Vascular leiomyoma

- Genetics ; Translocation 45,XX,t(4;5)(p12;q33), der(13;15)(q10;q10)/46,XX
- Treatment ; Surgical excision
- Recurrence ; Rare. But recur had been reported. (suggesting that it is significant for the complete excision of the tumor along the capsule.)
- Malignant transformation ; highly unlikely. However, there are only two reports about the malignant transformation of the benign angioleiomyoma in the reviewed literature. So patients should be monitored after surgery.

Case report

Angioleiomyoma arising in the subglottic area to upper trachea of a patient having underlying asthma: a rare case

Yeoun Eun Sung¹, Chin Kook Rhee², Kyo Young Lee¹

¹Department of Pathology, Seoul St. Mary's Hospital, College of Medicine, The Catholic University of Korea, Republic of Korea

²Division of Pulmonary, Allergy and Critical Care Medicine, Department of Internal Medicine, Seoul St. Mary's Hospital, College of Medicine, The Catholic University of Korea

Catholic University of Korea

of Internal Medicine, Seoul St. Mary's Hospital, College of Medicine, The

Division of Pulmonary, Allergy and Critical Care Medicine, Department

Reference

- ▣ 대한결핵 및 호흡기학회 – 기침진료지침 2014
- ▣ ACCP Evidence-Based Clinical Practice Guidelines 2006
- ▣ Anatomy and Neurophysiology of Cough- CHEST Guideline and Expert Panel Report 2014
- ▣ Giant laryngeal angioleiomyomas: a case report with review of literature
 - American Journal of Otolaryngology 30 (2009) 219–220
- ▣ A subglottic mass mimicking near-fatal asthma
 - The Journal of Emergency Medicine, Vol. 26, No. 1, pp. 57–60, 2004
- ▣ Angioleiomyoma a clinicopathologic and immunohistochemical reappraisal
 - Human Pathology (2007) 38, 645–651
- ▣ Angioleiomyomas in the head and neck: A retrospective clinical and immunohistochemical analysis
 - ONCOLOGY LETTERS 8: 241-247, 2014