

Advanced Bronchoscopic Techniques for Diagnosis and Staging of Lung cancer

Dongil Park

Division of Pulmonary and Critical Care Medicine

Chungnam National University Hospital

Contents

- Radial EBUS-guided Lung biopsy
- Electromagnetic Navigation Bronchoscopy (ENB)
- Robotic-assisted Bronchoscopy (RAB)
- Real-Time (Radial) EBUS-Guided TBNA (RT-EBUS-TBNA)
- Transbronchial lung cryobiopsy (TBLC)
- Mediastinal cryobiopsy & Case

Radial EBUS-Guided Lung biopsy

- Diagnostic yield: about 70%
- Favorable factors: Bronchus sign, within orientation, size > 2 cm, guide sheath (GS), solid > part-solid/GGN, malignant lesion
- Complication
 - Pneumothorax: 0.7~2% (chest tube insertion: 0.2~0.9%)
 - Bleeding: 1.5~2.5%
 - Infection: 4.5% (Pneumonia: 2.3%, lung abscess: 0.3%, empyema: 0.3%)
 - Risk factors: cavitation, low-density intralesional area on CT, airway segmental/subsegmental stenosis on bronchoscopy

• Sainz Zuñiga, Paula V et al. "Sensitivity of Radial Endobronchial Ultrasound-Guided Bronchoscopy for Lung Cancer in Patients With Peripheral Pulmonary Lesions: An Updated Meta-analysis." *Chest* vol. 157,4 (2020): 994-1011.

• Oki, Masahide et al. "Guide sheath versus non-guide sheath method for endobronchial ultrasound-guided biopsy of peripheral pulmonary lesions: a multicentre randomised trial." *The European respiratory journal* vol. 59,5 2101678.

• Ali, Muhammad S et al. "Radial endobronchial ultrasound for the diagnosis of peripheral pulmonary lesions: A systematic review and meta-analysis." *Respirology (Carlton, Vic.)* vol. 22,3 (2017): 443-453.

• McGuire, Anna L et al. "The Diagnostic Accuracy and Sensitivity for Malignancy of Radial-Endobronchial Ultrasound and Electromagnetic Navigation Bronchoscopy for Sampling of Peripheral Pulmonary Lesions: Systematic Review and Meta-analysis." *Journal of bronchology & interventional pulmonology* vol. 27,2 (2020): 106-121.

With Guide sheath (GS) vs. Without GS

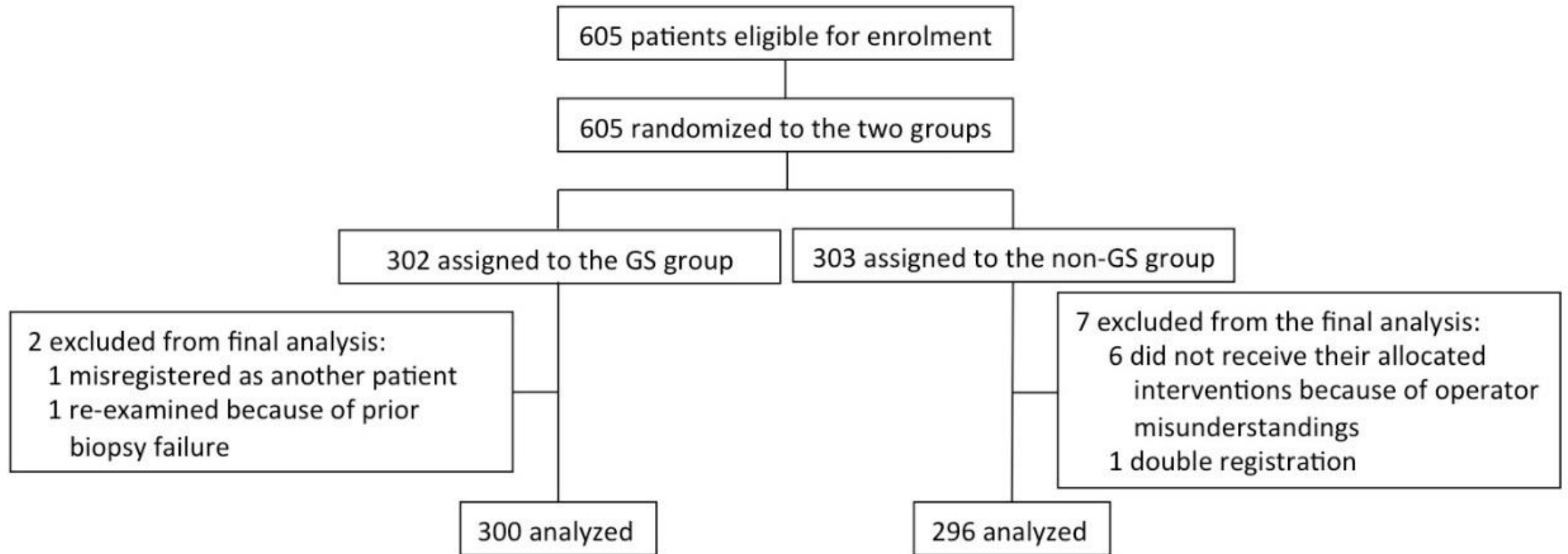
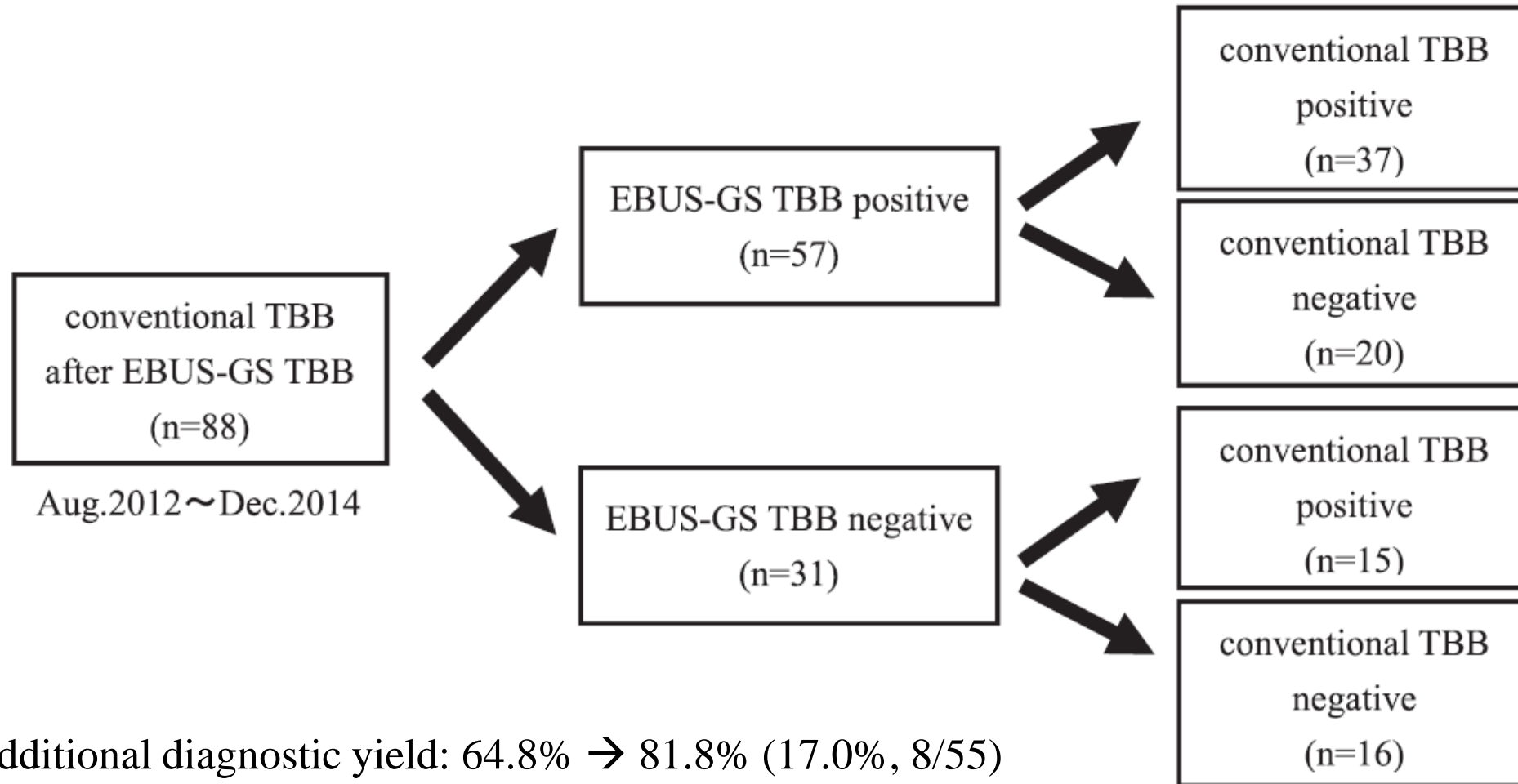


TABLE 3 Histopathological diagnostic yields of the allocated procedures.

Variables	Guide sheath group (n = 300)				Non-guide sheath group (n = 296)				P-value [#]	P-value for interaction ^f
	N/Total	(%)	95% CI	P-value	N/Total	(%)	95% CI	P-value		
Total	166/300	(55.3)	49.5–61.1		138/296	(46.6)	50.8–52.5		0.033	
Lesion size, mm										
≤ 20	79/159	(49.7)	41.7–57.7] 0.037	76/163	(46.6)	38.8–54.6] 0.999	0.583] 0.140
> 20 to 30	87/141	(61.7)	53.2–69.8		62/133	(46.6)	37.9–55.5		0.012	
Lesion type										
Malignant	155/237	(65.4)	59.0–71.4] < 0.001	128/231	(55.4)	46.6–59.8] < 0.001	0.027] 0.531
Benign	11/61	(18.0)	9.4–30.0		10/60	(16.7)	8.3–28.5		0.843	
Unknown	0/2	(0)			0/5	(0)			–	
Lobar location										
Upper lobe	101/160	(63.1)	55.2–70.6] 0.004	63/147	(42.9)	34.7–51.3] 0.197	< 0.001] 0.003
Other lobes	65/140	(46.4)	38.0–55.1		75/149	(50.3)	42.0–58.6		0.507	
Lesion location with respect to the hilum										
Intermediate	31/47	(66.0)	50.7–79.1] 0.111	28/45	(62.2)	46.5–76.2] 0.023	0.709] 0.639
Peripheral	135/253	(53.4)	47.0–59.6		110/251	(43.8)	37.6–50.2		0.032	
Positional relationship with the pleura										
Distant from the pleura	106/184	(57.6)	50.1–64.9] 0.318	90/167	(53.9)	46.0–61.6] 0.004	0.484] 0.191
Abutting the pleura	60/116	(51.7)	42.3–61.1		48/129	(37.2)	28.9–46.2		0.022	
Bronchus sign										
Present	142/240	(59.2)	52.7–65.5] 0.008	115/234	(49.1)	42.6–55.7] 0.091	0.029] 0.497
Absent	24/60	(40.0)	27.6–53.5		23/62	(37.1)	25.2–60.3		0.742	
Lesion texture on CT										
Solid	148/260	(56.9)	50.7–63.0] 0.158	116/256	(45.3)	39.1–51.6] 0.253	0.008] 0.072
Part-solid	18/40	(45.0)	29.3–61.5		22/40	(55.0)	38.5–70.7		0.371	



- Additional diagnostic yield: 64.8% → 81.8% (17.0%, 8/55)
- Fluoroscopy-guided TBLB
- 4.0/4.9 mm bronchoscope with 2.0 mm WC

CT-BS group I

“Obstructed” Type Ia	“Narrowing” Type Ib	“Penetrating” Type Ic
---------------------------------	--------------------------------	----------------------------------

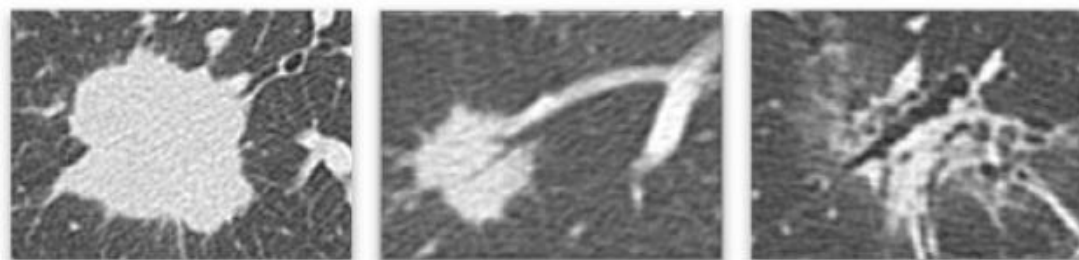
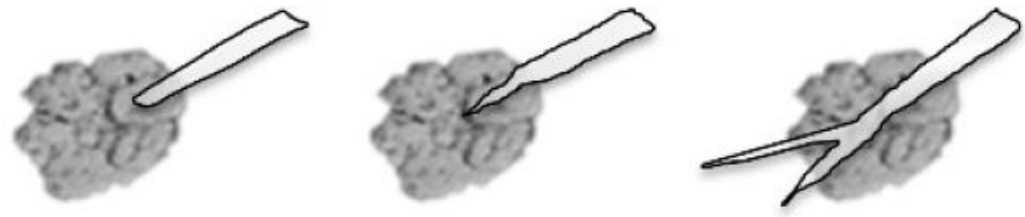Tsuboi et al. (1967) : I	II	
---------------------------------	-----------	--

Qiang et al. (2004) : I	II	III
--------------------------------	-----------	------------

Shinagawa et al. (2007) : 1

Minezawa et al. (2015) : A

Tokoro et al. (2016) : 2



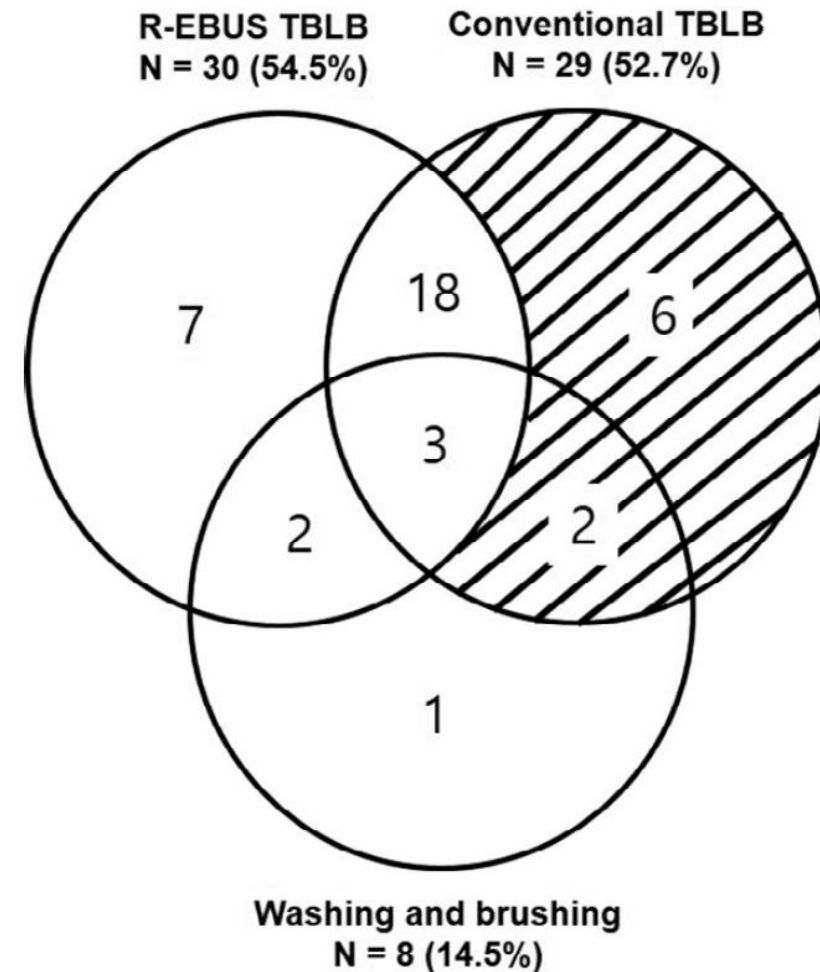
d by EBUS-GS TBB and underwent conventional TBB

3 negative (n = 31)

conventional TBB negative Group (n = 16/31)	P-value
70 ± 13.3	NS (0.523)
5/11	NS (0.611)
8	NS (0.853)
8	NS (0.585)
6	
1	
2	
4	
3	
15	NS (0.574)
0	
1	
10	< 0.05
1	
5	
0.4 ± 0.63	NS (0.188)
1.1 ± 1.1	NS (0.11)

EBUS-GS-TBLB + conventional forceps TBLB

- Additional diagnostic yield: 14.5% (8/55)
- Fluoroscopy-guided TBLB
- 4.8 mm bronchoscope (BF-Q290; Olympus, Tokyo, Japan)
- Lesion size: 28 mm
- Solid nodule: 81.8% (45/55)
- ‘Within’: 32 (58.2%)



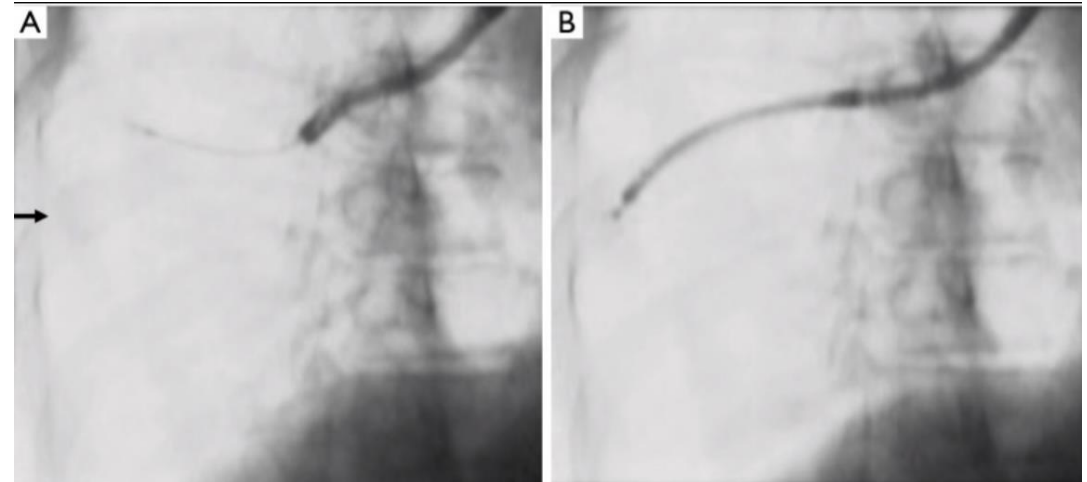
Thin bronchoscope (TB) vs. UltraTB

- TB

- Outer diameter – 4 mm
- Working channel – 2 mm

- UTB

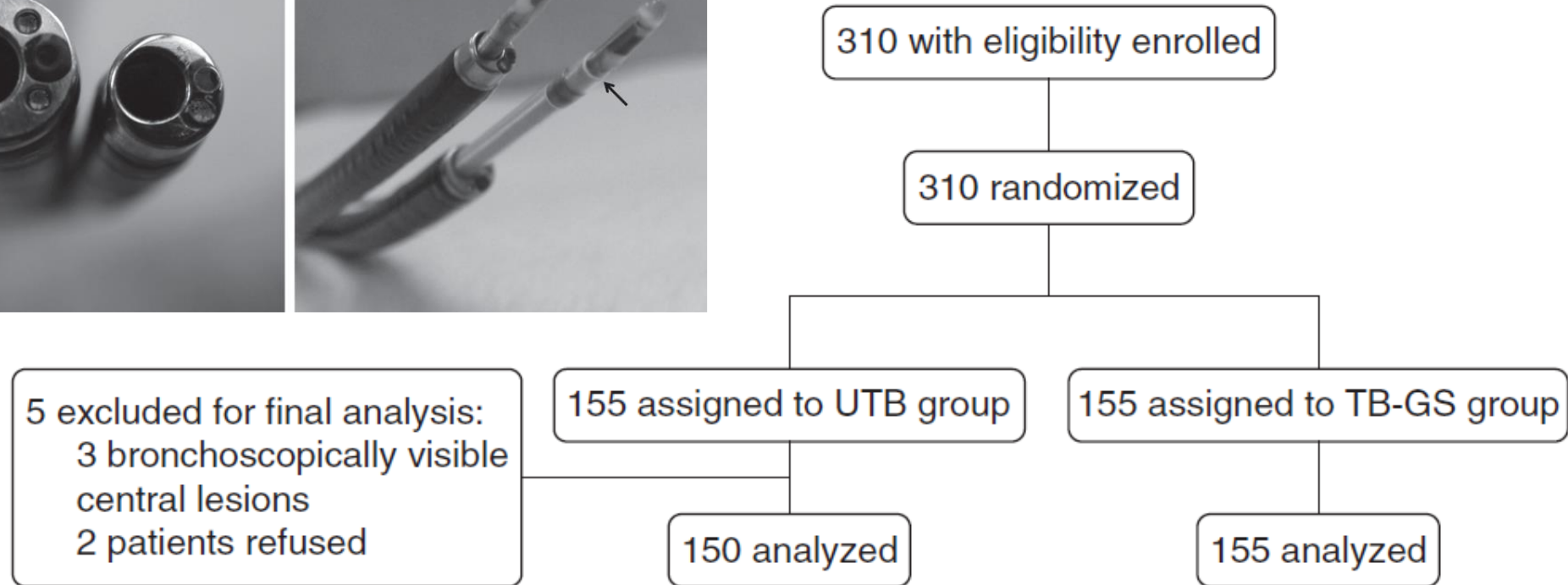
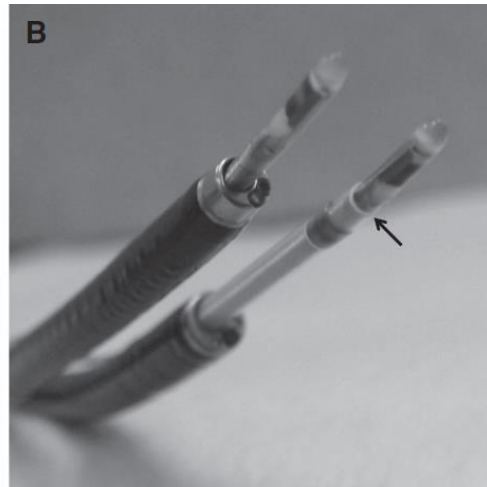
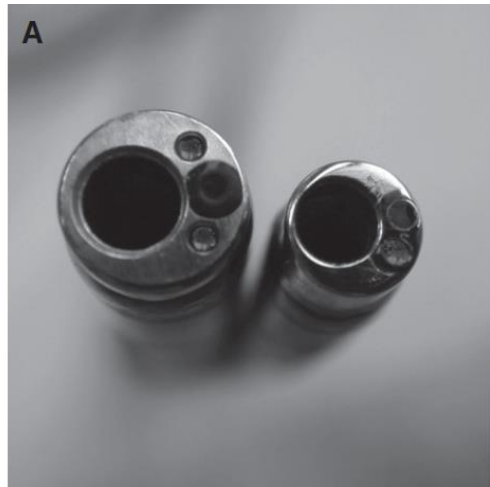
- Outer diameter < 3.0~3.5 mm
- Working channel 1.2 mm/1.7 mm



Ultrathin Bronchoscopy with Multimodal Devices for Peripheral Pulmonary Lesions

A Randomized Trial

Masahide Oki¹, Hideo Saka¹, Masahiko Ando², Fumihiro Asano³, Noriaki Kurimoto⁴, Katsuhiko Morita⁵, Chiyo Kitagawa¹, Yoshihito Kogure¹, and Teruomi Miyazawa⁶



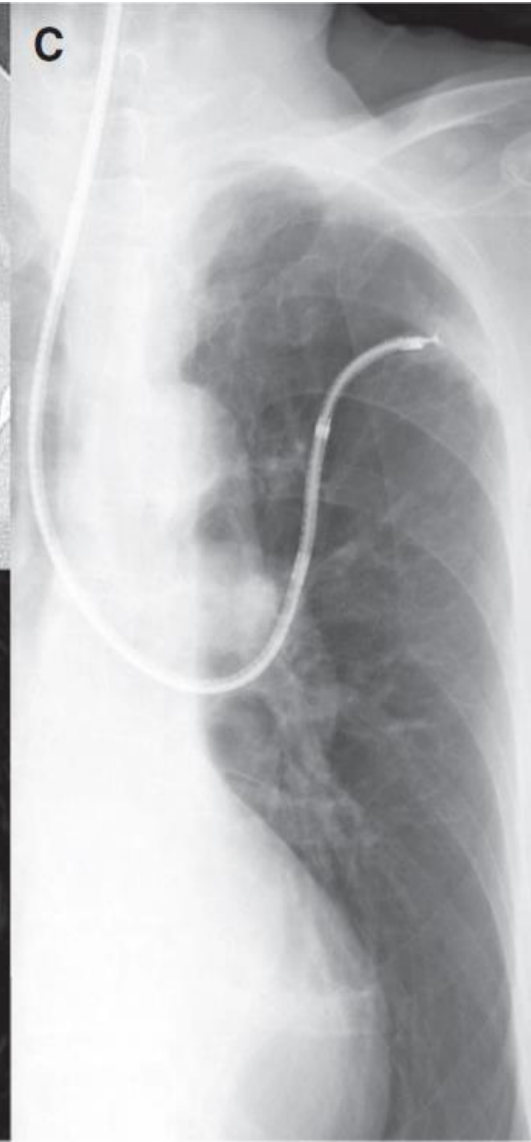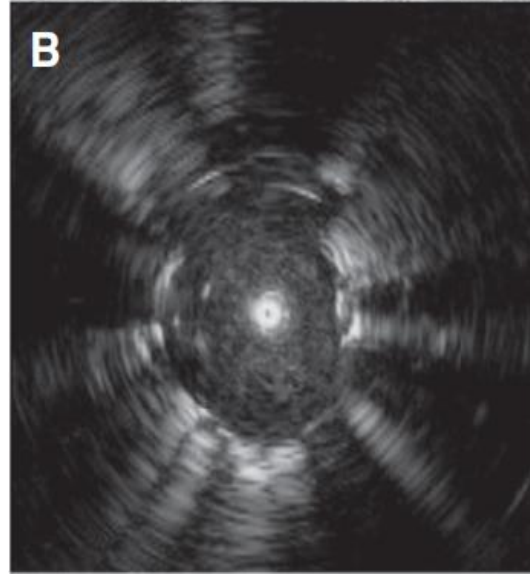
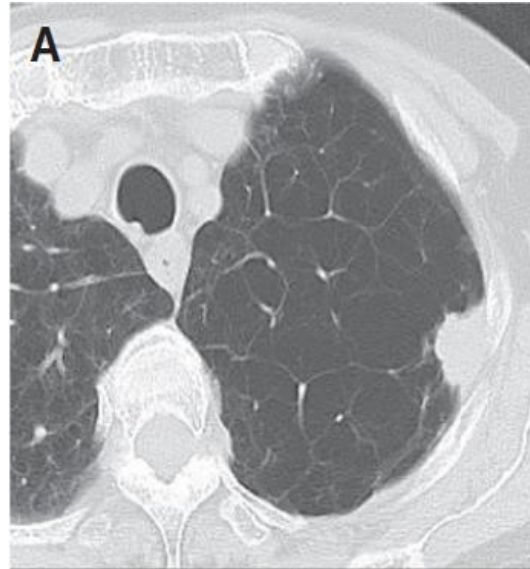
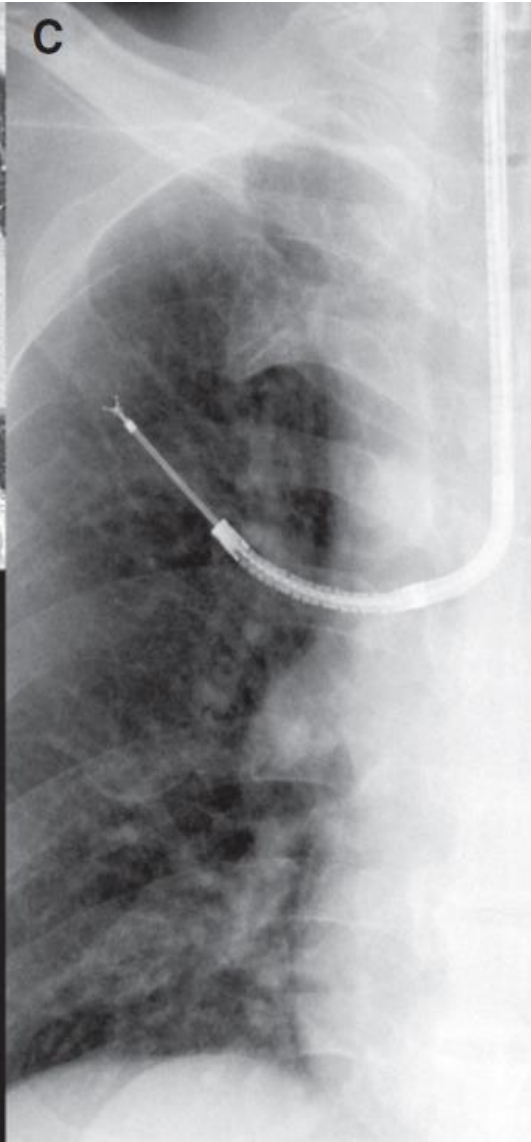
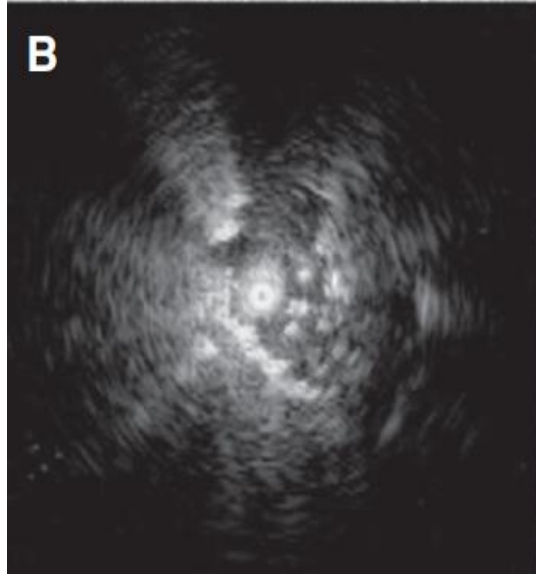
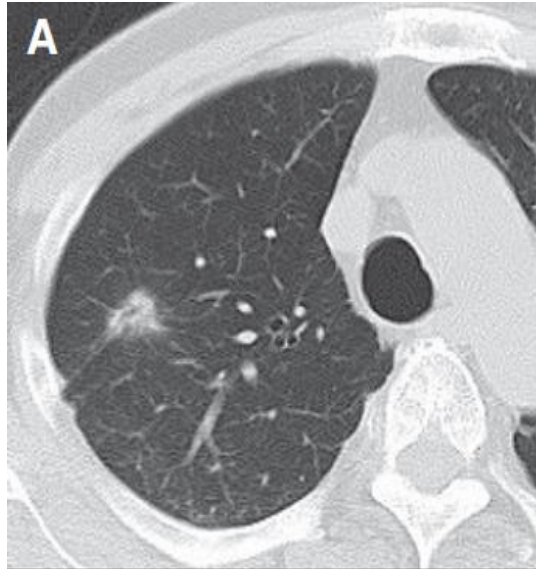


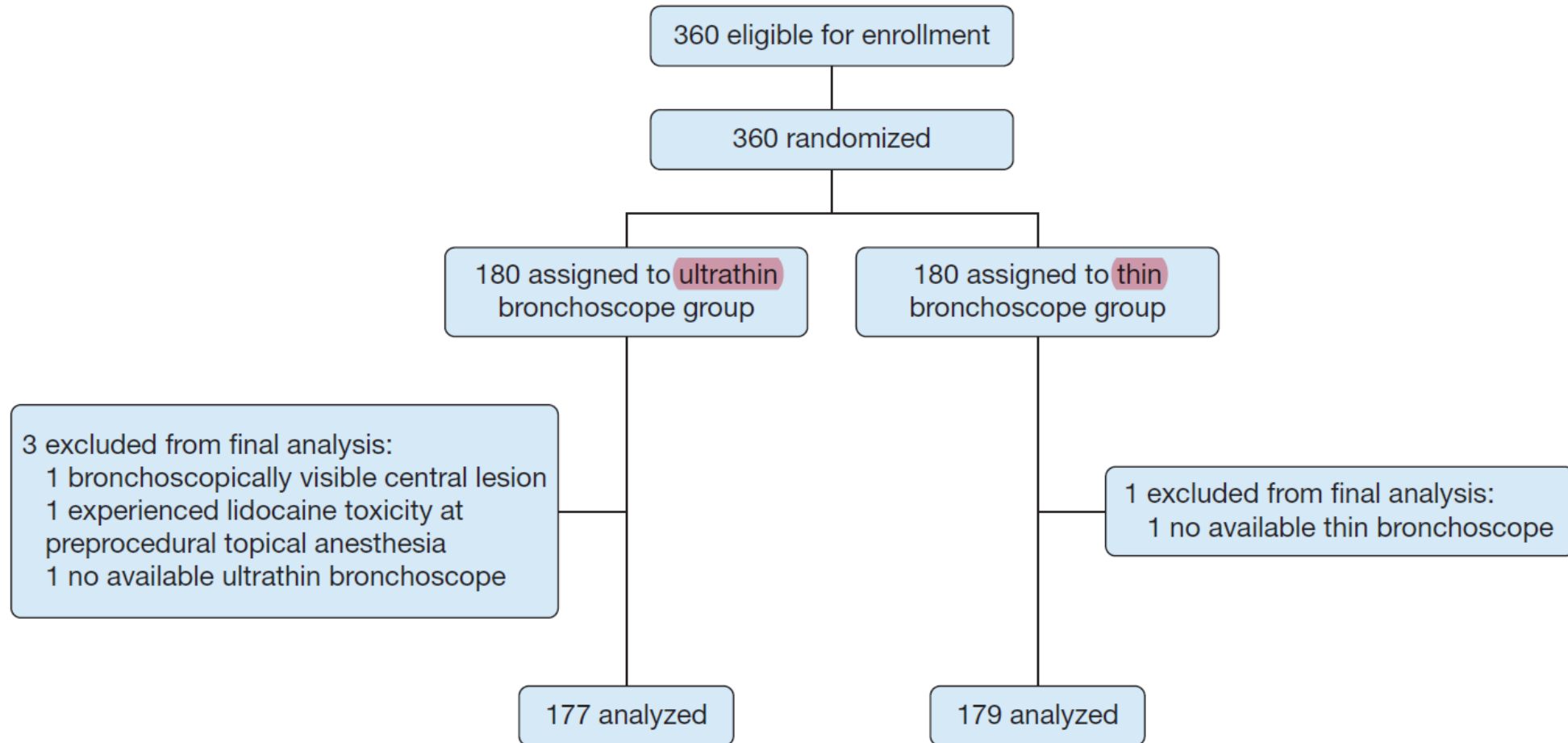
Table 3. Histopathologic Diagnostic Yield

Variables	UTB Group (n = 150)			TB-GS Group (n = 155)			P Value
	N/Total (%)	95% CI	P Value	N/Total (%)	95% CI	P Value	
Benign							
≤20 mm	5/17 (29)	10–56] 0.067	5/24 (21)	7–42] 0.019	0.529
>20 to ≤30 mm	6/9 (67)	30–93		11/20 (55)	32–77		0.555
Total	11/26 (42)	23–63		16/44 (36)	22–52		0.622
Malignant							
≤20 mm	47/62 (76)	63–86] 0.115	35/57 (61)	48–74] 0.048	0.090
>20 to ≤30 mm	53/61 (87)	76–94		41/52 (79)	65–89		0.255
Total	100/123 (81)	73–88		76/109 (70)	60–78		0.040
Unknown*							
≤20 mm	0/1 (0)			0/1 (0)			
>20 to ≤30 mm				0/1 (0)			
All							
≤20 mm	52/80 (65)	54–75] 0.007	40/82 (49)	38–60] 0.005	0.037
>20 to ≤30 mm	59/70 (84)	74–92		52/73 (71)	59–81		0.061
Total	111/150 (74)	66–81		92/155 (59)	51–67		0.044 [†]

Variables	UTB Group (n = 150)		TB-GS Group (n = 155)		P Value [†]
Bronchus level reached with the bronchoscope, median (range), generation, all	5 (3–12)		4 (2–7)		<0.001
Right upper lobe	5 (4–9)] P = 0.084	4 (2–7)] P = 0.385	<0.001
Right middle lobe	6 (4–12)		4 (3–7)		0.031
Right lower lobe	5 (3–9)		4 (3–6)		<0.001
Left upper lobe	5 (4–7)		4 (3–7)		0.002
Lingula	5 (3–7)		4 (3–5)		0.186
Left lower lobe	4 (3–8)		4 (3–7)		0.173
Histopathologic diagnostic yield by lobar location					
Right upper lobe	32/45 (71)] P = 0.389	36/57 (63)] P = 0.380	0.398
Right middle lobe	13/17 (64)		4/8 (50)		0.186
Right lower lobe	23/36 (76)		18/30 (60)		0.745
Left upper lobe	20/23 (87)		20/32 (63)		0.045 [‡]
Lingula	4/6 (67)		5/6 (83)		0.505
Left lower lobe	19/23 (83)		9/22 (41)		0.004 [§]
Histopathologic diagnostic yield by lesion location from the hilum					
Central or intermediate	24/37 (65)] P = 0.144	28/44 (64)] P = 0.494	0.909
Peripheral	87/113 (77)		64/111 (58)		0.002
Histopathologic diagnostic yield by bronchus sign					
Present	94/115 (82)] P < 0.001	80/127 (63)] P = 0.050	0.001 [¶]
Absent	17/35 (49)		12/28 (43)		0.651
Location of probe in relation to lesion confirmed by EBUS					
Within the lesion	117 (78)] P = 0.080	103 (66)] P = 0.101	0.080
Adjacent to the lesion	26 (17)		41 (26)		
Invisible with EBUS	7 (5)		11 (7)		
Procedural time, median (range), min	27.5 (12–77)		28.5 (15–81)		0.101
Complications, all	5 (3)		7 (5)		0.595
Pneumothorax	3 (2)		5* (3)		
Pneumonia	1 (1)		0 (0)		
Bleeding	0 (0)		2 (1)		
Chest pain	1 (1)		0 (0)		

Use of an Ultrathin vs Thin Bronchoscope for Peripheral Pulmonary Lesions

A Randomized Trial



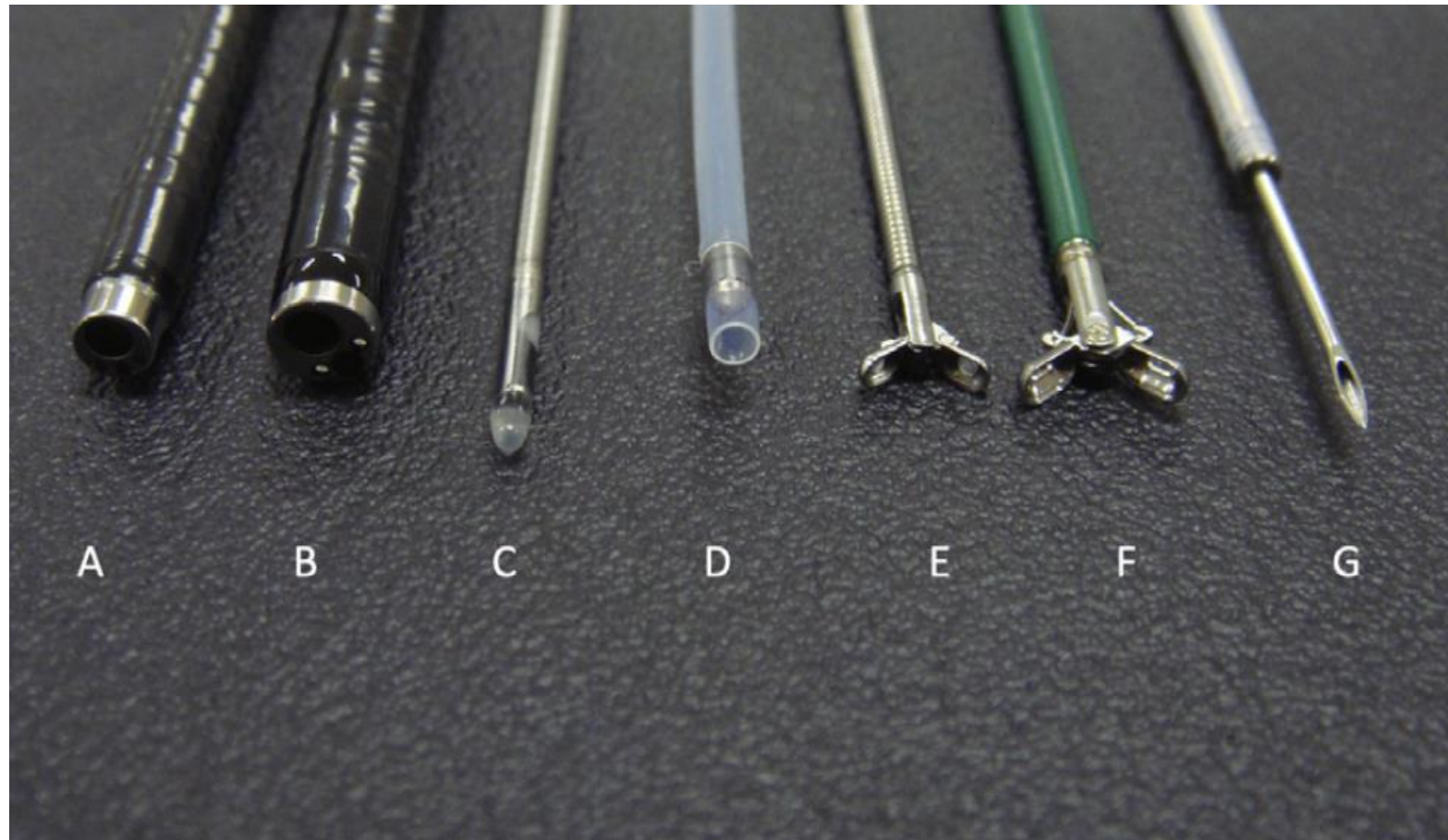
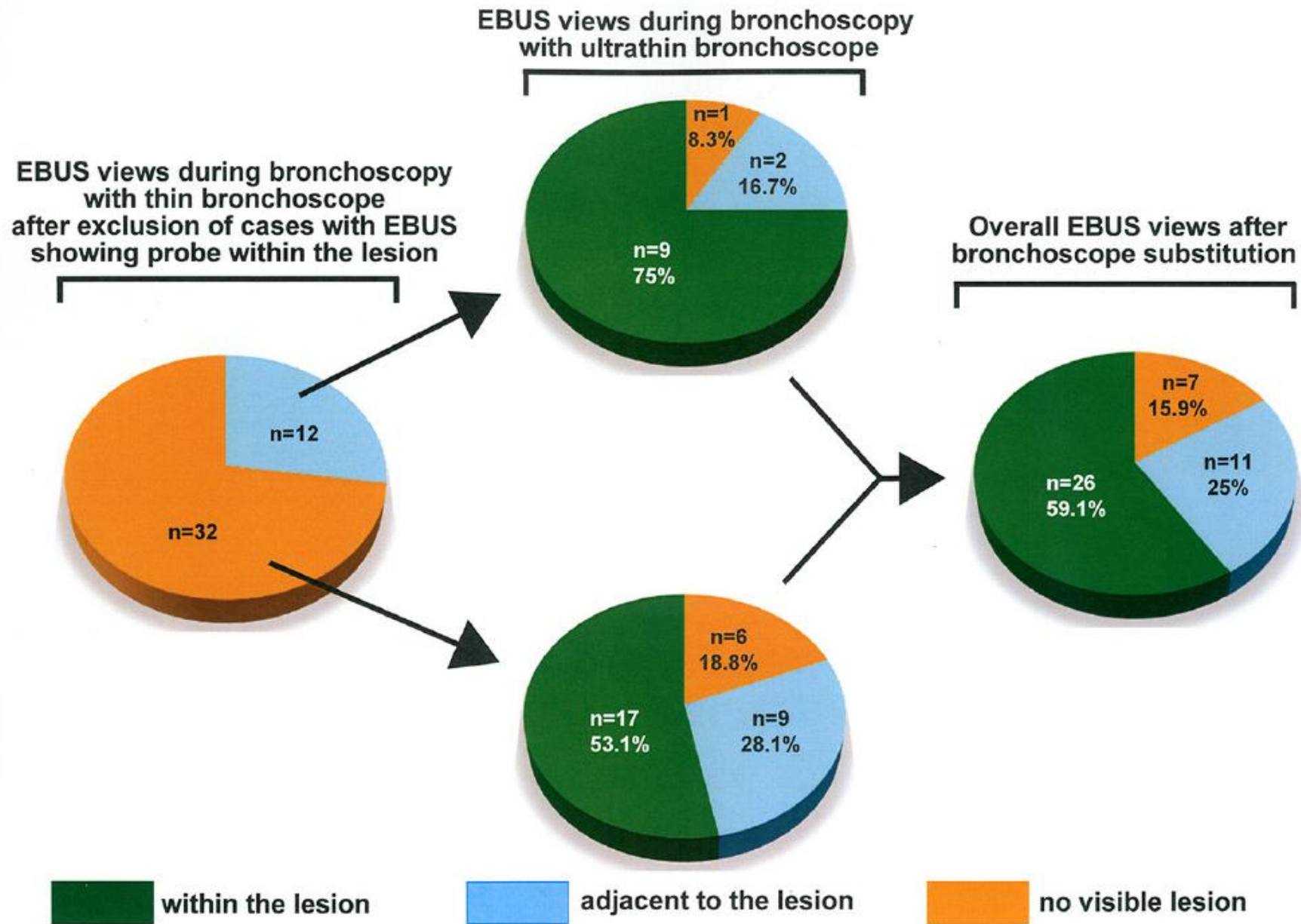


Figure 1 – Bronchoscopes and sampling instruments: a 3.0-mm ultrathin bronchoscope with a 1.7-mm working channel (marker A); a 4.0-mm thin bronchoscope with a 2.0-mm working channel (marker B); the 1.4-mm-diameter, radial, endobronchial ultrasound probe (marker C); the guide sheath (marker D); the 1.5-mm biopsy forceps (marker E); the 1.9-mm standard-sized biopsy forceps (marker F); and the 21-gauge needle (marker G).

TABLE 5] Diagnostic Yield

Variables	UTB Group (n = 177)		Thin Bronchoscope Group (n = 179)		P Value	P Value for Interaction ^a
Total	124/177 (70.1)		105/179 (58.7)		.027	
Lesion size in the largest diameter on CT scan						
≤ 20 mm	64/102 (62.7)	<i>P</i> = .004	52/101 (51.5)	<i>P</i> = .027	.120	<i>P</i> = .664
> 20 to ≤ 30 mm	62/75 (82.7)		53/78 (67.9)		.041	
Lesion nature						
Malignant	111/142 (78.2)	<i>P</i> < .001	99/140 (70.7)	<i>P</i> < .001	.173	<i>P</i> = .172
Benign	13/32 (40.6)		6/37 (16.2)		.032	
Unknown	0/3 (0)		0/2 (0)		...	
Lobar location						
Upper lobe	56/85 (65.9)	<i>P</i> = .244	61/97 (62.9)	<i>P</i> = .212	.757	<i>P</i> = .089
Other	68/92 (73.9)		44/82 (53.7)		.007	
Lesion location from the hilum						
Intermediate	29/40 (72.5)	<i>P</i> = .701	26/37 (70.3)	<i>P</i> = .107	1.000	<i>P</i> = .163
Peripheral	95/137 (69.3)		79/142 (55.6)		.019	
Locational relationship with pleura						
Apart from the pleura	73/102 (71.6)	<i>P</i> = .608	67/105 (63.8)	<i>P</i> = .096	.368	<i>P</i> = .448
Abutting on the pleura	51/75 (68.0)		38/74 (51.4)		.046	
Bronchus sign						
Present	97/130 (74.6)	<i>P</i> = .028	87/133 (65.4)	<i>P</i> = .002	.109	<i>P</i> = .549
Absent	27/47 (57.4)		18/46 (39.1)		.098	
Appearance on CT scan						
Solid	107/148 (72.3)	<i>P</i> = .141	94/153 (61.4)	<i>P</i> = .067	.051	<i>P</i> = .784
Part-solid nodule	17/29 (58.6)		11/26 (42.3)		.285	



Overall DY: 65.9%
'Within': 80.8%
'Adjacent to': 72.7%
'Invisible': 0%

Value of adding ultrathin bronchoscopy to thin bronchoscopy for peripheral pulmonary lesions: A multicentre prospective study

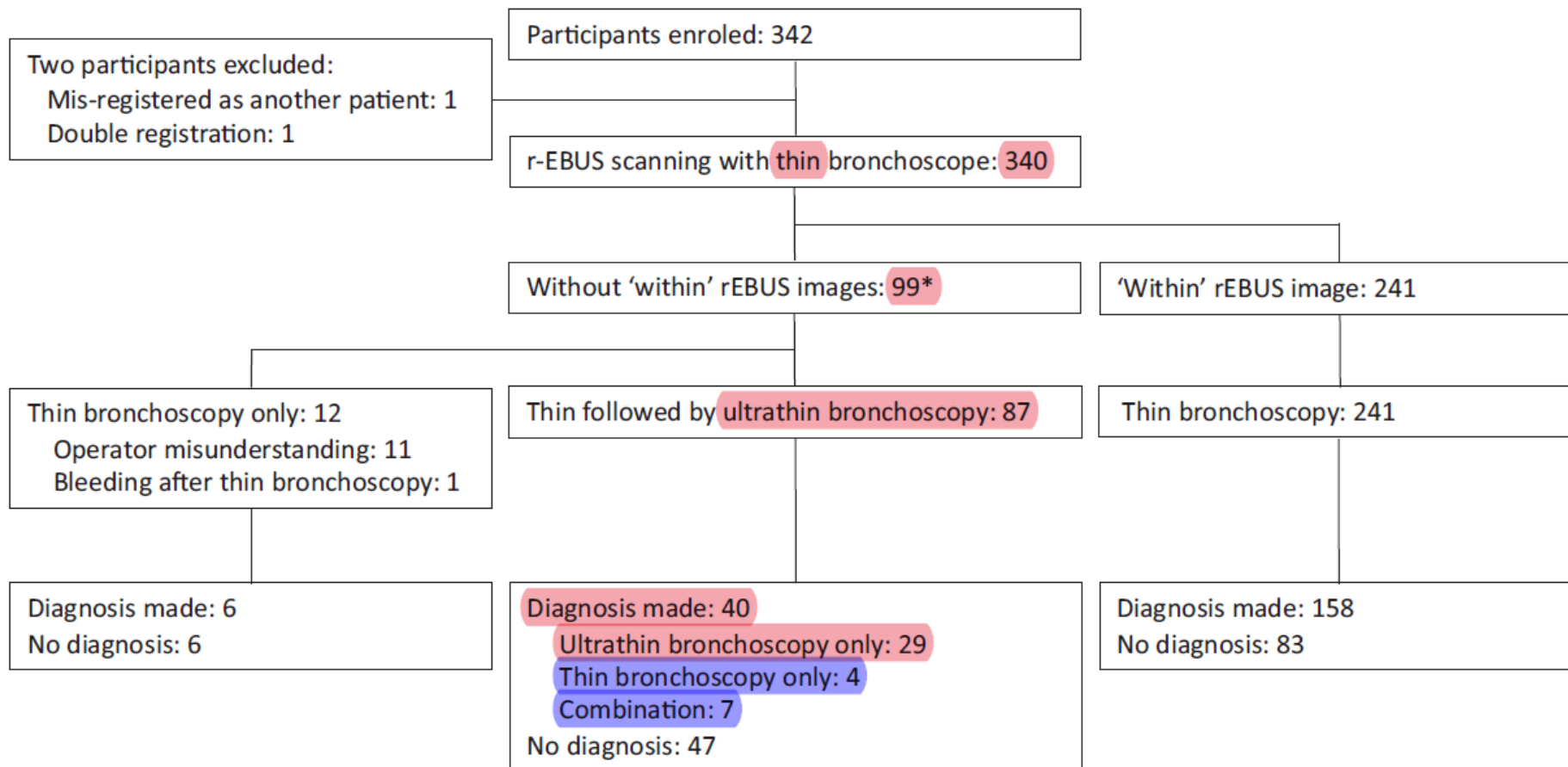


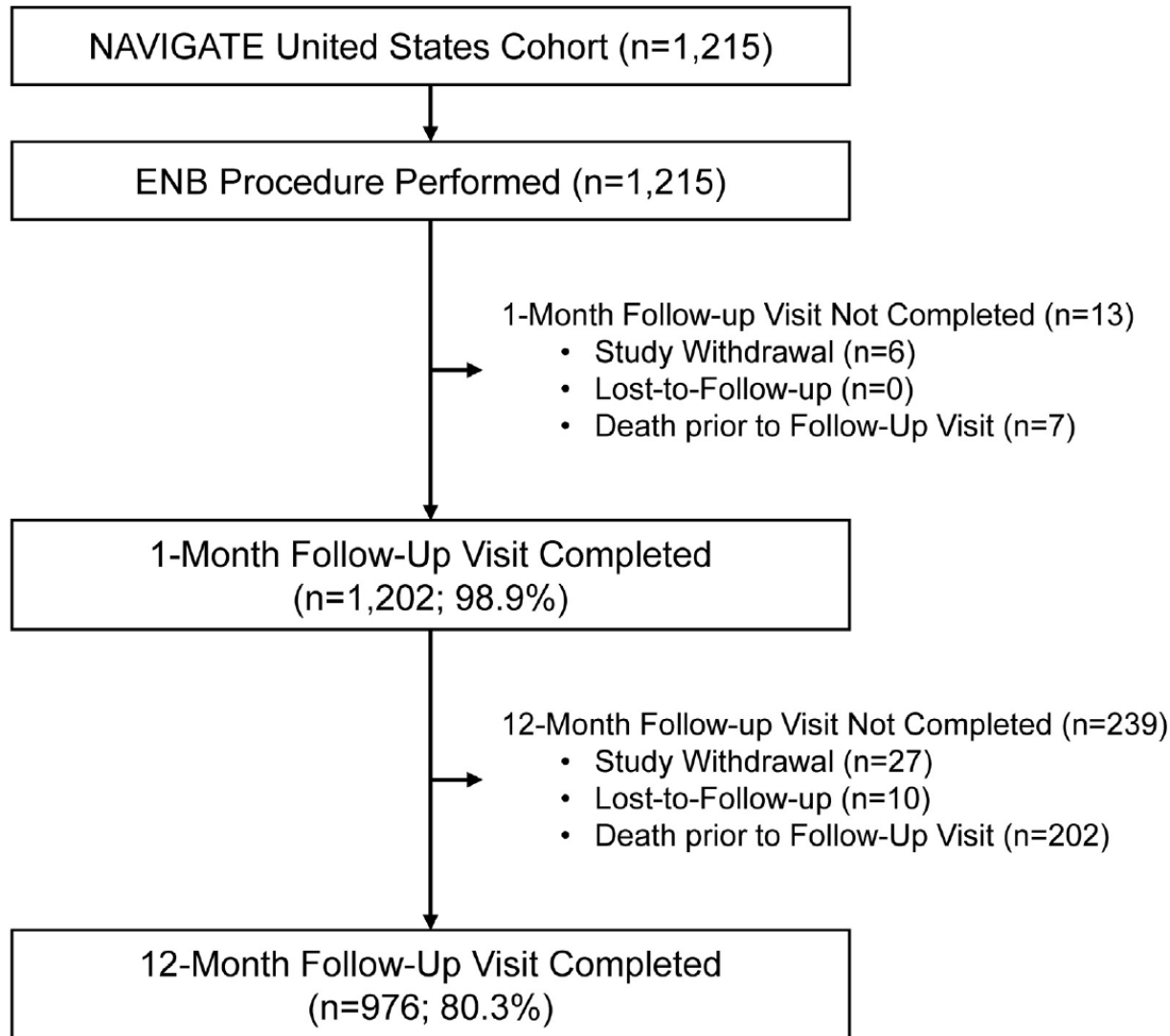
TABLE 3 Procedural details

Variables	Thin bronchoscopy		Ultrathin bronchoscopy		p-value
Bronchus level reached with the bronchoscope					
Median generation of bronchi (range)	4	(2–7)	5	(3–9)	<0.001
Use of a guide sheath					
Yes	36	(41.4)	0	(0)	
No	51	(58.6)	87	(100)	
Location of probe in relation to the lesion					
Within the lesion	2 ^a	(2.3)	50	(57.5)	<0.001
Adjacent to the lesion	37	(42.5)	22	(25.3)	
Invisible with rEBUS	48	(55.2)	15	(17.2)	
Forceps biopsy					
Performed	49	(56.3)	84	(96.6)	<0.001
Median number of biopsies (range)	6	(1–10)	10	(1–12)	<0.001
Not performed	38	(43.7)	3	(3.4)	

TABLE 4 Histopathological diagnostic yield

Variables	Thin bronchoscopy			Ultrathin bronchoscopy			p-value
	n/total	(%)	95% CI	n/total	(%)	95% CI	
Total	11/87	(12.6)	6.5–21.5	36/87	(41.4)	30.9–52.4	<0.001
Lesion size							
≤20 mm	9/65	(13.8)	6.5–24.7	20/65	(30.8)	19.9–43.5	0.019
>20 to ≤30 mm	2/22	(9.1)	1.1–29.2	16/22	(72.7)	49.8–89.3	<0.001
Lesion nature							
Malignant	11/60	(18.3)	9.5–30.4	33/60	(55.0)	41.6–67.9	0.002
Benign	0/26	(0)	0.0–13.2	3/26	(11.5)	2.5–30.2	0.250
Unknown	0/1	(0)		0/1	(0)		
Lobar location							
Upper lobe	5/48	(10.4)	3.5–22.7	20/48	(41.7)	27.6–56.8	0.001
Others	6/39	(15.4)	5.7–30.5	16/39	(41.0)	25.6–57.9	0.013
Lesion location from the hilum							
Intermediate	1/9	(11.1)	0.3–48.3	2/9	(22.2)	2.8–60.0	1.000
Peripheral	10/78	(12.8)	6.3–22.3	34/78	(43.6)	32.4–55.3	<0.001
Bronchus sign							
Present	5/45	(11.1)	3.7–24.1	23/45	(51.1)	35.8–66.3	<0.001
Absent	6/42	(14.3)	5.4–28.5	13/42	(30.9)	17.6–47.1	0.092
Lesion texture on CT							
Solid	9/75	(12)	5.6–21.6	32/75	(42.7)	31.3–54.6	<0.001
Part-solid nodule	2/12	(16.7)	2.1–48.4	4/12	(33.3)	9.9–65.1	0.500
Use of a guide sheath during thin bronchoscopy							
Yes	5/36	(13.9)	4.7–29.5	19/36	(52.8)	35.5–69.6	<0.001
No	6/51	(11.8)	4.4–23.9	17/51	(33.3)	20.8–47.9	0.009

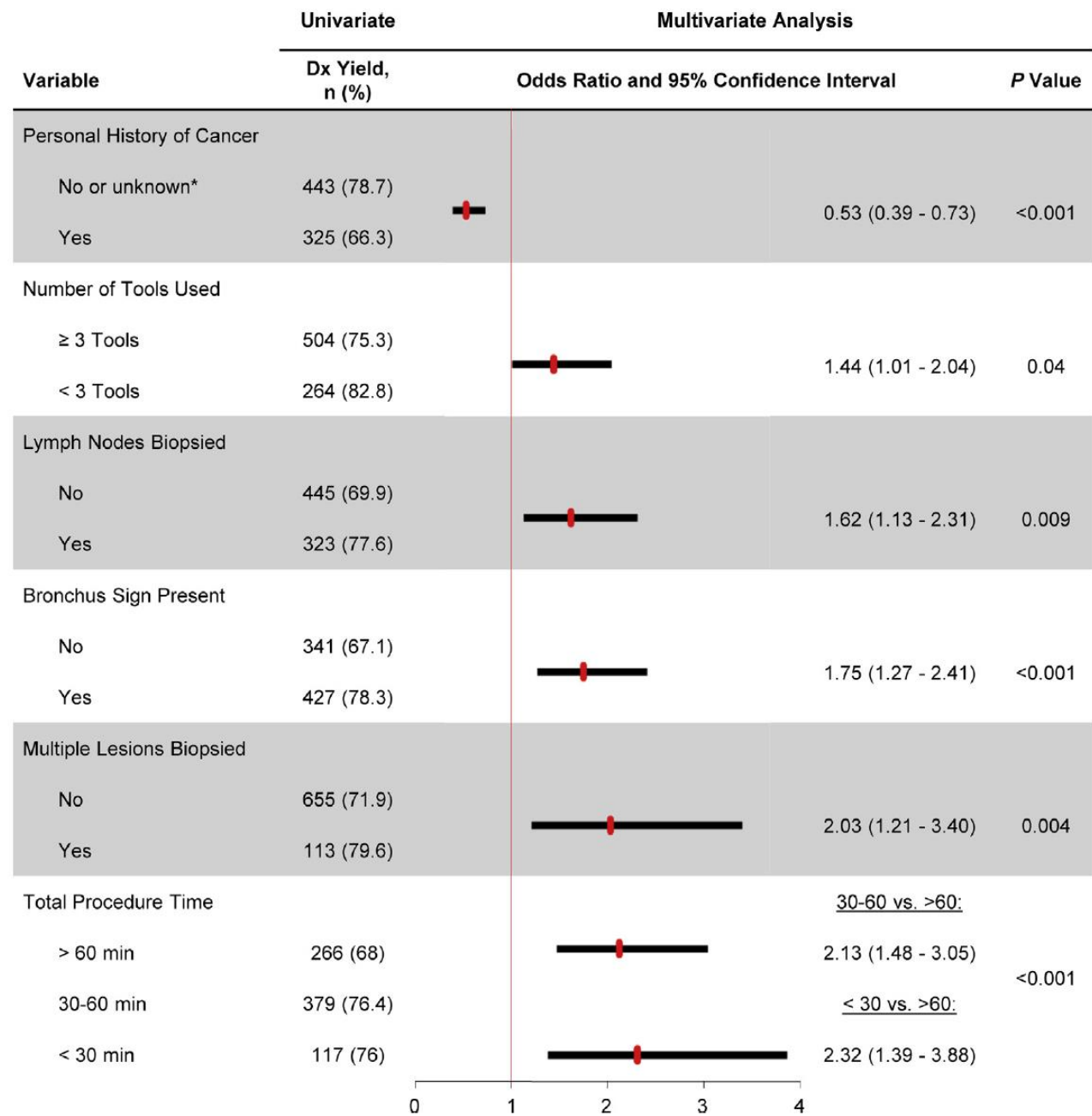
Electromagnetic Navigation Bronchoscopy (ENB)

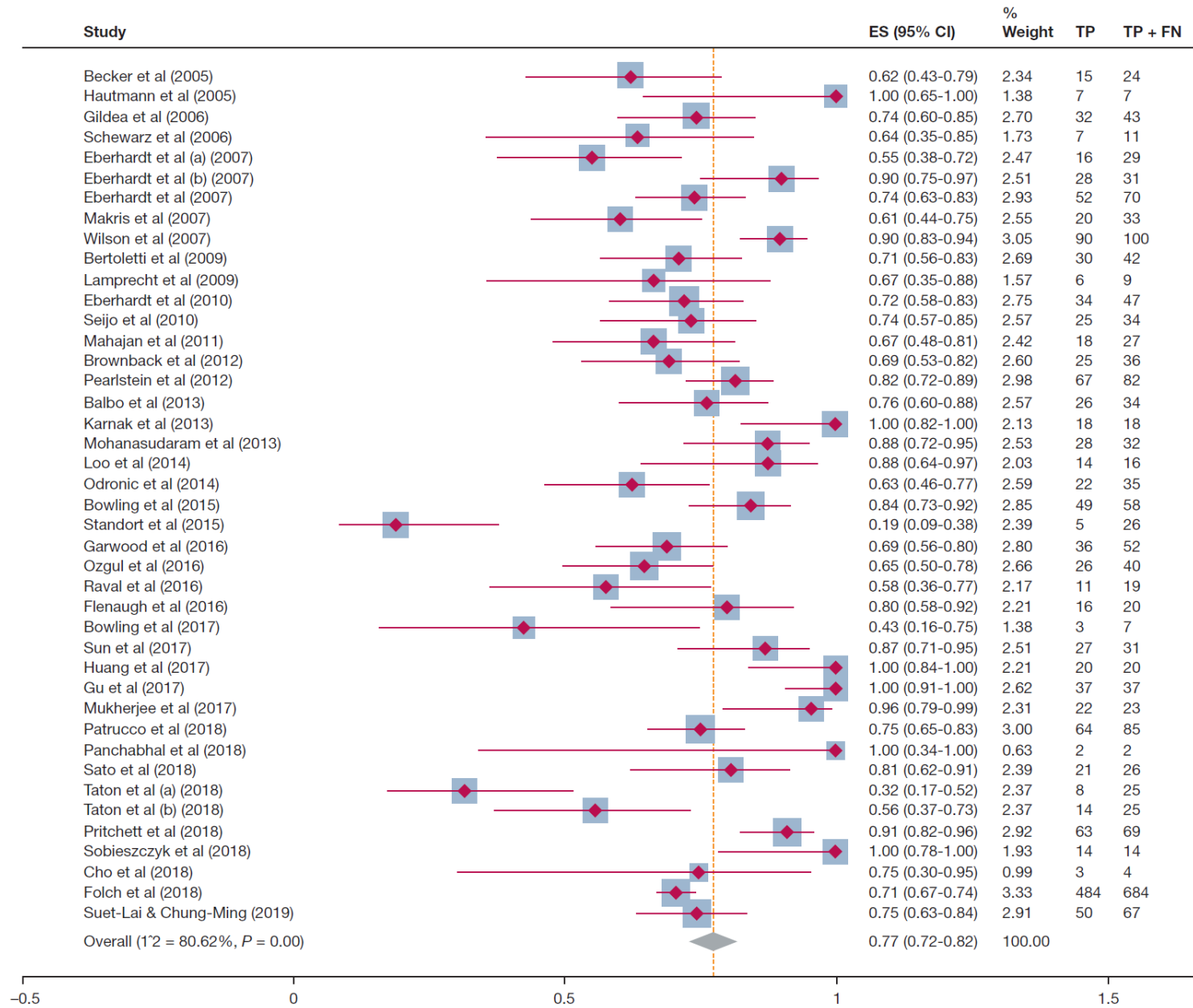


- Lesion size (median): 20 mm
- Diagnostic yield: 73%
- Pneumothorax: 5% (requiring admission or chest tube placement): 2.9%

Lesion properties	N = 1344 lesions in 1157 subjects undergoing lung lesion biopsy
Average lesion size < 20 mm	49.1% (660/1343)
Upper lobe lesion location	58.0% (780/1344)
Lesion in peripheral third of the lung	66.9% (899/1344)
Median distance from lesion to pleura (mm)	9.0 (1-20)
Ground glass lesions (Suzuki class 1 or 2)	6.3% (84/1338)
Spiculated lesion border	59.9% (804/1342)
Bronchus sign present on CT	48.5% (652/1344)
Multiple lesions sampled	13.7% (158/1157)
Pre-test probability of malignancy ≥65% ^b	59.0% (591/1002) ^c

Procedure characteristics	N = 1215 ENB procedures in 1215 subjects
General anesthesia	81.4% (989/1215)
Radial EBUS used during ENB	57.4% (698/1215)
Cone-beam CT used during ENB	4.9% (60/1215)
Fluoroscopy used during ENB	91.0% (1223/1344 lesions)
ROSE used	68.5% (748/1092 subjects)
Median total procedure time (bronchoscope in/out)	52.0 min (35-71)
Median ENB-specific procedure time (LG/EWC in/out)	25.0 min (14-40)
≥3 Biopsy tools used to sample lung lesions	72.7% (794/1092)
Operator experience prior to NAVIGATE	
0-4 ENB cases per month	7.9% (96/1215)
5-10 ENB cases per month	46.6% (566/1215)
> 10 ENB cases per month	45.5% (553/1215)
ENB-guided fiducial placement conducted	21.2% (258/1215)

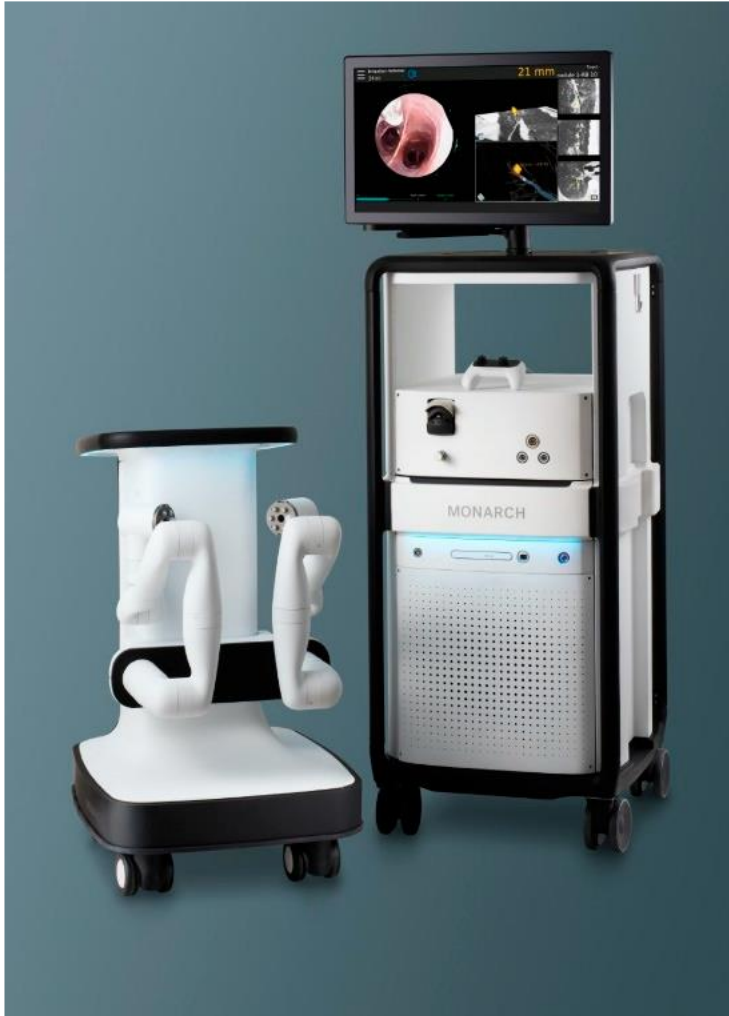



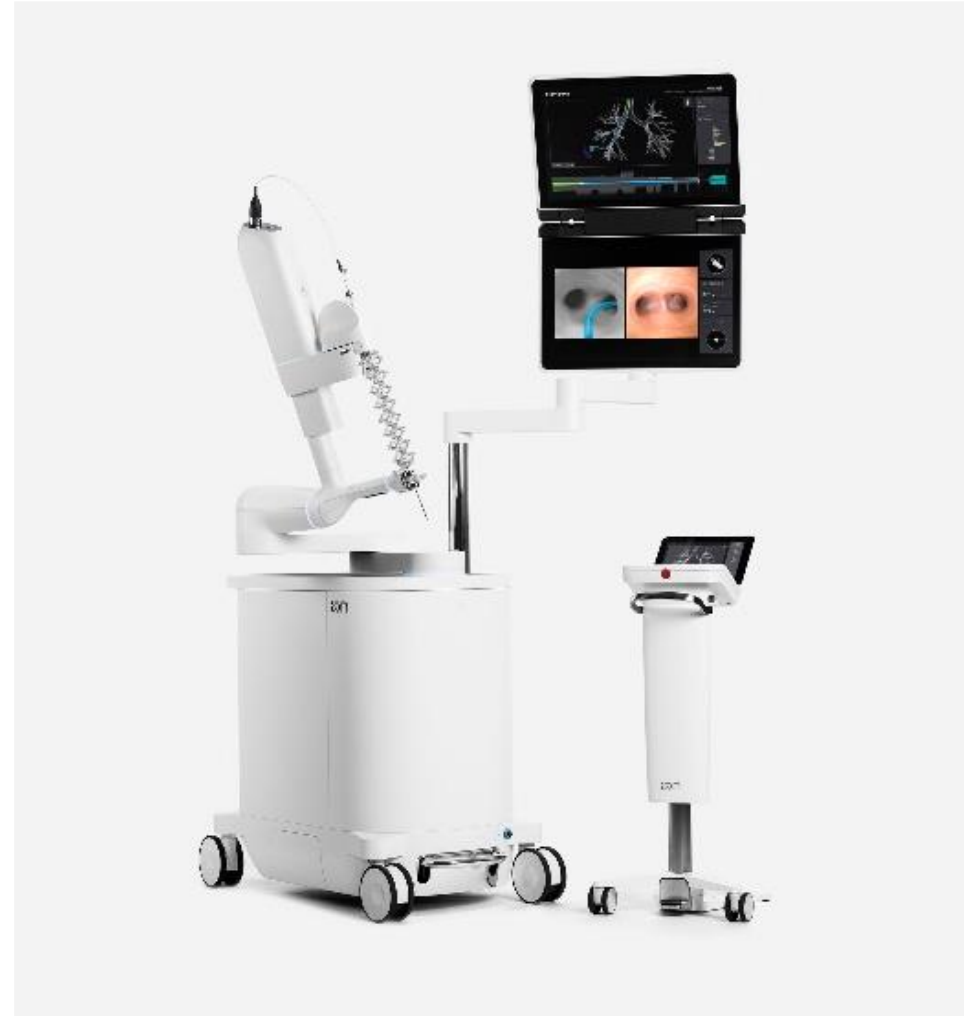- Meta-analysis including 40 studies (3,342 participants)
- superDimension system: 38 studies (95%)
- Sensitivity: 77%
- Pneumothorax: 2%

Robotic-assisted Bronchoscopy (RAB)

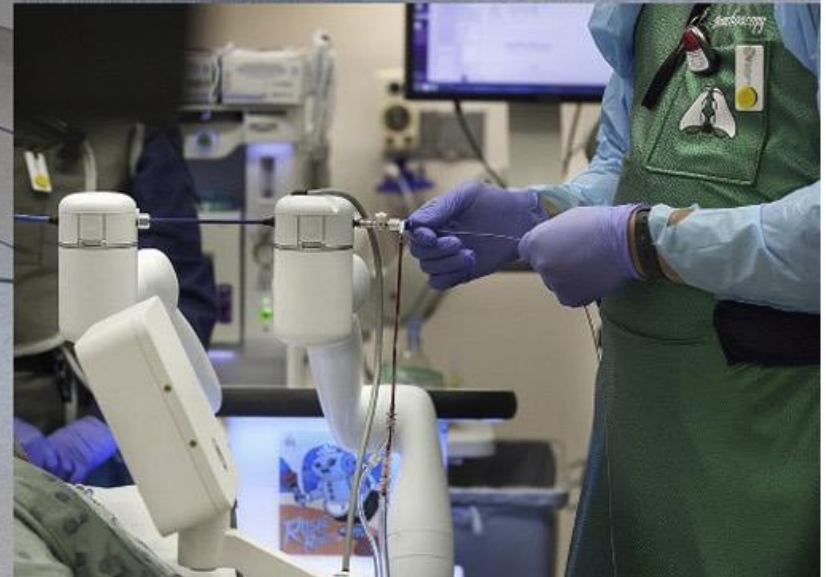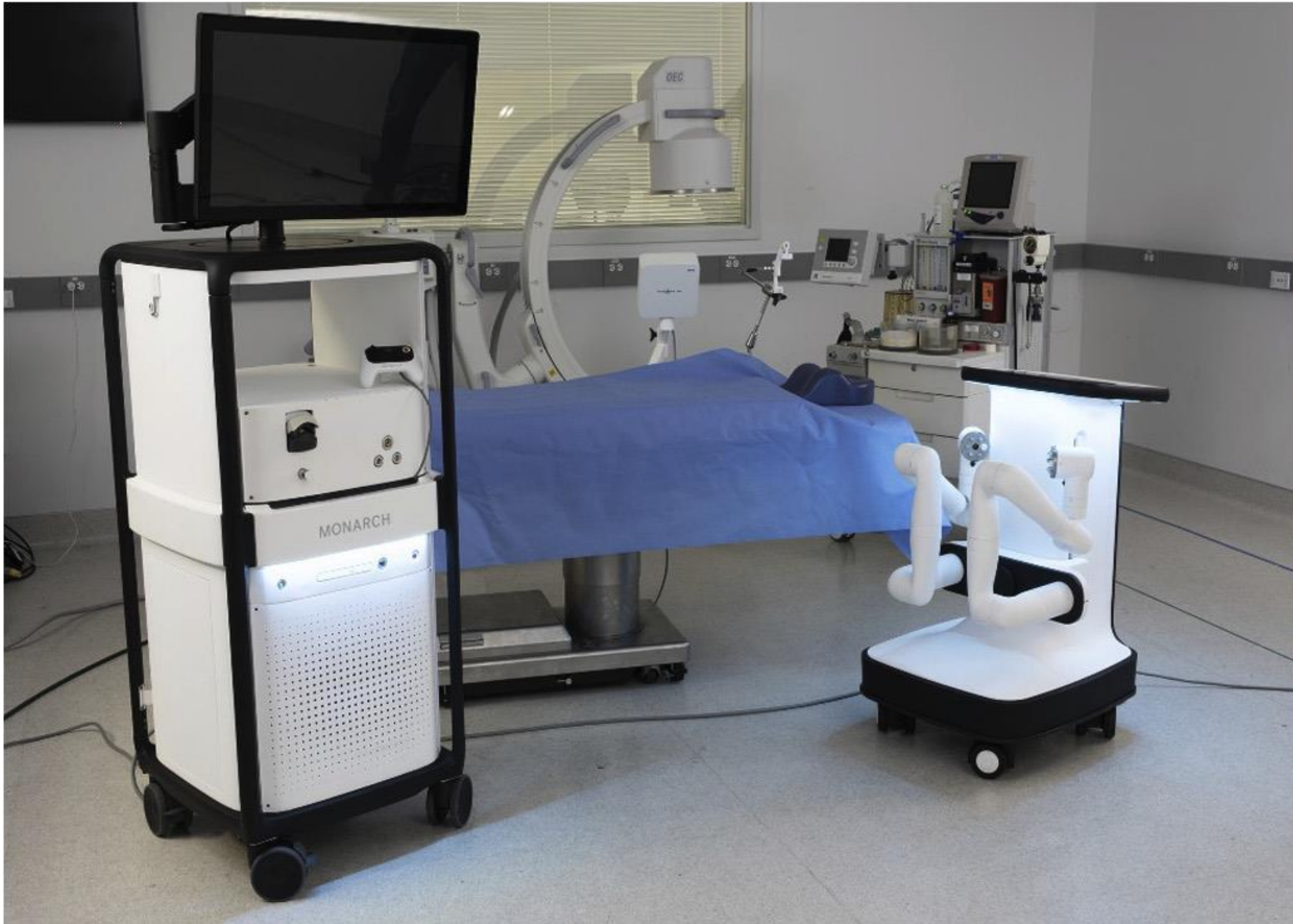Robotic-assisted Bronchoscopy (RAB)



Monarch® (Auris Health)



Ion™ (Intuitive Surgical)



Chen, Alexander C et al. "Robotic Bronchoscopy for Peripheral Pulmonary Lesions: A Multicenter Pilot and Feasibility Study (BENEFIT)." *Chest* vol. 159,2 (2021): 845-852.

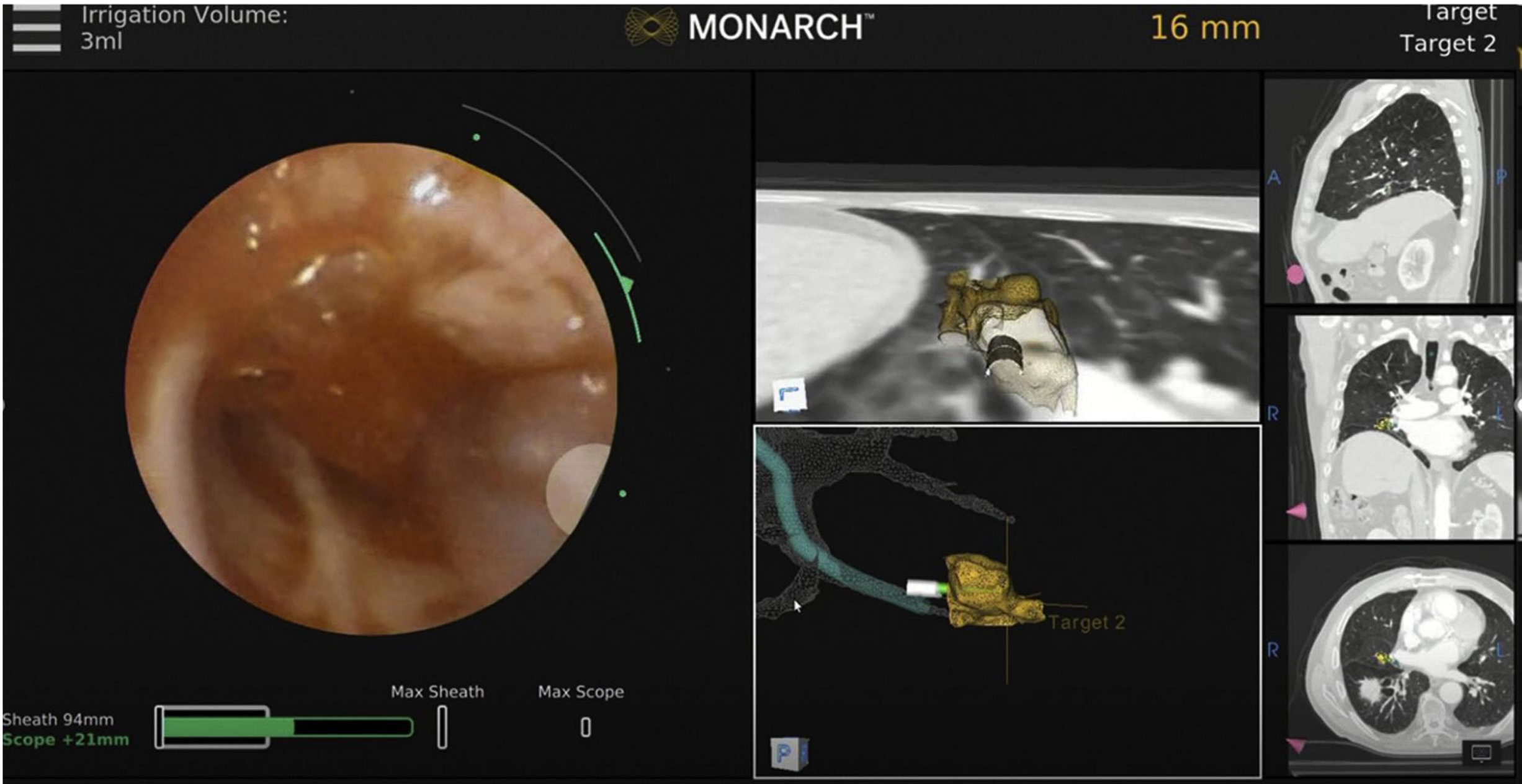
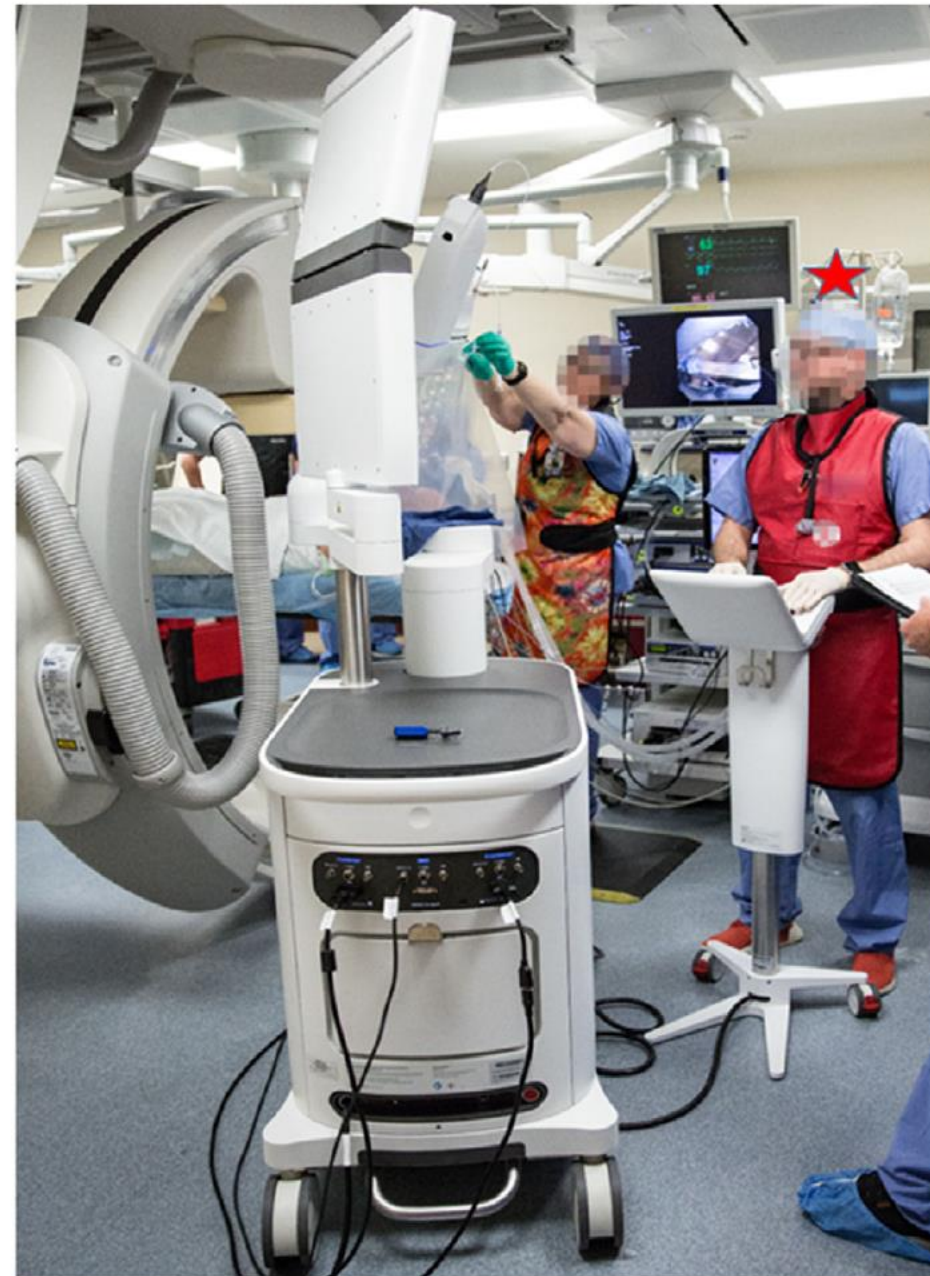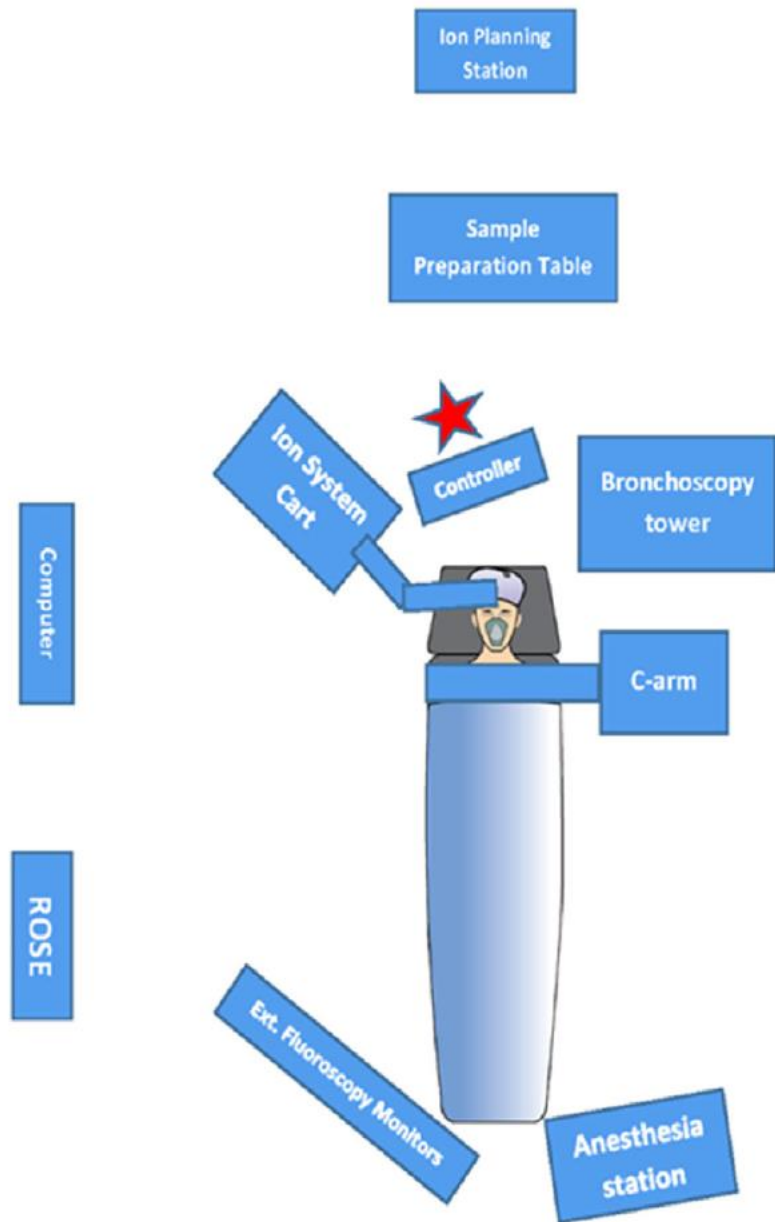



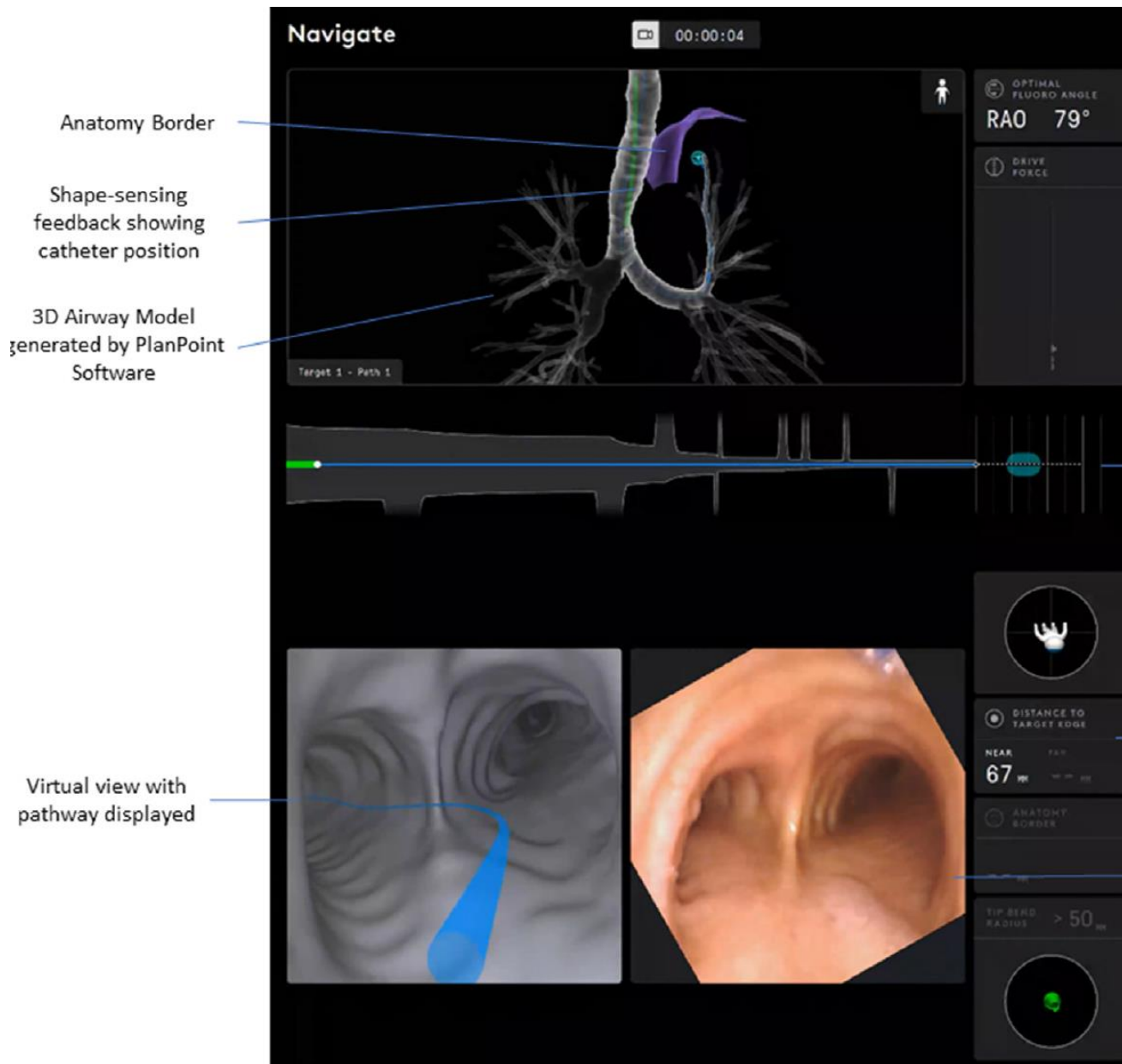
TABLE 1] Baseline Characteristics

Characteristic	Value
Patient	
Total, ^a No.	54
Female, No. (%)	29 (53.7)
Age, mean (SD), y	67.1 (8.5)
BMI, mean (SD), kg/m ²	28.8 (6.3)
Lesion	
Nodule size, mean (SD), ^b mm	23.2 (10.8)
≤20	23 (42.6)
21-30	19 (35.2)
>30	12 (22.2)
Bronchus sign, No. (%)	32 (59.3)
Nodule location, No. (%)	
Right upper lobe	19 (35.2)
Left upper lobe	12 (22.2)
Right middle lobe	6 (11.1)
Right lower lobe	8 (14.8)
Left lower lobe	9 (16.7)

TABLE 3] Results

Result	No./No. (%)	P Value
Lesion localization^a		
Overall	51/53 (96.2)	
Concentric	31/51 (60.8)	
Eccentric	20/51 (39.2)	
Diagnostic yield		
Overall radial endobronchial ultrasound view	40/54 (74.1)	
Concentric	25/31 (80.6)	.502
Eccentric	14/20 (70.0)	
Bronchus sign		
Present	24/32 (75.0)	>.999
Absent	16/22 (72.7)	
Lesion size, mm		
≤30	30/42 (71.4)	.710
>31	10/12 (83.3)	





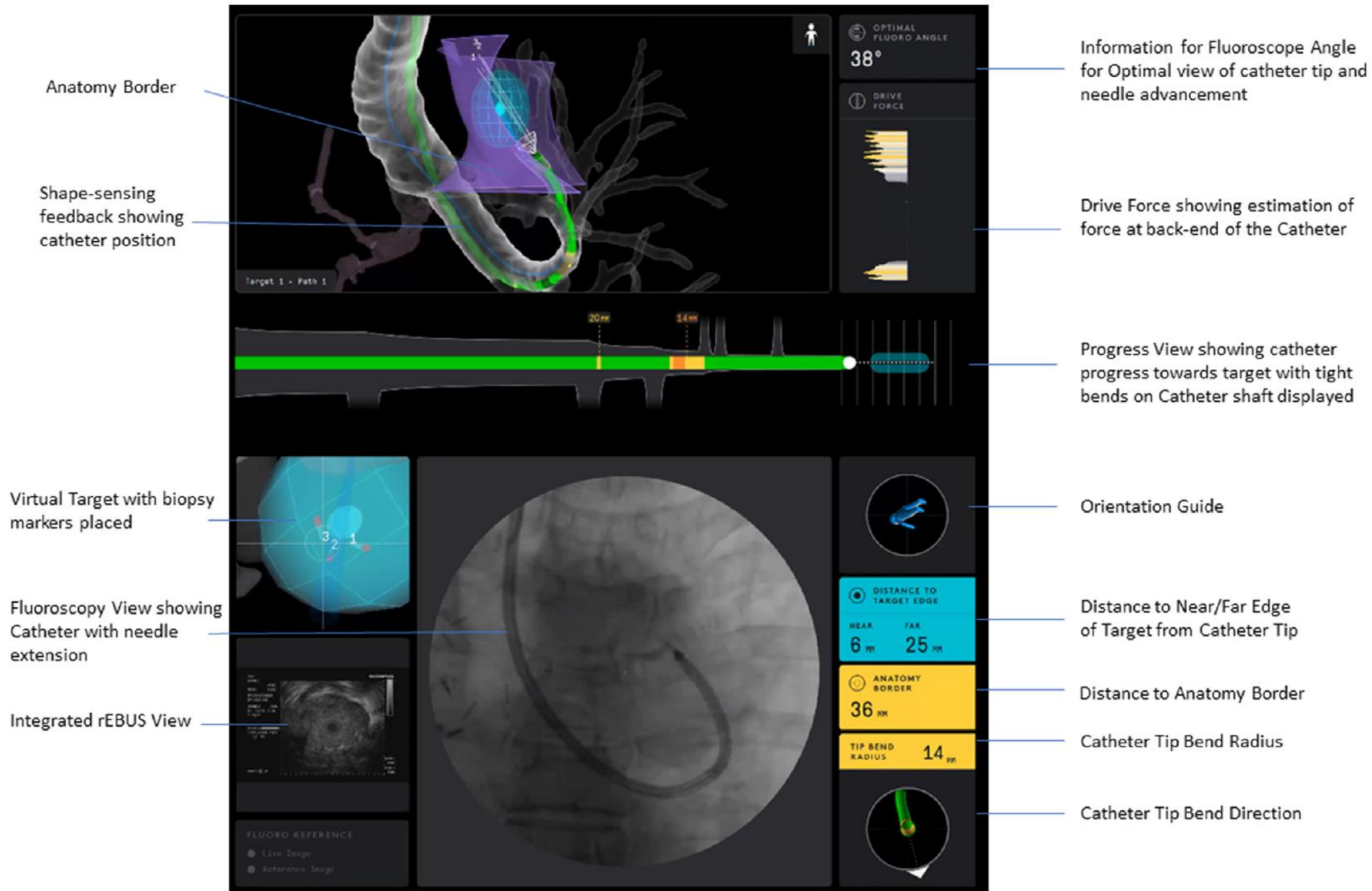
View showing catheter progress towards target

Distance to Near/Far Edge of Target from catheter Tip


Live real-time airway view from Ion Peripheral Vision Probe

Simoff, Michael J et al. "Shape-sensing robotic-assisted bronchoscopy for pulmonary nodules: initial multicenter experience using the Ion™ Endoluminal System." *BMC pulmonary medicine* vol. 21,1 322. 16 Oct. 2021

Reisenauer, Janani et al. "Ion: Technology and Techniques for Shape-sensing Robotic-assisted Bronchoscopy." *The Annals of thoracic surgery* vol. 113,1 (2022): 308-315.



Shape-Sensing Robotic-Assisted Bronchoscopy with Concurrent use of Radial Endobronchial Ultrasound and Cone Beam Computed Tomography in the Evaluation of Pulmonary Lesions

Kim Styrvoky¹  · Audra Schwalk¹ · David Pham¹ · Hsienchang T. Chiu¹ · Anastasiia Rudkovskaia¹ · Kristine Madsen² · Stephen Carrio³ · Elizabeth M. Kurian⁴ · Luis De Las Casas⁴ · Muhanned Abu-Hijleh¹

Accepted: 7 November 2022 / Published online: 11 November 2022

© The Author(s), under exclusive licence to Springer Science+Business Media, LLC, part of Springer Nature 2022

Abstract

Purpose Lung nodules are a common radiographic finding. Non-surgical biopsy is recommended in patients with moderate or high pretest probability for malignancy. Shape-sensing robotic-assisted bronchoscopy (ssRAB) combined with radial endobronchial ultrasound (r-EBUS) and cone beam computed tomography (CBCT) is a new approach to sample pulmonary lesions. Limited data are available regarding the diagnostic accuracy of combined ssRAB with r-EBUS and CBCT.

Methods We conducted a retrospective analysis of the first 200 biopsy procedures of 209 lung lesions using ssRAB, r-EBUS, and CBCT at UT Southwestern Medical Center in Dallas, Texas. Outcomes were based on pathology interpretations of samples taken during ssRAB, clinical and radiographic follow-up, and/or additional sampling.

Results The mean largest lesion dimension was 22.6 ± 13.3 mm with a median of 19 mm (range 7 to 73 mm). The prevalence of malignancy in our data was 64.1%. The diagnostic accuracy of ssRAB combined with advanced imaging was 91.4% (CI 86.7–94.8%). Sensitivity was 87.3% (CI 80.5–92.4%) with a specificity of 98.7% (CI 92.8–100%). The negative and positive predictive values were 81.3% and 99.2%. The rate of non-diagnostic sampling was 11% (23/209 samples). The only complication was pneumothorax in 1% (2/200 procedures), with 0.5% requiring a chest tube.

Conclusion Our results of the combined use of ssRAB with r-EBUS and CBCT to sample pulmonary lesions suggest a high diagnostic accuracy for malignant lesions with reasonably high sensitivity and negative predictive values. The procedure is safe with a low rate of complications.

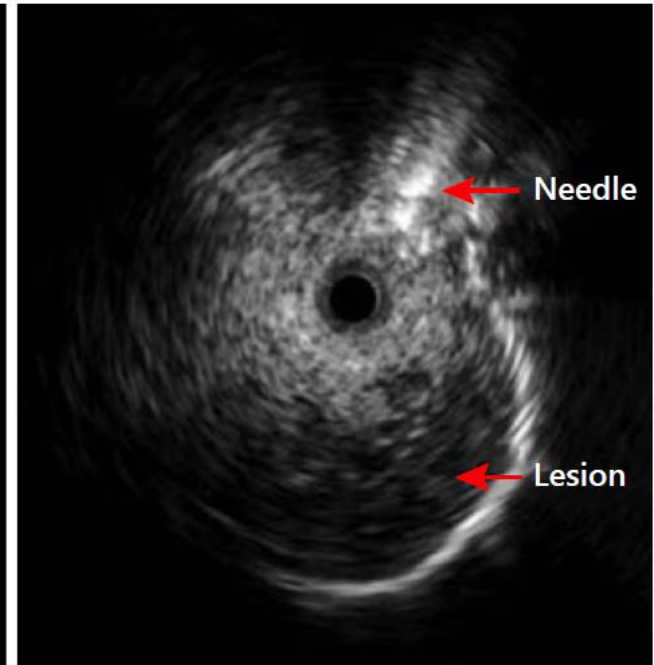
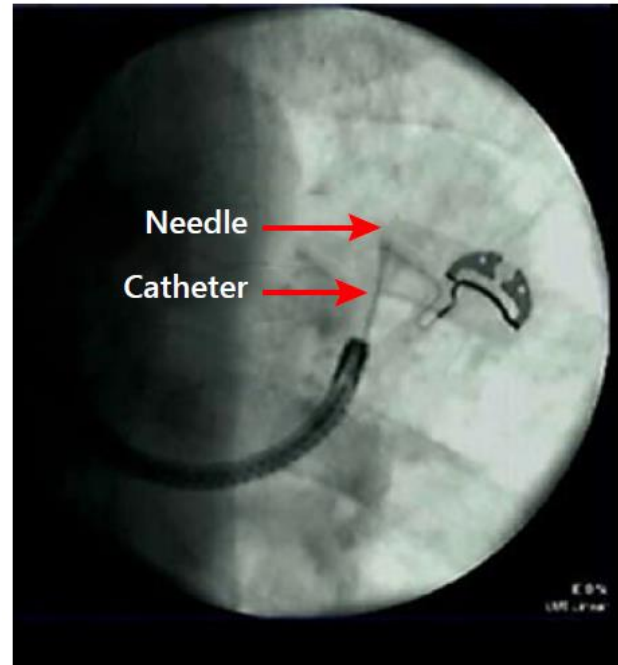

Table 2 Nodule characteristics (n = 67 nodules)

Variable	Outcome
Size, median mm (IQR)	
Axial	17.5 (12.0, 24.0)
Coronal	16.0 (11.8, 21.0)
Sagittal	16.2 (12.0, 22.0)
Largest cardinal diameter	20.0 (14.0, 27.0)
Lobe location, n (%)	
LLL	8 (11.9)
LUL	18 (26.9)
RLL	21 (31.3)
RML	3 (4.5)
RUL	17 (25.4)
Distance from pleura or fissure, median mm (IQR)	4.0 (0.0, 15.0)
Bronchial generation count, median n (IQR)	7.0 (6.0, 8.0)
Location, n (%) ^a	
Endoluminal	10 (15.4)
Extraluminal	55 (84.6)
Nodule type, n (%)	
Solid	55 (82.1)
Cavitary	4
Semi-solid	12 (17.9)
CT Bronchus sign present, n (%)	25 (37.3)
rEBUS attempted, n (%)	66 (98.5)
rEBUS visualization, n (%) ^b	59 (89.4)
Concentric, initially	23 (40)
Eccentric converted to concentric	8 (13.6)
Eccentric	28 (47.5)

Table 4 Biopsy outcomes

Variable	Outcome
Biopsy completion, n (%) ^a	
Subject level (n = 60)	58 (96.7) 95% CI: 92.1%, 100% ^b
Nodule level (n = 67)	65 (97.0) 95% CI: 92.9%, 100% ^b
Closest distance to nodule, median mm (IQR) ^c	7.0 (2.0, 12.0)
Serious adverse events, n (%)	0 (0)
Pneumothorax (with or without chest tube)	0 (0)
Airway bleeding (with or without intervention)	0 (0)
Other	0 (0)
Complications, n (%)	2 (3.3)
Cardiac arrhythmia, CTCAE grade 2 (intra-procedure)	1 (1.7)
Pneumonia, CTCAE grade 2 (post-procedure)	1 (1.7)

**Real-Time (Radial) EBUS-Guided
TBNA (RT-EBUS-TBNA)**



Yarmus, Lonny B et al. "First-in-Human Use of a Hybrid Real-Time Ultrasound-Guided Fine-Needle Acquisition System for Peripheral Pulmonary Lesions: A Multicenter Pilot Study." *Respiration; international review of thoracic diseases* vol. 98,6 (2019): 527-533.

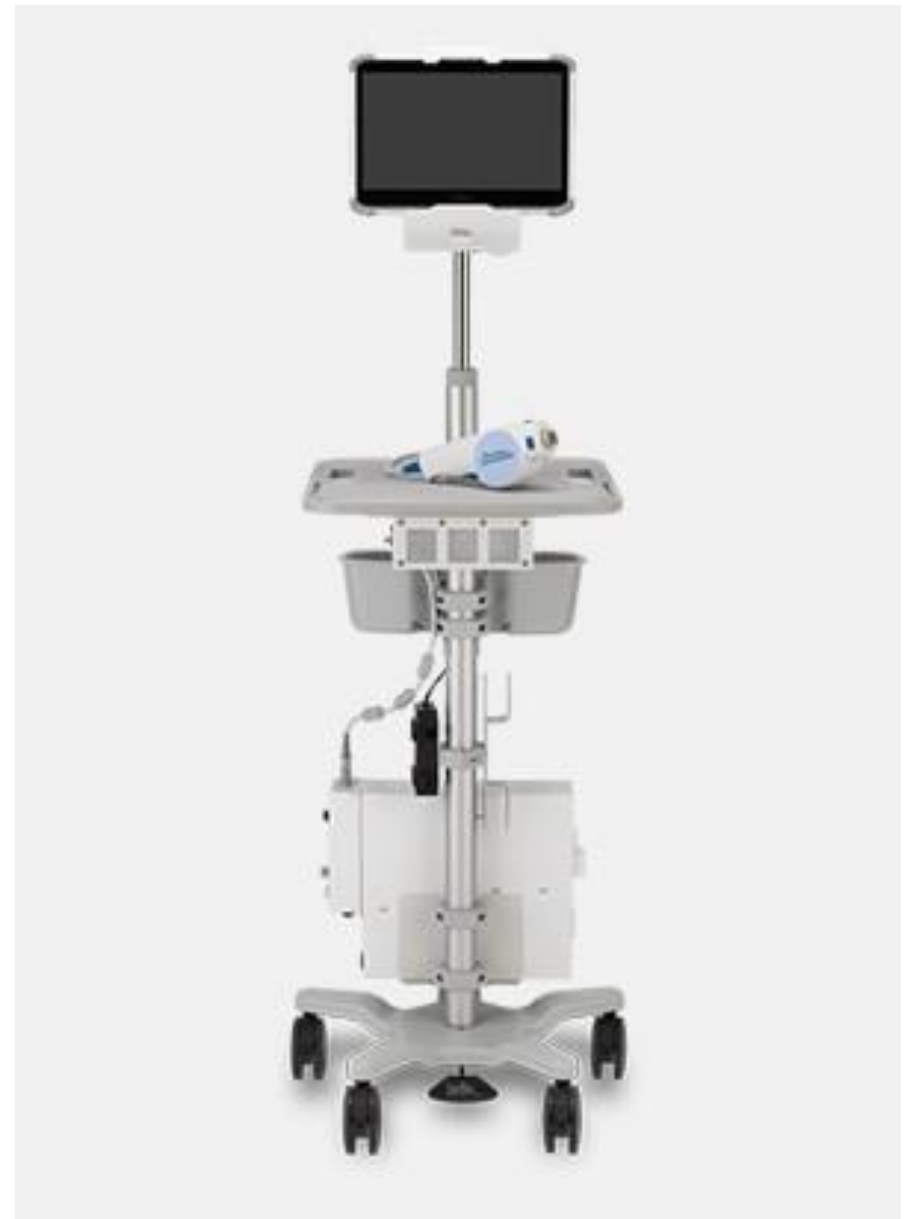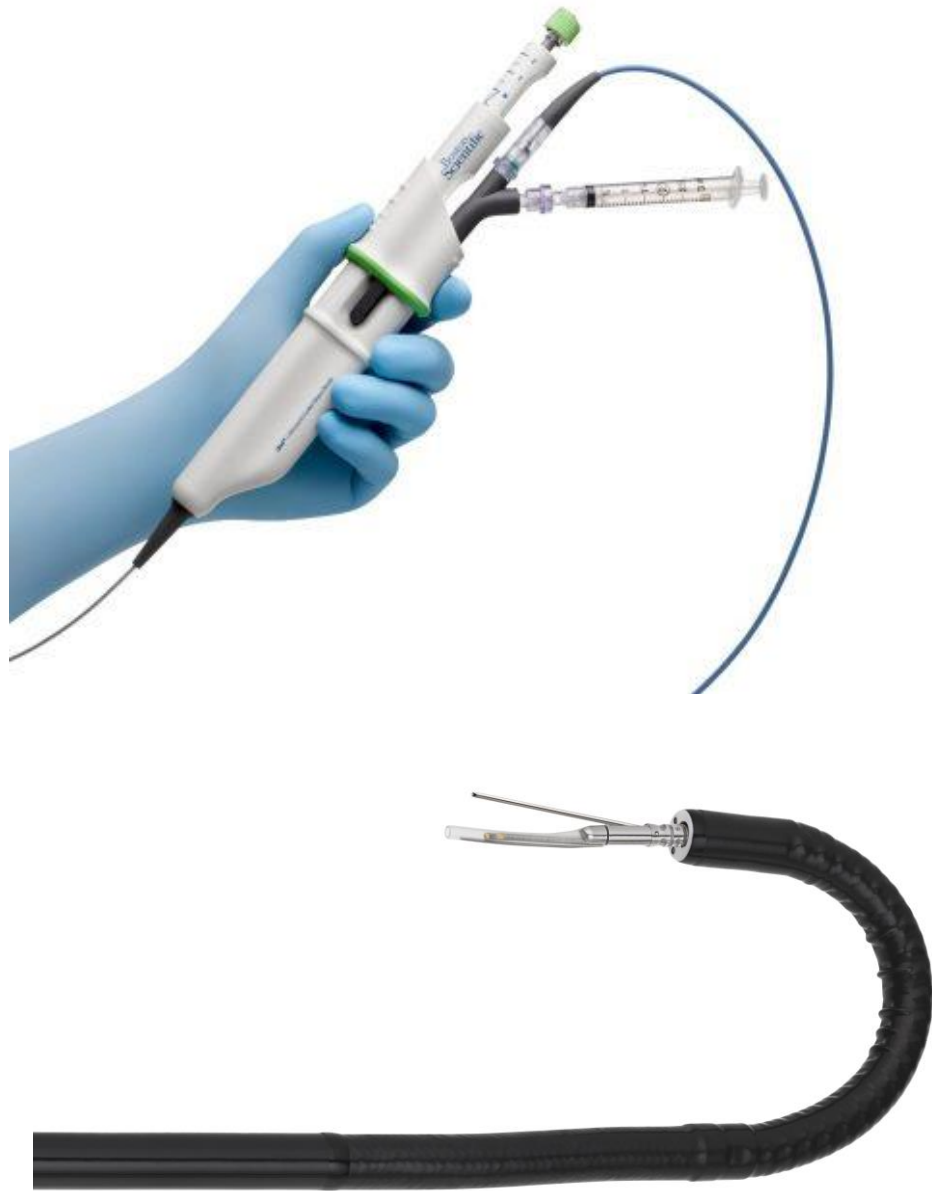Table 2. Lesion characteristics in 23 patients

Location	
Right upper lobe	45.8%
Right middle lobe	8.3%
Right lower lobe	8.3%
Left upper lobe	16.7%
Left lower lobe	20.8%
Density	
Solid	95.8%
Ground-glass component	4.2%
Mean diameter, cm (\pm SD)	3.6 \pm 1.3
Positive bronchus sign	95.8%

- Diagnostic yield (RT-EBUS-TBNA):
70% (16/23)
- If, no cellular material (i.e., blood only)
using ROSE \rightarrow CR-EBUS with
forceps, TBNA, brush

Table 3. Diagnostic yield of RT-EBUS-TBNA and CR-EBUS

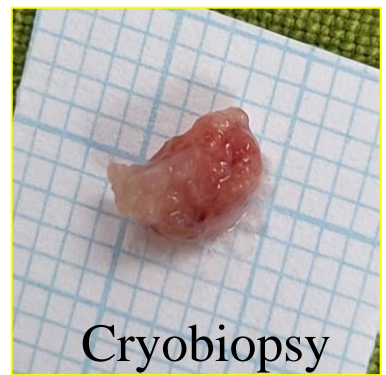
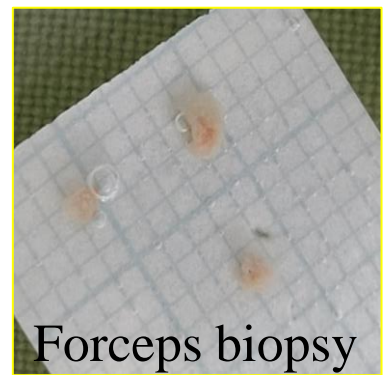
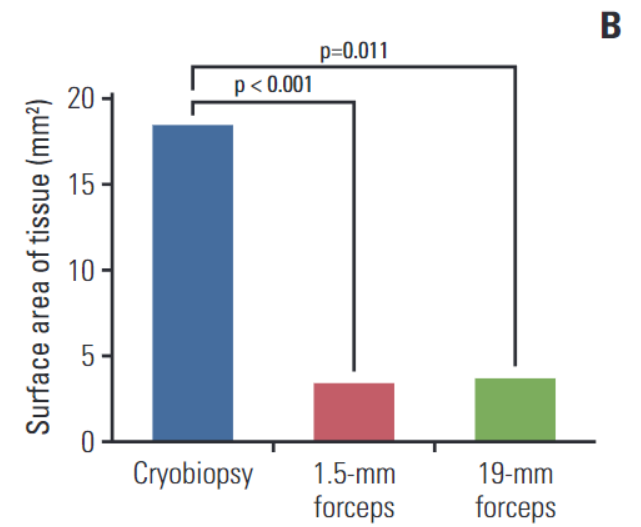
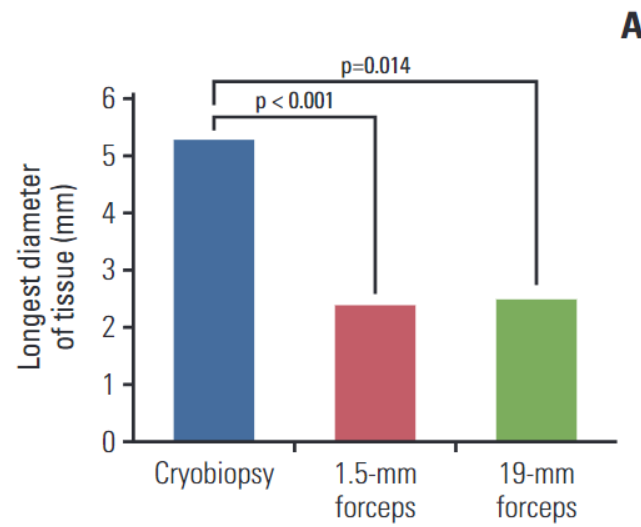
Case No.	RT-EBUS-TBNA	CR-EBUS
1	adenocarcinoma	adenocarcinoma
2	adenocarcinoma	adenocarcinoma
3	adenocarcinoma	adenocarcinoma
4	adenocarcinoma	not performed
5	adenocarcinoma	adenocarcinoma
6	adenocarcinoma	adenocarcinoma
7	squamous-cell carcinoma	squamous-cell carcinoma
8	non-small-cell carcinoma	non-small-cell carcinoma
9	non-small-cell carcinoma	non-small-cell carcinoma
10	non-small-cell carcinoma	not performed
11	epithelioid neoplasm	epithelioid neoplasm
12	melanoma	not performed
13	acute inflammation ^a	acute inflammation ^a
14	acute inflammation ^a	acute inflammation ^a
15	acute inflammation ^a	acute inflammation ^a
16	acute inflammation ^a	acute inflammation ^a
17	nondiagnostic	nondiagnostic
18	nondiagnostic	nondiagnostic
19	nondiagnostic	nondiagnostic
20	nondiagnostic	nondiagnostic
21	nondiagnostic	nondiagnostic
22	nondiagnostic	typical carcinoid
23	nondiagnostic	squamous-cell carcinoma

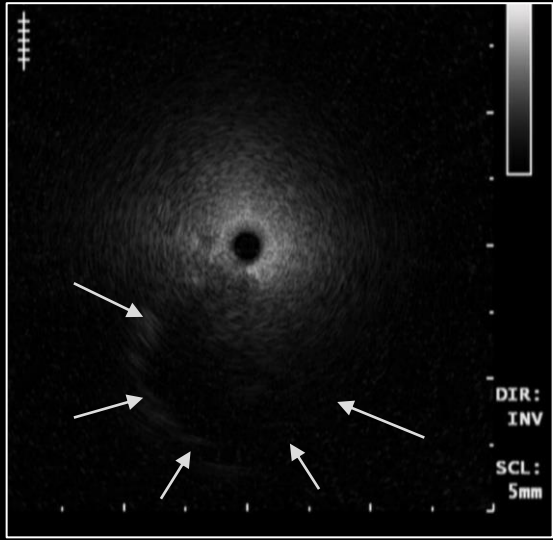


Transbronchial lung cryobiopsy (TBLC)

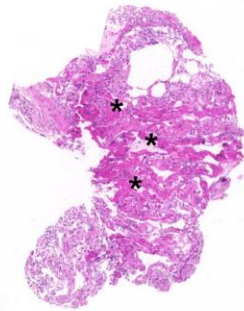
Transbronchial lung cryobiopsy (TBLC)

- Forceps TBLB vs. Transbronchial lung cryobiopsy (TBLC)
 - Larger tissues / Less crushing artifact
 - Additional diagnostic yield for peripheral pulmonary lesions (PPLs)
- 1.1 mm cryoprobe
 - Excellent flexibility
 - With 1.95 mm guide sheath (GS) in 2.0 mm working channel



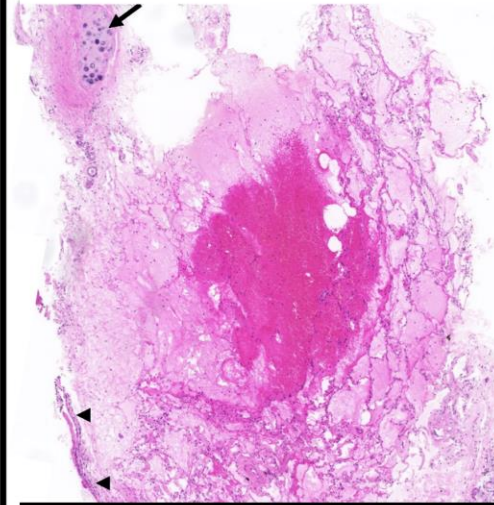


1st specimen (forceps biopsy)

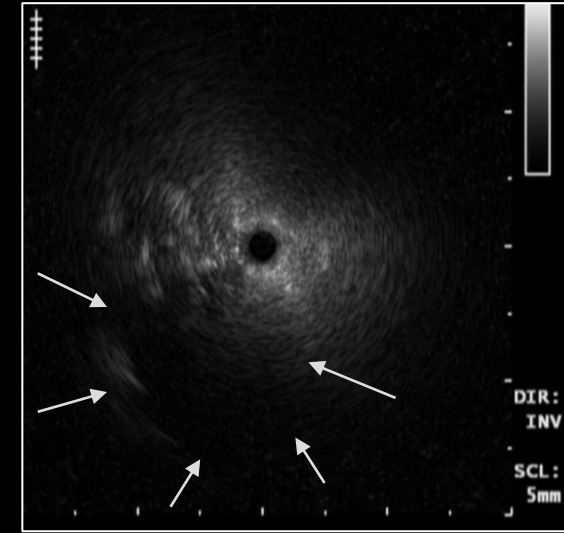


Normal lung parenchyma

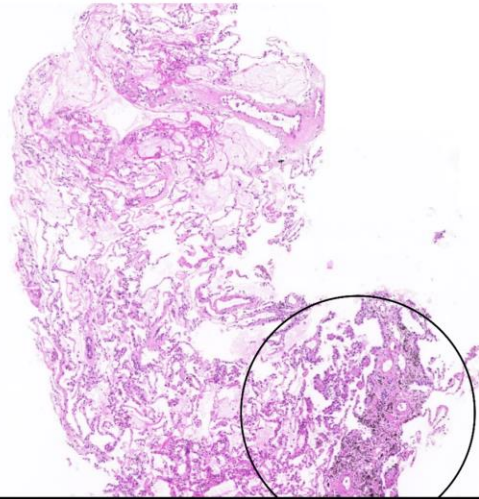
2nd specimen (cryobiopsy)



Bronchial wall & cartilage

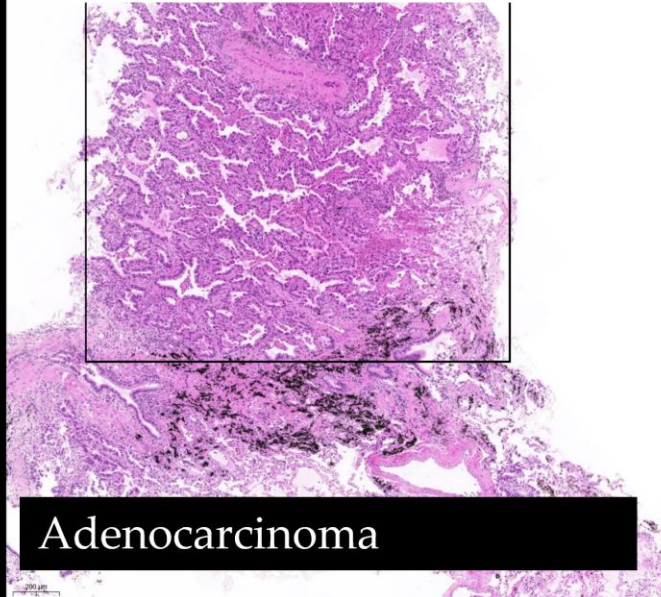


3rd specimen (cryobiopsy)

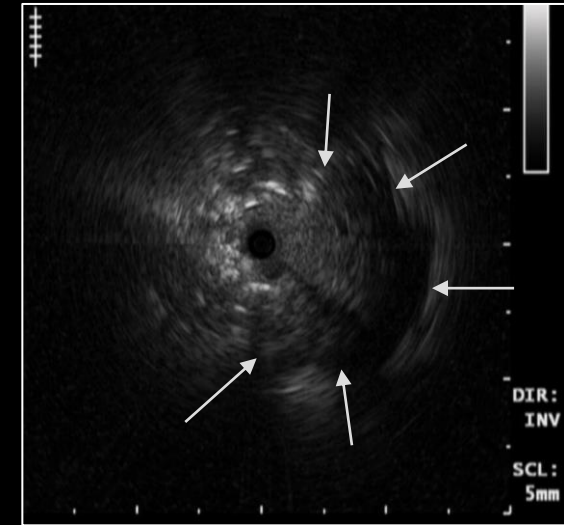


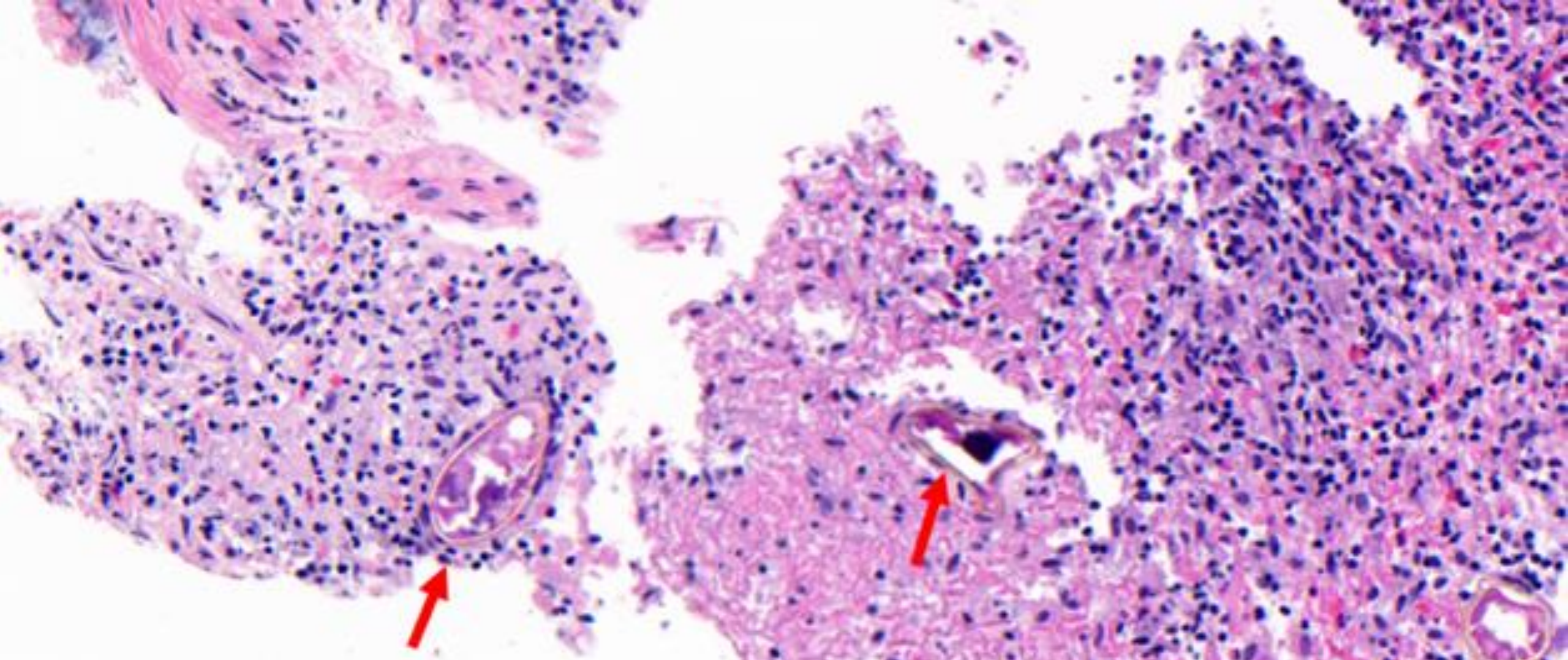
Atypical cells

4th specimen (cryobiopsy)



Adenocarcinoma





Pathologic findings of transbronchial lung cryobiopsy revealed eggs of *Paragonimus westermani* (red arrows) with infiltration of inflammatory cells, especially eosinophils (hematoxylin and eosin stain, $\times 200$). CT, computed tomography.

Diagnostic yield of TBLC for PPLs

- Diagnostic yield (2021~2023): 89.9-91.5%
- Additional diagnostic yield (DY)
 - Matsumoto Y, et al. (2021) (n = 257)
 - 8.6% (81.3% → 89.9%)
 - ‘Adjacent to’ / ‘Within’: 14.9% / 3% (p = 0.001)
 - Bronchus sign (-) / (+): 15.4% / 6.3% (p = 0.011)
 - Nakai T , et al. (2022) (n = 139)
 - 76.3% (FB) / 81.3% (TBLC) / 89.9% (Total)
 - ‘Adjacent to’: conventional biopsy 67.4% vs. cryobiopsy 81.9% (p = 0.019)
 - ‘Within’: FB 94.2% (49/52) vs. cryobiopsy 84.6% (44/52) (p = 0.18)
 - Chaeuk Chung, et al. (2023) (n = 199)
 - 65.3% (FB) / 84.4% (TBLC) / 91.5% (Total)
 - ‘Adjacent to’ / ‘Within’: 29.9% / 25.2% (p = 0.003)

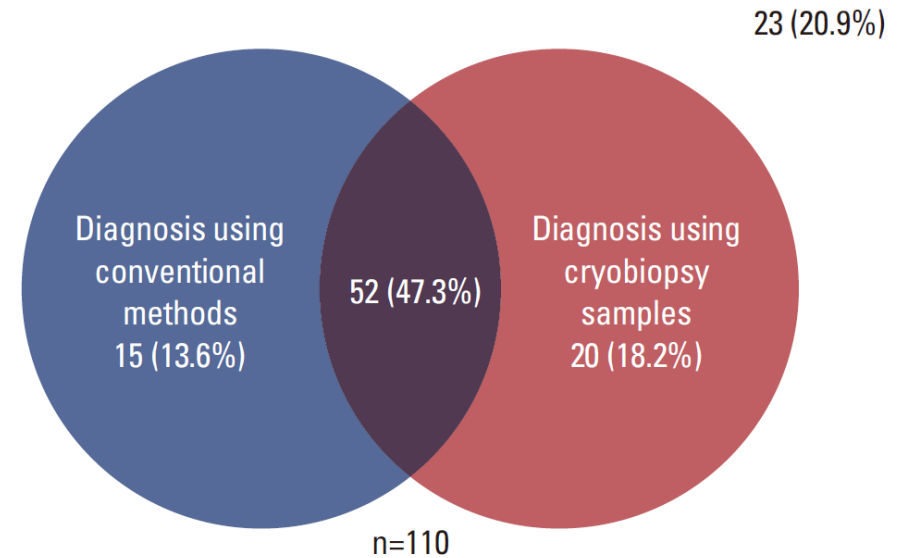


Fig. 2. Venn diagram of results of the bronchoscopy procedure.

Ultrathin bronchoscopic cryobiopsy of peripheral pulmonary lesions

Masahide Oki¹ | Hideo Saka^{1,2} | Yoshihito Kogure¹ | Hideyuki Niwa¹ |
Arisa Yamada¹ | Atsushi Torii¹ | Chiyo Kitagawa¹

Methods: Patients with peripheral pulmonary lesions ≤ 30 mm in diameter were prospectively enrolled in the study. All patients underwent forceps biopsy followed by cryobiopsy using a 3.0-mm ultrathin bronchoscope under radial probe endobronchial ultrasound guidance, virtual bronchoscopic navigation and fluoroscopic guidance. The primary endpoint was the feasibility of cryobiopsy.

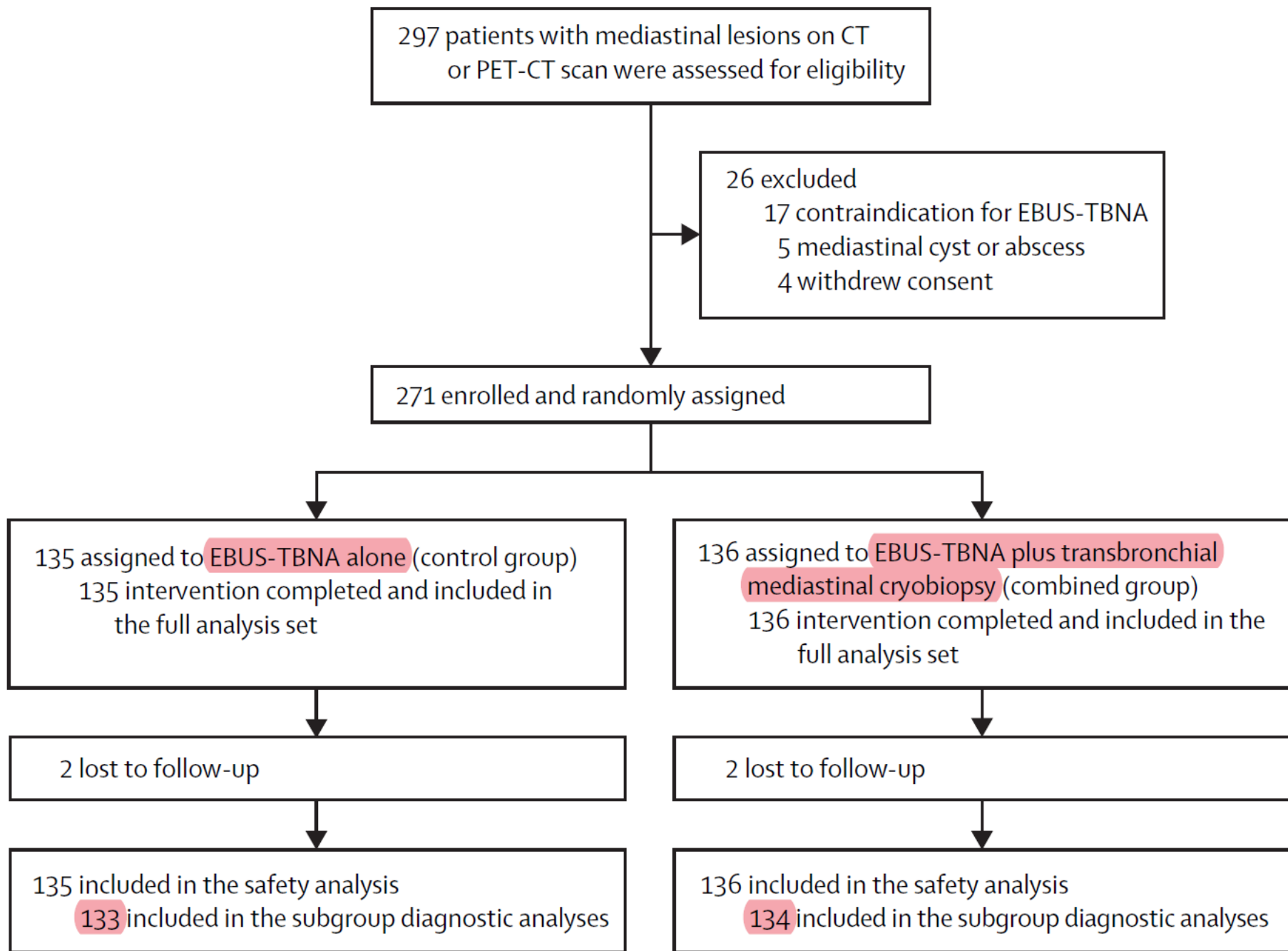
Results: In total, 50 patients with peripheral pulmonary lesions were enrolled in the study; the median longest diameter on computed tomography was 17.9 mm. Cryobiopsy was performed successfully in 49 patients (98%). Forceps biopsy, cryobiopsy and the combination of these two methods provided a specific diagnosis in 54% (27/50), 62% (31/50) and 74% (37/50) of patients, respectively. The median size of specimens obtained via cryobiopsy was significantly larger than the median size obtained via forceps biopsy (7.0 vs. 1.3 mm², respectively, $p < 0.001$). Mild bleeding during cryobiopsy occurred in 47 patients (94%). No moderate/severe bleeding or pneumothorax occurred.

Mediastinal Cryobiopsy

Transbronchial needle aspiration combined with cryobiopsy in the diagnosis of mediastinal diseases: a multicentre, open-label, randomised trial



Ye Fan*, An-Mei Zhang*, Xian-Li Wu*, Zan-Sheng Huang*, Konstantina Kontogianni, Kai Sun, Wan-Lei Fu, Na Wu, Wolfgang M Kuebler, Felix J F Herth



	EBUS-TBNA alone group (n=135)	Combined group (n=136)
Age, years	56.2 (12.5)	57.3 (12.5)
Sex		
Female	56 (41%)	50 (37%)
Male	79 (59%)	86 (63%)
Ethnicity		
Asian	85 (63%)	86 (63%)
White	50 (37%)	50 (37%)
BMI, kg/m ²	24.1 (3.6)	23.6 (4.0)
Smoking, pack-years	13.3 (22.2)	15.2 (19.2)
Lesion short axis diameter, cm	2.1 (0.8)	2.0 (0.9)

	EBUS-TBNA alone group (n=135)	Combined group (n=136)
Lesion station		
7	43 (32%)	47 (35%)
13R	1 (1%)	1 (1%)
12R	2 (1%)	2 (1%)
11R	15 (11%)	15 (11%)
10R	1 (1%)	2 (1%)
4R	23 (17%)	30 (22%)
2R	14 (10%)	4 (3%)
13L	0	1 (1%)
11L	7 (5%)	6 (4%)
10L	5 (4%)	6 (4%)
4L	8 (6%)	16 (12%)
2L	12 (9%)	6 (4%)
3A	1 (1%)	0
3P	3 (2%)	0

	EBUS-TBNA alone group (n=135)	Combined group (n=136)	p value
Diagnostic yield	0.0039
No definitive diagnosis	26 (19%)	10 (7%)	..
Definitive diagnosis	109 (81%)	126 (93%)	..
Procedure time, min	17.0 (8.2)	22.3 (6.4)	<0.0001
Adverse events			
Coughing	12 (9%)	19 (14%)	0.19
Dyspnoea	4 (3%)	2 (1%)	0.67
Haemoptysis	2 (1%)	3 (2%)	1.00
Bleeding
Grade 2	14 (10%)	16 (12%)	0.72
Grade 3	2 (1%)	3 (2%)	1.00
Grade 4	0	0	..
Pneumothorax	4 (3%)	2 (1%)	0.67
Pneumomediastinum	0	1 (1%)	1.00
Death	0	0	..

Data are n (%) or mean (SD) unless otherwise stated. EBUS-TBNA=endobronchial ultrasound-guided transbronchial needle aspiration.

Table 2: Diagnostic yield and adverse event analyses in the full analysis set (interindividual comparisons)

	Total (n=134)	EBUS-TBNA alone (n=134)	EBUS-TBNA plus cryobiopsy (n=134)	p value
Diagnostic yield	0.0026
No definitive diagnosis	..	24 (18%)	8 (6%)	..
Definitive diagnosis	..	110 (82%)	126 (94%)	..
Lung cancer	1.00
Any	64 (48%)	63 (47%)	63 (47%)	..
Lung, adenocarcinoma	31 (23%)	30 (22%)	30 (22%)	..
Lung, squamous cell	7 (5%)	7 (5%)	7 (5%)	..
Lung, large cell	3 (2%)	3 (2%)	3 (2%)	..
Lung, neuroendocrine	1 (1%)	1 (1%)	1 (1%)	..
Lung, small cell	22 (16%)	22 (16%)	22 (16%)	..
Other metastatic carcinoma	-
Any	5 (4%)	5 (4%)	5 (4%)	..
Breast cancer	2 (1%)	2 (1%)	2 (1%)	..
Oesophageal cancer	1 (1%)	1 (1%)	1 (1%)	..
Prostatic cancer	2 (1%)	2 (1%)	2 (1%)	..
Uncommon tumour	0.27
Any	17 (13%)	10 (7%)	13 (10%)	..
Lymphoma	10 (7%)	5 (4%)	8 (6%)	..
Neurilemmoma	1 (1%)	1 (1%)	1 (1%)	..
NUT midline carcinoma	1 (1%)	0	0	..
Seminoma	1 (1%)	1 (1%)	1 (1%)	..
Thymic carcinoma	1 (1%)	0	0	..
Thymoma	3 (2%)	3 (2%)	3 (2%)	..
Benign disorder*	0.0009
Any	48 (36%)	32 (24%)	45 (34%)	..
Pneumoconiosis	10 (7%)	9 (7%)	10 (7%)	..
Sarcoidosis	16 (12%)	12 (9%)	16 (12%)	..
Tuberculosis	19 (14%)	11 (8%)	19 (14%)	..

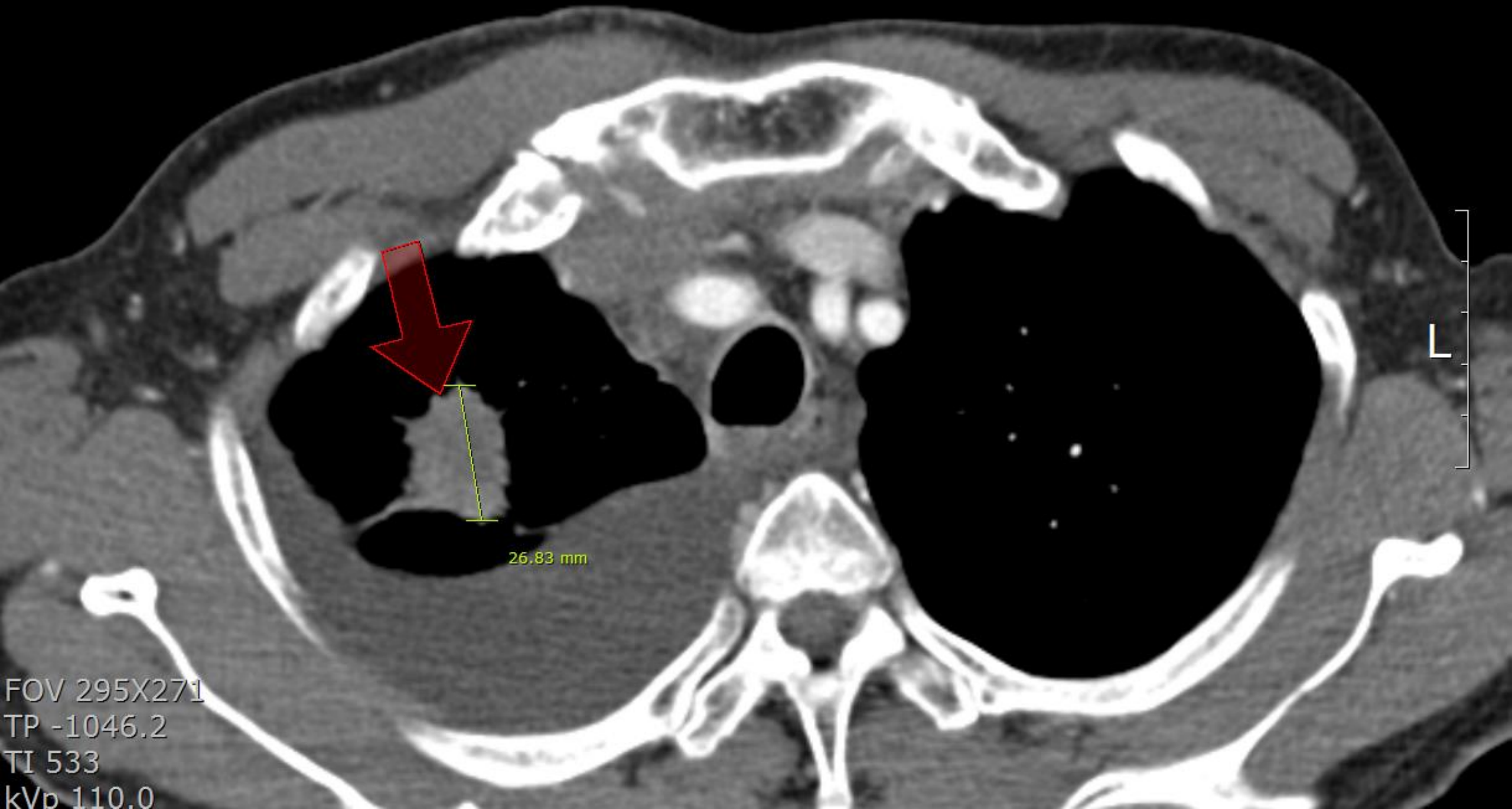
- Lung cancer **genomic testing** and **PD-L1 immunohistochemistry assay** were suitable in almost all (37 [**97%**] of 38) of the non-small-cell lung cancer samples retrieved from the combined approach, whereas they were only available in 30 (**79%**) of 38 samples from the EBUS-TBNA alone approach (RR 1.23 [95% CI 1.04–1.47]; p=0.033).
- Additionally, the post-hoc analyses stratified by study site showed **no between-site differences** in the major findings on safety and diagnostic yield.



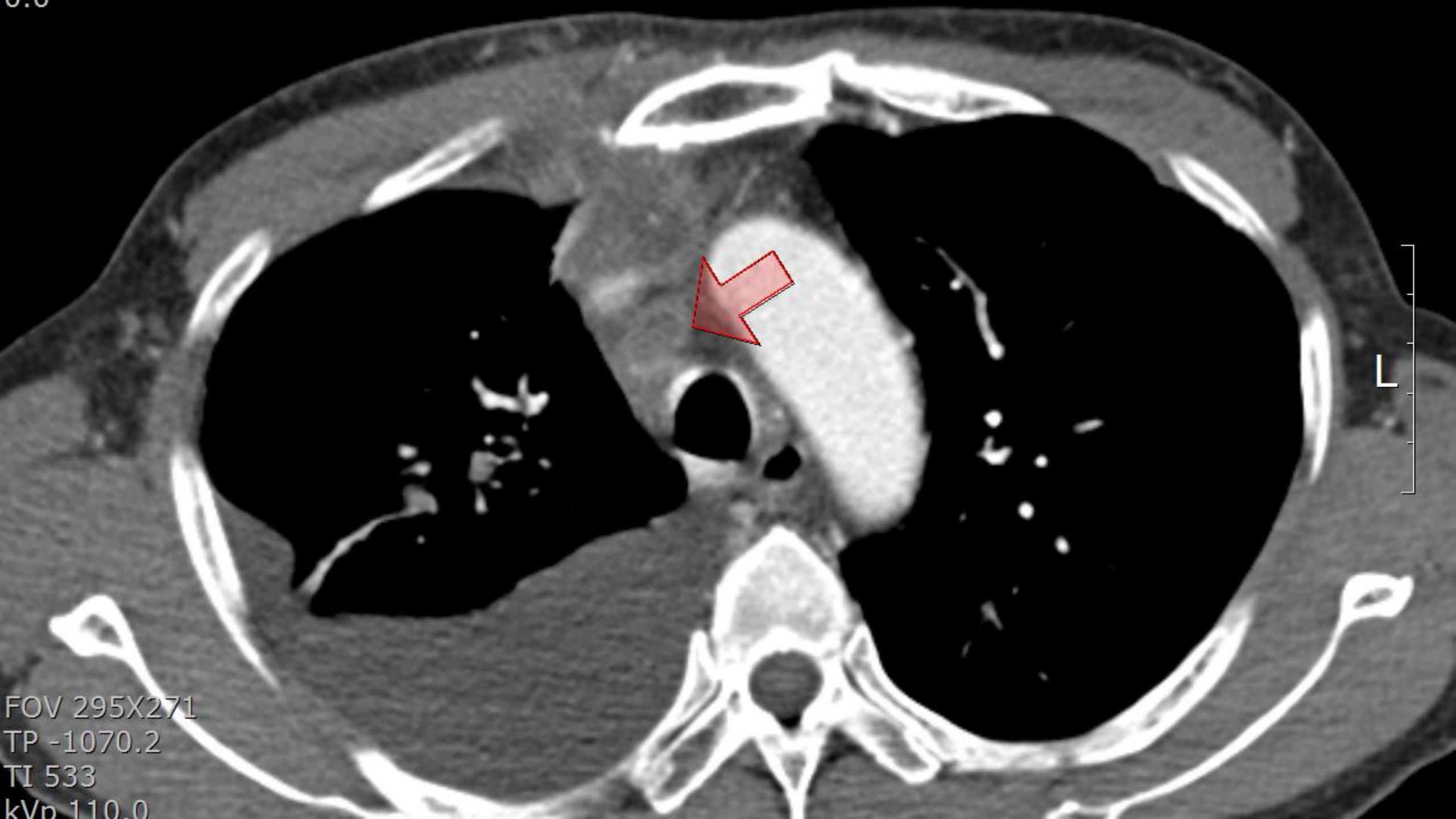
Case

62/M

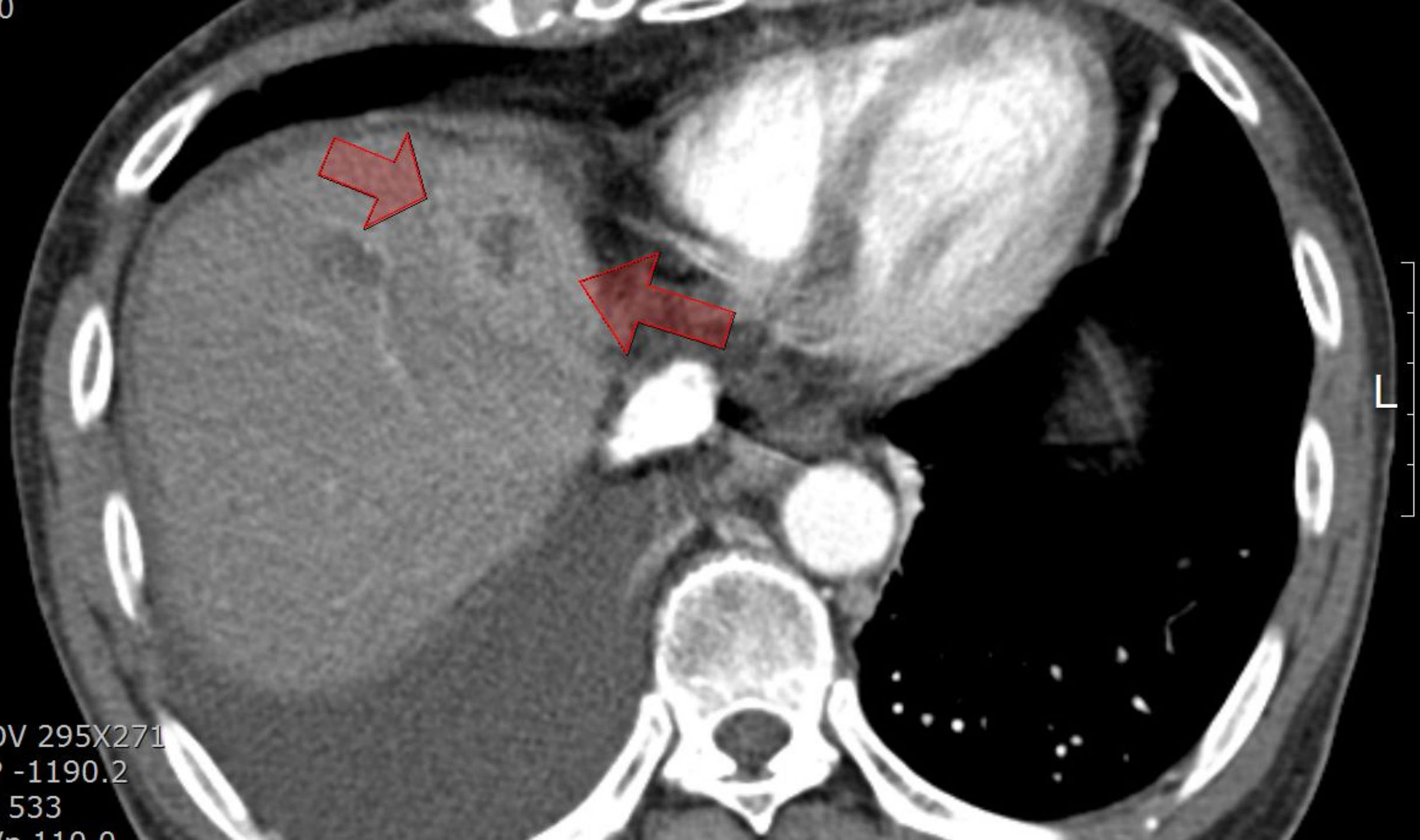
- 15년 전 HCC → S6 wedge resection
- 한달 전부터 호흡곤란
- 원인 평가 중 발견된 흉수로 전원



FOV 295X271
TP -1046.2
TI 533
kVp 110.0



FOV 295X271
TP -1070.2
TI 533
kVp 110.0



FOV 295X271
TP -1190.2
TI 533
kVp 110.0

EBUS-TBNA (22G)

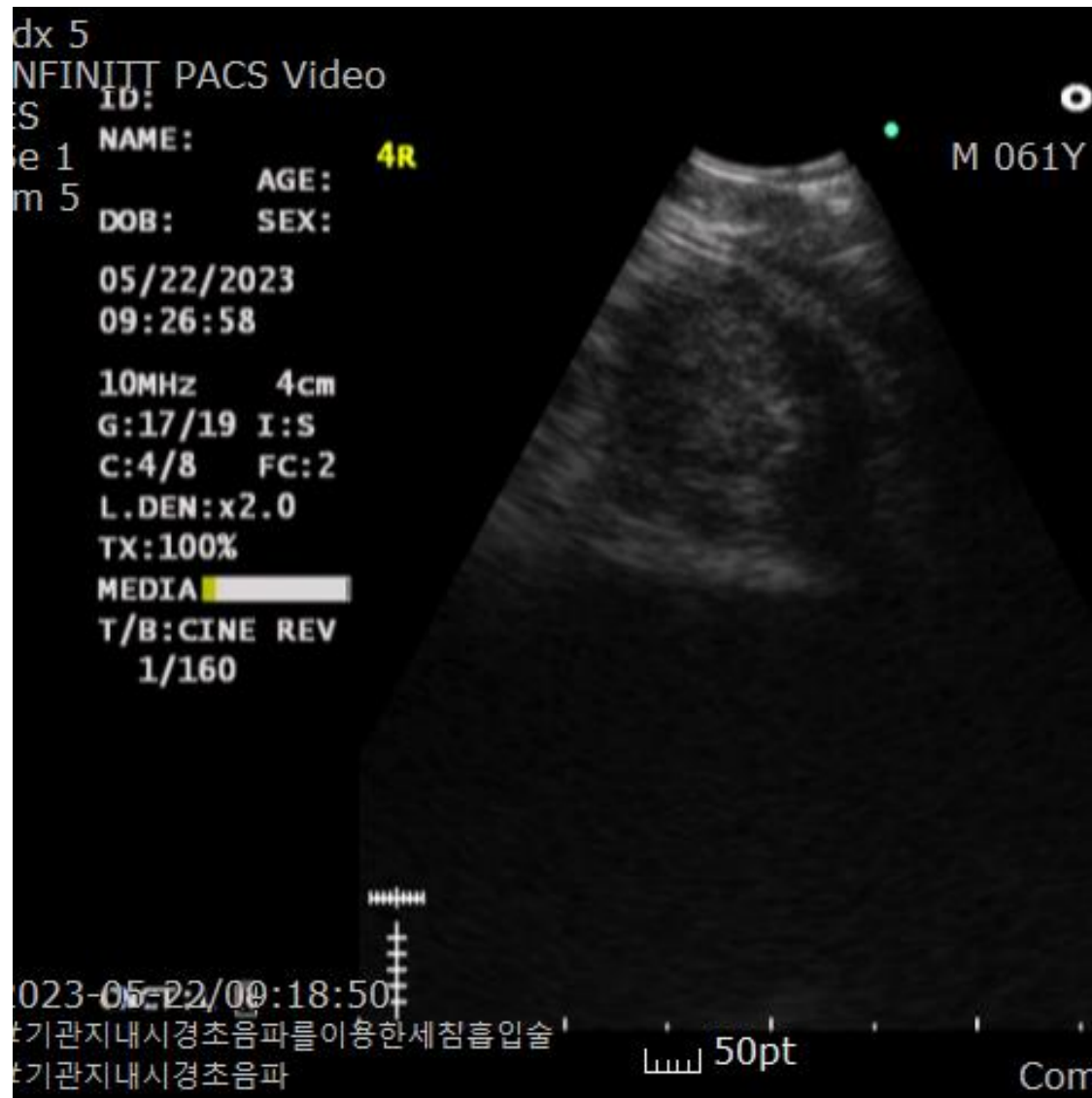
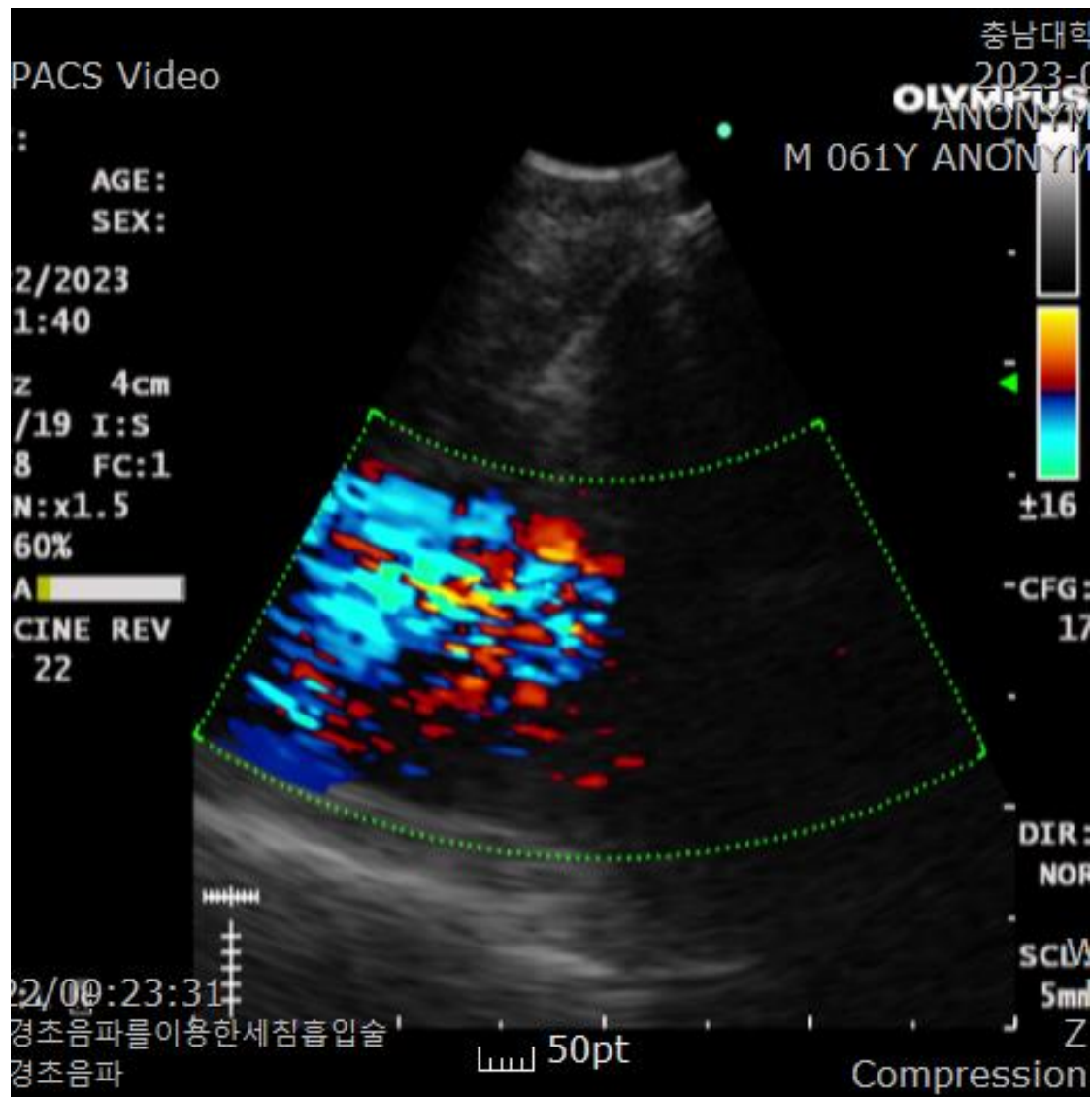
- Lymph node, mediastinal, "4R", EBUS-biopsy;
- A few atypical cells

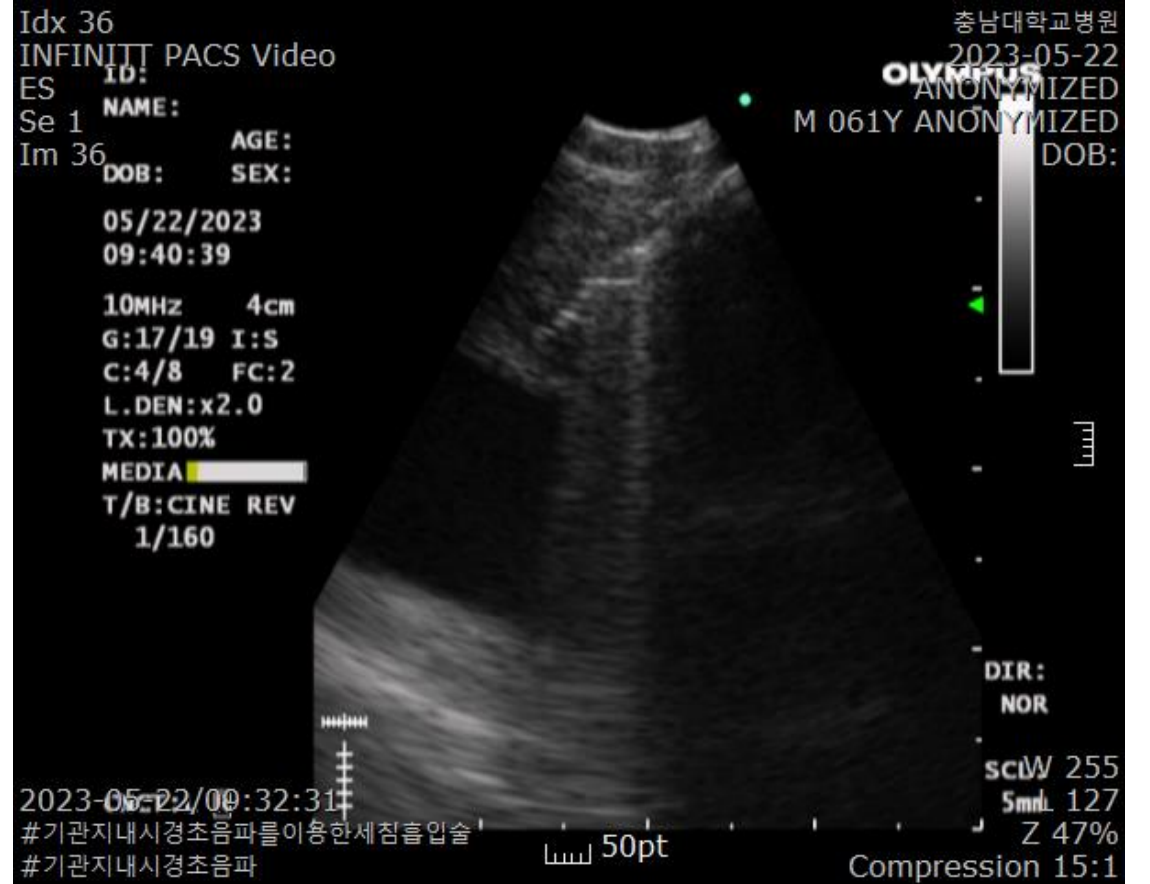
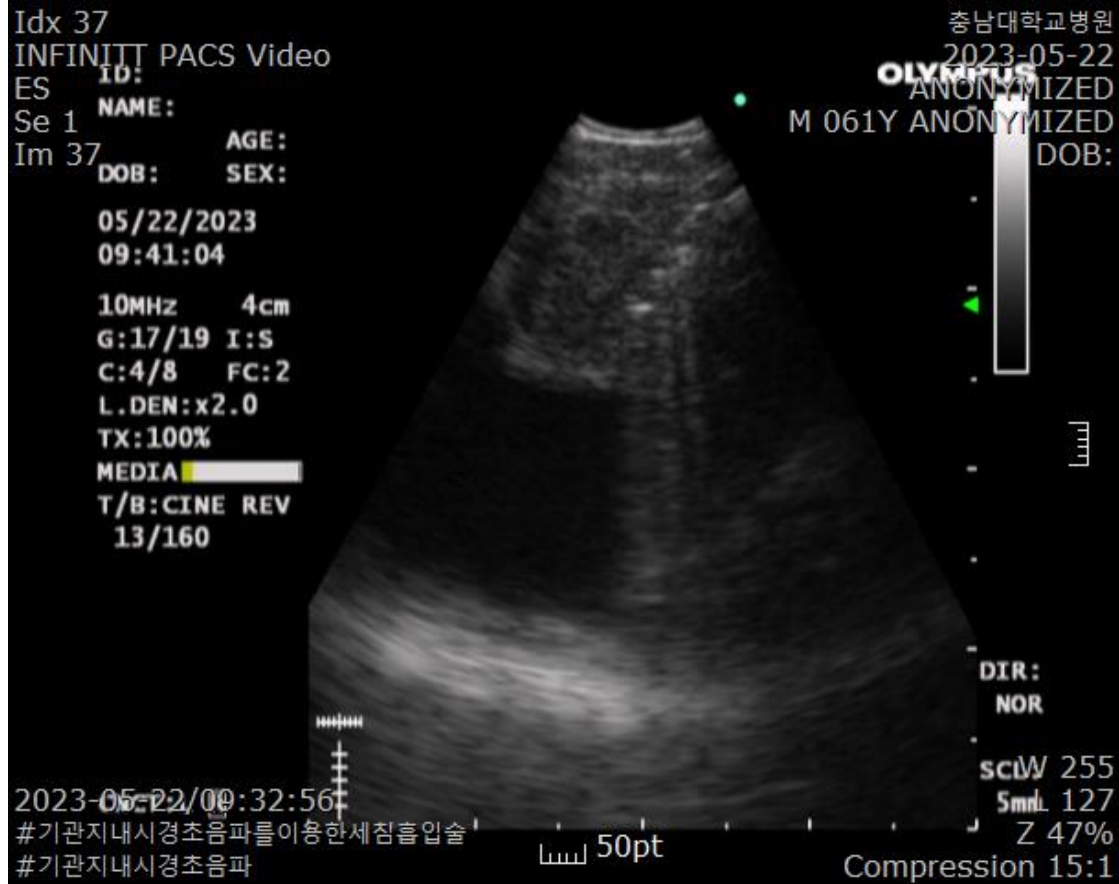
- < FINAL DIAGNOSIS >

- Lymph node, mediastinal, "4R", EBUS-biopsy;
- A few atypical cells

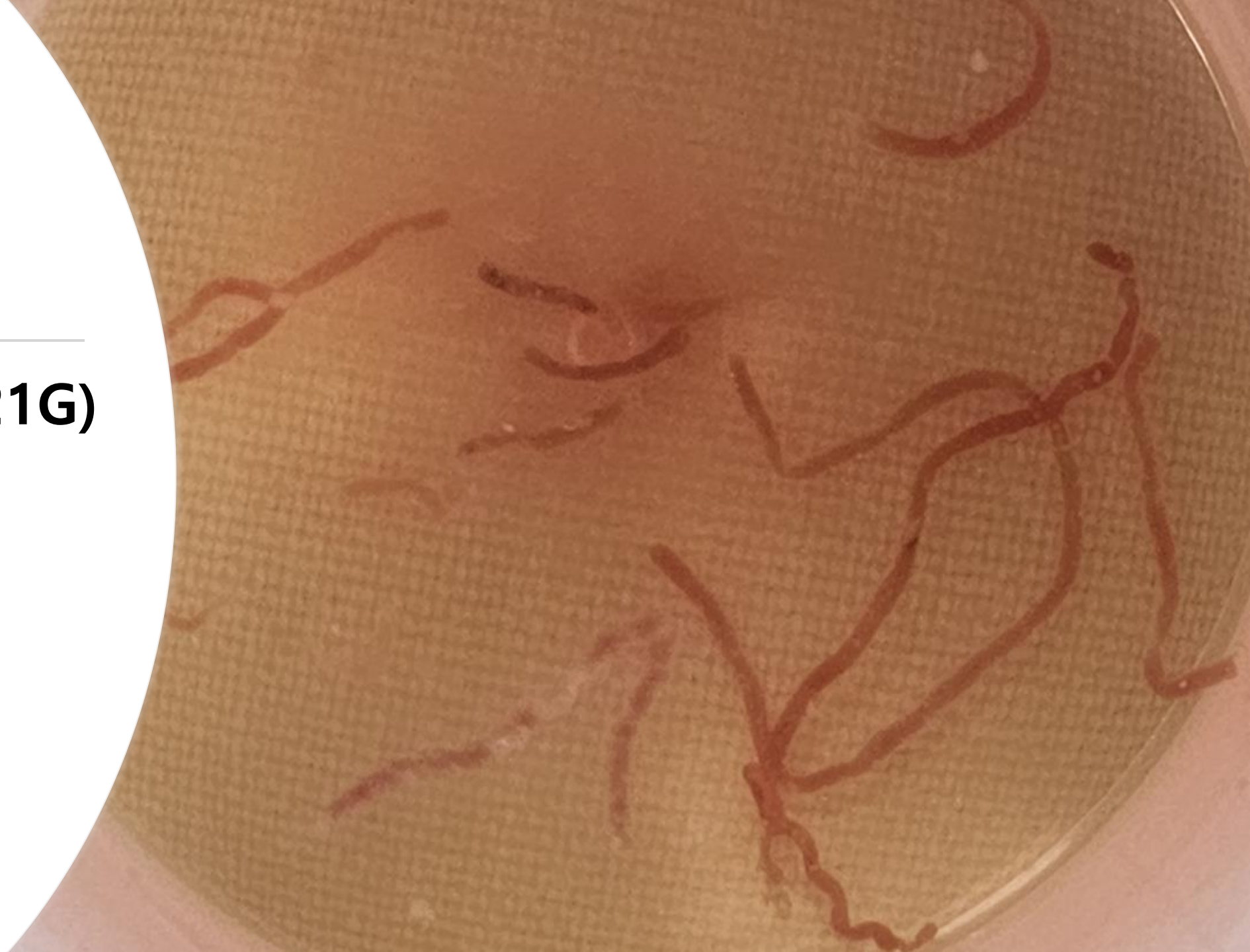- * Immunohistochemical stain results;
- 1) CK: positive
- 2) TTF-1: equivocal
- 3) CD56, P40: negative

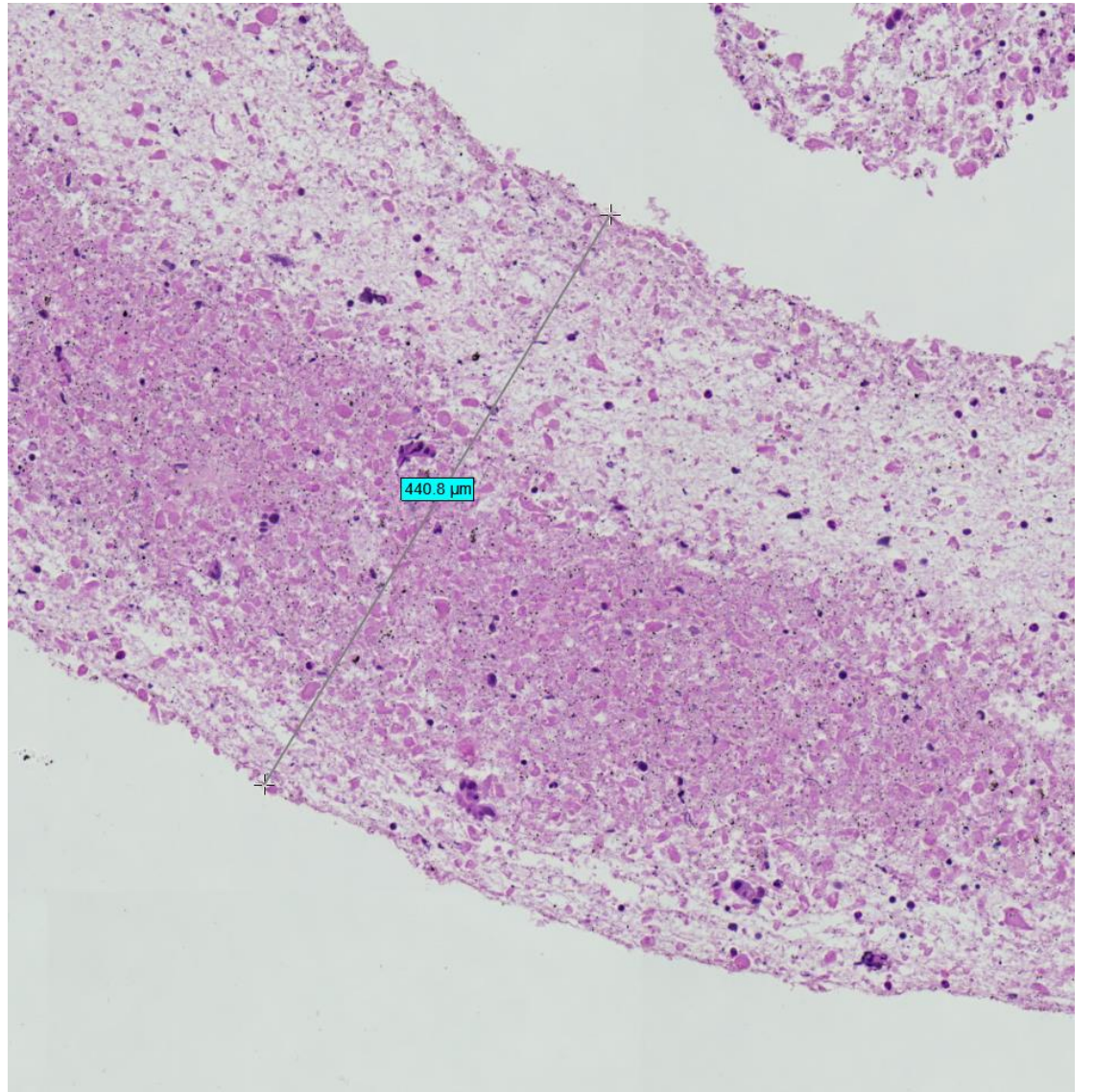
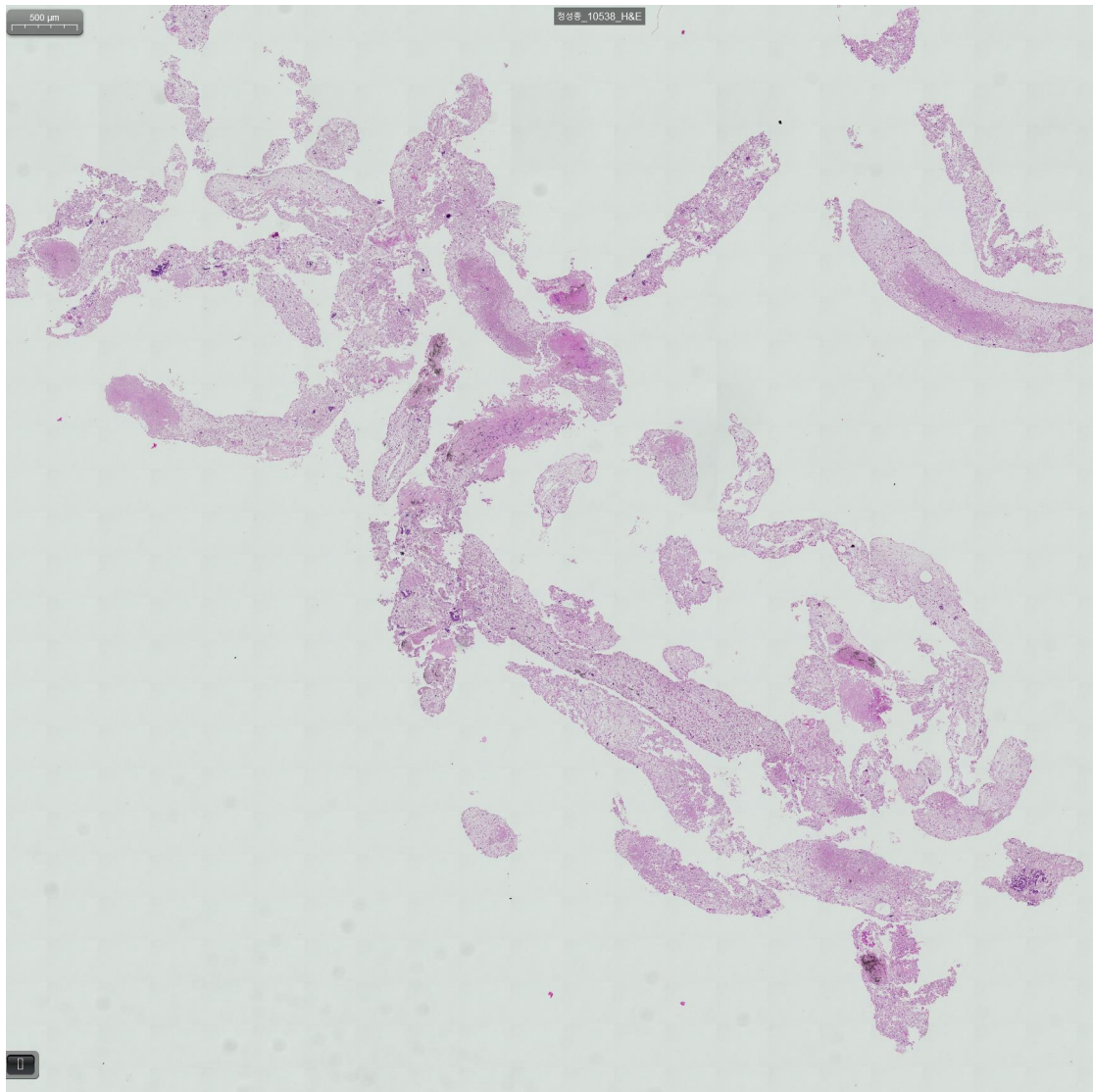
- * Note: 소량의 atypical cell이 관찰되나 양이 너무 적어 진단하기 어렵습니다.

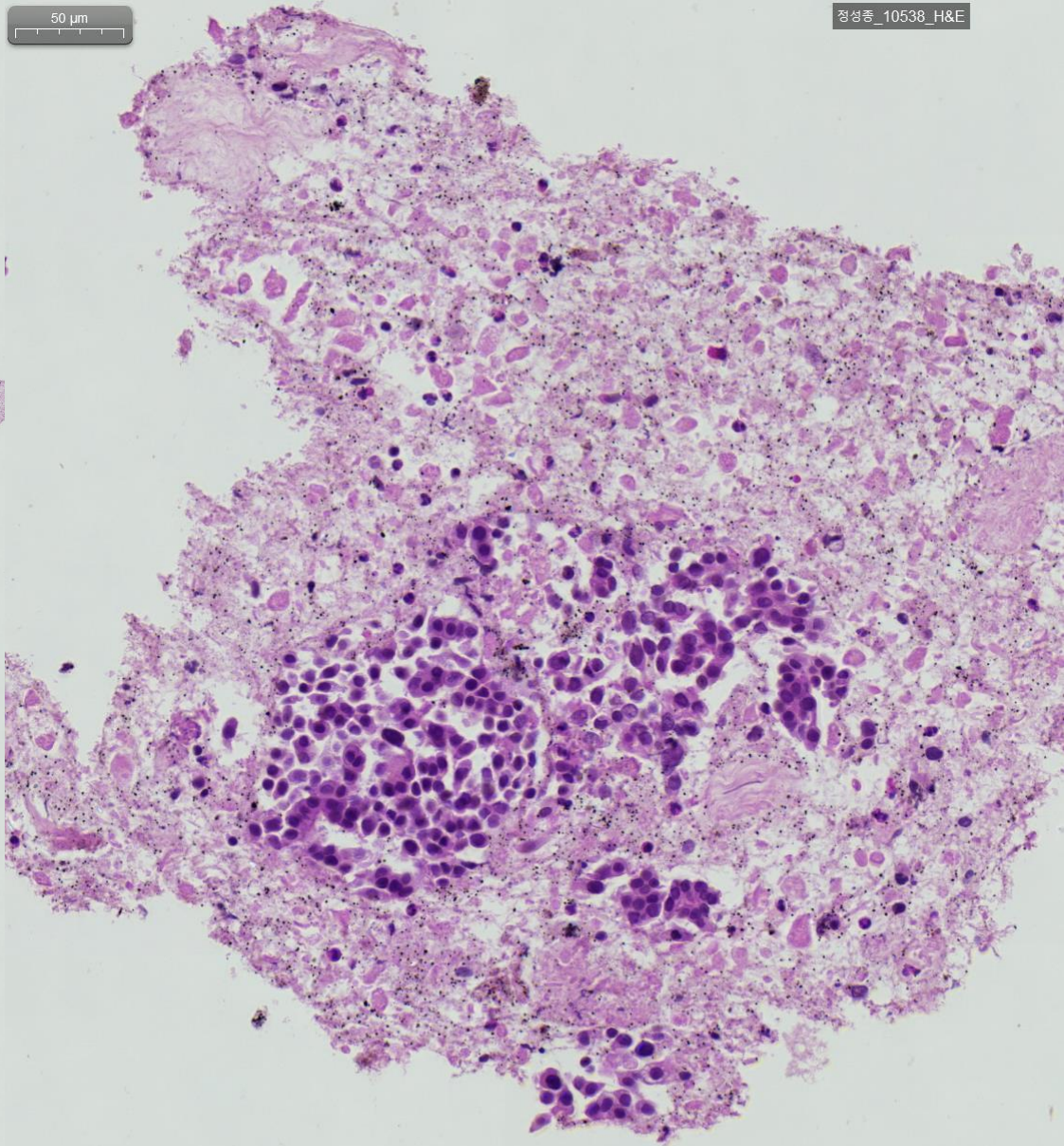
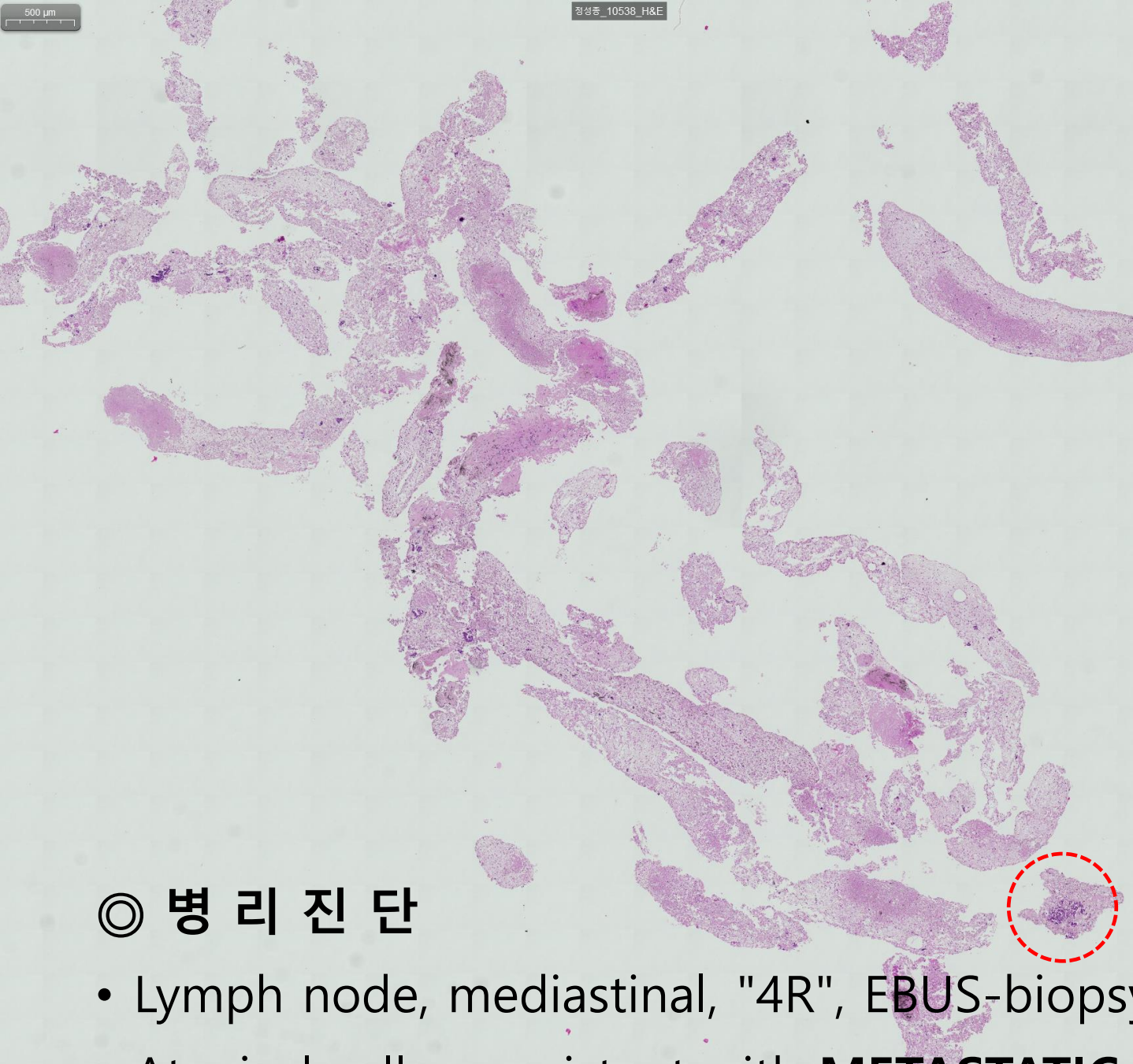



EBUS-TBNA (21G)







◎ 병 리 진 단

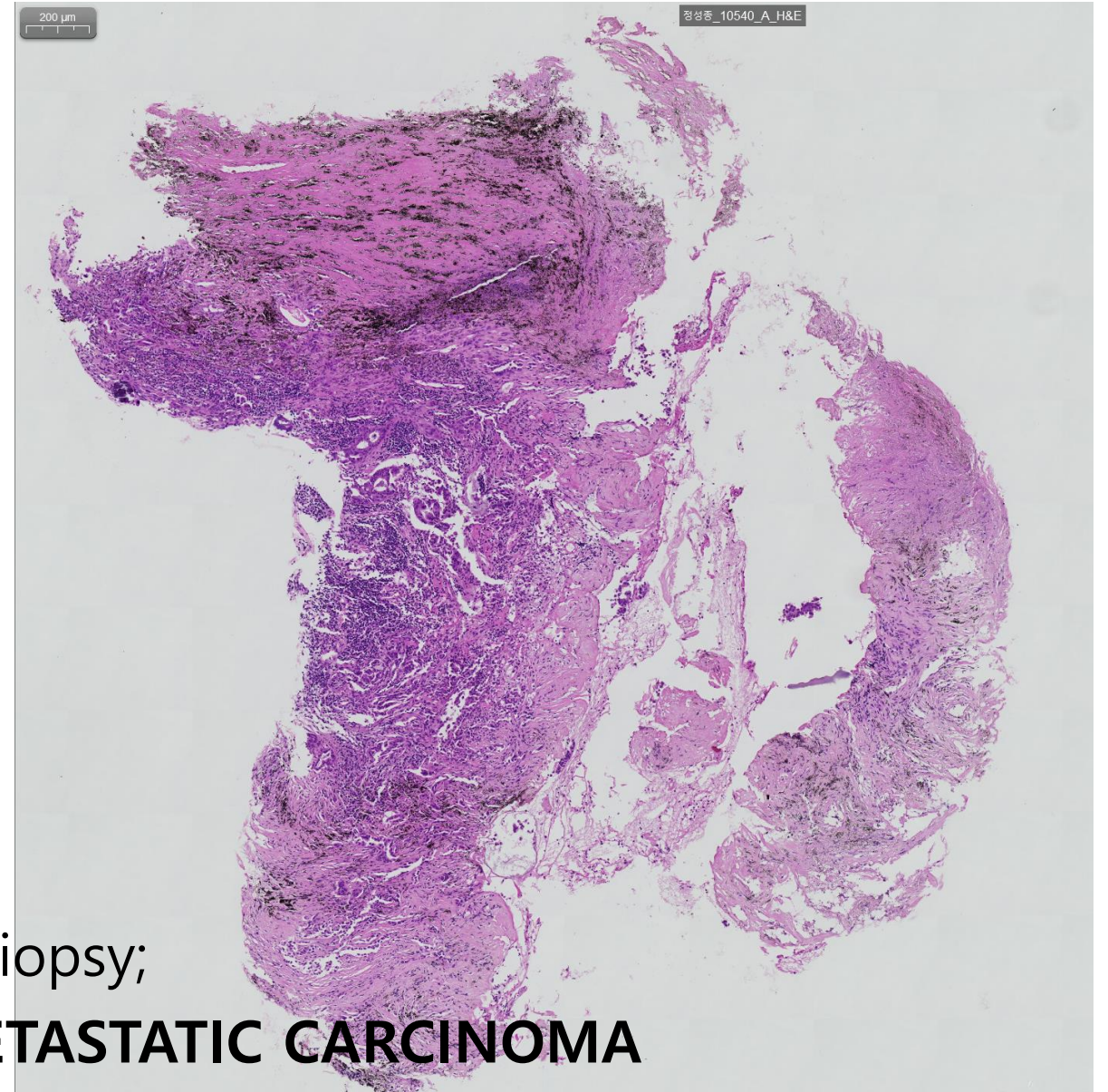
- Lymph node, mediastinal, "4R", EBUS-biopsy;
- Atypical cells, consistent with **METASTATIC ADENOCARCINOMA**

Cryobiopsy (1.1 mm probe)



◎ 병 리 진 단

- Lymph node, mediastinal, "4R", cryobiopsy;
- A few atypical cells, suggestive of **METASTATIC CARCINOMA**

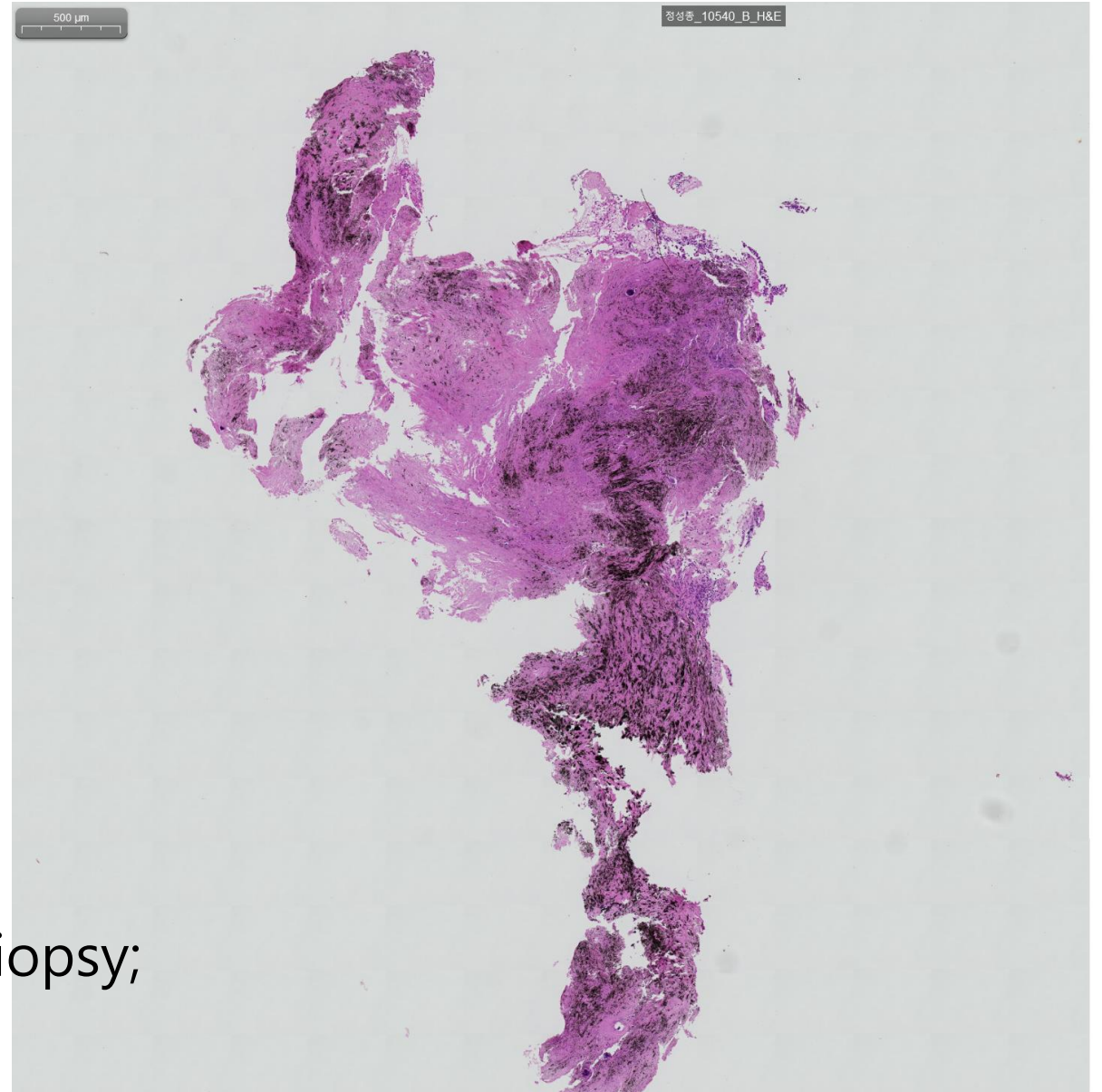


Cryobiopsy (1.1 mm probe)



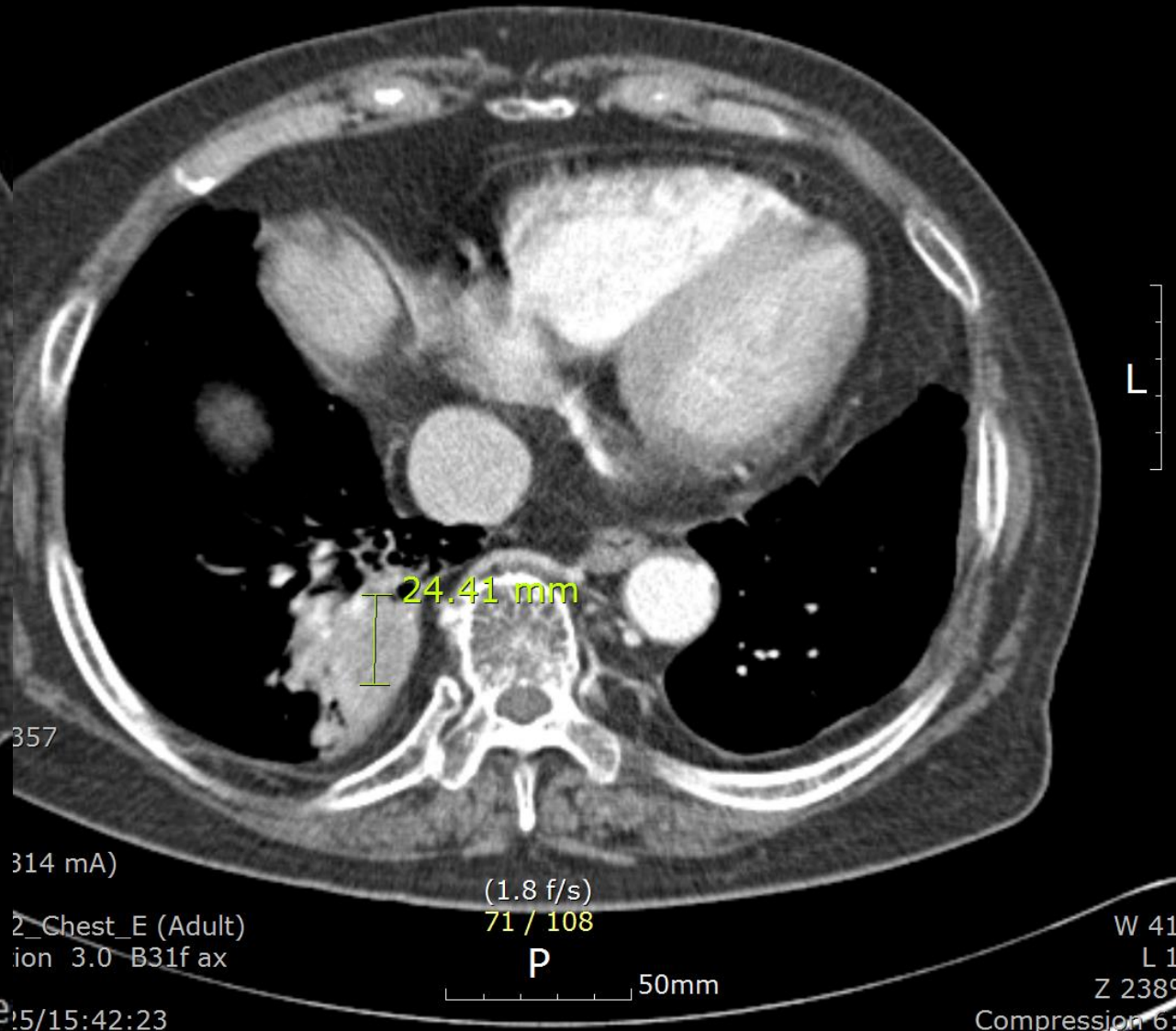
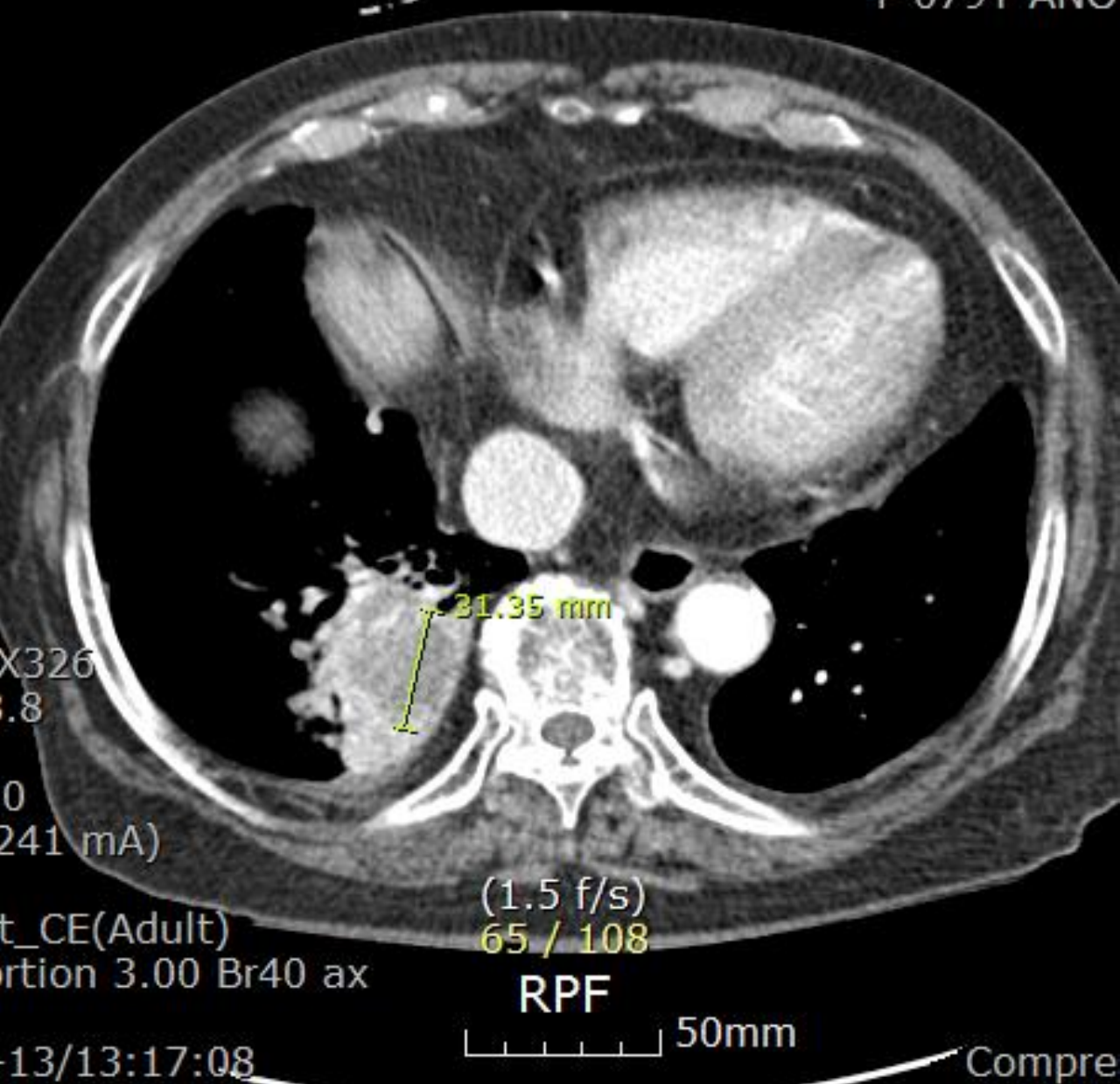
◎ 병 리 진 단

- Lymph node, mediastinal, "4R", cryobiopsy;
- Anthracofibrosis



80/F

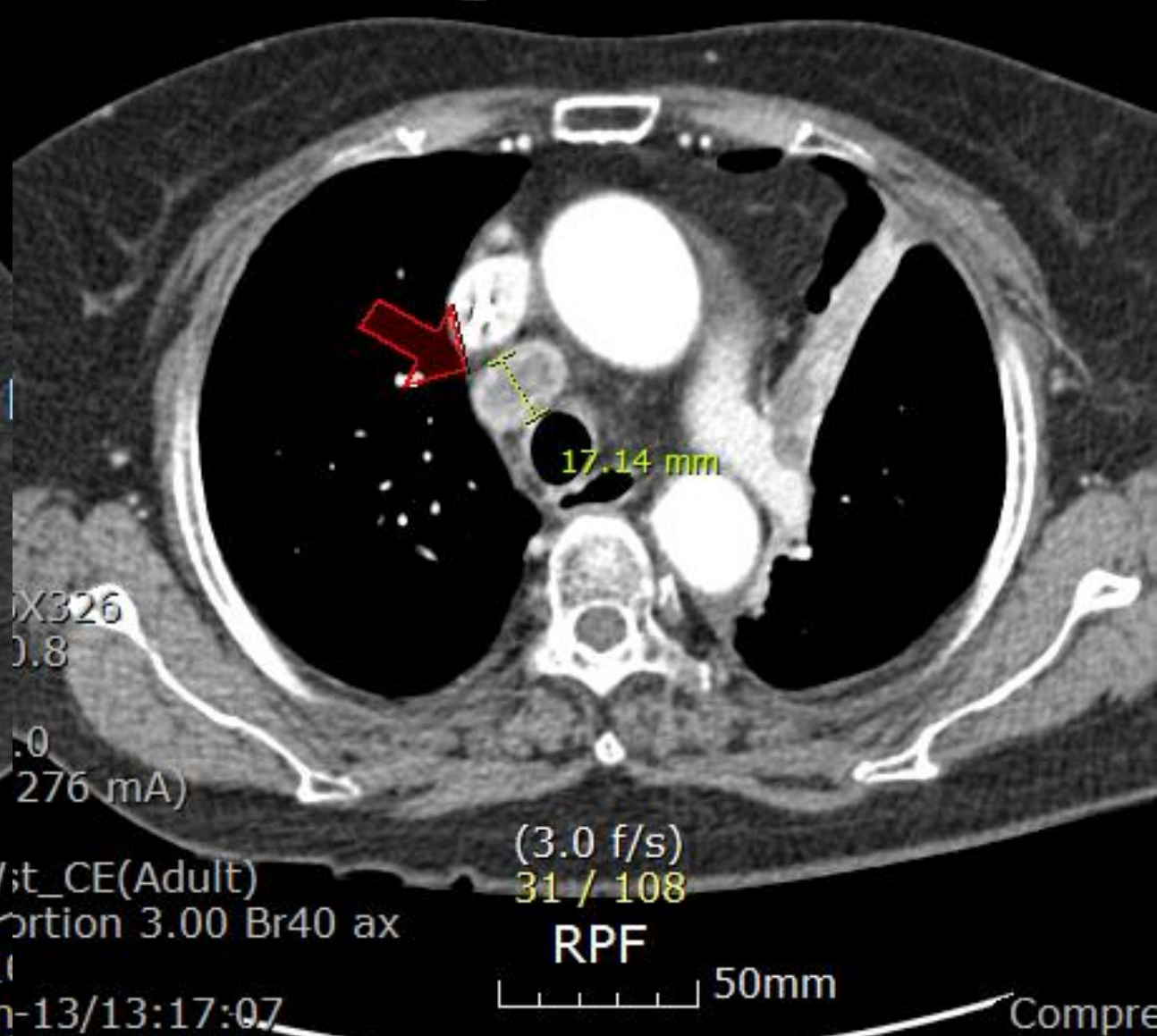
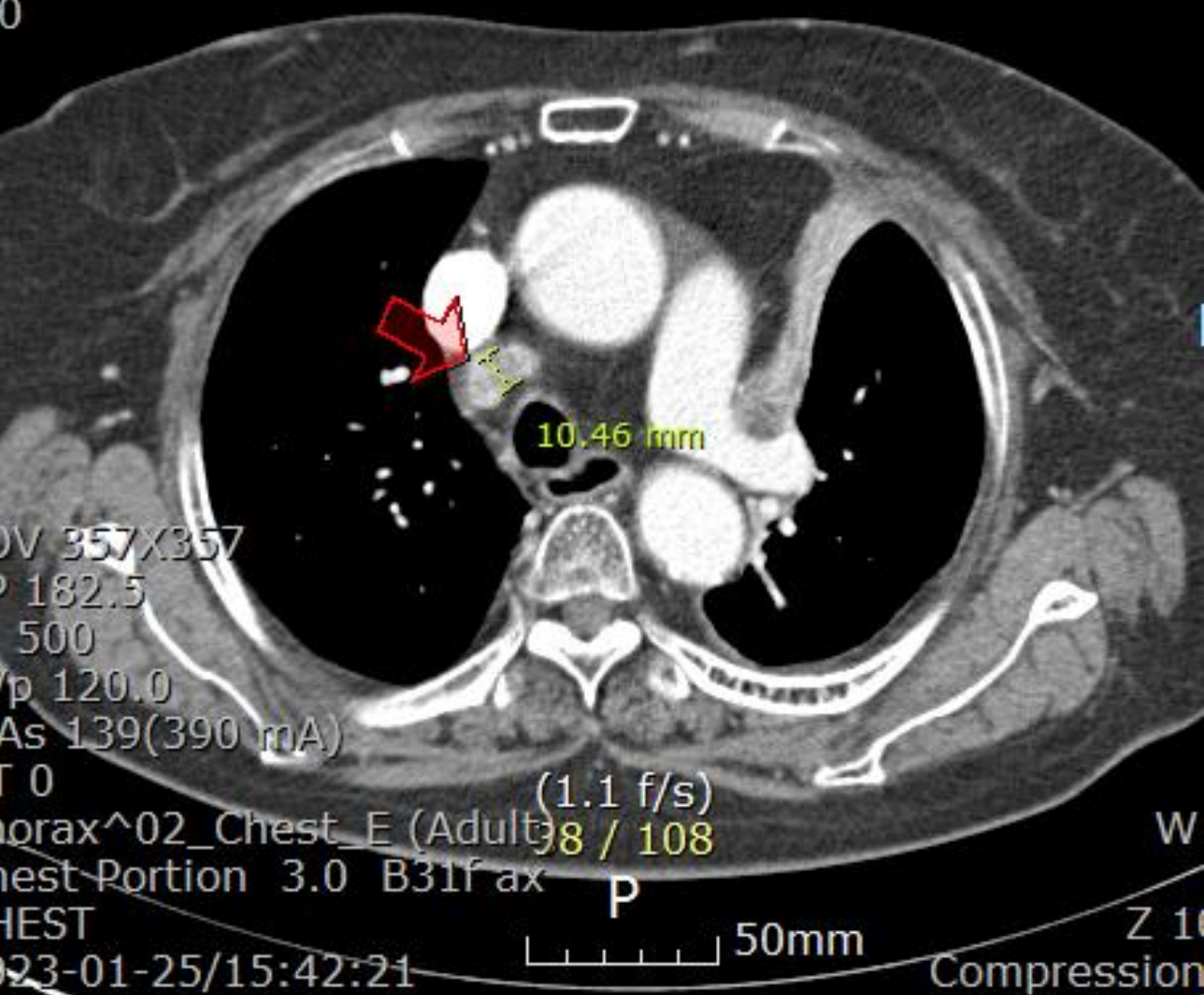
- NSCLC, T4N2M1c → Adenocarcinoma (high Pd-L1) / EGFR/ALK 음성
- 2018-05-18 #1-4. Cisplatin + Alimta → #1-33. alimta maintenance → chest CT : PD → Observation
- 2020.12.24 #1. Pembrolizumab
- 2021.01.20 #2. Pembrolizumab
- Immune related BOOP reaction으로 중단함
- 2021.11.3 SBRTx to RLL (40 Gy/4 fx) → RTx pneumonitis
- 2022.5.18 chest CT : LAP → 2022.6.24 EBUS biopsy- EGFR mutation L858R
- 2022.7.13 GKS
- 2022.7.5~2022.8.18 Afatinib
- BOOP → methyl PD → Observation



x 3
ensation 64
e 4
n 38
S
0thk
0


ChungNam Univ. Hospit
2023-01M X.cite
ANONYMI
F 079Y ANONYMI
D

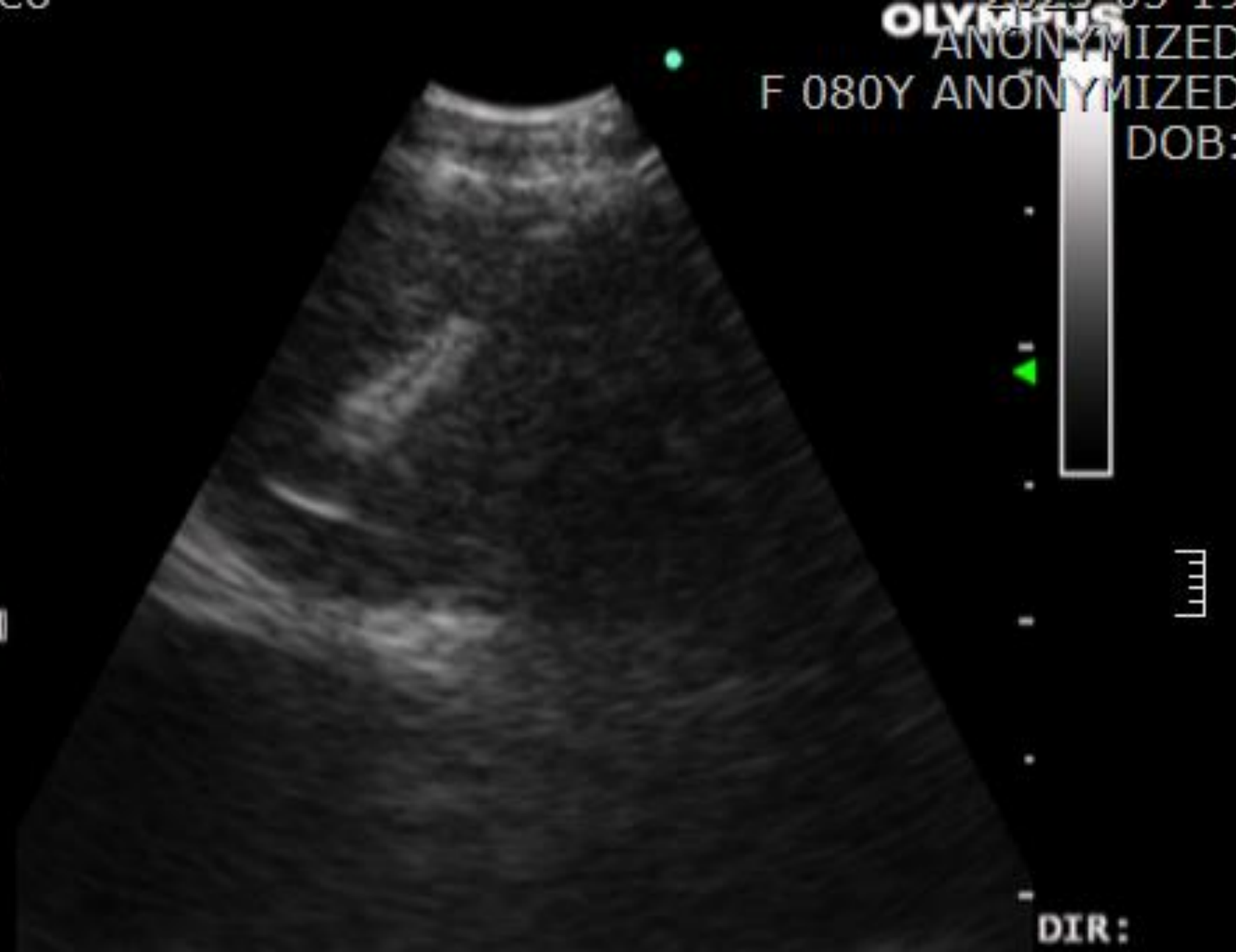
20
ANC
F 079Y ANC



WININT11.PACS.VIDEO
ES ID:
Se 1 NAME:
Im 36 AGE:
DOB: SEX:

05/19/2023
13:17:37

10MHz 4cm
G:17/19 I:S
C:4/8 FC:2
L.DEN:x2.0
TX:100%
MEDIA 
T/B:NONE



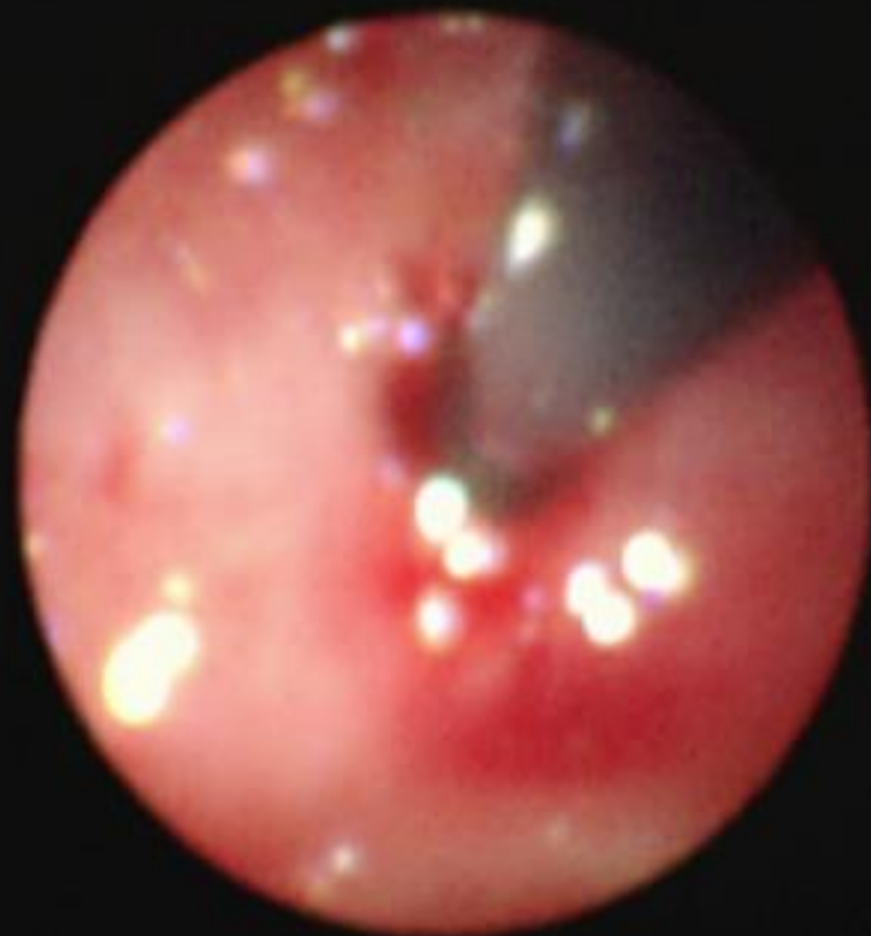
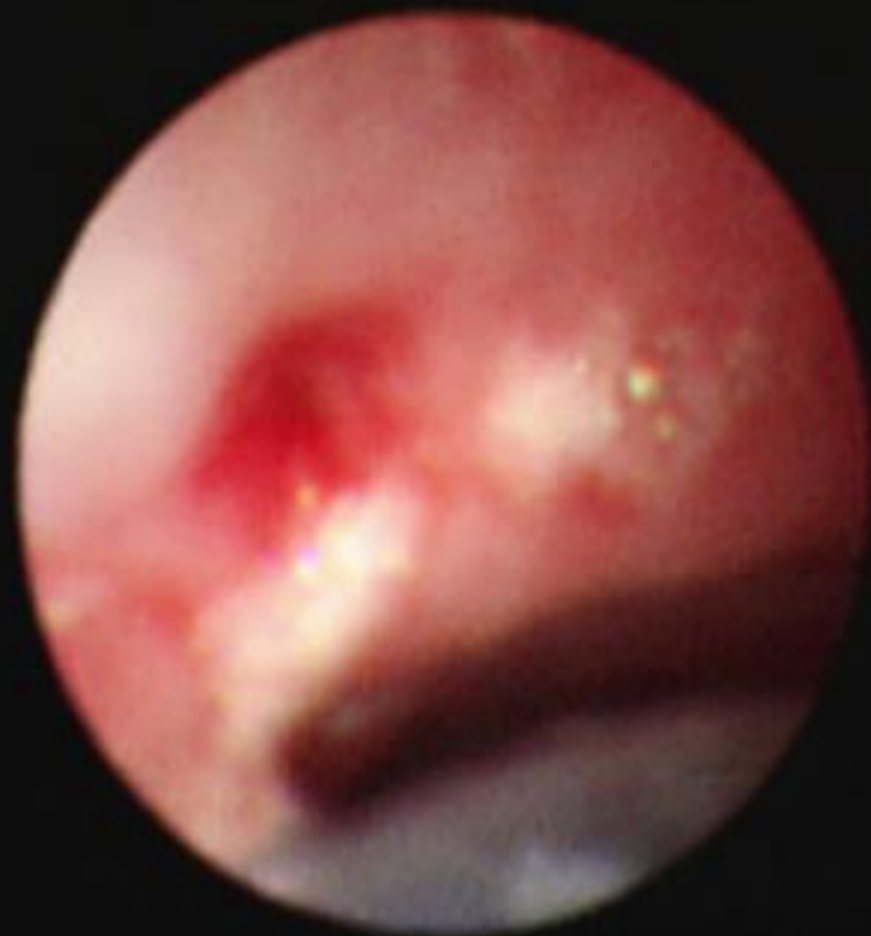
OLYMPUS
F 080Y ANONYMIZED
DOB:

DIR:

Video

충남대
2023; Video
ANONY
F 080Y ANONY

충남대
2023
ANONY
F 080Y ANONY



:15:46
파를이용한세침흡입술
파

50pt

Compressio파

:17:06
파를이용한세침흡입술
파

50pt

Compressio

Se 1
Im 54

NAME:
AGE:
DOB: SEX:

05/19/2023
13:28:17

10MHz 4cm

G:17/19 I:S

C:4/8 FC:2

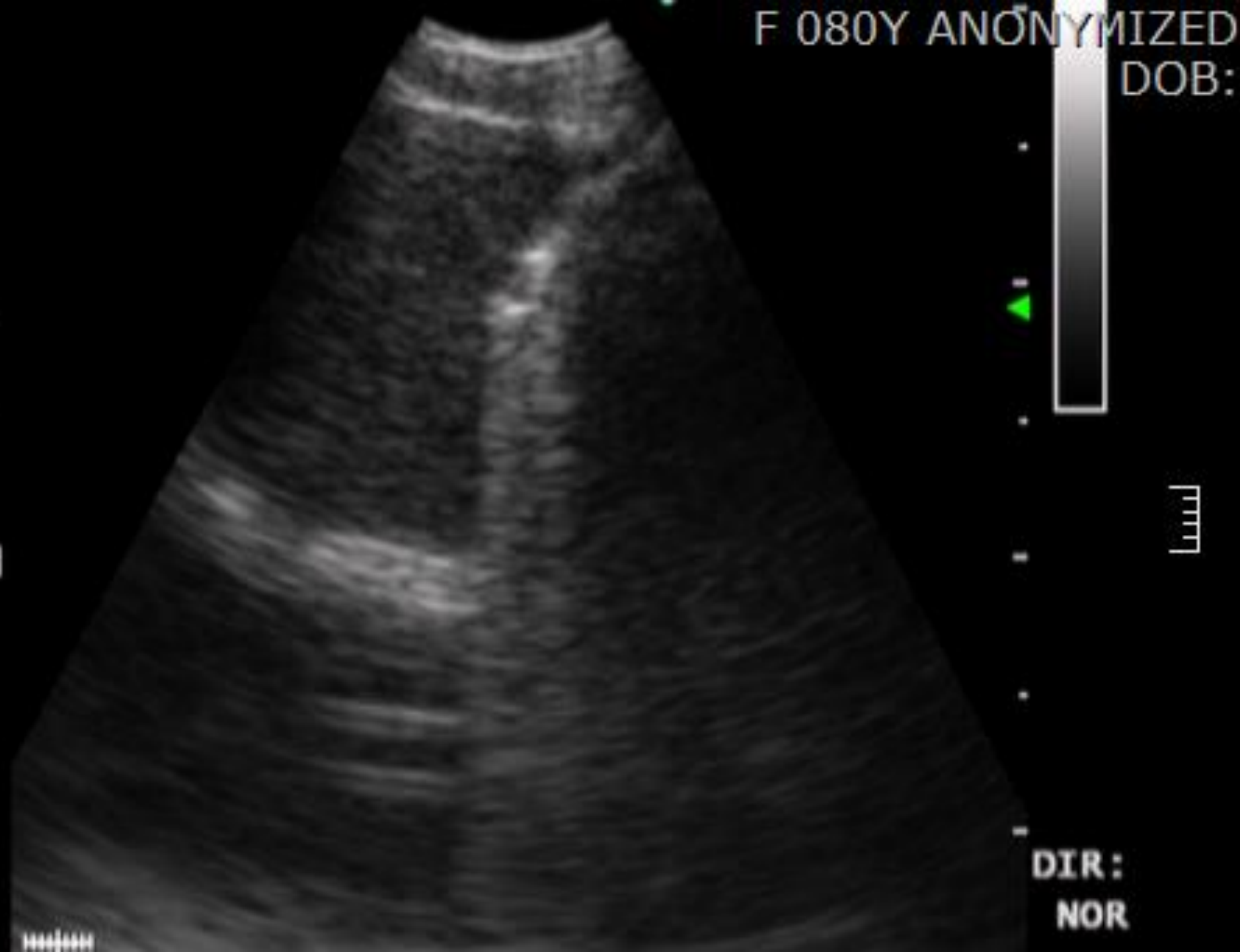
L.DEN:x2.0

TX:100%

MEDIA 

T/B:NONE

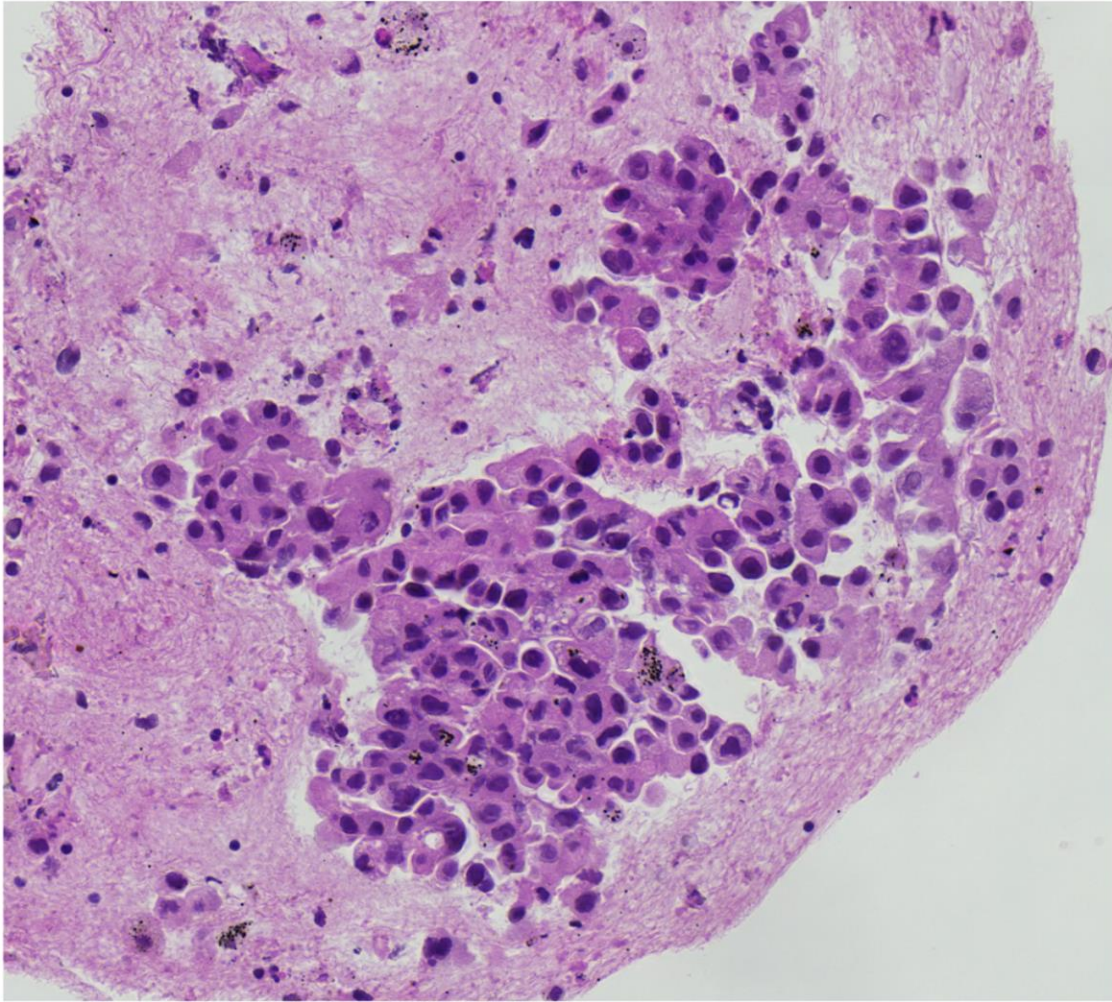
F 080Y ANONYMIZED
DOB:



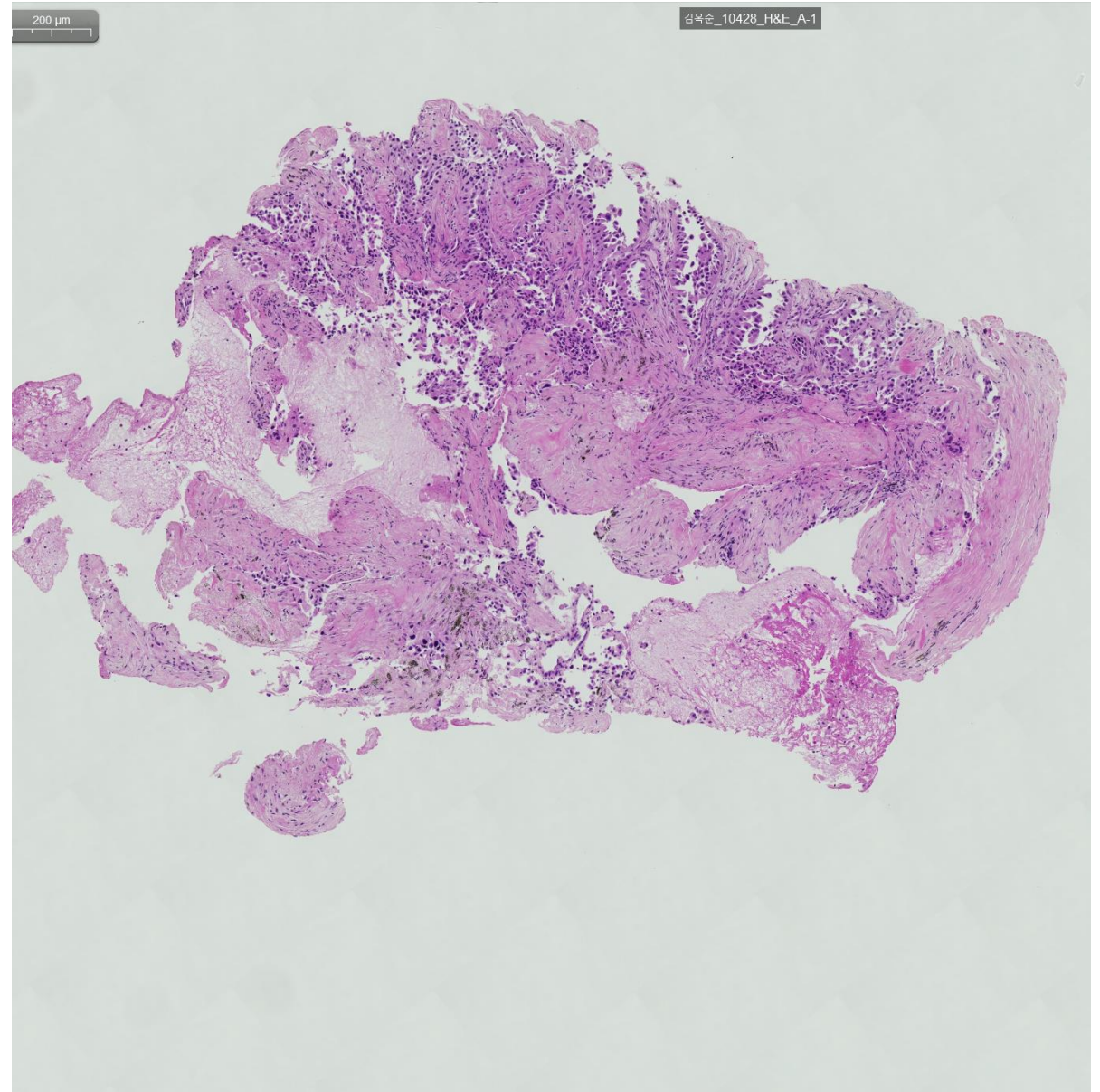
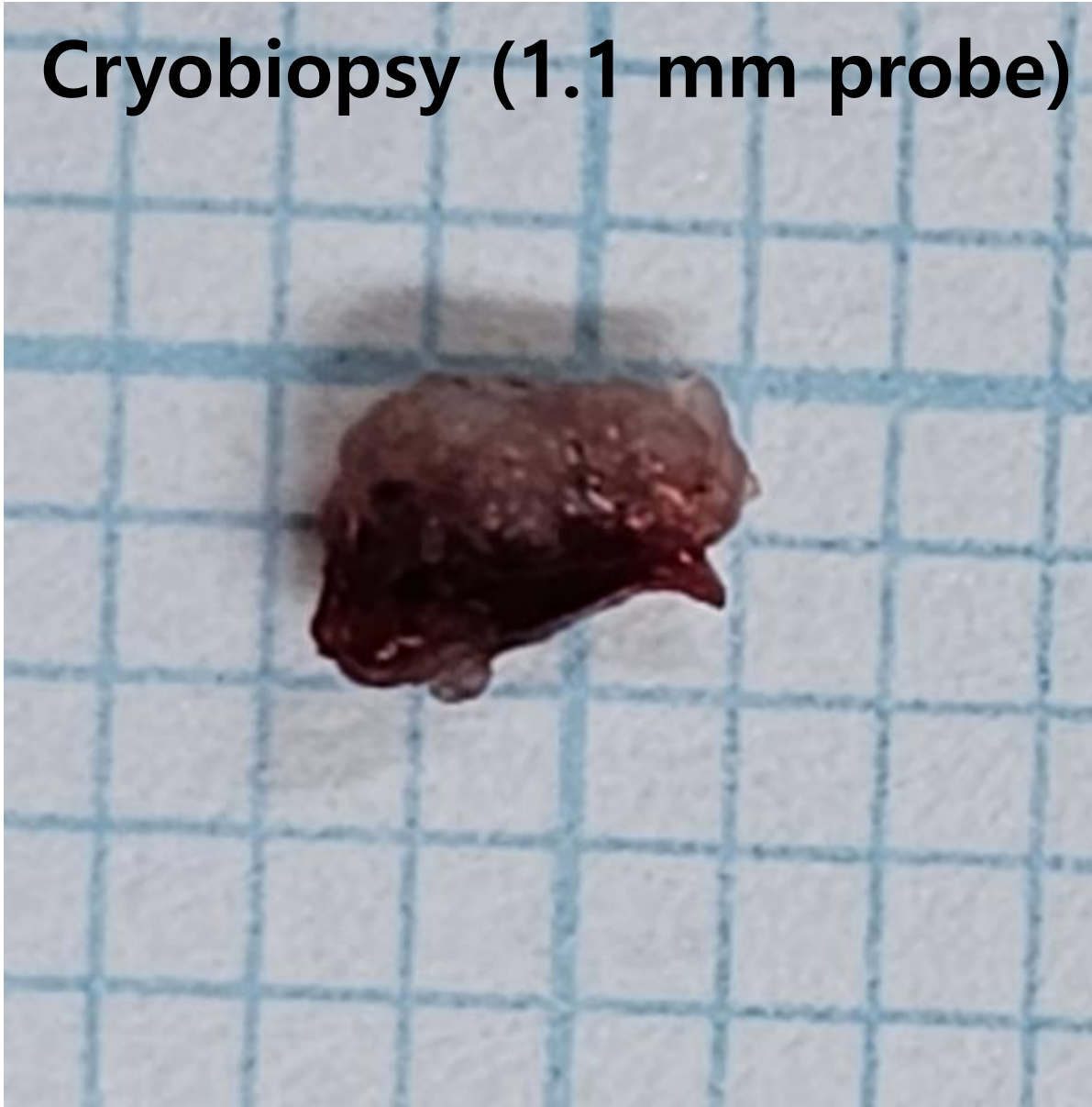EBUS-TBNA (21G)

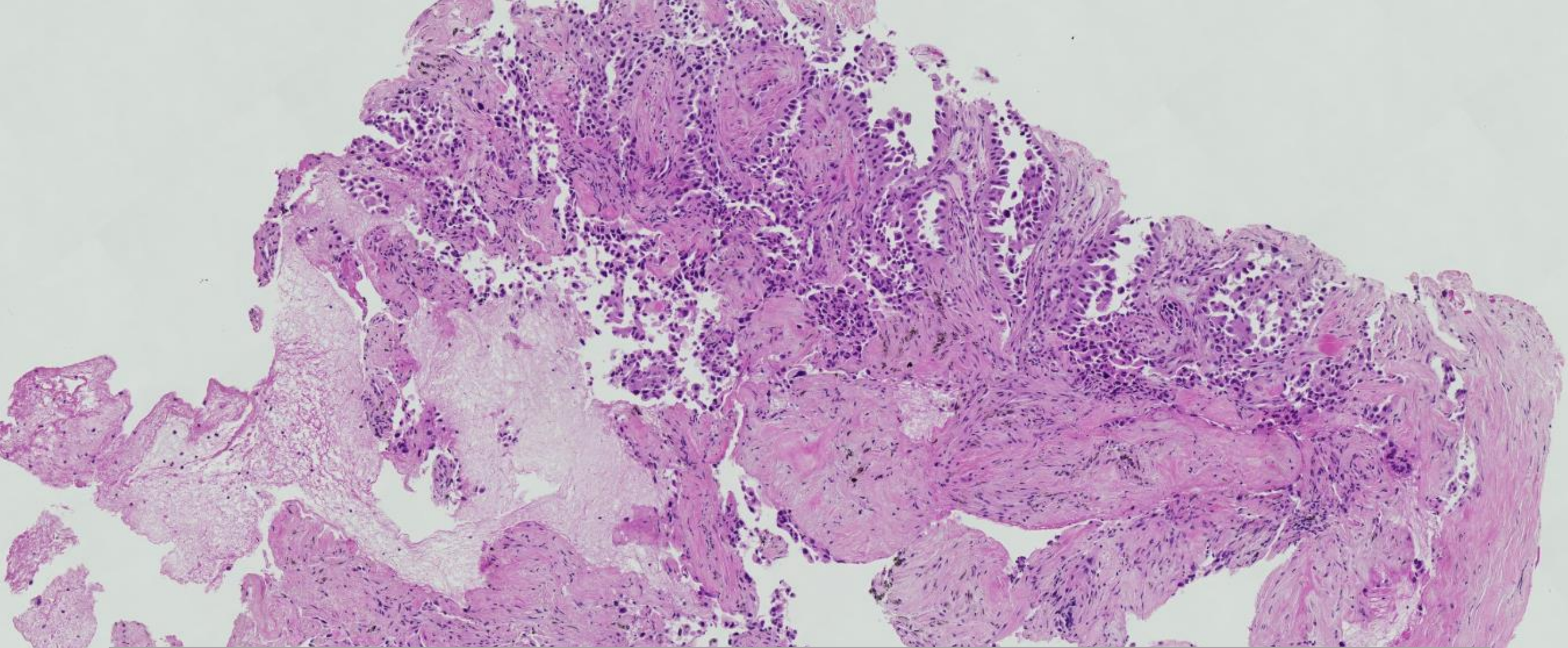
◎ 병 리 진 단

- Lymph node, mediastinal, "4R", cryobiopsy;
- Atypical cells, consistent with **METASTATIC CARCINOMA**



Cryobiopsy (1.1 mm probe)





◎ 병 리 진 단

- Lymph node, mediastinal, "4R", cryobiopsy;
- Involved by **ADENOCARCINOMA**

Summary

- PPLs + GGN → conventional forceps TBLB
 - Fluoroscopy guidance
 - Brushing / Cryobiopsy
- Upper lobes → GS, UTB > conventional forceps TBLB
- Invisible or Adjacent lesion (R-EBUS) → UTB (~50%)
- CTBS negative → Multiple biopsy devices
- Novel approach: RAB → Higher DY
- Real-time radial EBUS-guided TBNA → Without fluoroscopy/CBCT
- Benign lesion → Consider cryobiopsy

Thanks for your attention

Email: rahm3s@gmail.com