

대한결핵 및 호흡기학회 심포지엄

서울백병원 내과
R4 서영기

Chief Complaints

Abnormal chest x-ray

F/14

Onset : 1 week ago

Present illness

- 내원 1달전(2014. 04) 타병원 정신의학과에서 거식증 진단 받고 폐쇄병동 입원 치료 권유 받았으나 폐쇄병동에 대한 불안감으로 외래 경과 관찰만 유지하고 있던 환자로 1주전 신경정신과 외래에서 촬영한 흉부방사선상 종격동기종 소견 보여 입원 권유하였으나 본원에서의 치료 원하여 내원함.
- 10일 전부터 기침, 소량의 가래 증상 있었으며 이에 상기도감염 진단하에 경구 약물치료 이후 증상 호전됨.

Present illness

- 평소 체중 55kg이었으나 다이어트 위해 운동과 함께 식사량 줄여 금년 1월 체중 40kg으로 감소함. 금년 1월 이후부터 식사 후 복부 불편감 있어 한끼에 1~2 숟갈 정도로 식사량 더욱 감소하였고 4월 초 30kg으로 3개월 만에 10kg 감량함.

Past history

DM/HTN/Tbc/Hepatitis (- / - / - / -)

Anorexia nervosa : 2014.04 진단

Social history

직업 : 학생

Smoking (-) / Alcohol (-)

Family history

N-S

Review of system

General

Generalized weakness (+) / fatigue (-)

Febrile sense /chilling sense (- / -)

Weight loss/gain (+ / -) 26kg 감량

Poor oral intake (+) 1끼당 1~2스푼의 식사

HEENT

Headache /dizziness (- / -)

Sore throat (-)

Cardiovascular

Chest pain/palpitation (- / -)

Chest discomfort (-)

Review of system

Respiratory

Cough /Sputum /Rhinorrhea (- / - / -)

약 10일 전 기침과 가래 동반되었었고

PO medication 후 증상 호전되고 있음

Dyspnea /Orthopnea /D.O.E. (- / - / -)

Gastrointestinal

Abdominal discomfort /pain (- / -)

A/N/V/C/D (+ / - / - / - / -)

Review of system

Genitourinary	Dysuria /frequency /urgency (-/-/-) Voiding difficulty (-) Amenorrhea (+) : 6 months
Musculoskeletal	Back pain (-) Abnormal sensation (-)

Physical Examination

- HEENT** : : Not anemic conjunctivae
Anicteric sclerae
Not dehydrated tongue
No palpable neck mass
Palpable subcutaneous bubble on neck
- Chest** : : Clear lung sound w/o crackle
Regular heart beat w/o murmur
Palpable subcutaneous bubble on clavicle and axilla
Petechiae (+) : ant.chest

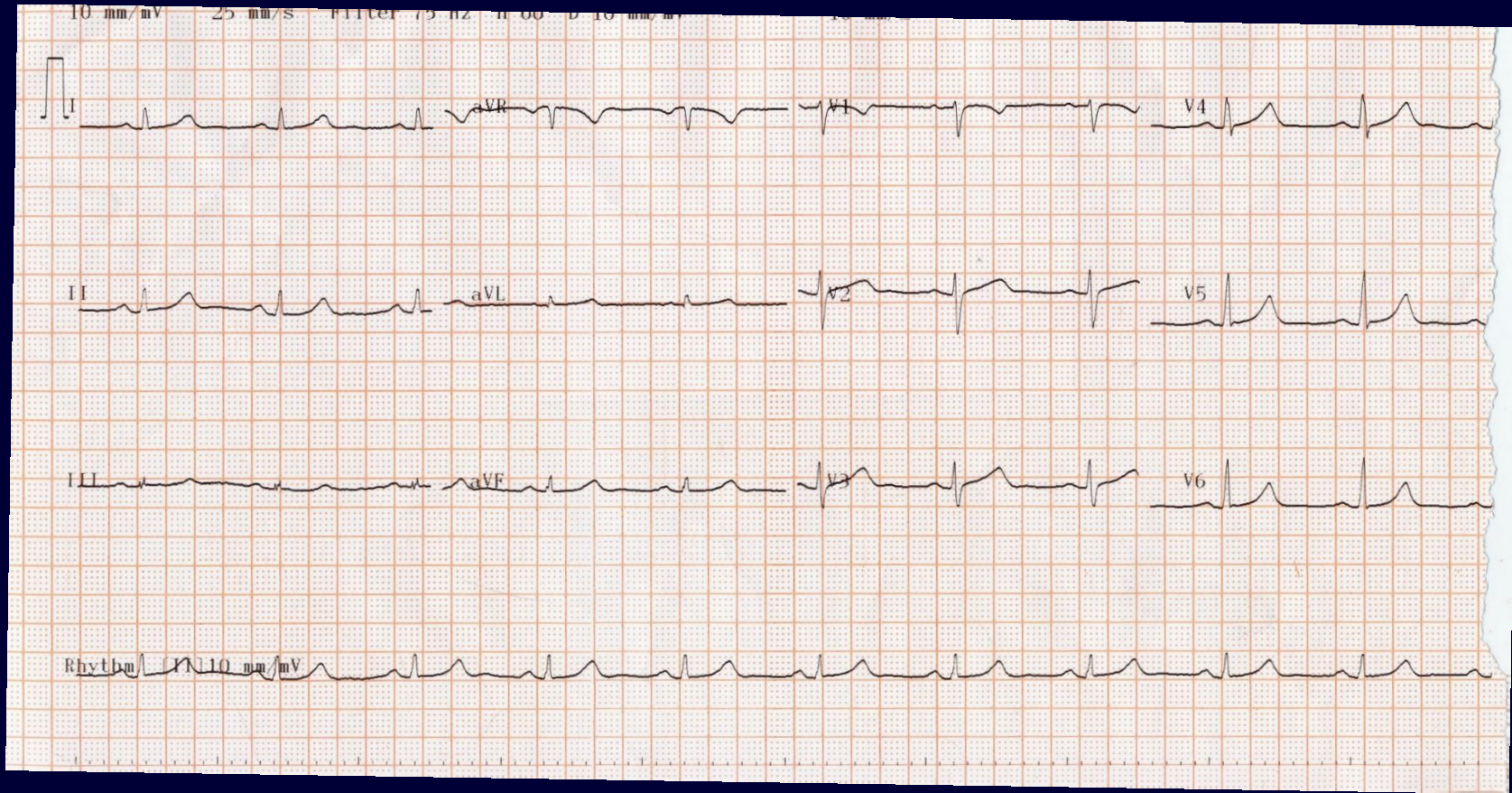
Physical Examination

- Abdomen:** Soft & flat
Hypoactive bowel sound
Tenderness (+) LUQ area
Rebound tenderness (-)
- Back & Ext.:** Pretibial pitting edema (-/-)
CVAT (-/-)
Skin rash (-)
Petechiae (+) : upper & lower extremity
Lanugo (+) : whole body
Itching sense (-)
Acrocyanosis (+) : dark, cold hand & foot

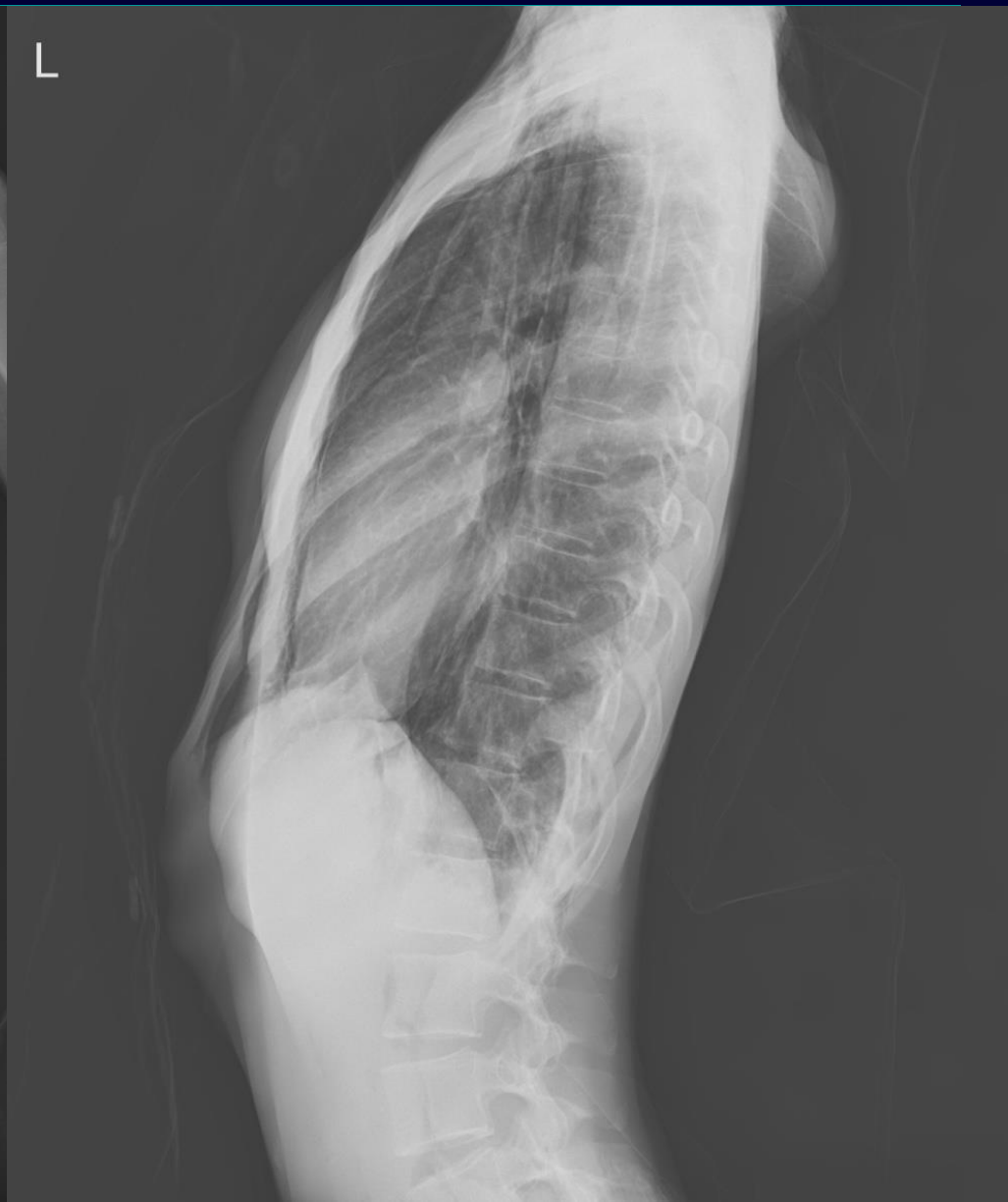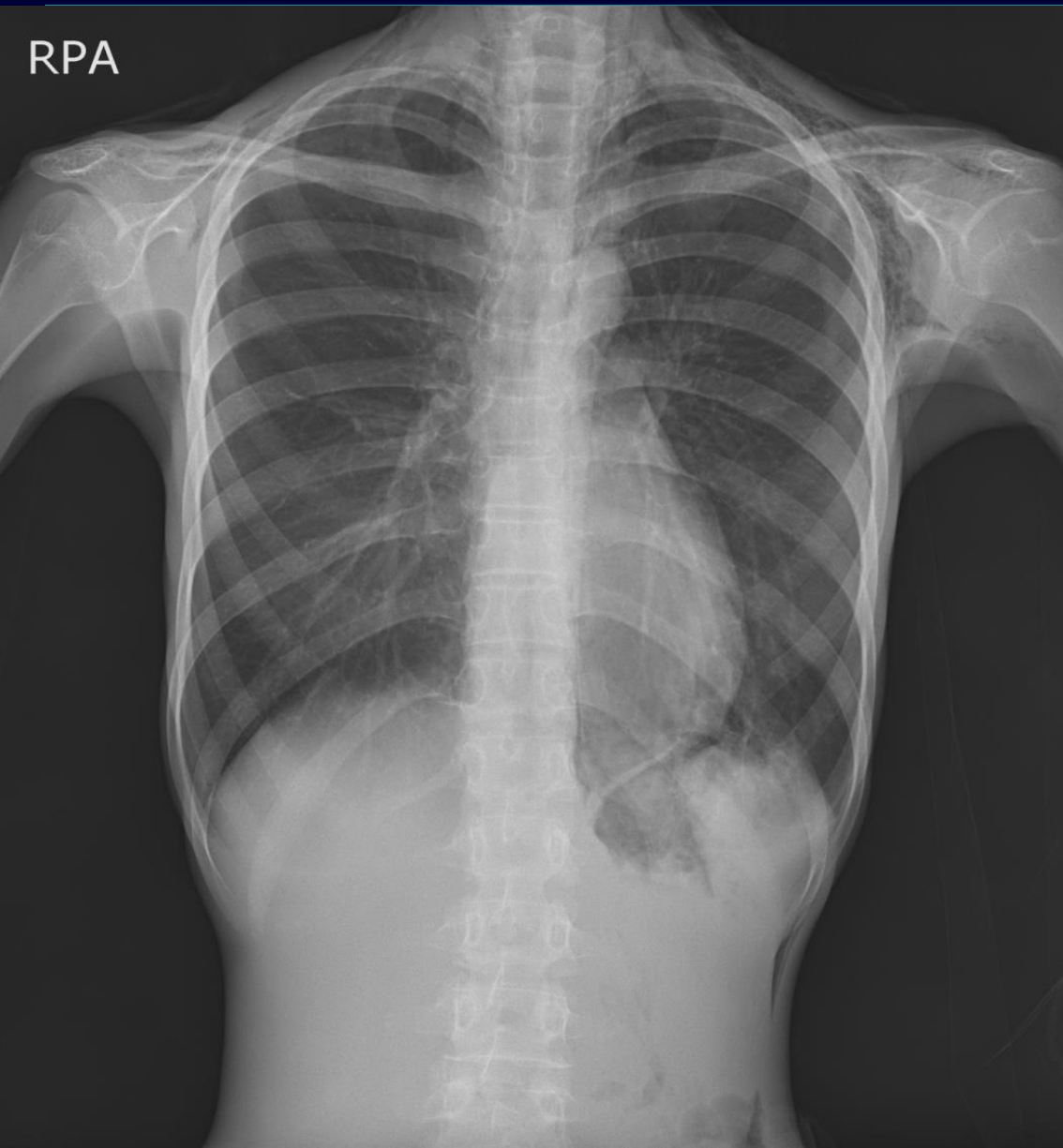
Initial laboratory finding

CBC : 11.8g/dL - 33.6% - 6130 /mm³ - 186,000/mm³
Electrolyte : 137 - 4.3 - 101 mmol/L
BUN/Cr : 28 / 0.74 mg/dL
Glucose : 69 mg/dL
AST/ALT, T.bil : 34 / 50 IU/L, 0.6 mg/dL
CK/LDH: 148 / 352 IU/L (140 ~ 271)
Amylase: 87 U/L (16 ~ 80)
Protein/albumin : 6.2 / 4.1 g/dl
PT/PTT : 13.5 (INR 1.07) / 35.7 sec
CRP : 0.7 mg/dl
T.Cholesterol: 177mg/dl

EKG



Initial chest X-ray

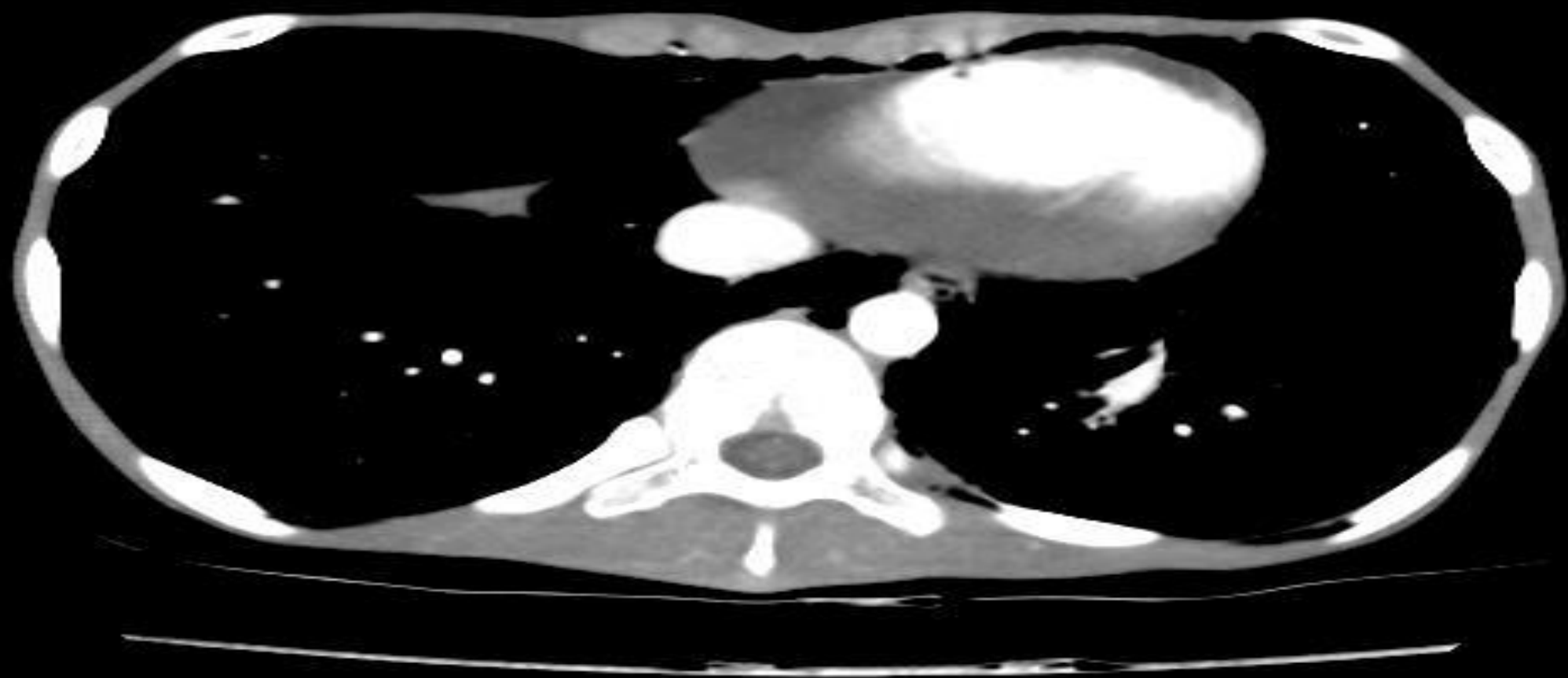


Work up

- ✓ **Chest CT**
- ✓ **Esophagogram**
- ✓ **CXR F/U**
- ✓ **Hormonal study (TFT, FSH, LH, Progesterone)**

Therapeutic plan

- ✓ **Oxygen supply**
- ✓ **Nutritional support**
- ✓ **Psychiatric consultation**



Esophagogram

CHOE SEON YEONG
1819982
14,F

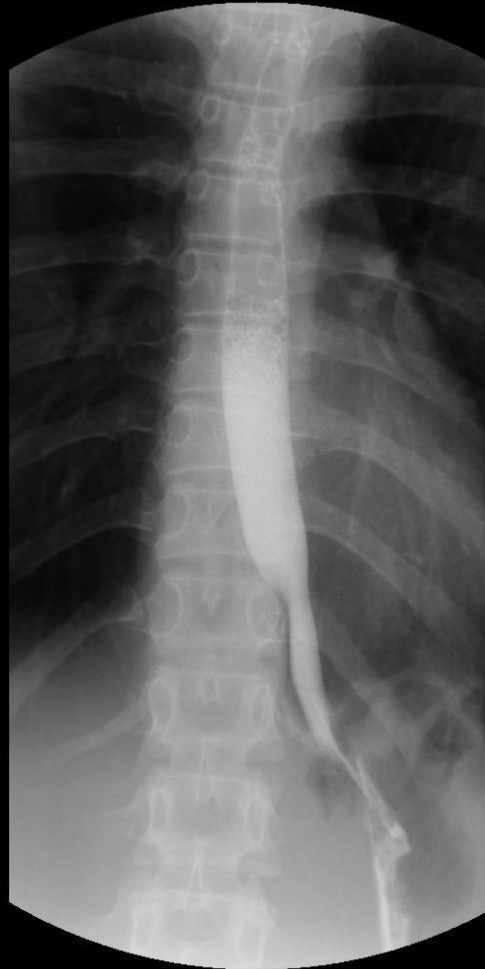
SEOUL PAIK HOSPITAL
12-May-14
09:52:39

Esophagogram (Gastrografin)
673-3-1

Esophagus

SID 1110
AP

TILT 89



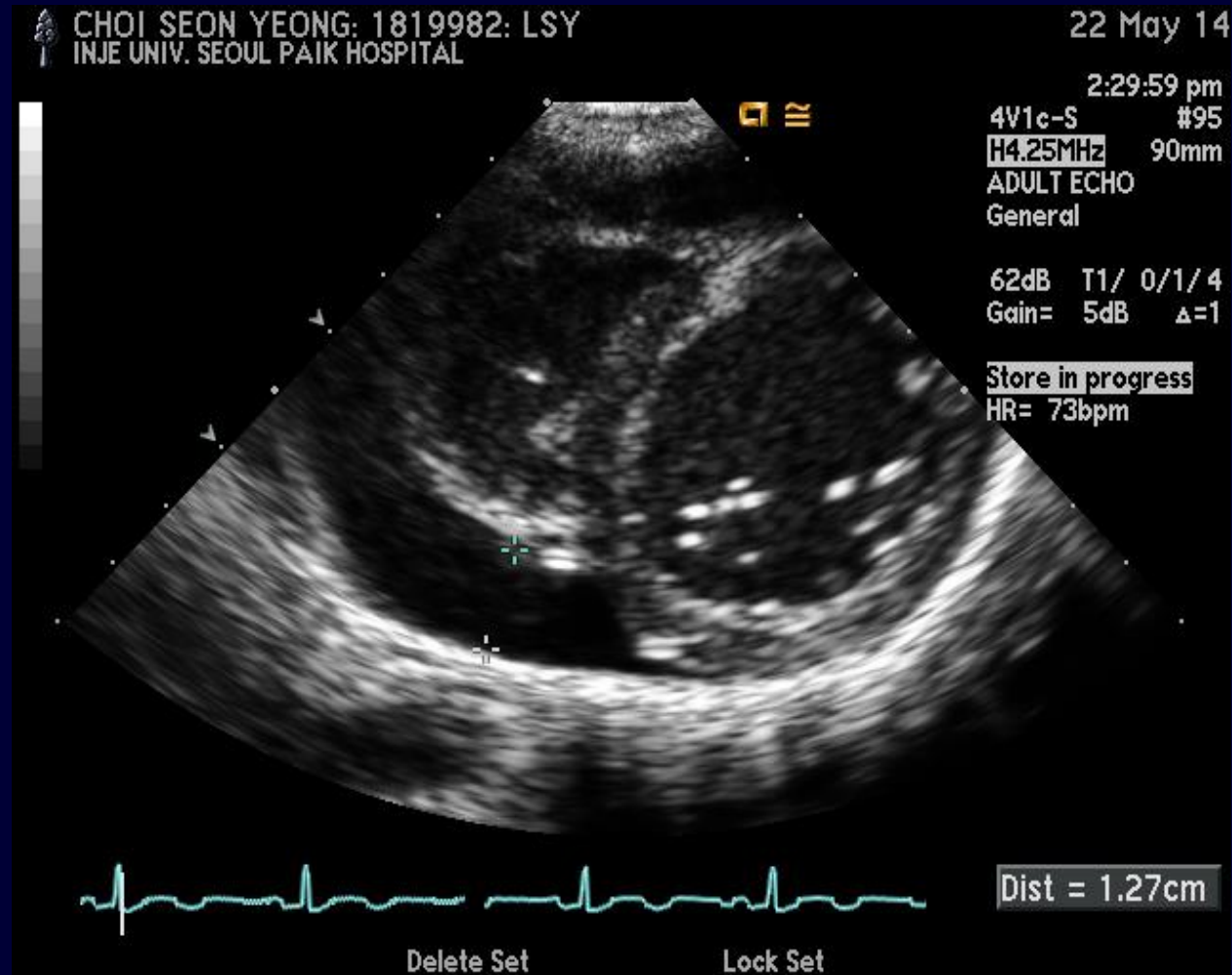
GAMMA M2
EDGE BP1
Medium
16"
65 kV
160 mA
9.7 ms

DCF AA
SHUTTERS
DR:Sequence esopagus 2f/s

W2: 1364
W1: -62

No abnormality on esophagogram

TTE



Small amount pericardial effusion

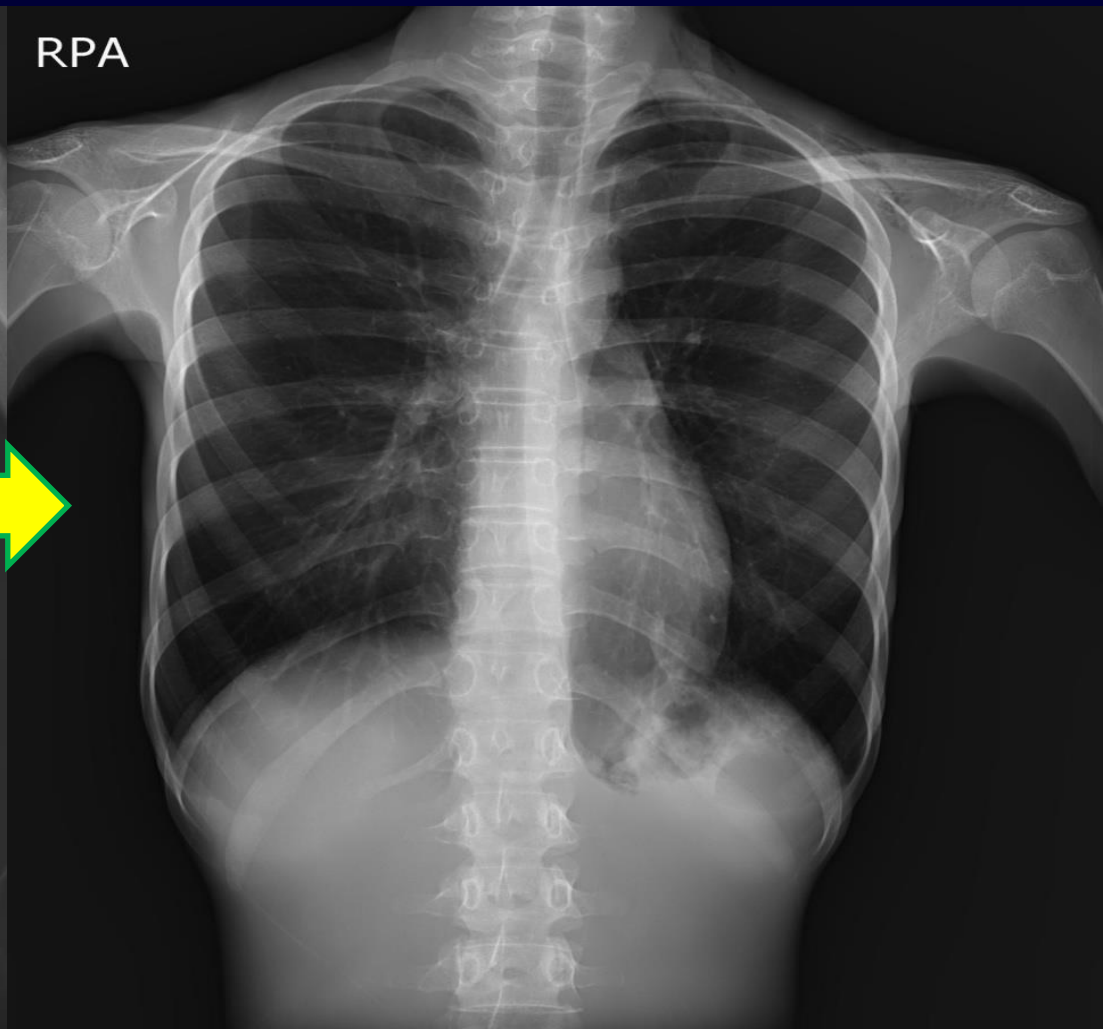
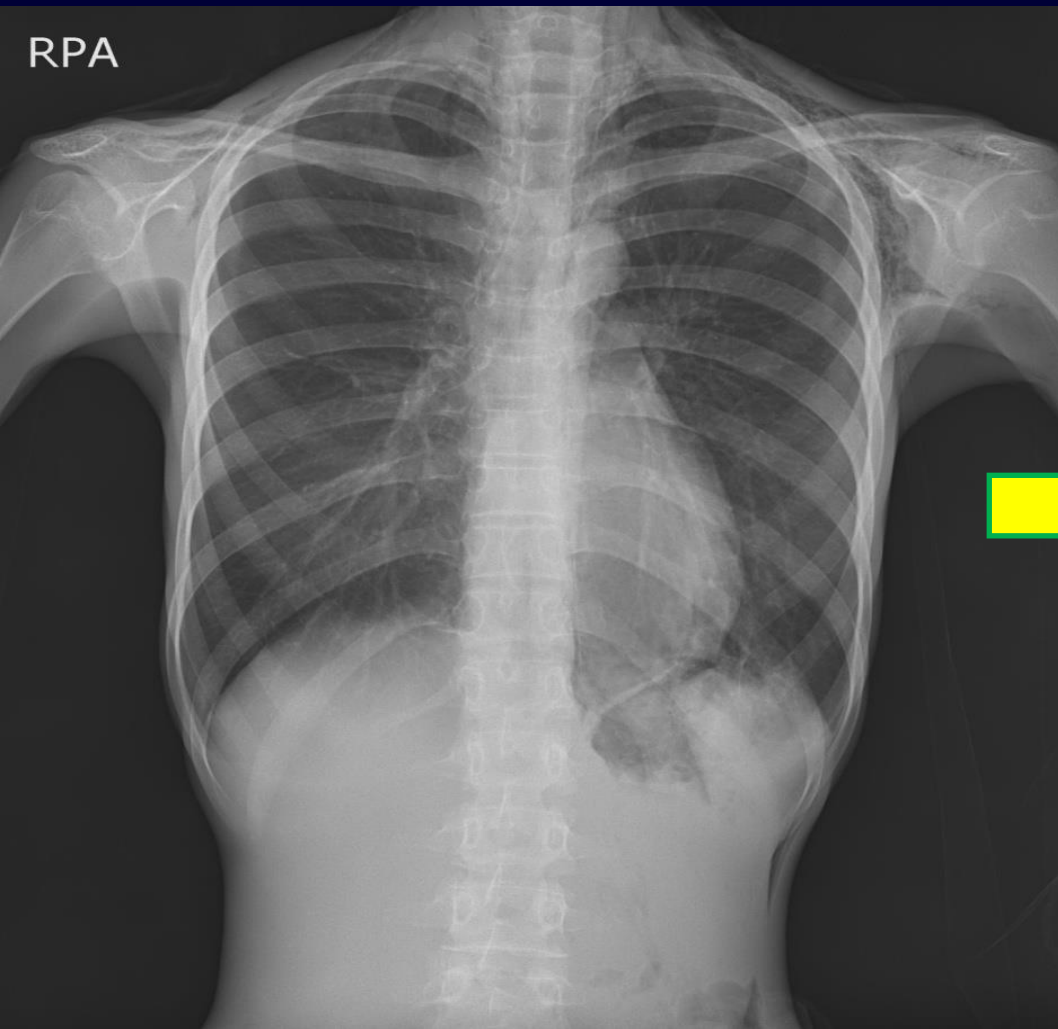
Hormonal study

Laboratory		
Sex hormone	FSH	0.8 mIU/ml
	LH	<0.07 mIU/ml
	Estradiol	6.4 pg/ml
TFT	TSH	4.571 μ IU/ML
	Free T4	0.83 ng/dL

HD #7

Admission Chest PA

HD7 Chest PA



Final diagnosis

Spontaneous pneumomediastinum
& diffuse soft tissue emphysema
in patient with anorexia nervosa