

Point of care **Ultrasound**

for **lung exam as monitoring tools**

Kyung Soo Chung

Division of Pulmonary & Critical Care Medicine
Department of Internal Medicine
Yonsei University College of Medicine
Severance Hospital

학습 목표

1. "Lung Ultrasound"의 기본 원리와 사용방법을 알아야 한다
2. "Lung Ultrasound Score (LUS)" 를 측정하고 계산할 수 있다
3. LUS를 통해 모니터링할 수 있는 질환을 이해한다
 - ①. 속(shock) 에서 수액 치료의 결정
 - ②. 기계호흡관련 폐렴에서 치료 반응 평가
 - ③. 급성호흡곤란증후군에서 호기말양압의 적용 평가
 - ④. 인공호흡기 이탈에서 평가

초음파 기계 설정 및 probe 선택

- 기계 설정 : no harmonic (THI ; tissue harmonic imaging)
- Probe (5MHz) : micro-convex or curve-linear probe



검사 부위

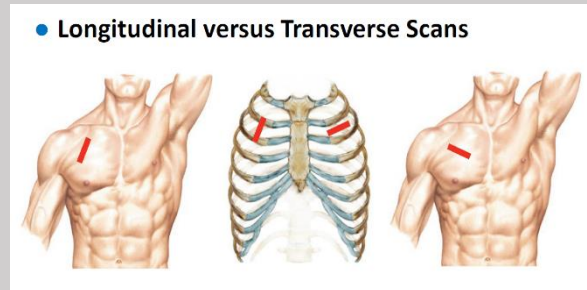
- BLUE point : fast & simple
- Semi-quantitative measure

환자 자세

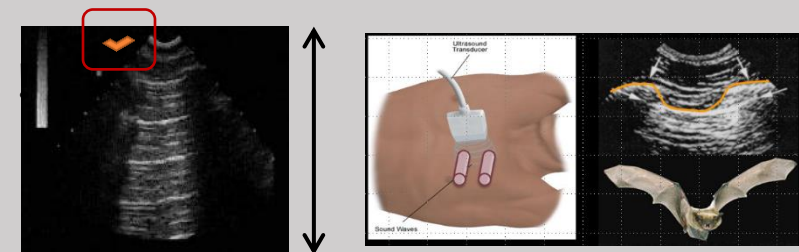
- Supine (B-line)
- Reclined at 45 degree (pleural effusion)

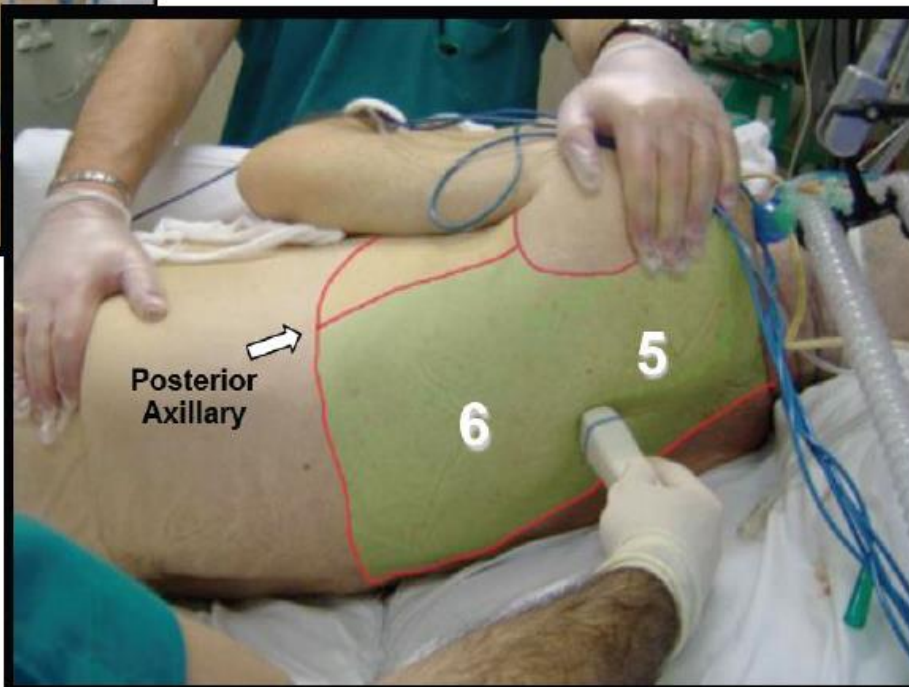
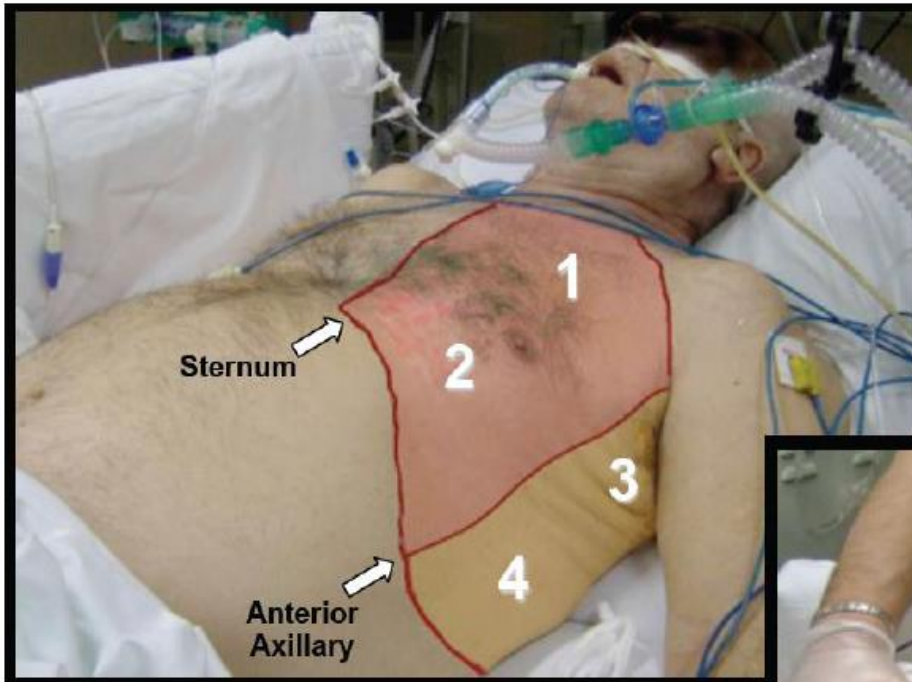
Initial basic view

- Perpendicular to the rib
- Marker to Left of screen
- Depth : 10cm
- Bat sign

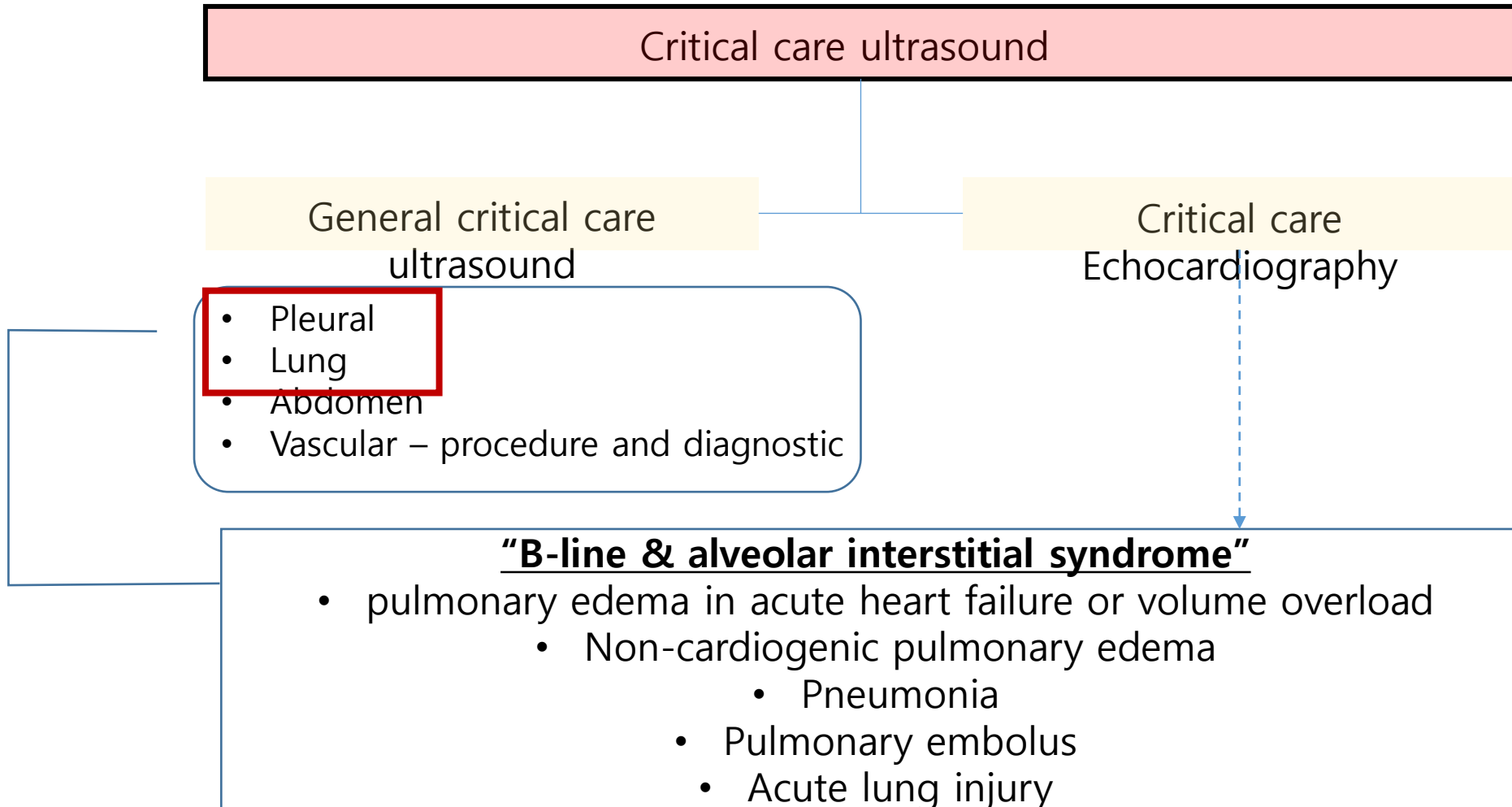


Lung : 4~7MHz



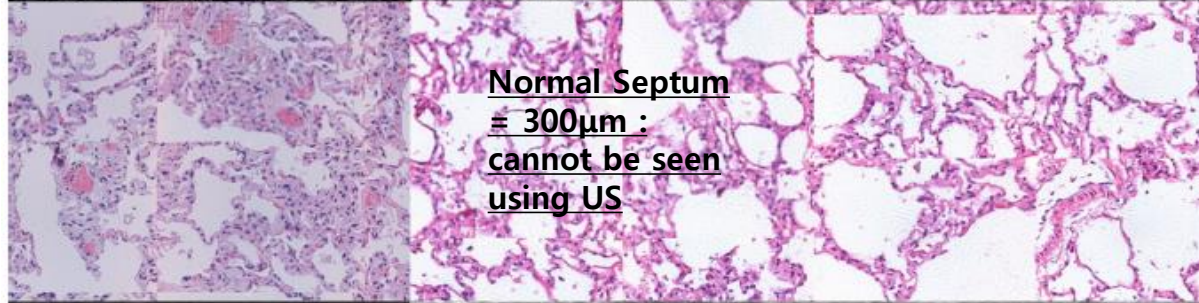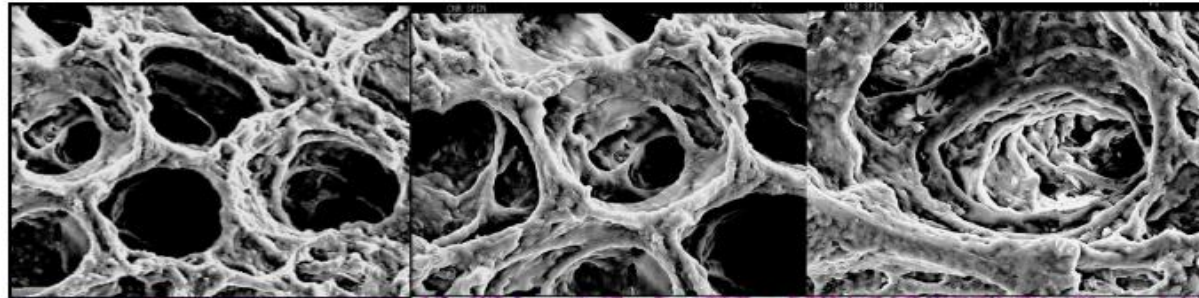

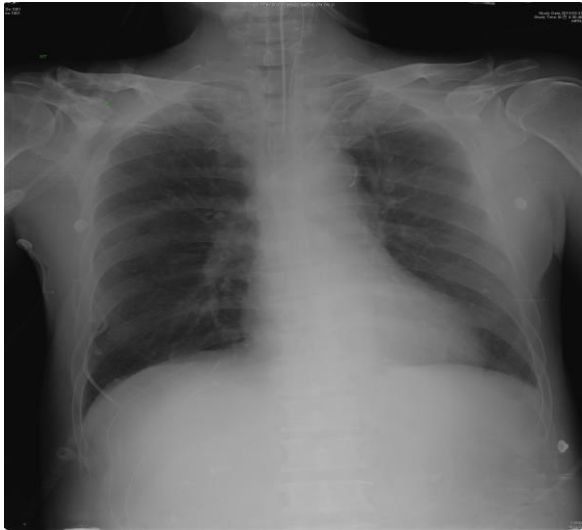
Branches of critical care ultrasound

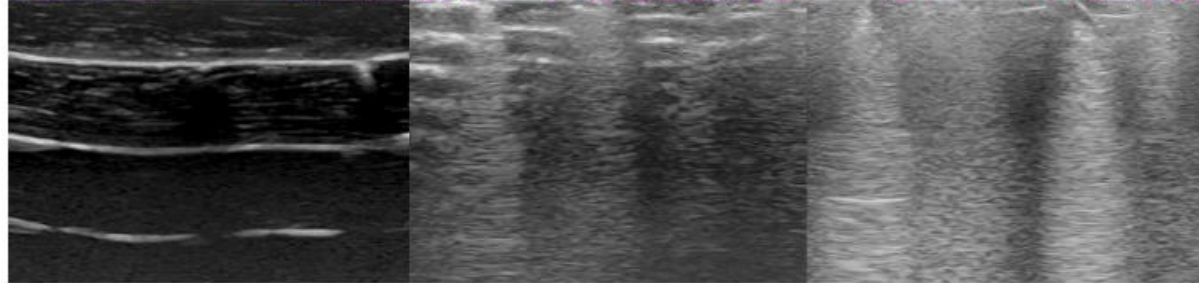


A-line & B-line

Reverberation artifact Air-fluid interface in the interstitial space



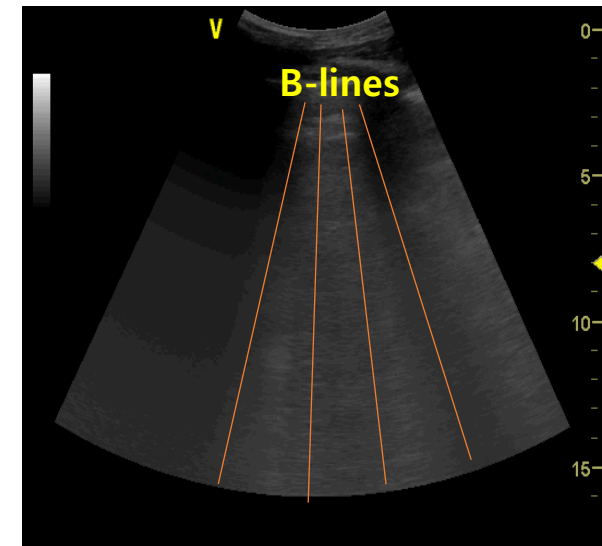
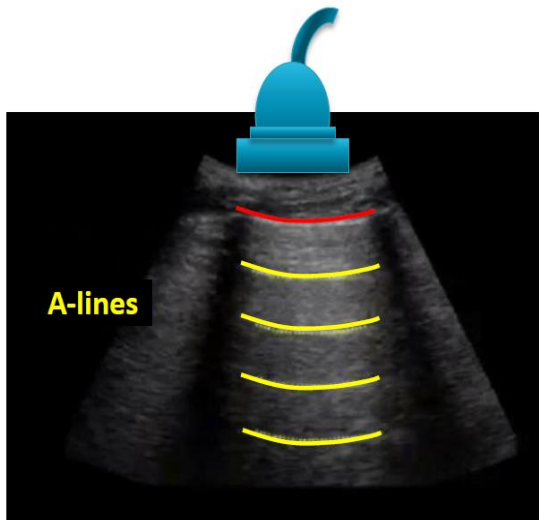
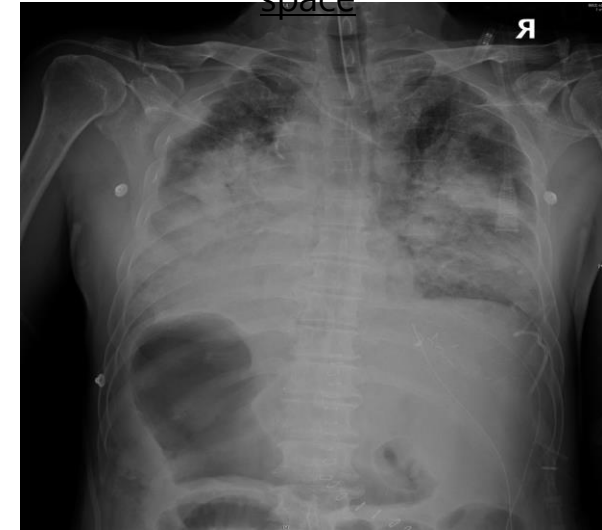
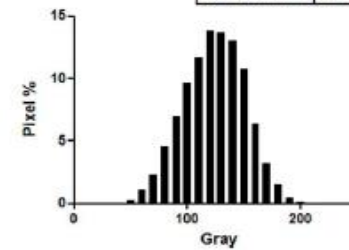
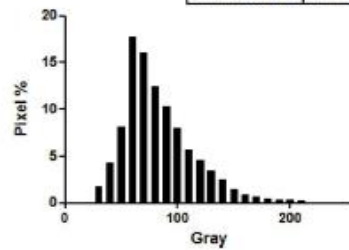
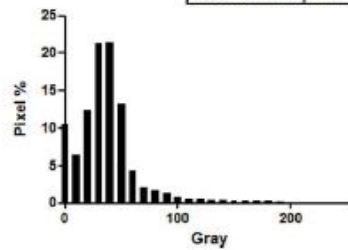
Normal Septum
 $\approx 300\mu\text{m}$
 cannot be seen using US



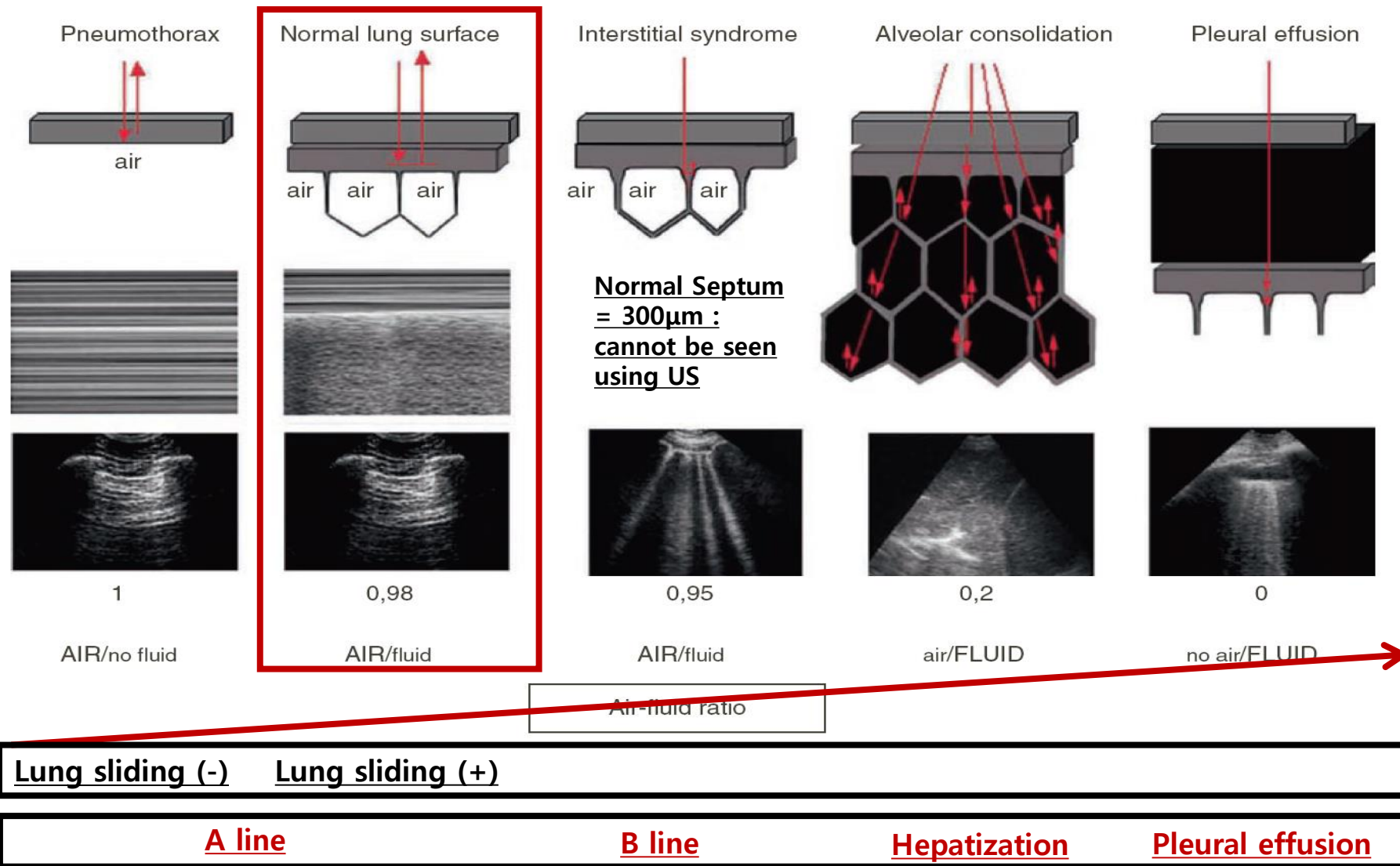
Mean	37.62
Std. Deviation	30.07

Mean	83.14
Std. Deviation	31.93

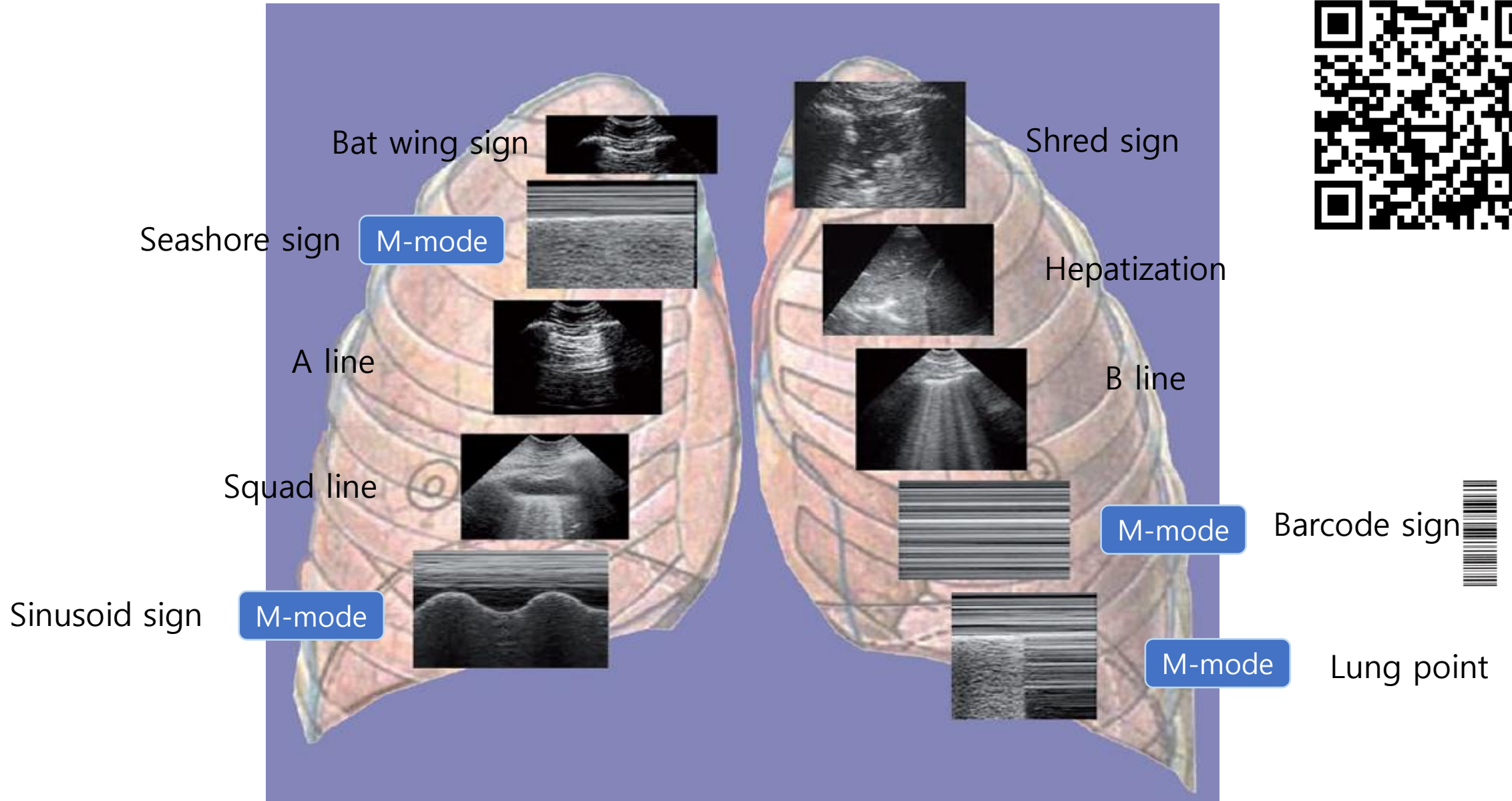
Mean	123.2
Std. Deviation	26.89



Transition from A to B or from B to A

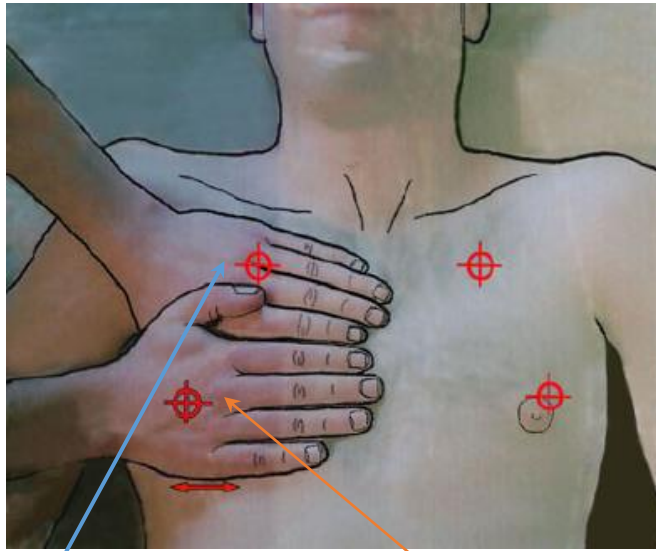


Terminology



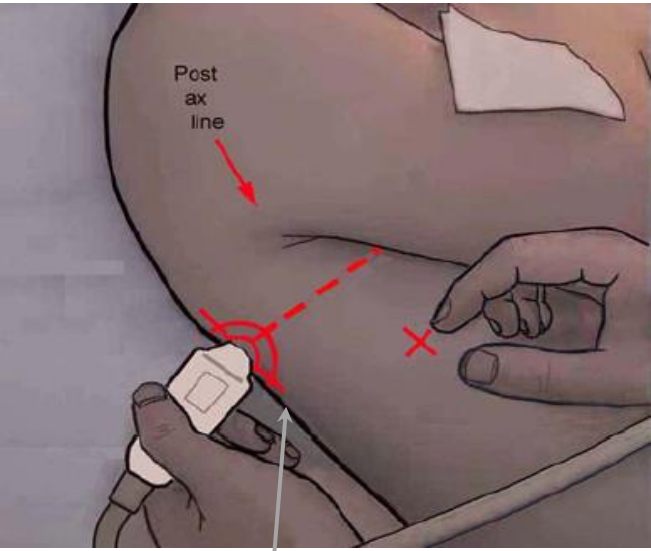
Lung & Pleural Ultrasound

- 검사부위 : **BLUE points** & Quantitative Measure Points



Upper Blue Points

Lower Blue Points



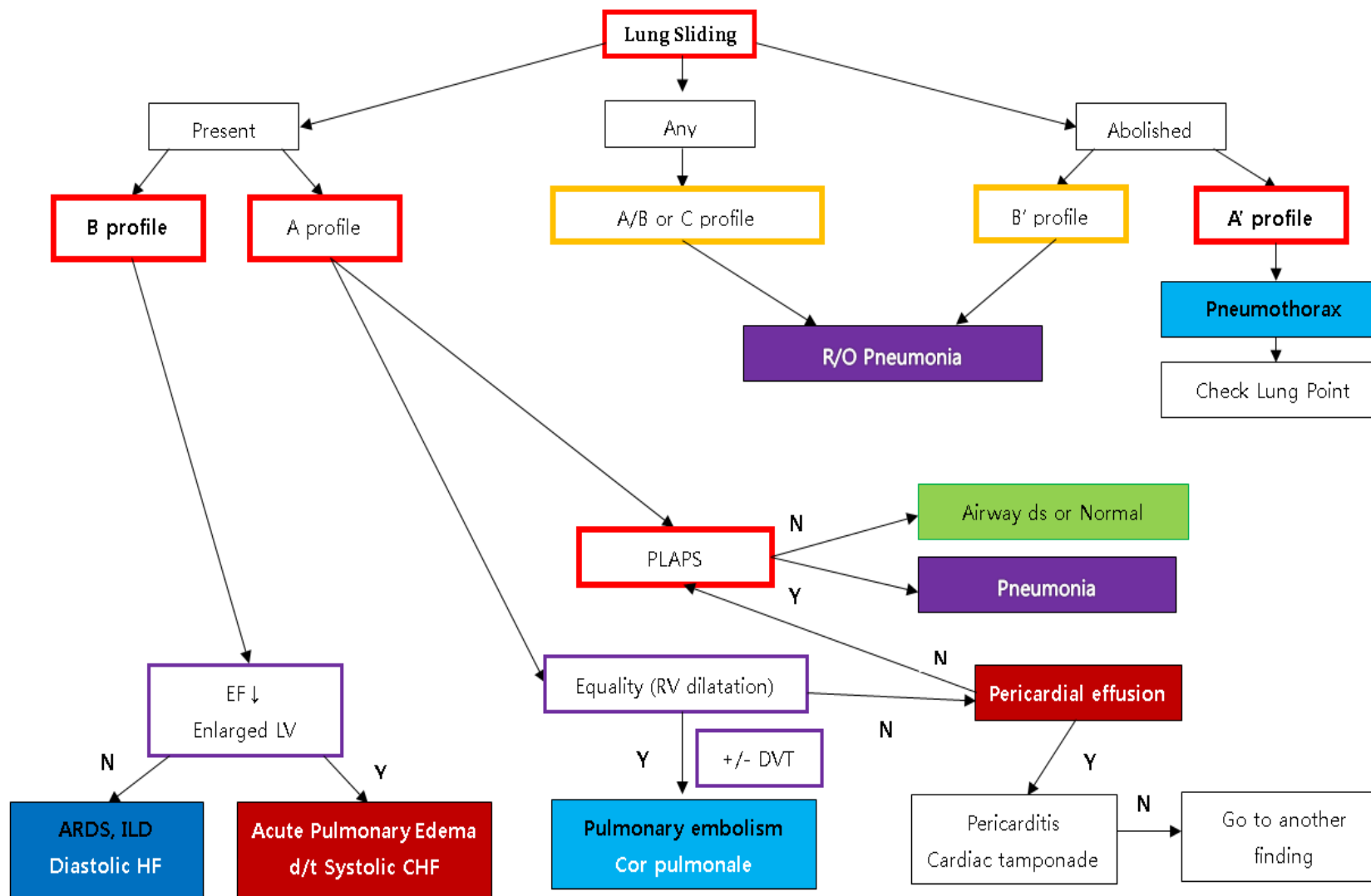
PLAPS (Posterior and/or Lateral, Alveolar and/or Pleural Syndrome)

※ BLUE : Bedside Lung Ultrasound in Emergency ; by *Lichtenstein*

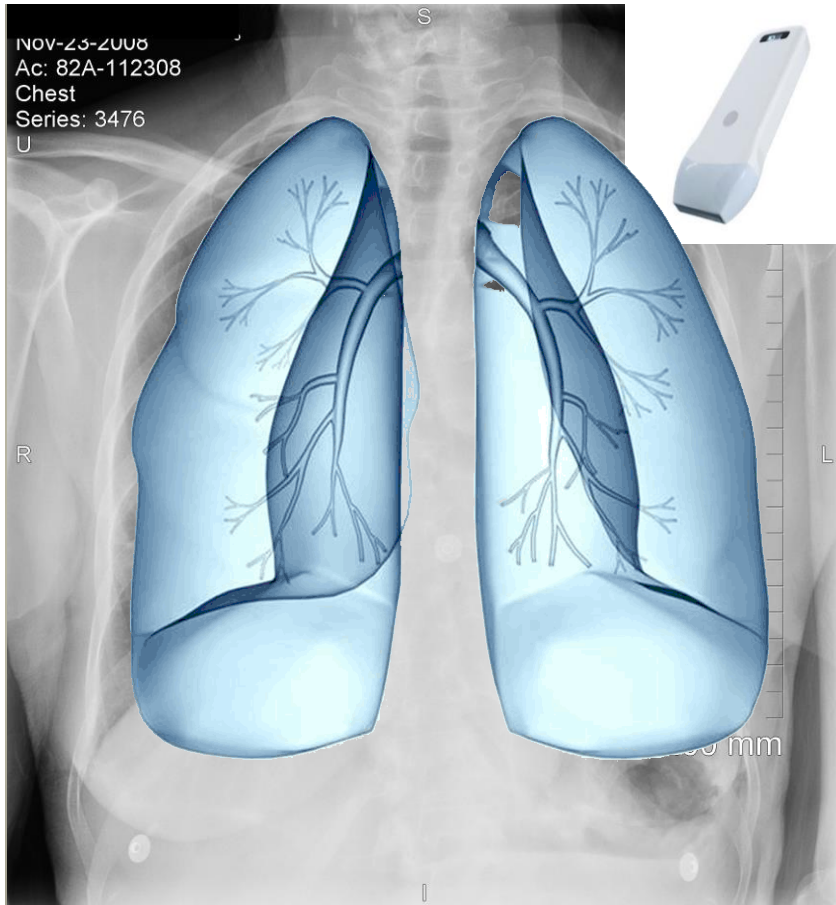
Lung ultrasound: Diagnostic algorithm

BLUE protocol

Ultrasonography in Acute Respiratory Failure (Modified BLUE)



Lung Ultrasound Score 계산법



질환 or 임상 상황	Pathophysiology	폐초음파소견
DILD ARDS	Interstitial thickening	B or B'-profile
ARDS Cardiac/pulmonary edema Fluid therapy Ventilator weaning	Interstitial edema	B-profile
Pneumonia	Consolidation/effusion	B or B' profile, C-profile

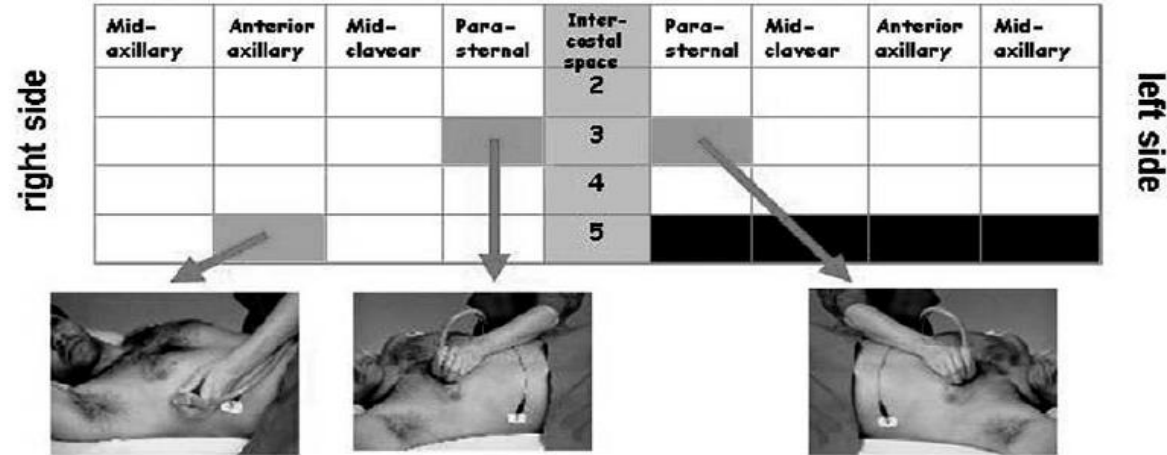
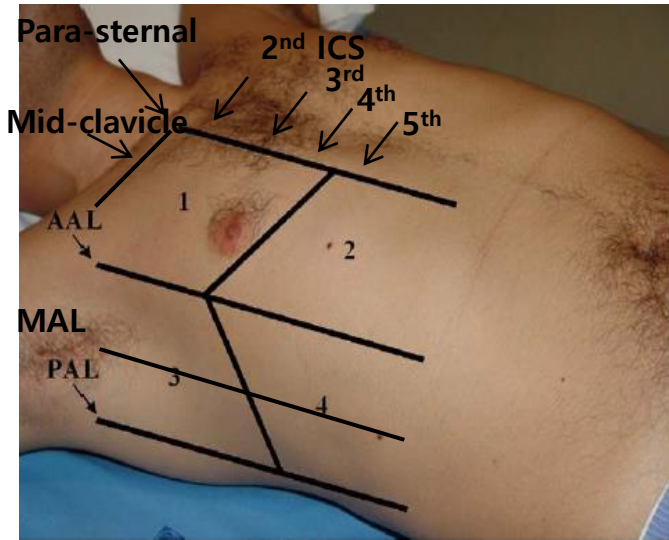
1. Lung ultrasound score는 "alveolar-interstitial syndrome" 의 초음파 소견이다

Alveolar-interstitial syndrome was defined according to the Fleischner Society's recommendations as the presence of one or the combination of ground-glass opacities, consolidation, reticulation, and septal thickening.

2. 모니터링이란 의학적 진단 후 치료 혹은 처치가 원하는 결과를 달성하고 있는지 평가하는 것으로, 2회 이상의 검사 비교를 필요로 한다

- 검사부위 : BLUE points & **Quantitative Measure Points I**

Landmark

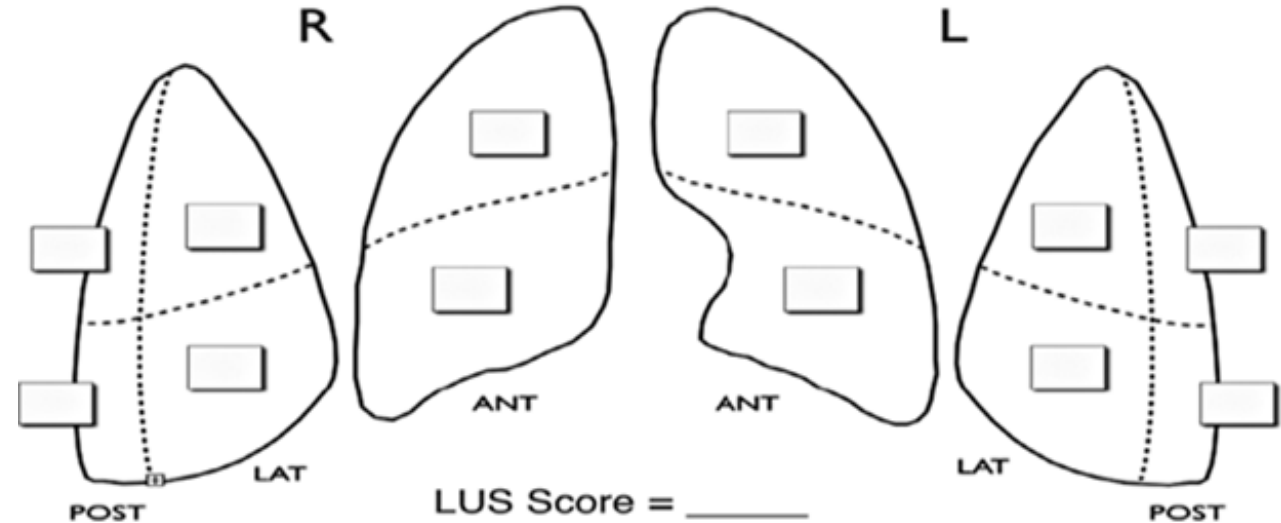
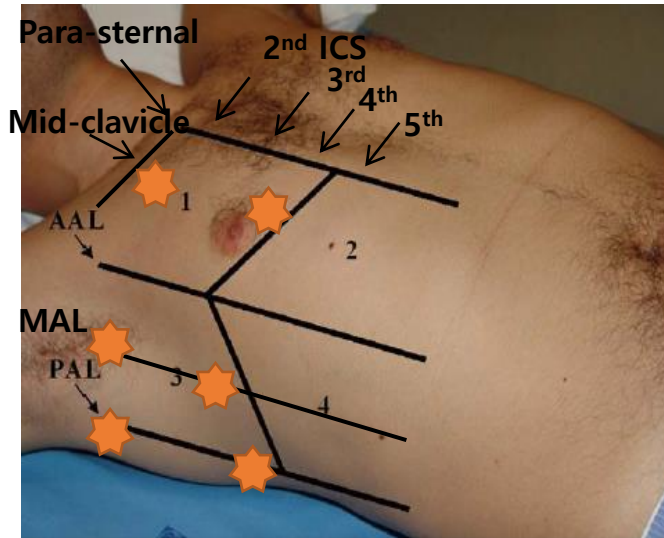


Comet score : overall number of the ultrasound lung comets **B line**


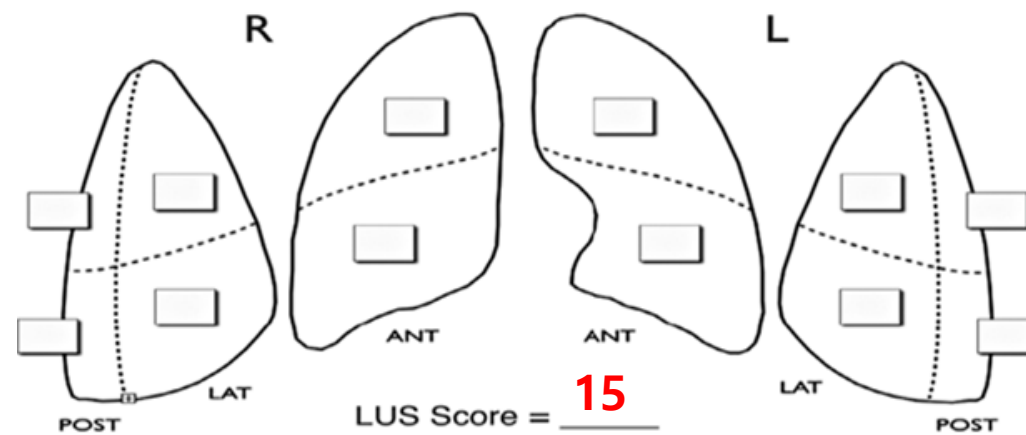
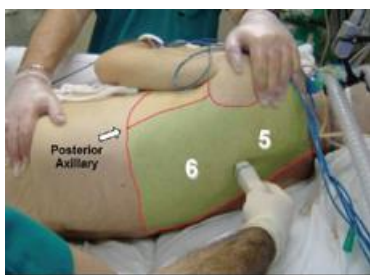
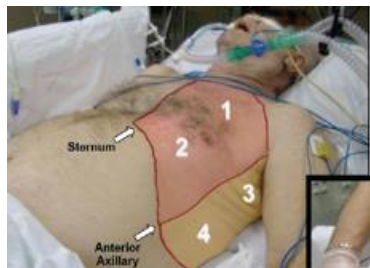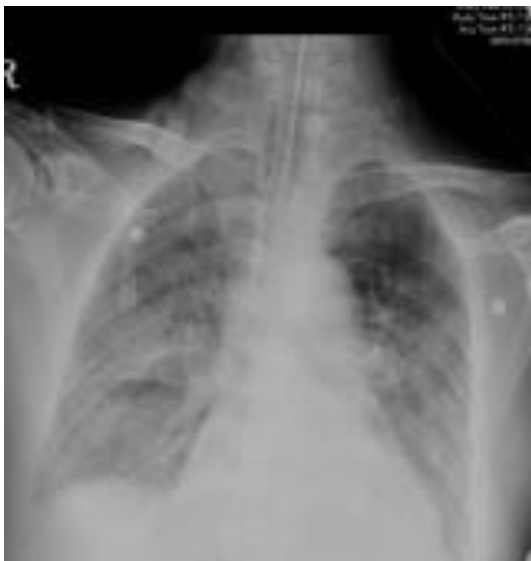
Points	Number of ULCs	Extravascular lung water
0	<5	No signs
1	5-15	Mild degree
2	15-30	Moderate degree
3	>30	Severe degree

- 검사부위 : BLUE points & **Quantitative Measure Points II**

Landmark

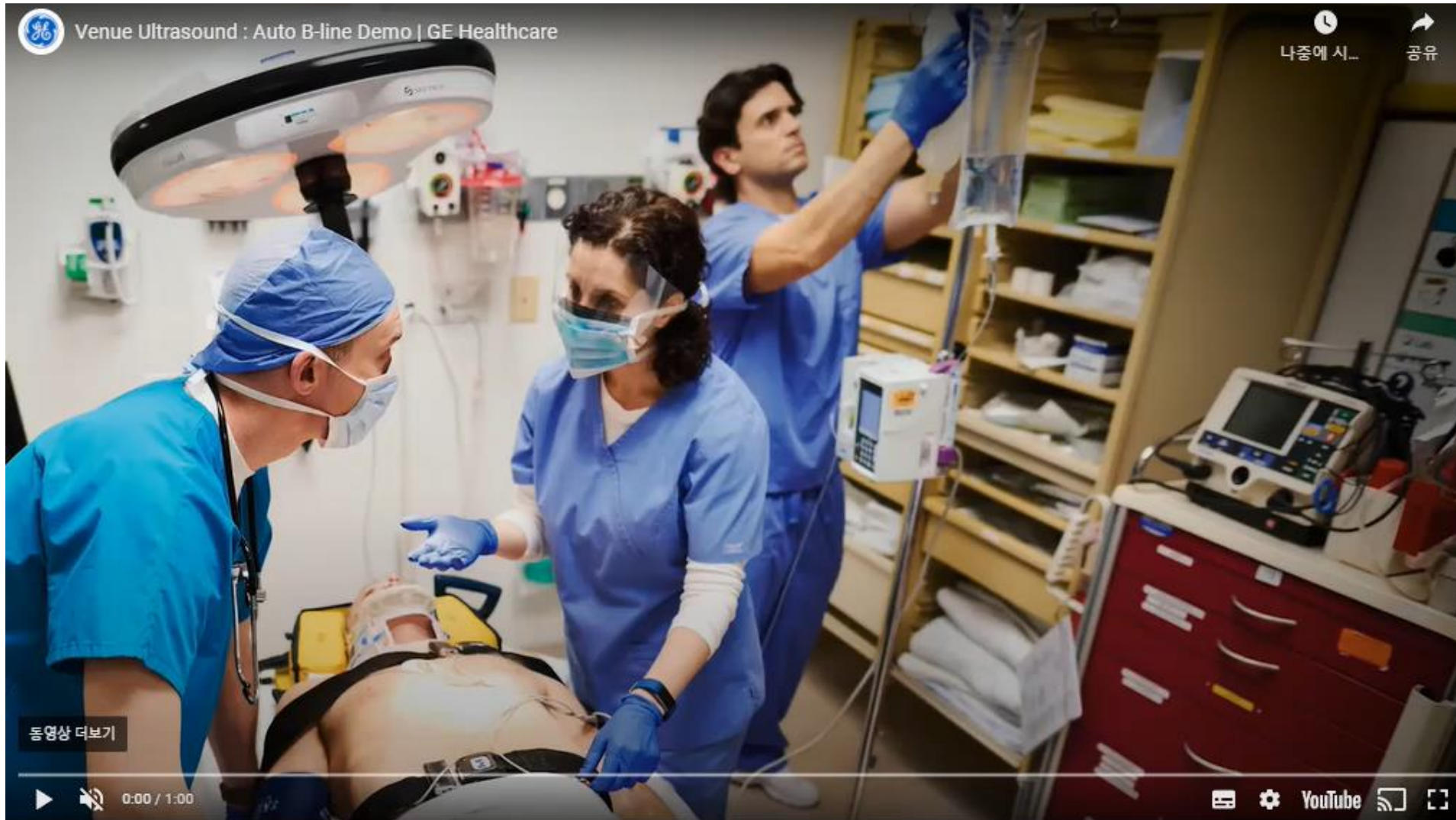


Points	Degrees of lung aeration	Patterns
0	Normal aeration	Horizontal A-lines (or no more than two B-lines)
1	Moderate loss of aeration	Multiple B lines , either regularly spaced (7mm apart), or irregularly spaced and even coalescent but only visible in a limited area of the intercostal space
2	Severe loss of aeration	Multiple coalescent B-lines , in prevalent areas of the intercostal spaces and observed in one or several intercostal spaces
3	Complete loss of aeration	Lung consolidation , with or without air bronchograms



Unsolved problem: standardization & Inter-observer variation → Reliable & objective results

Automation of B-line counting



Unsolved problem: standardization & observer variation → Reliable & objective results

Deep learning using ultrasound

Automated Lung Ultrasound B-Line Assessment Using a Deep Learning Algorithm

IEEE Trans Ultrason Ferroelectr Freq Control. 2020 Nov;67(11):2312-2320

Yale New Haven Hospital Emergency Department
Philips SPARQ ultrasound (total 2415 clips) – 85:15 (Training:Test)

B-line identification by Deep learning

- Recognition (binary)
- Semi-quantitative measurement (severity rating) (multiclass)

Transducer (linear, curvilinear, phased array) adjustment

		Expert	
		0	1
DL	0	45	4
	1	2	49

AUC = 0.97
Kappa unweighted :
0.88
Overall accuracy =
94%

		Expert				
		0	1	2	3	4
DL	0	21	8	1	0	0
	1	2	7	2	0	0
	2	2	6	13	7	2
	3	0	0	3	11	8
	4	1	0	1	1	4

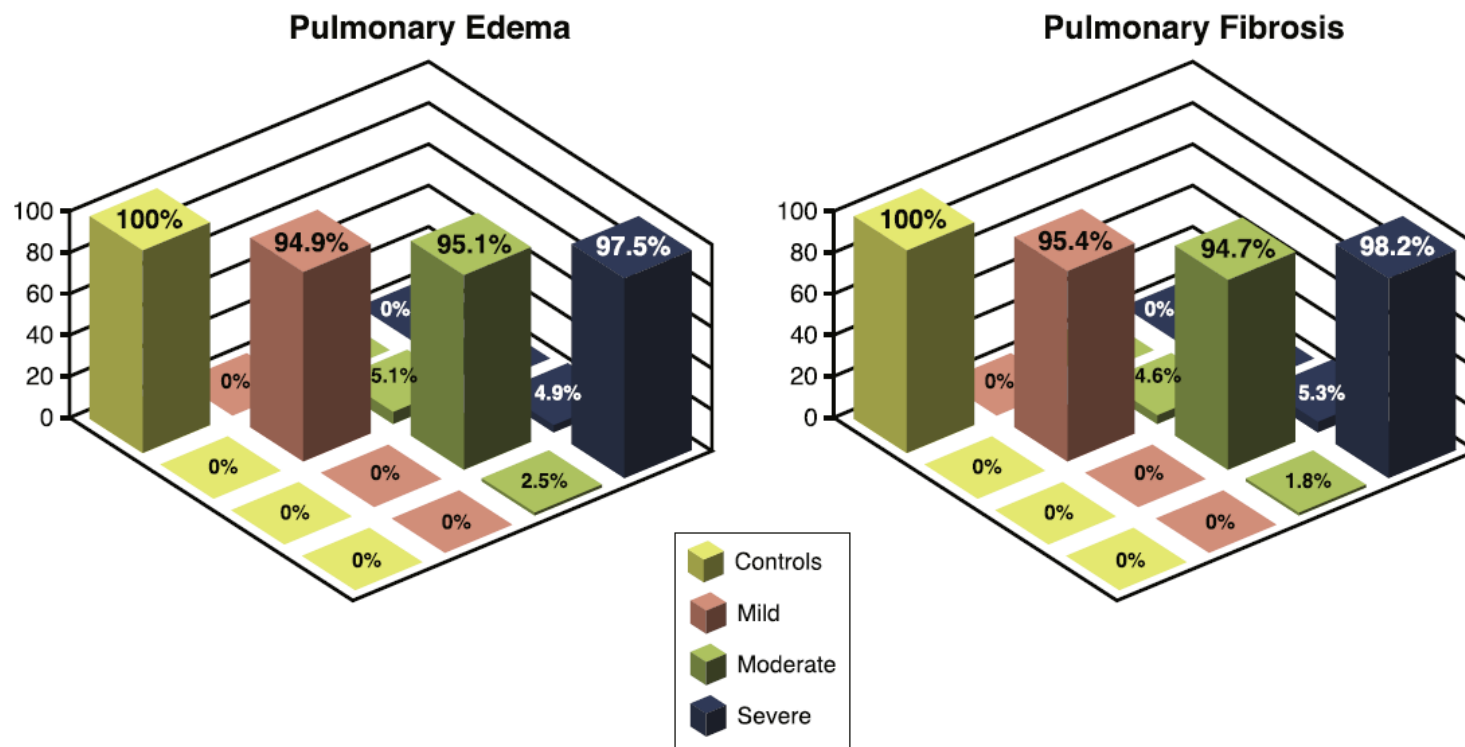
Kappa linear weighted : 0.65
Overall accuracy (perfect match) =
56%

Unsolved problem: low specificity - pulmonary fibrosis vs. pulmonary edema

Deep learning using ultrasound

A Soft Computing-based B-line analysis for Objective Classification of Severity of Pulmonary edema and fibrosis

JACC : Cardiovascular imaging, 2015 (8)4; 493-8



Unsolved problem: Accessibility

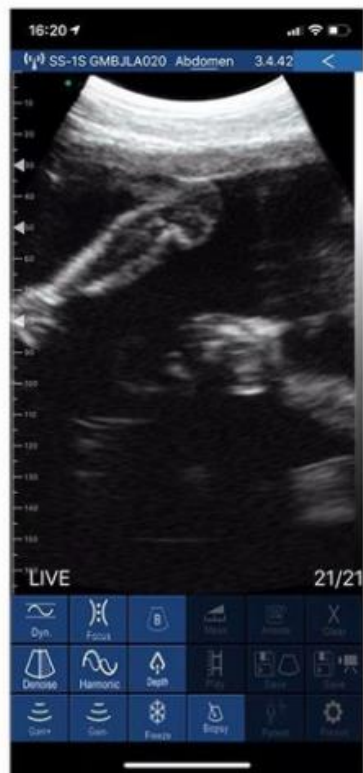Portable & wireless ultrasound scanner

Gadgets > Office > Office Electronics > Scanners

Overview

Related

Shop products related to this item



Hot Selling Portable WIFI Wireless Ultrasound Scanner Convex Array Probe 3.5Mhz 80 Elements 16 Channel

★★★★★ (1 review)

₩1,270,041

Size:

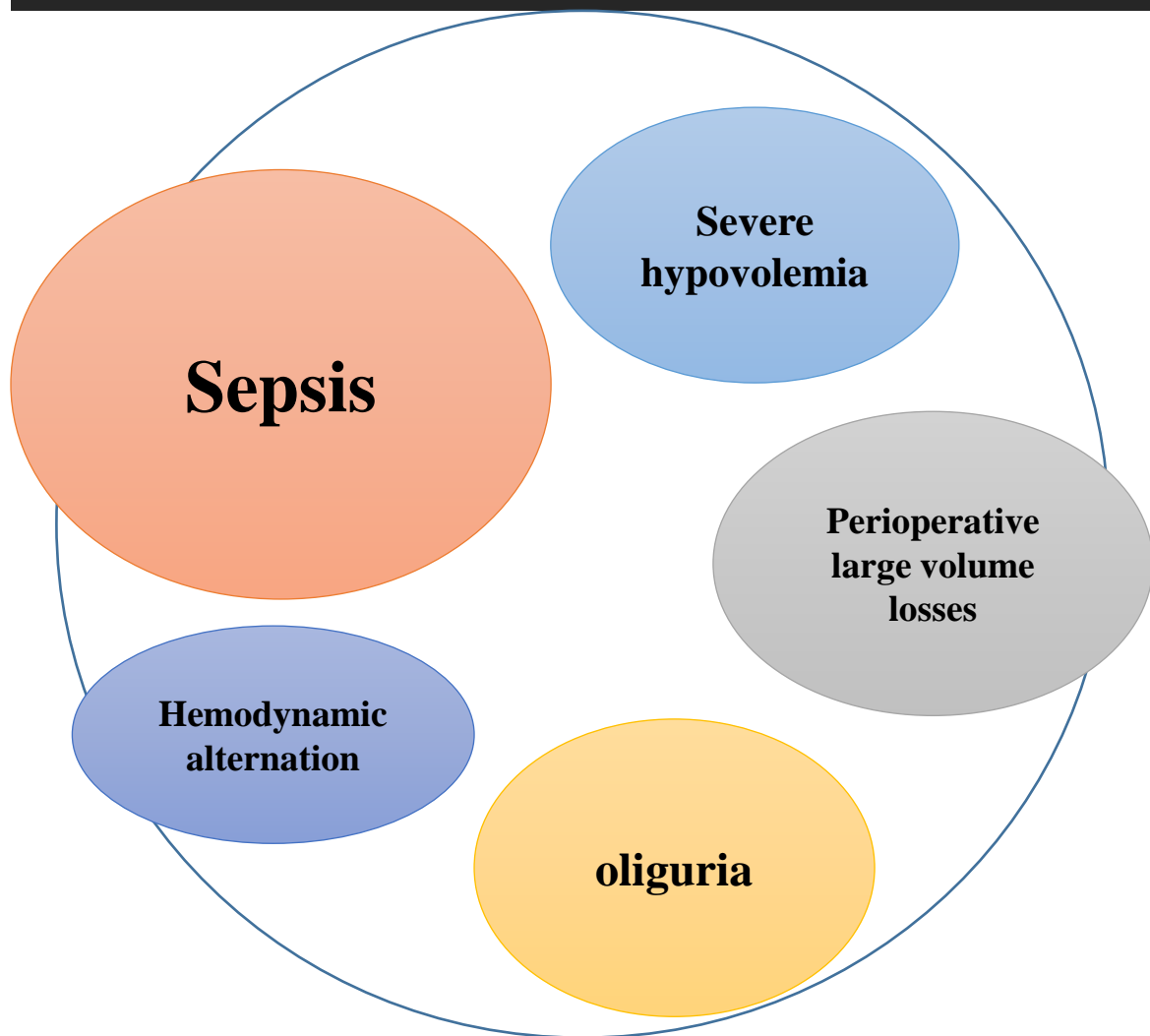
Select Size

Buy

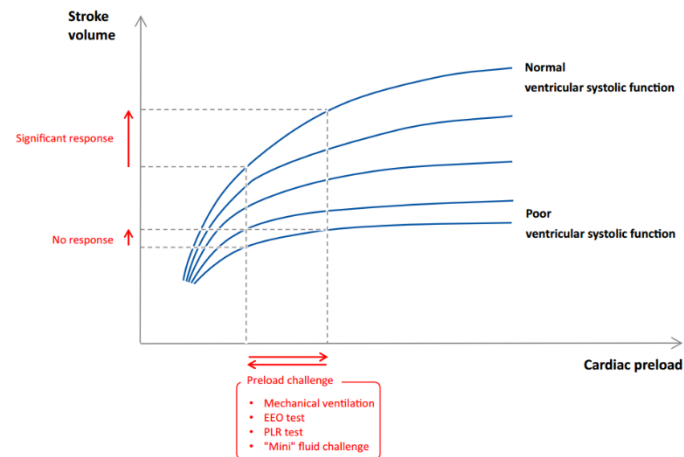
♡ Add to Wishlist

실제 적용

①. 속 (shock) 에서 수액 치료의 결정

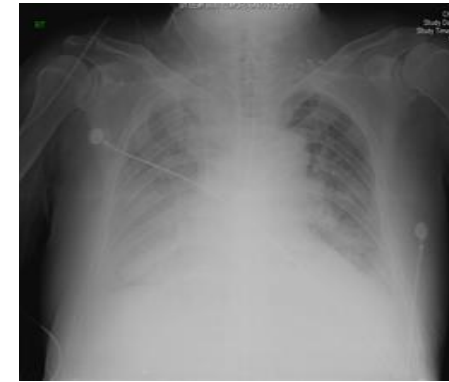
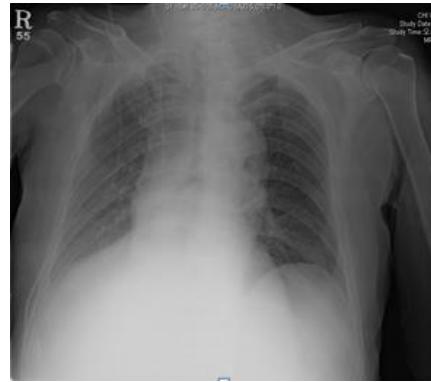
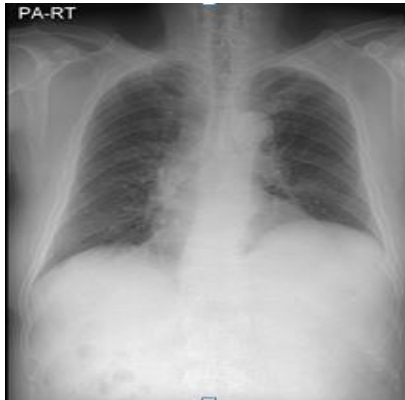Fluid bolus therapy: "Knowing the Risk"

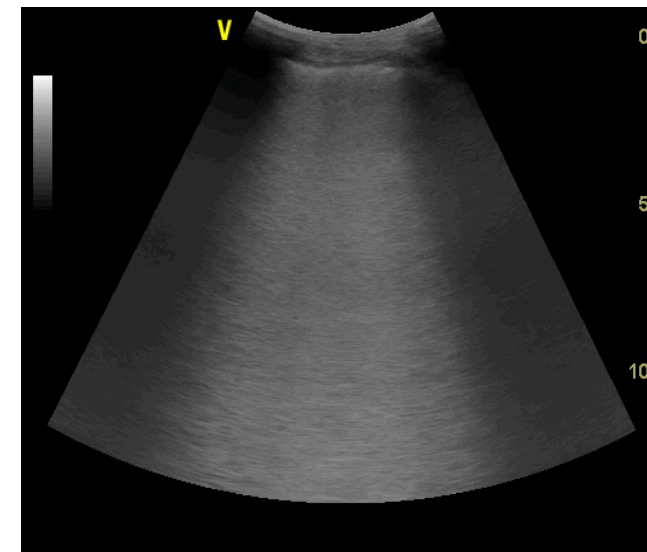
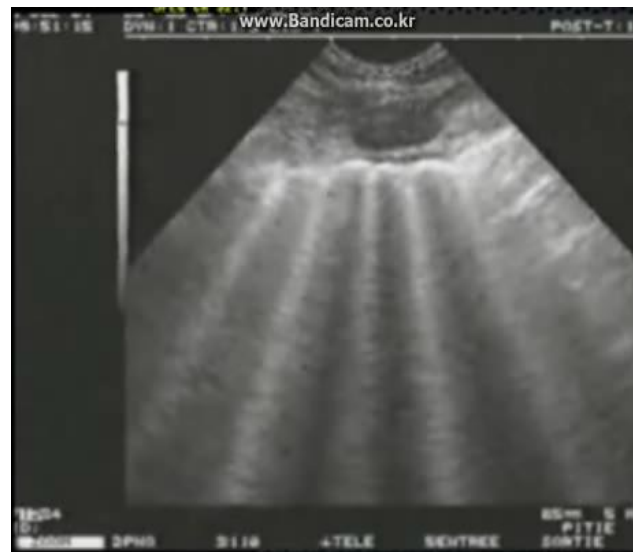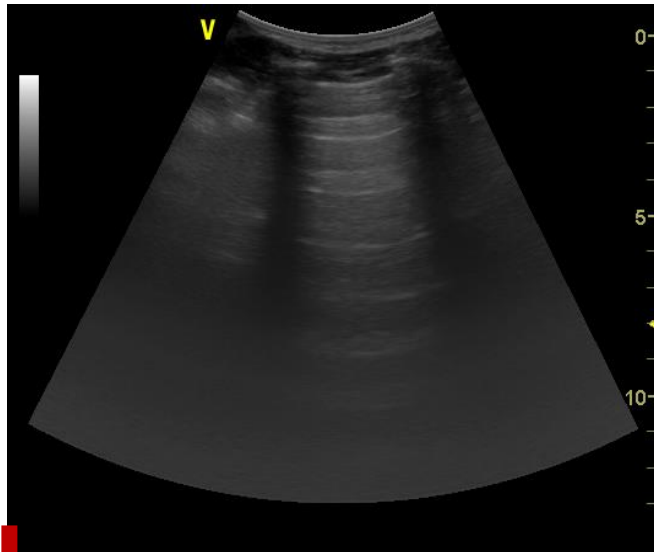


Heart function	Intravascular volume	Fixed dose fluid therapy	Results
N	N		N or pul edema?
N	↓		Improved? Or pul edema?
↓	N		Pul edema?
↓	↓		Pul edema?

Treatment : Fluid management



Fluid administration



+ Echo, IVC, renal perfusion

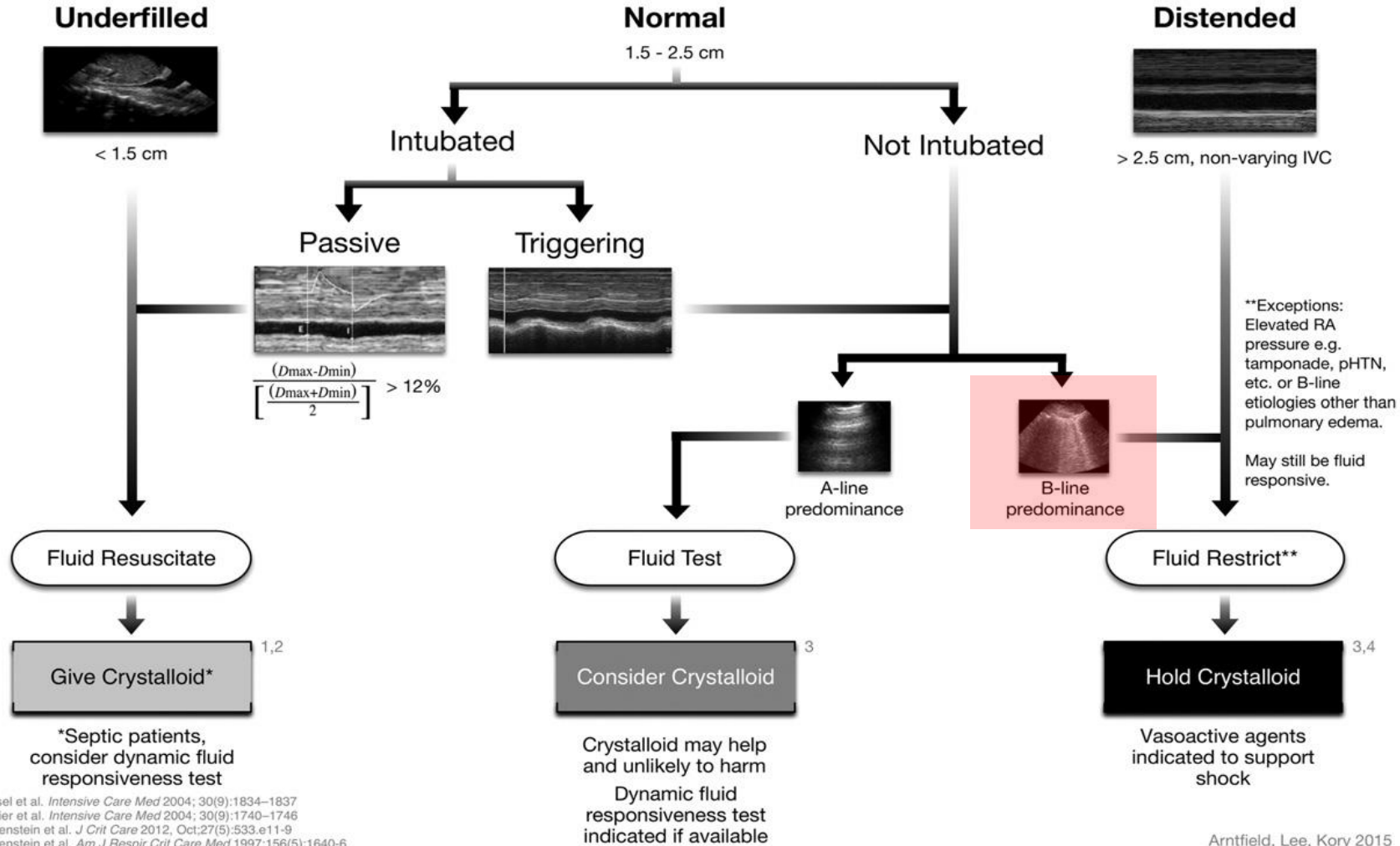
Diuretics

↑FALLS = fluid administration limited by lung sonography

Treatment : Treatment : Fluid therapy - POCUS assessment

Point of Care Ultrasound *Fluid Resuscitation Guide*

- using IVC and lung ultrasound -



②. 기계호흡관련 폐렴에서 치료 반응 평가

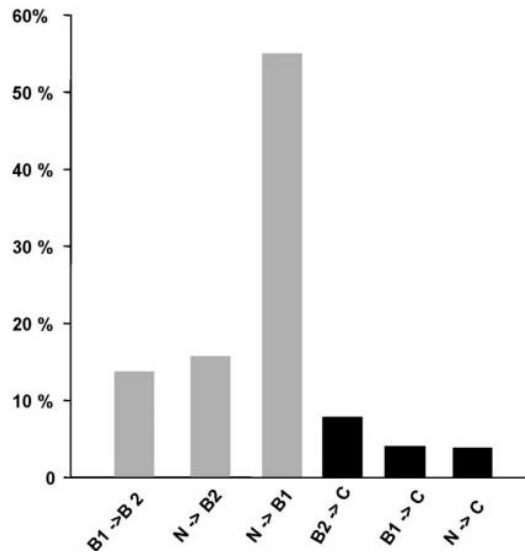
Ultrasound assessment of antibiotic-induced pulmonary re-aeration in ventilator-associated pneumonia*

Bélaïd Bouhemad, MD, PhD; Zhi-Hai Liu, MD; Charlotte Arbelot, MD; Mao Zhang, MD; Fabio Ferarri, MD, PhD; Morgan Le-Guen, MD; Martin Girard, MD; Qin Lu, MD, PhD; Jean-Jacques Rouby, MD, PhD

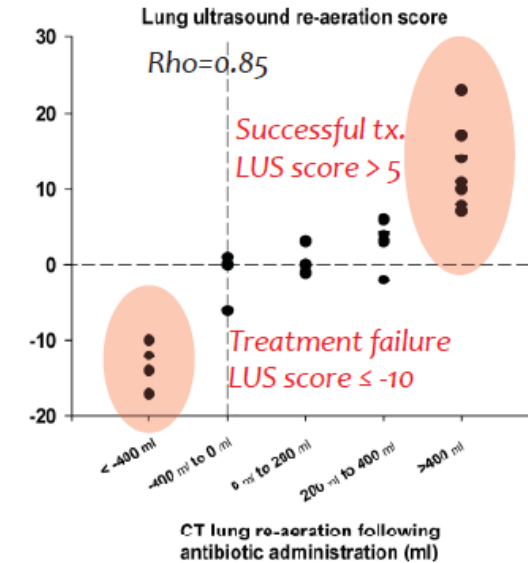
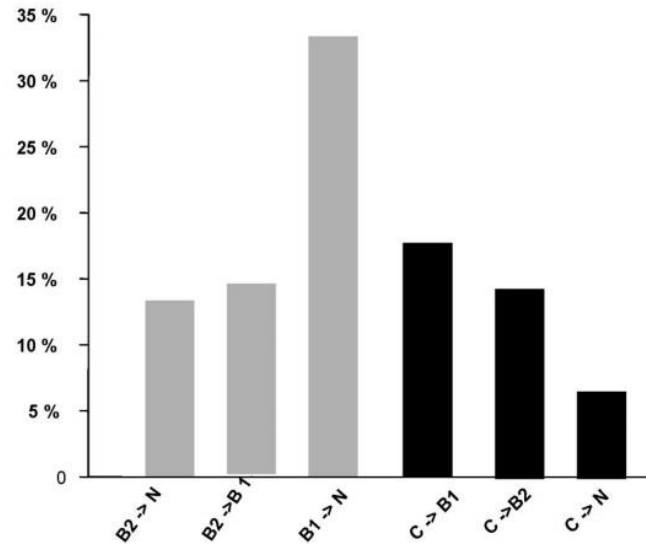
Table 1. Lung ultrasound re-aeration score aimed at evaluating the effects of antibiotics on lung aeration


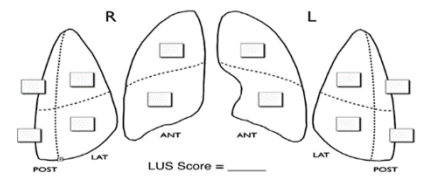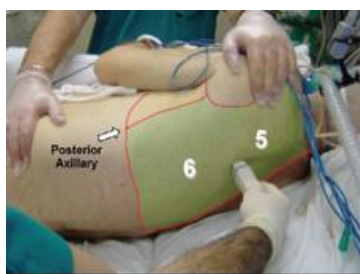
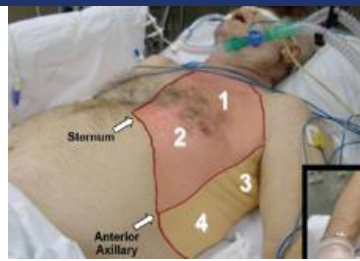
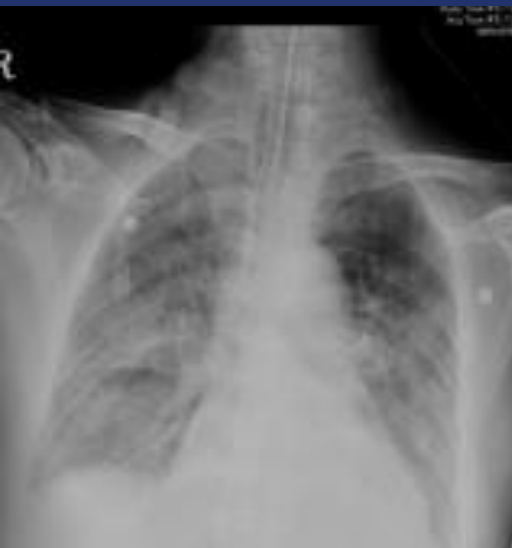Quantification of Reaeration			Quantification of Loss of Aeration		
1 point B1 → N	3 points B2 → N C → B1	5 points C → N	-5 points N → C	-3 points N → B2 B1 → C	-1 point N → B1 B1 → B2 B2 → C

% of ROI examined in patients with failure of antimicrobial therapy



% of ROI examined in patients with success of antimicrobial therapy

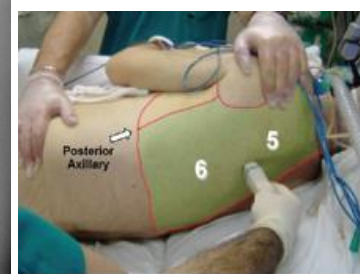
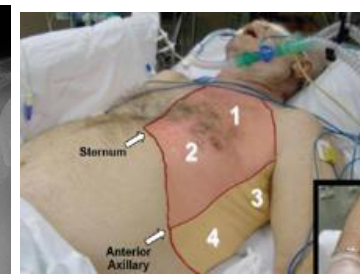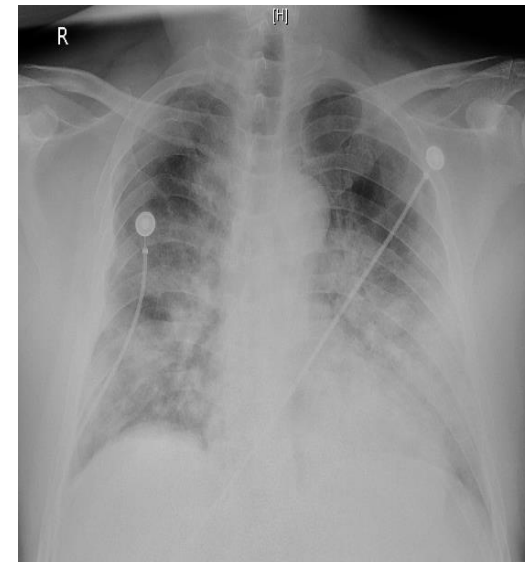
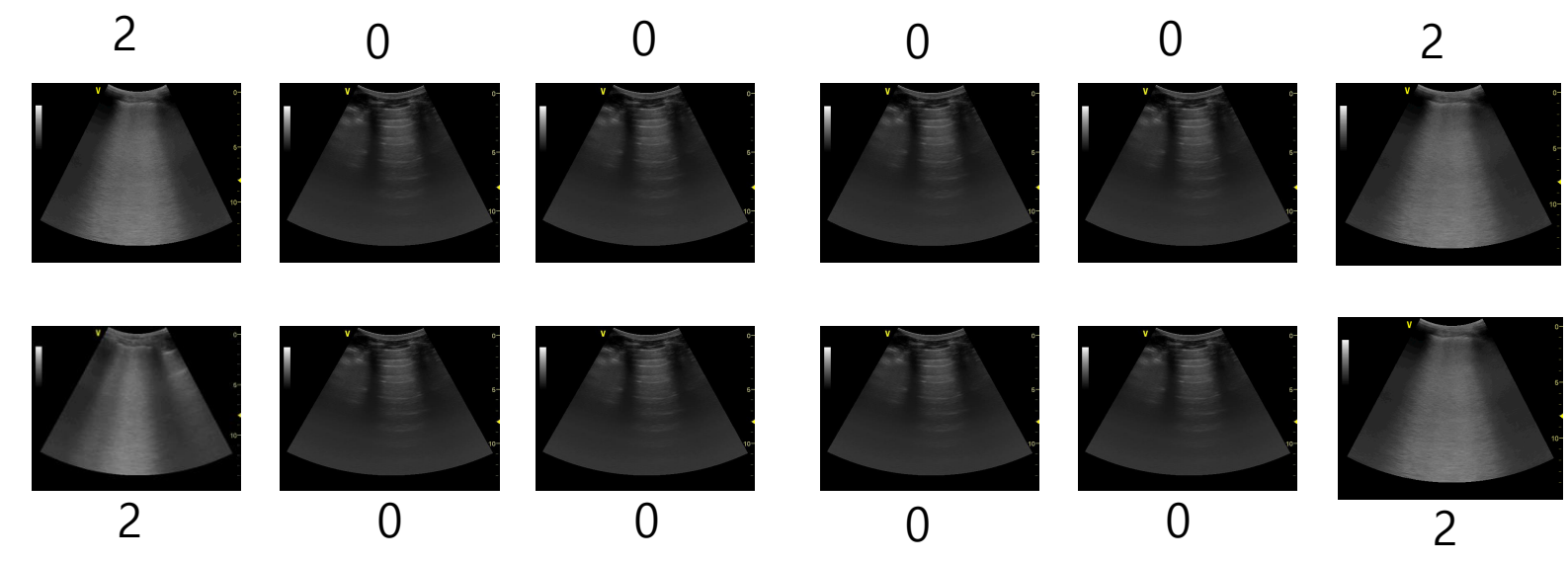




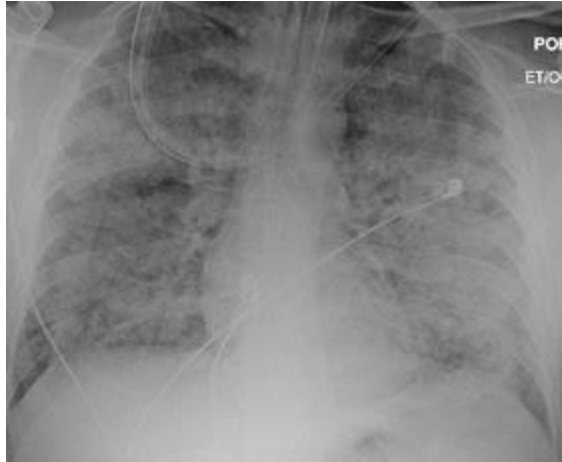15



8



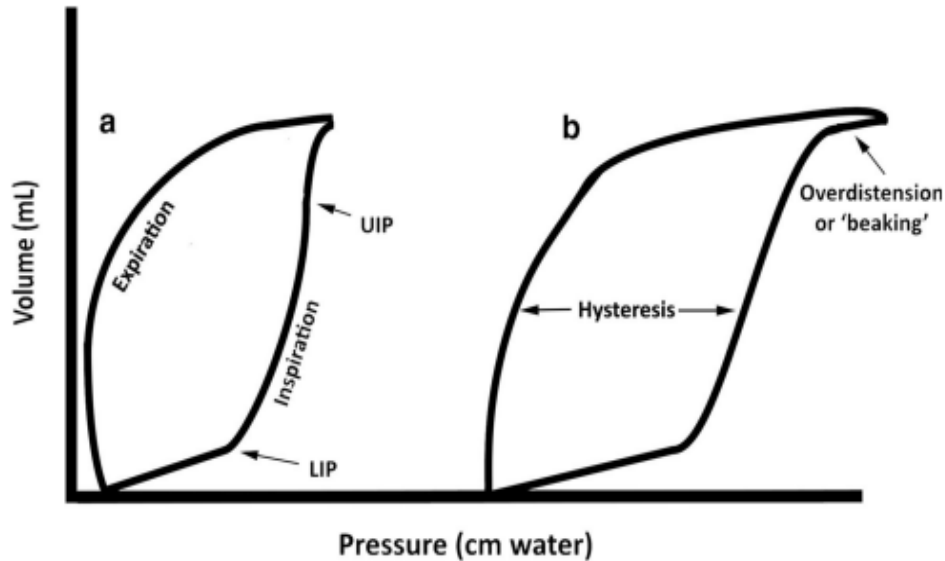
③. 급성호흡곤란증후군에서 호기말양압의 적용 평가



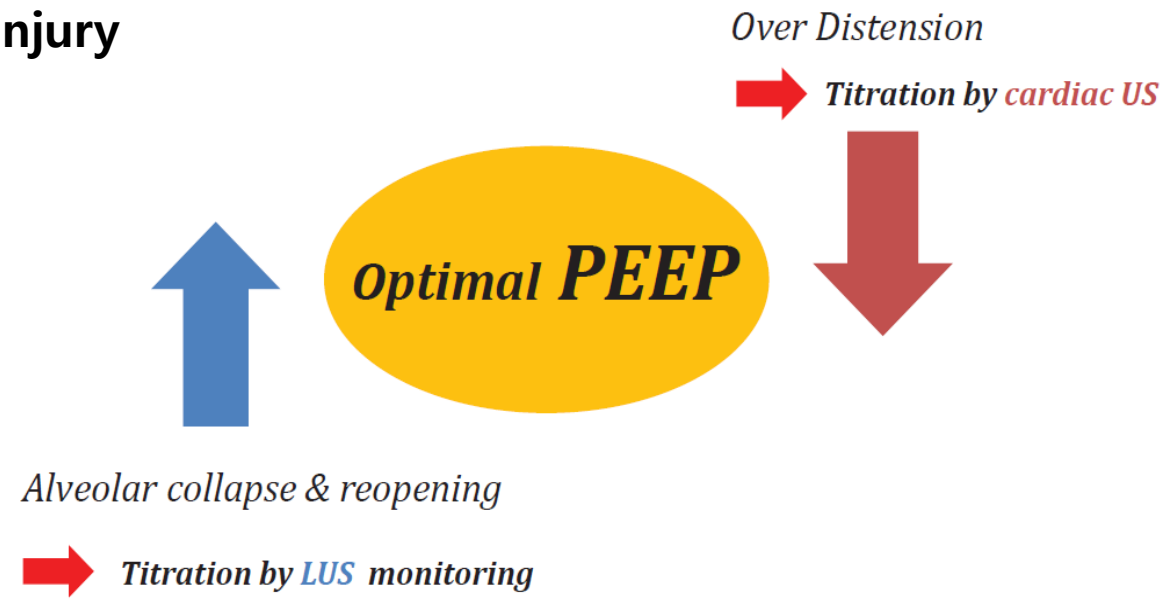
ARDS

Ventilator induced lung injury

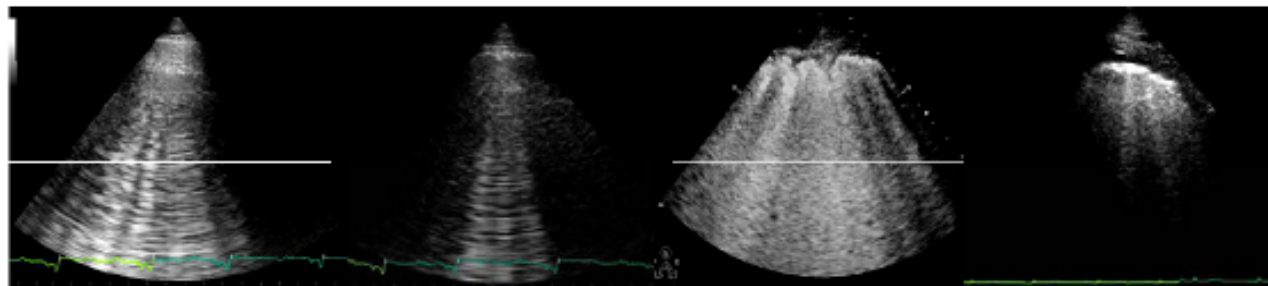
Hysteresis in ventilator



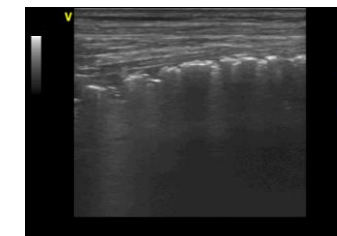
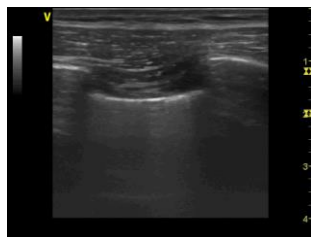Predicting Lung recruitment



Differentiating between cardiogenic and non-cardiogenic pulmonary edema



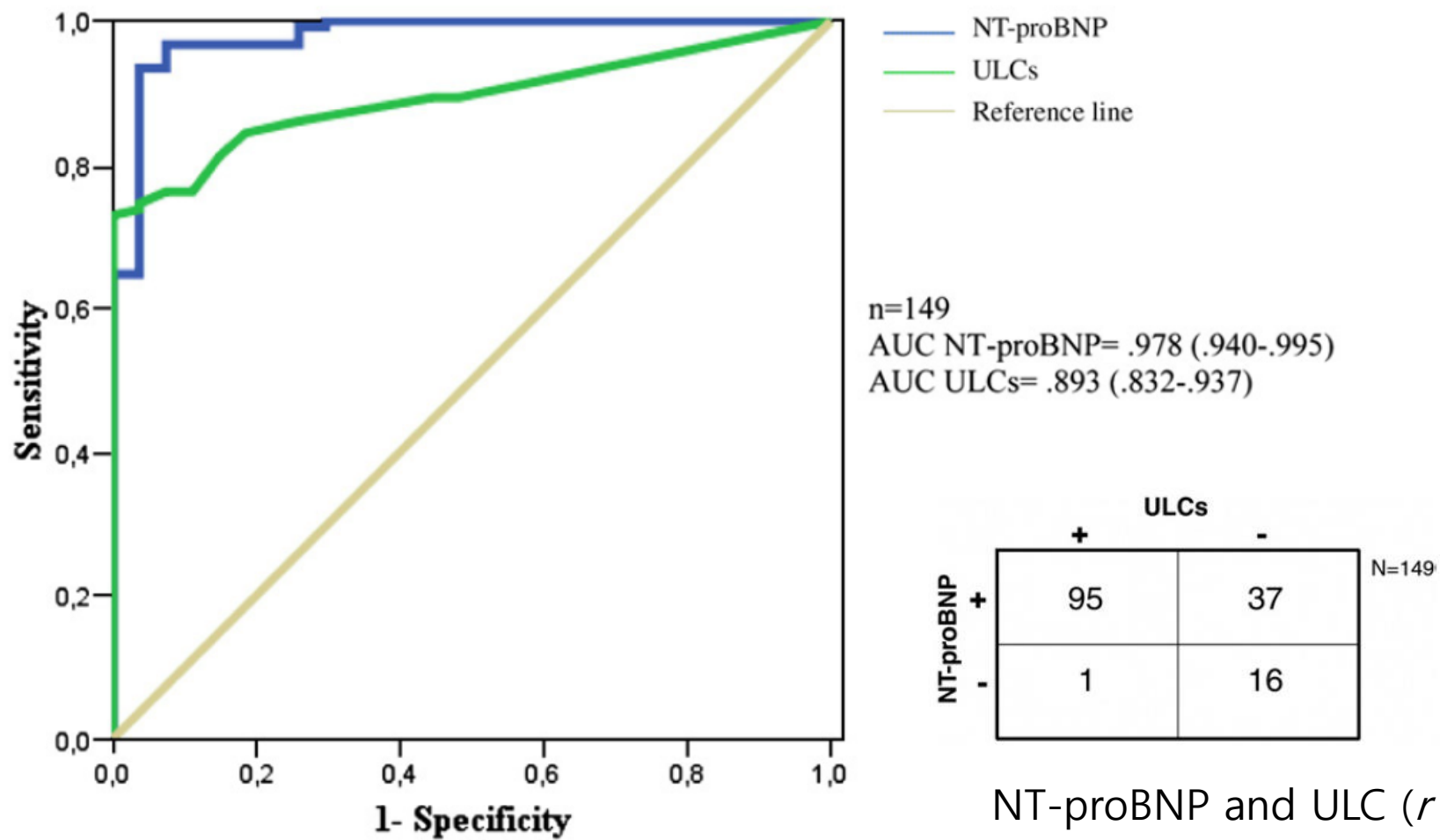
	Acute cardiogenic pulmonary edema	Chronic heart failure	ALI/ARDS	Pulmonary fibrosis
Clinical setting	acute	chronic	acute	chronic
B-lines number	++++	+ / + / + / +	++++	+ / + / + / +
B-lines distribution	multiple, diffuse, bilateral (white lung)	multiple, diffuse, bilateral, following decubitant regions (black and white lung)	non-homogeneous distribution, presence of spared areas	more frequently posterior at lung basis
Other LUS signs	pleural effusion	pleural effusion	pleural effusion, pleural alterations, parenchymal consolidations of various size	pleural thickening
Echocardiogram	abnormal	abnormal	likely normal	likely normal



ALI = acute lung injury; ARDS = acute respiratory distress syndrome; LUS = lung ultrasound.

Diagnosis: B-lines and NT-proBNP

ROC curve for NT-proBNP and ULCs for differentiating dyspnea of cardiac origin from non-cardiac origin

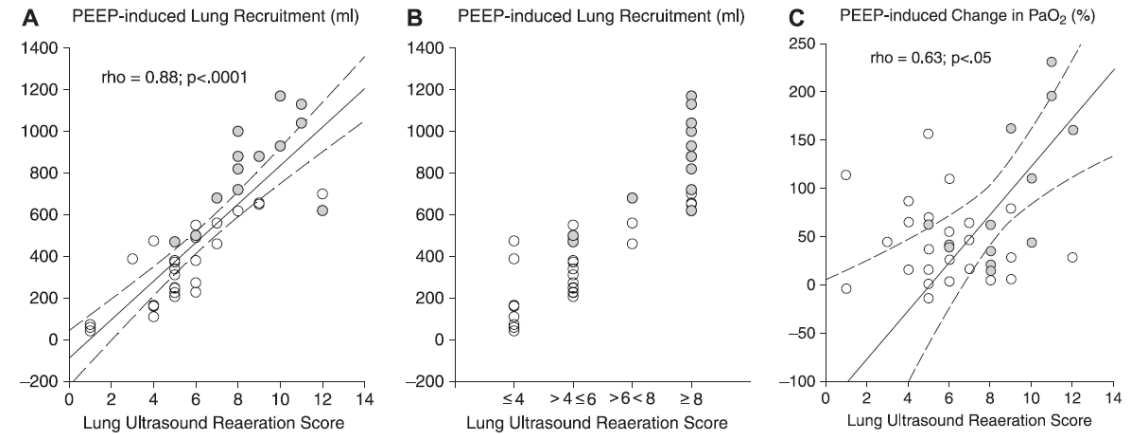
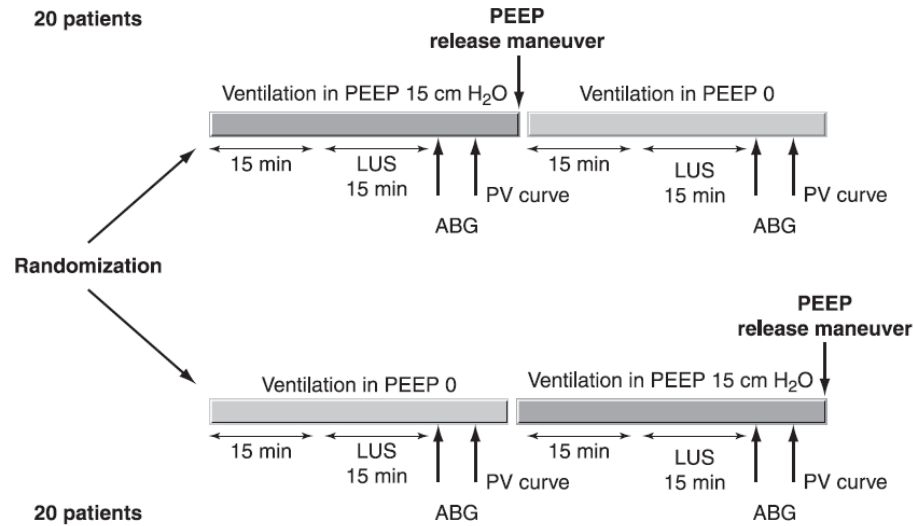


Bedside Ultrasound Assessment of Positive End-Expiratory Pressure-induced Lung Recruitment

Belaïd Bouhmad¹, Hélène Brisson¹, Morgan Le-Guen¹, Charlotte Arbelot¹, Qin Lu¹, and Jean-Jacques Rouby¹

¹Multidisciplinary Intensive Care Unit Pierre Viars, Assistance Publique Hôpitaux de Paris, UPMC (Université Pierre et Marie Curie) Paris-6, Department of Anesthesiology and Critical Care Medicine, La Pitié-Salpêtrière Hospital, Paris, France

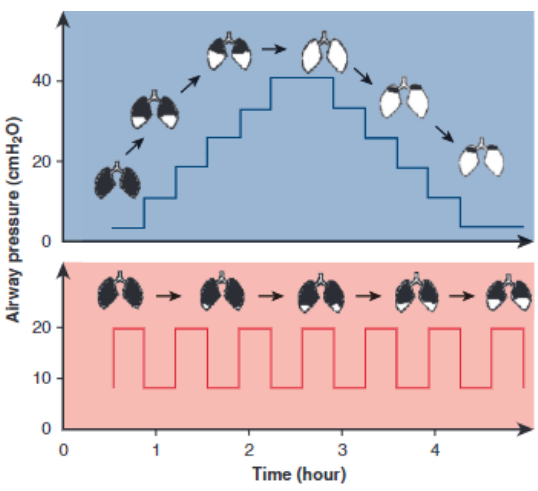
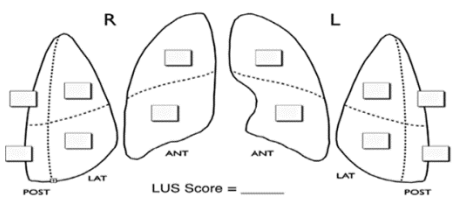
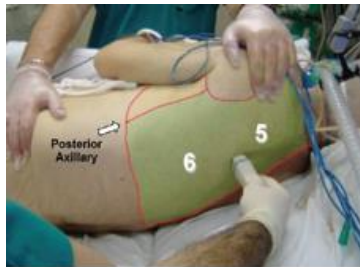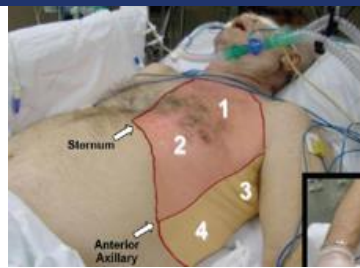
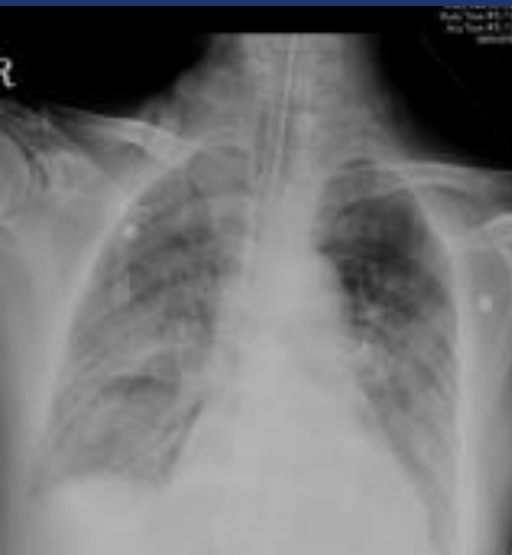Comparison PV curve method with LUS for PEEP in ARDS(N=30)/ALI(N=10)




$\leq 4 \rightarrow 75 \sim 450 \text{ml}$

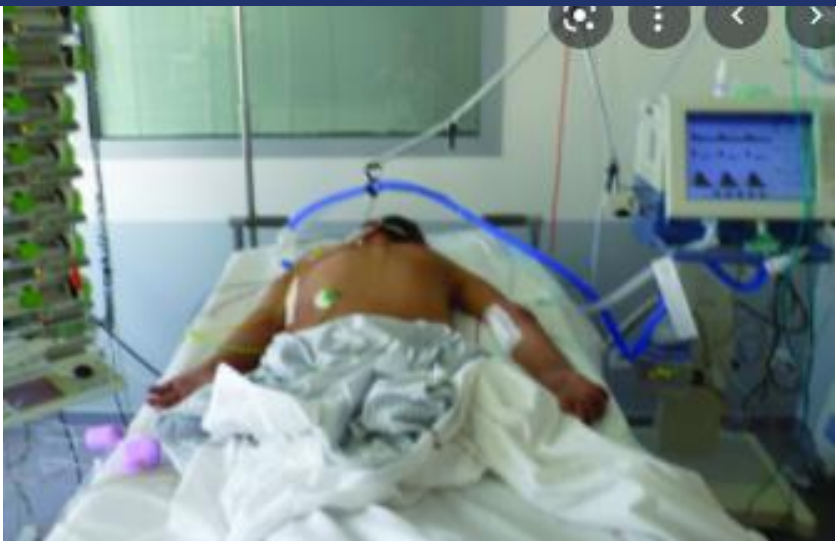
$\geq 8 \rightarrow > 600 \text{ml}$

Recruiting lesion : anterior > lateral > posterior

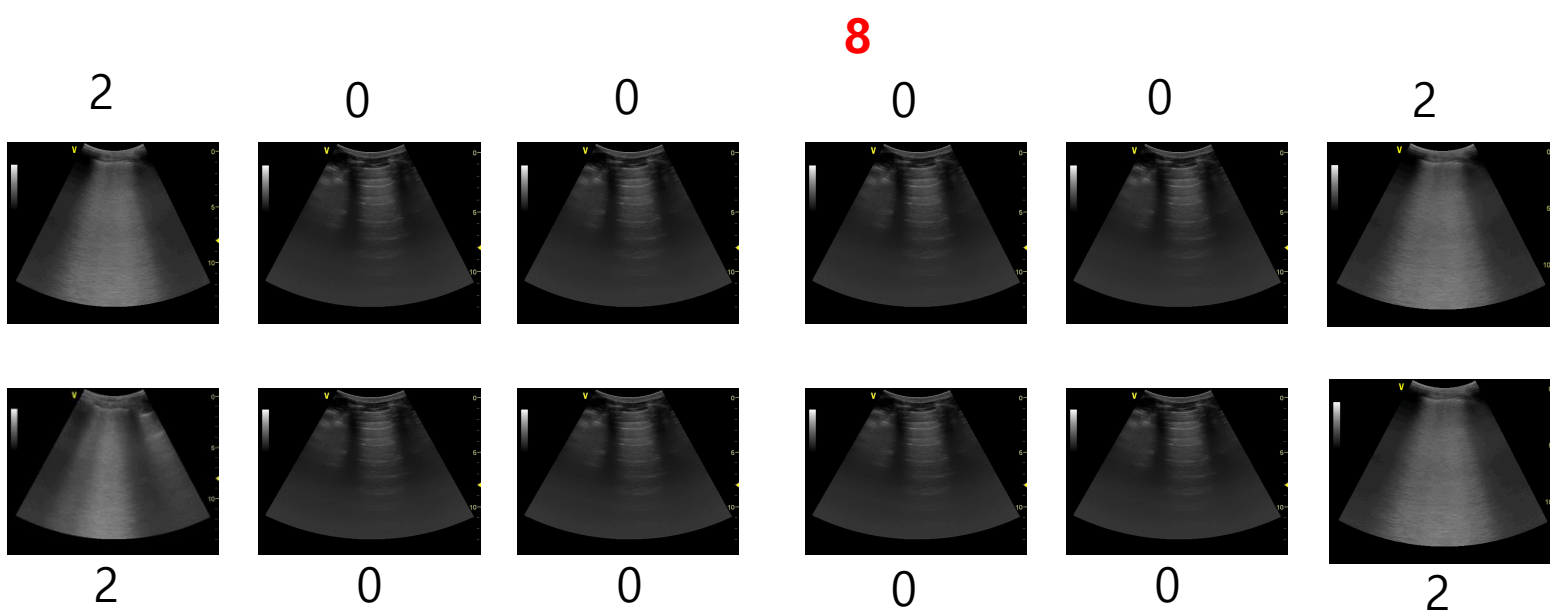
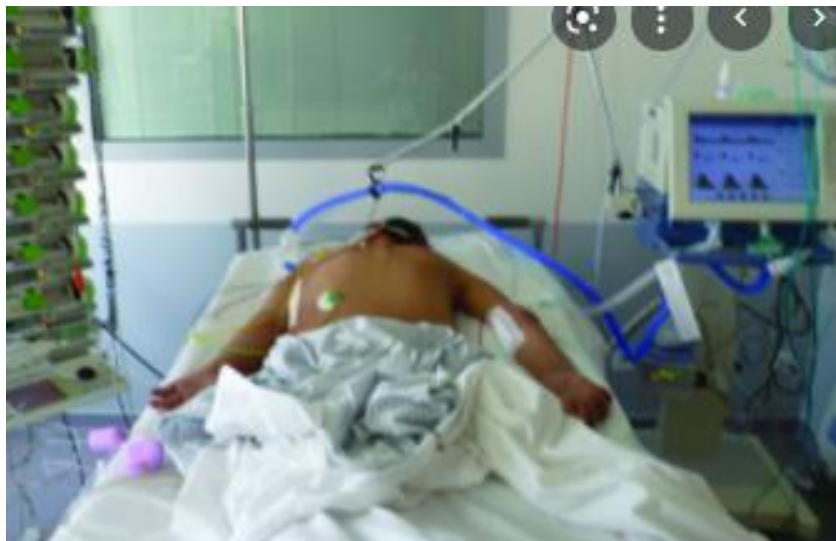

: Recruited lung
 : Collapsed lung
 : Recruitment maneuvers
 : Conventional mechanical ventilation

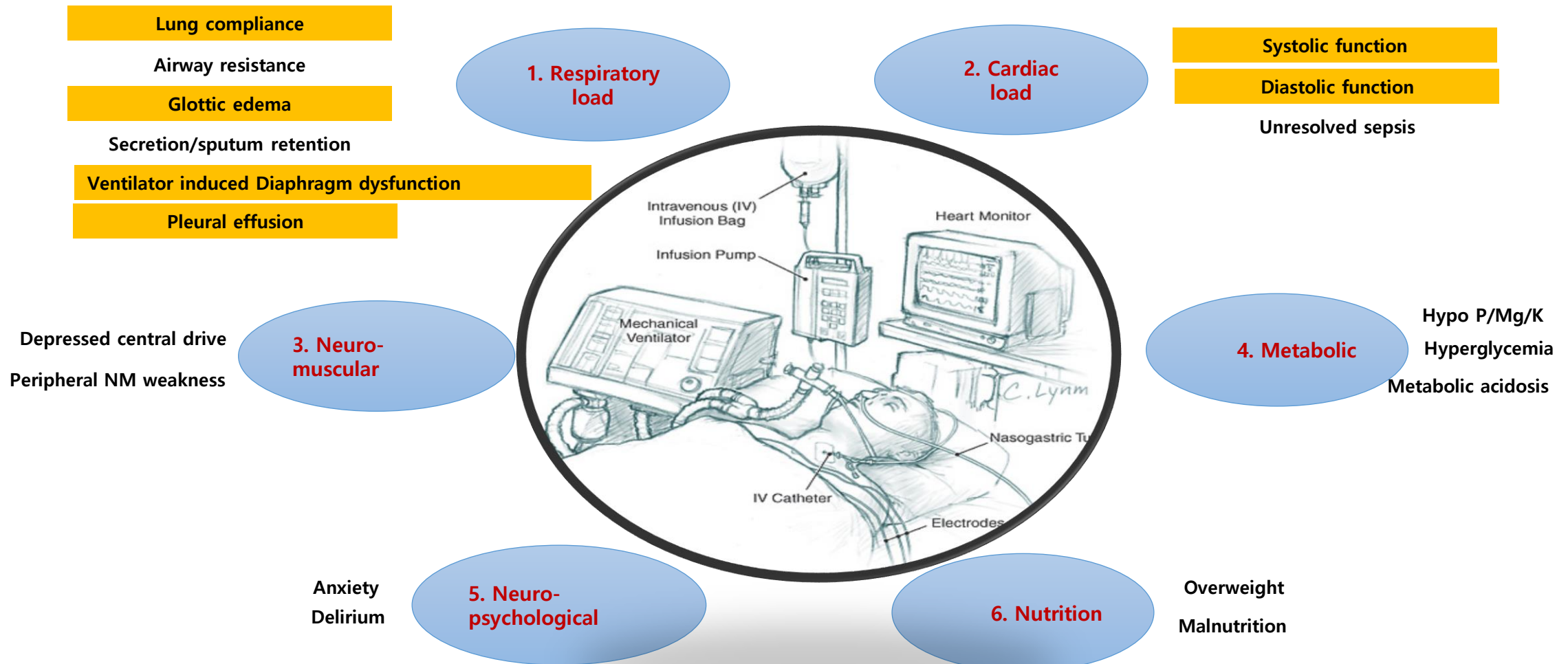




15 ↓ 몇 시간 후?

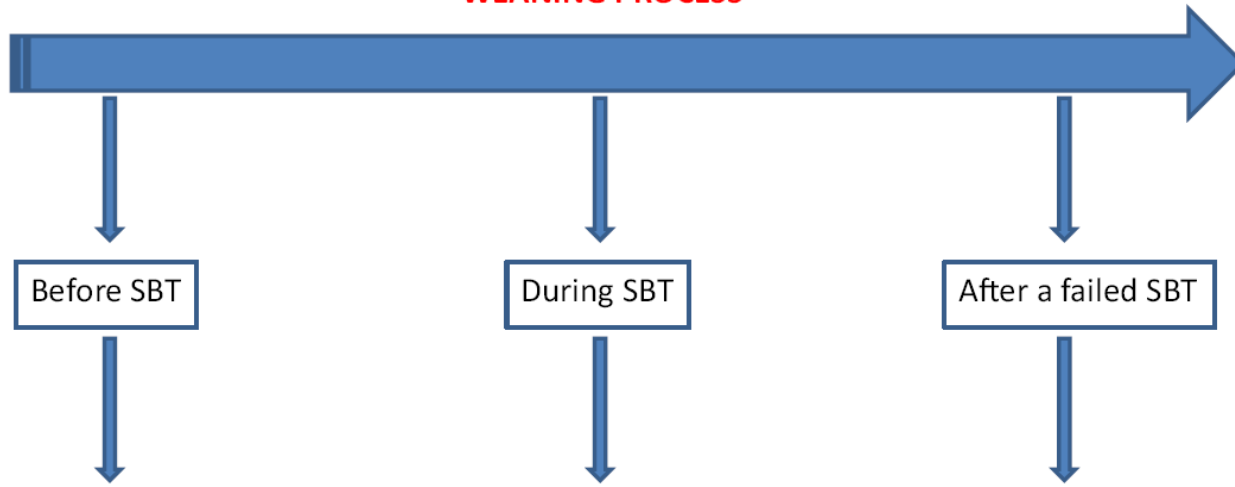

④. 인공호흡기 이탈에서 평가



US evaluation during weaning process

WEANING PROCESS



Before SBT

Detect high-risk patients

1- ECHOCARDIOGRAPHY

- Moderate to severe LV diastolic impairment ($E' < 8$ cm/s, E/A 0.8-1.5 or > 2)
- Preload-independency
- LV systolic dysfunction (LVEF $< 40\%$)
- Obstructive CM

2- LUNG/PLEURAL US

- Alteration in lung aeration (LUS score)
- Pleural effusion related lung consolidation

During SBT

Predict weaning success

1- LUNG US

- No lung de-recruitment (LUS score)

2- DIAPHRAGMATIC US

- No diaphragmatic dysfunction (excursion and thickening during inspiration)

After a failed SBT

Diagnose cause of failure

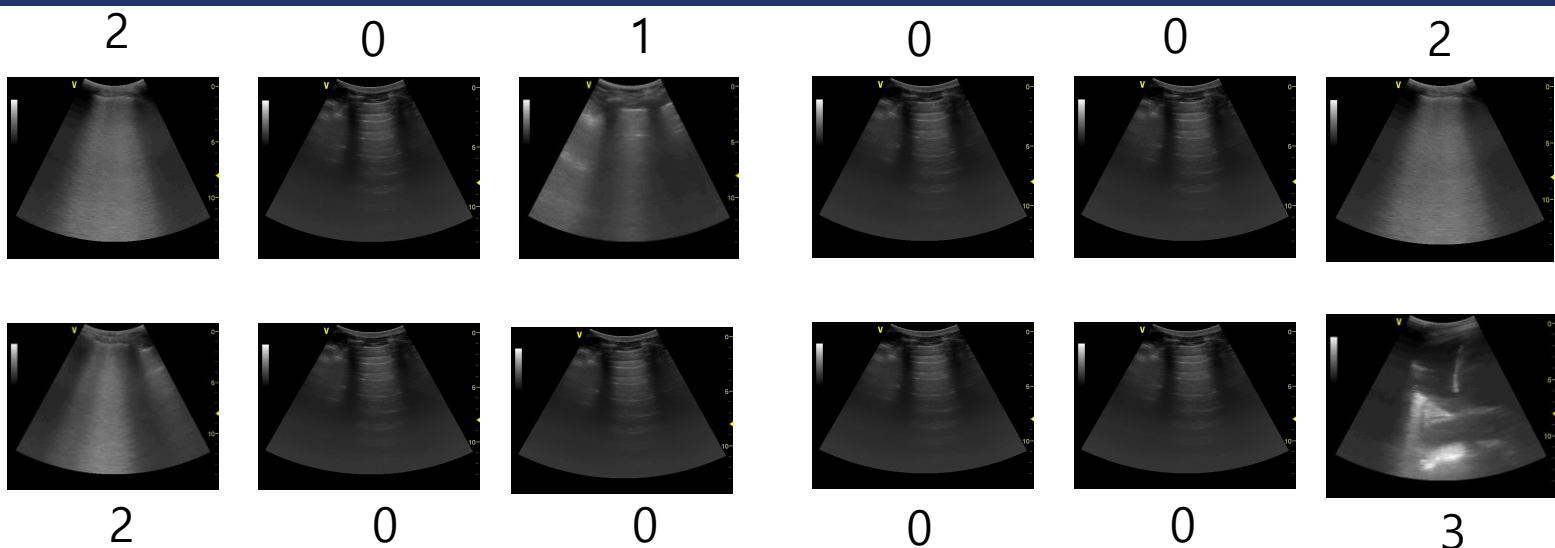
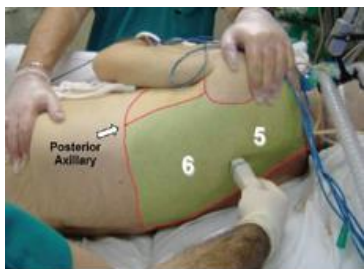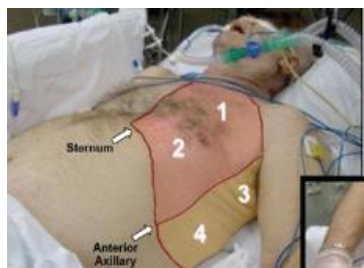
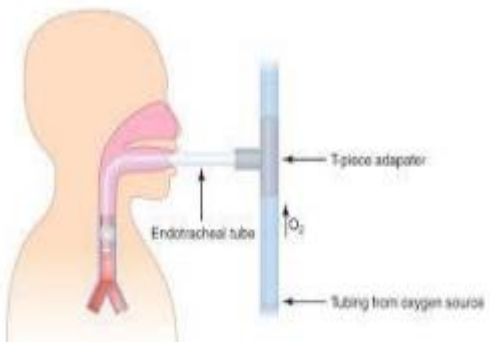
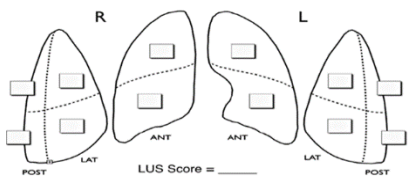
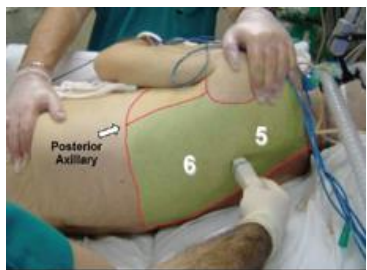
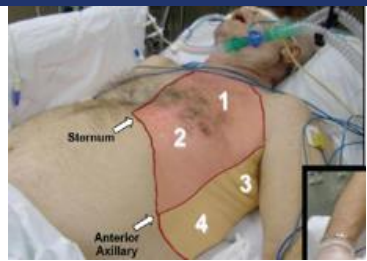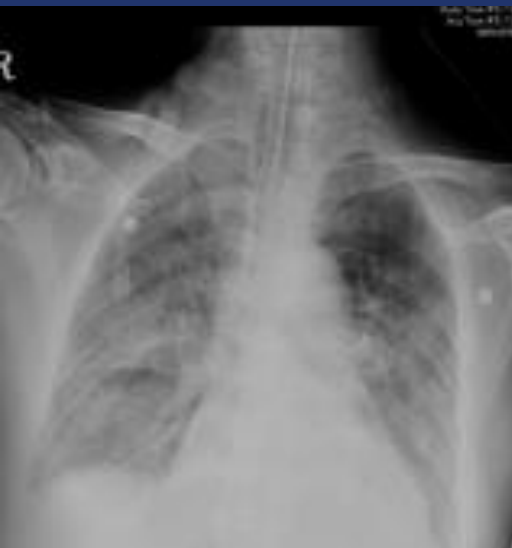1- ECHOCARDIOGRAPHY

- CPE (elevated LV filling pressure)

2- LUNG US

- Lung de-recruitment (LUS score)


LUS at end of SBT	Value	Potential utility
LUS score	< 13	Increased likelihood of success of extubation
LUS score	13-17	Indetermine likelihood
LUS score	> 17	Increased likelihood of failure of extubation



10



25




Limitation of Lung ultrasound

Lung Ultrasound interpretation

- Subcutaneous emphysema
- Calcification of the pleura
- Large thoracic dressing
- Pleural symphysis & pleurodesis
- Generalized edema
- Overlying lines and tubes
- Obese
- Over-distension of alveoli

Lung Sliding interpretation

- Small Tidal Volume
- Pleural adhesion
- COPD
- Rt. main bronchial intubation & atelectasis
- HFOV



Thank you for your attention!