

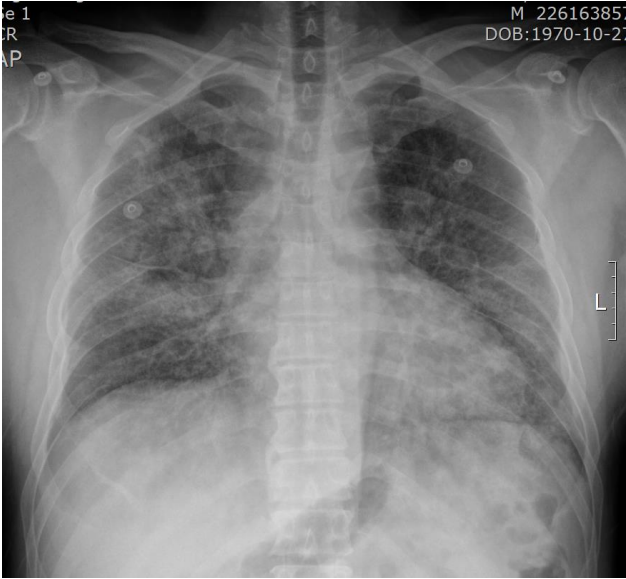


# Repair, Remodeling & Regeneration in Acute Respiratory Distress Syndrome

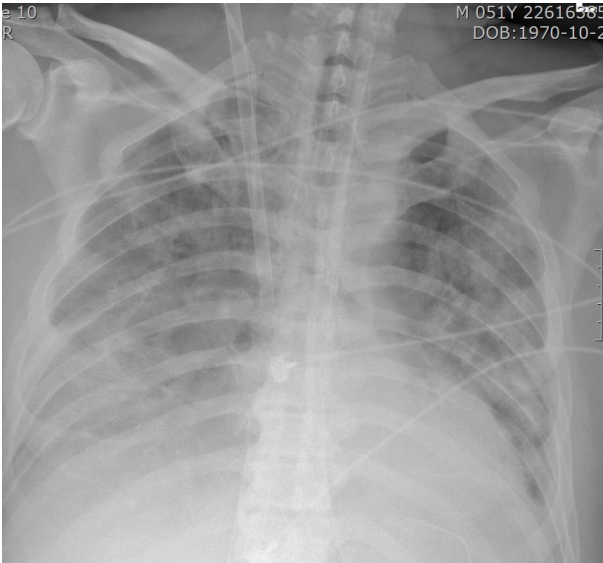
Department of pulmonary and critical care medicine  
Pusan National University Yangsan Hospital  
Woo Hyun Cho

# COVID-19 ARDS, long standing & slow progressive

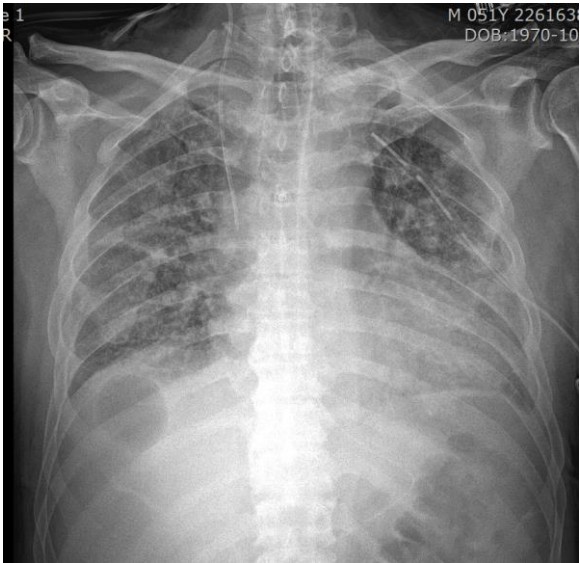
COVID-19, 2wk



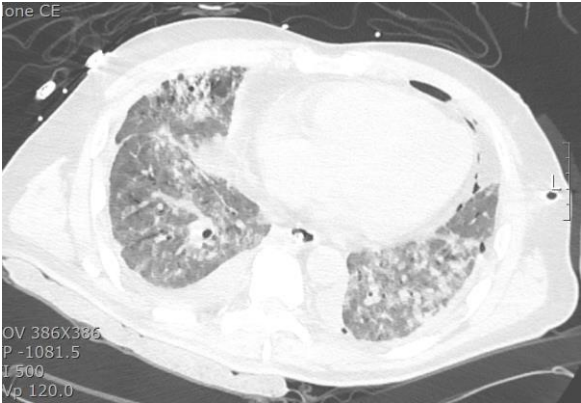
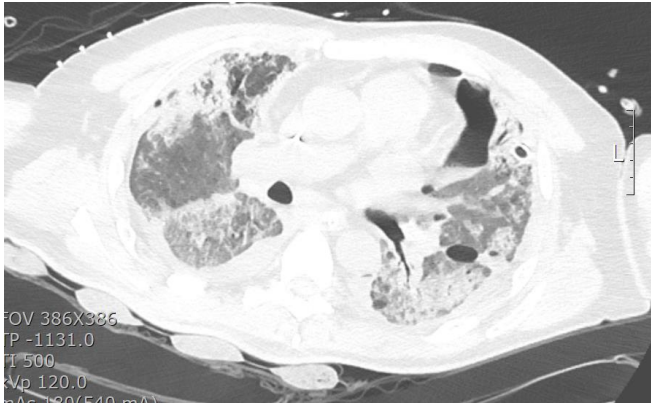
COVID-19, 4wk



COVID-19, 4M



COVID-19, 3M2W



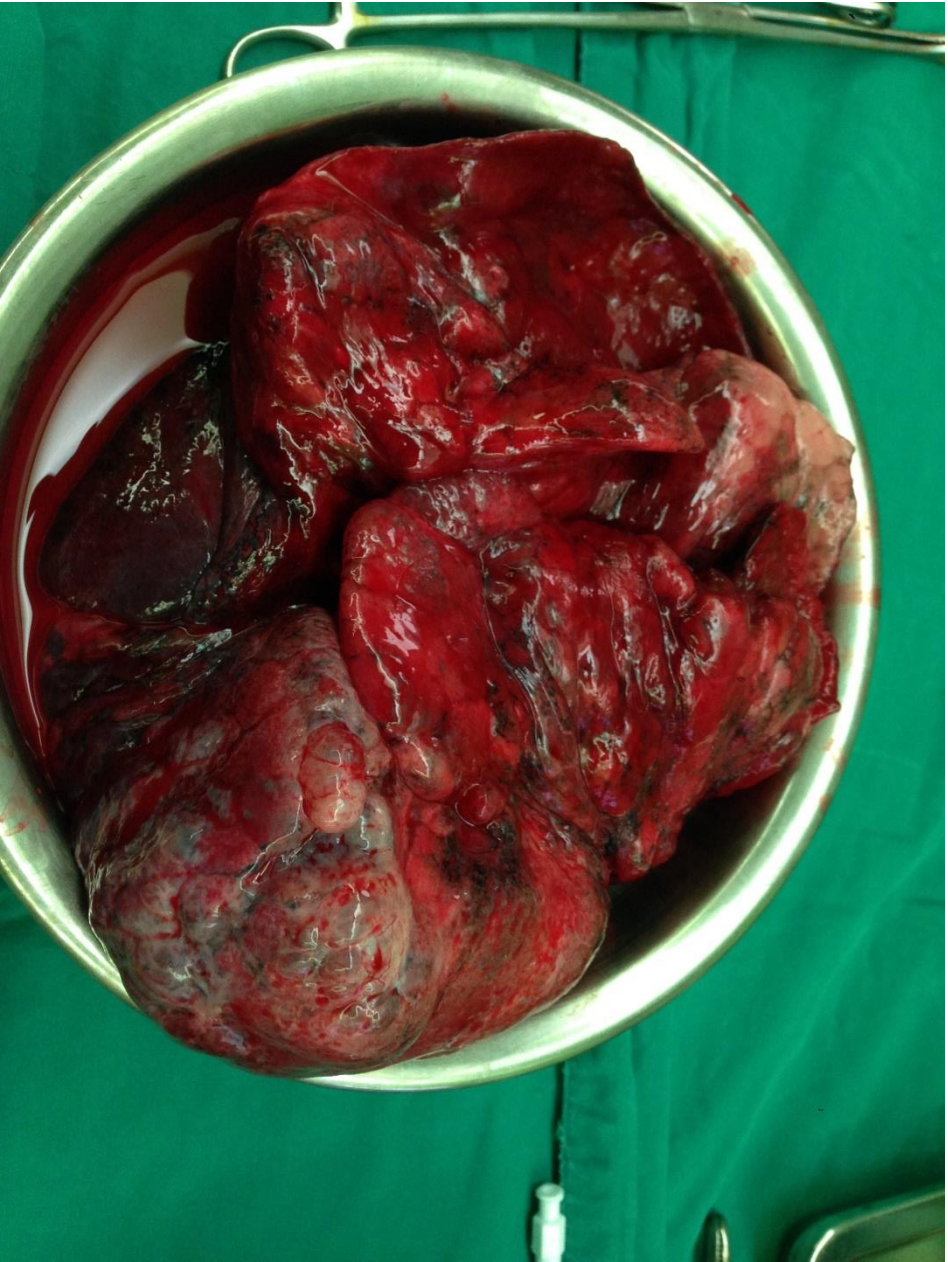
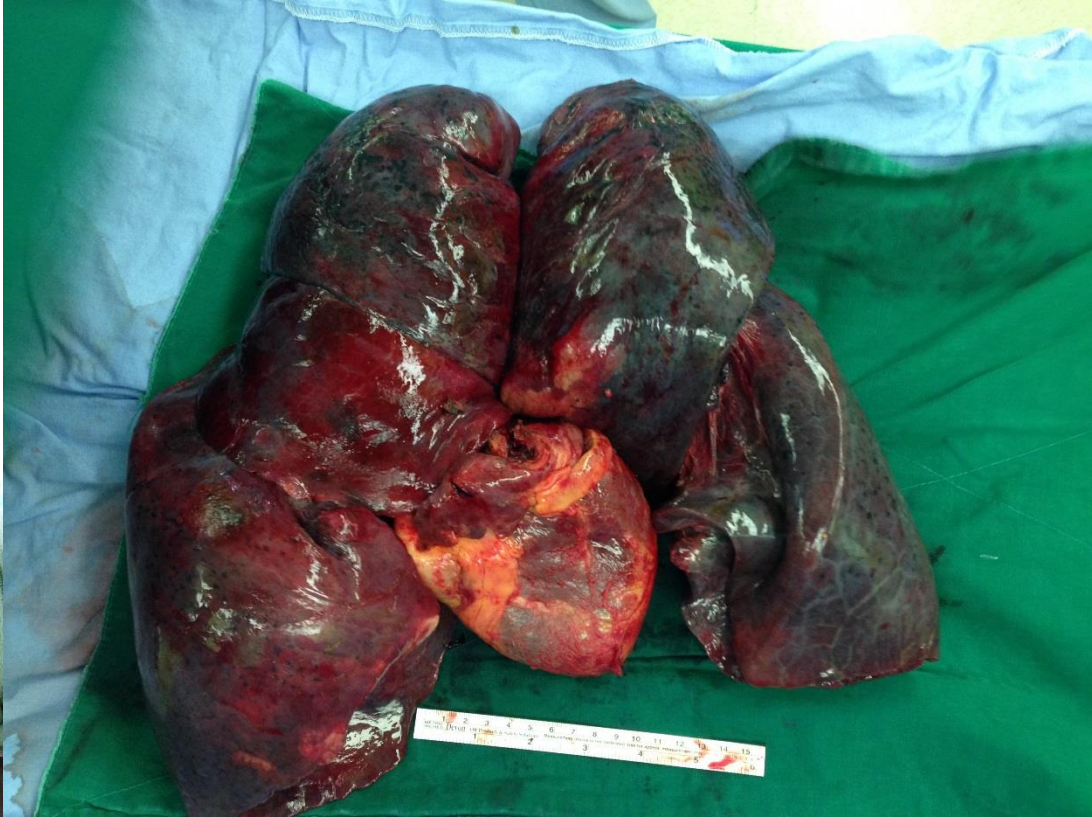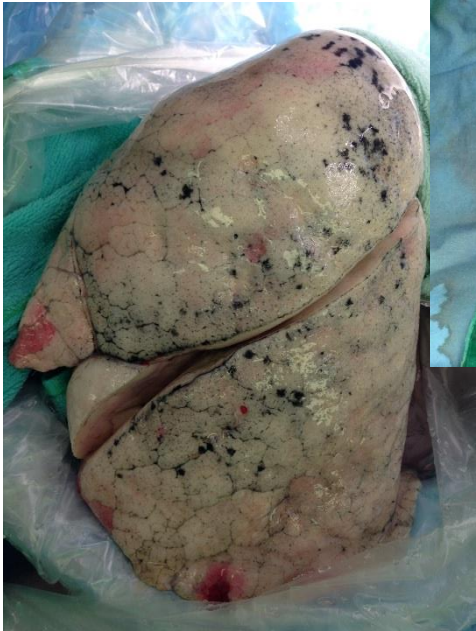# Lung Transplant in ARDS

---

<b>Virus</b>	<b>Age</b>	<b>Sex</b>	<b>MV duration</b>	<b>ECMO duration</b>	<b>ICU stay</b>	<b>Hospital stay</b>	<b>ICU survival</b>	<b>Discharge alive</b>
Influenza	47	M	45	32	45	67	Y	Y
Influenza	51	M	66	41	73	88	Y	Y
Influenza	59	M	40	16	40	66	Y	Y
COVID	48	F	29	3	30	106	Y	Y
COVID	36	M	69	46	42	121	Y	Y
COVID	46	F	13	8	14	305	Y	N
COVID	53	M	28	77	29	29	N	N
COVID	52	M	Still on mV	30	still in ICU	still in GW	?	?
COVID	47	M	21	14	25	still in GW	Y	?
COVID	50	M	38	31	38	still in GW	Y	?
COVID	65	F	21	14	25	still in GW	Y	?

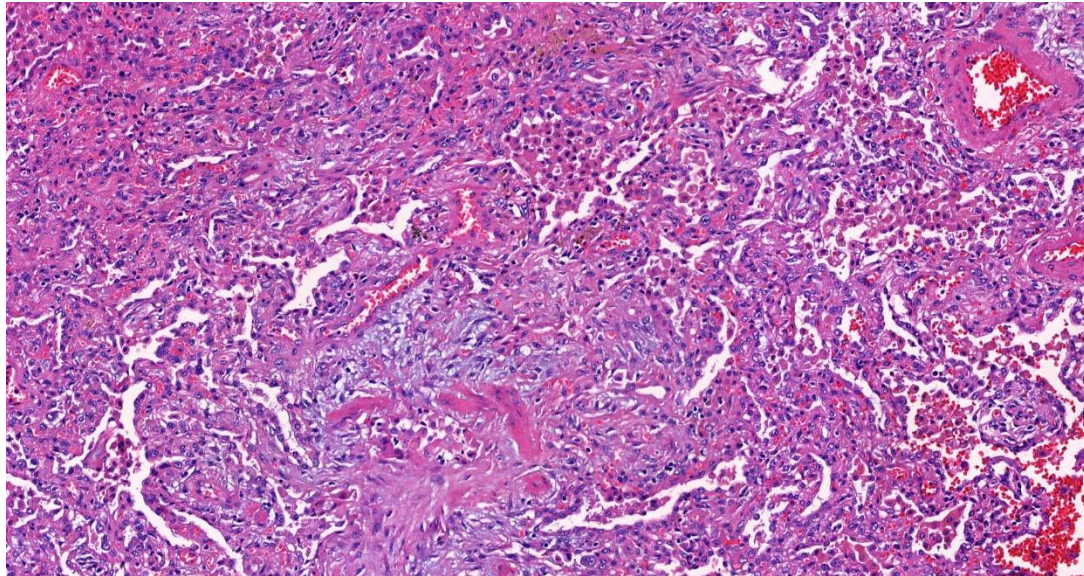
---

# End stage ARDS

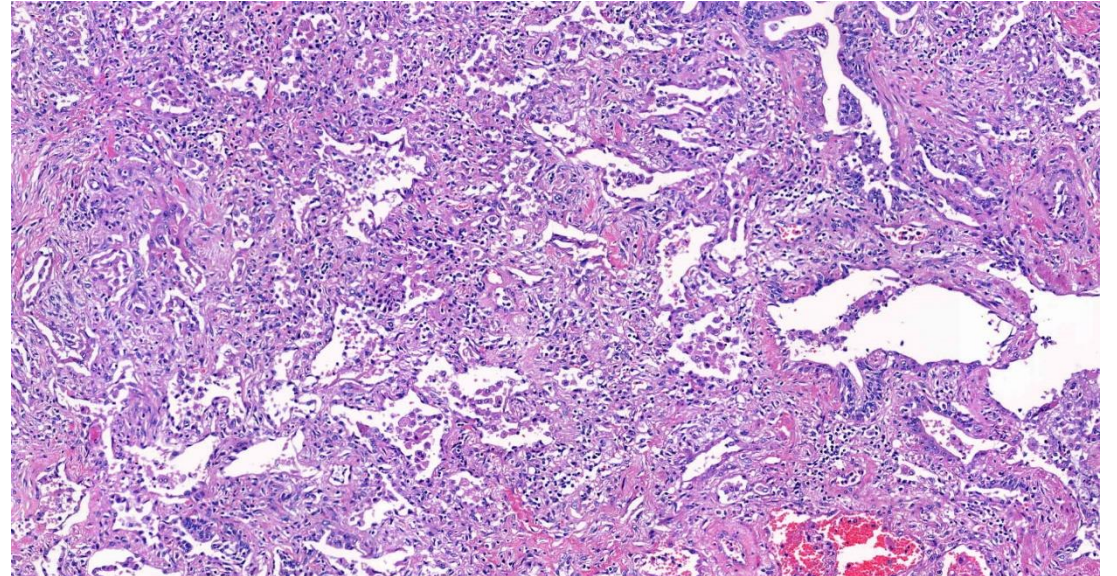


# Pathologic difference ?

**Influenza (H1N1, 2016)**

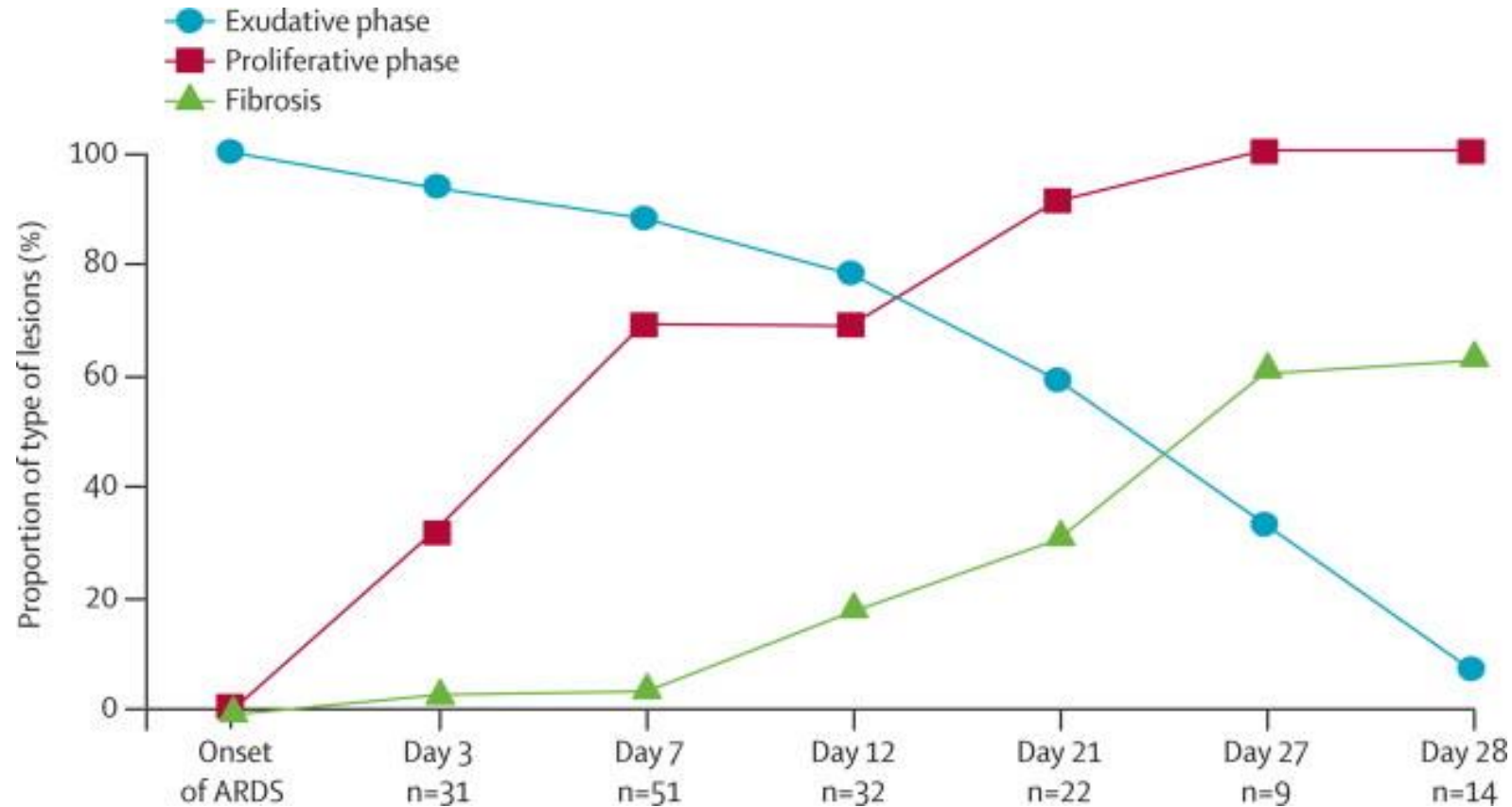


**COVID-19**

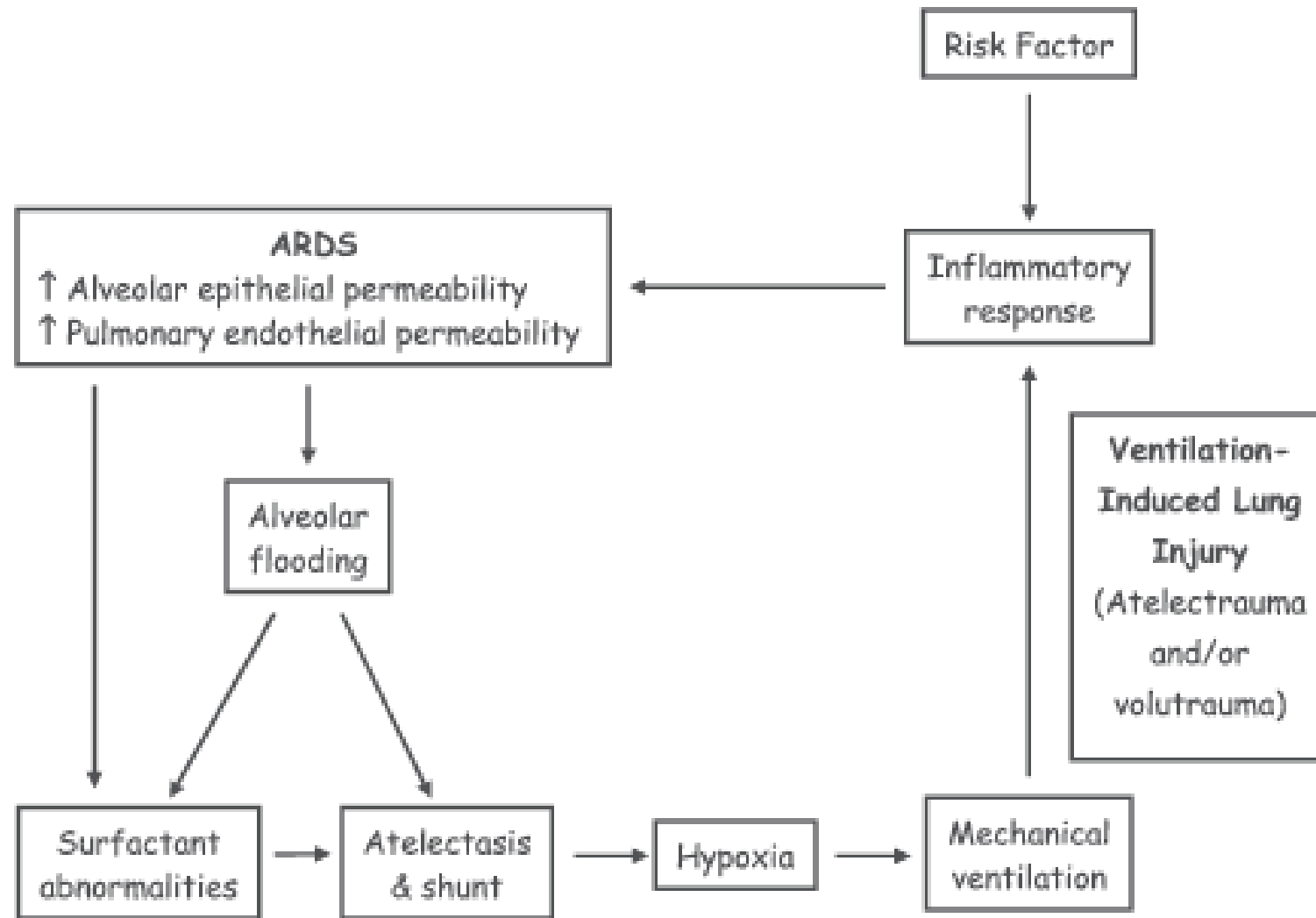


Massive organizing intra-alveolar or interstitial fibrosis  
Temporal heterogeneity ??

# Chronology of histological lesions in ARDS with diffuse alveolar damage: a prospective cohort study of clinical autopsies



# The scheme of ARDS pathogenesis



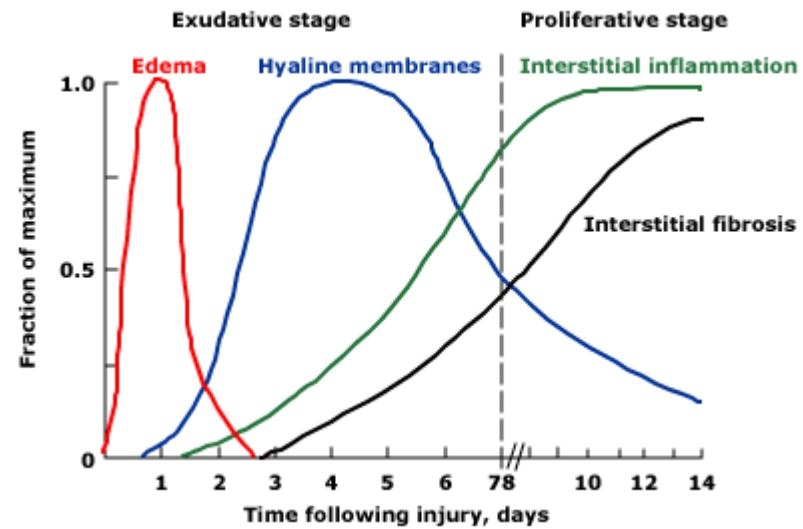
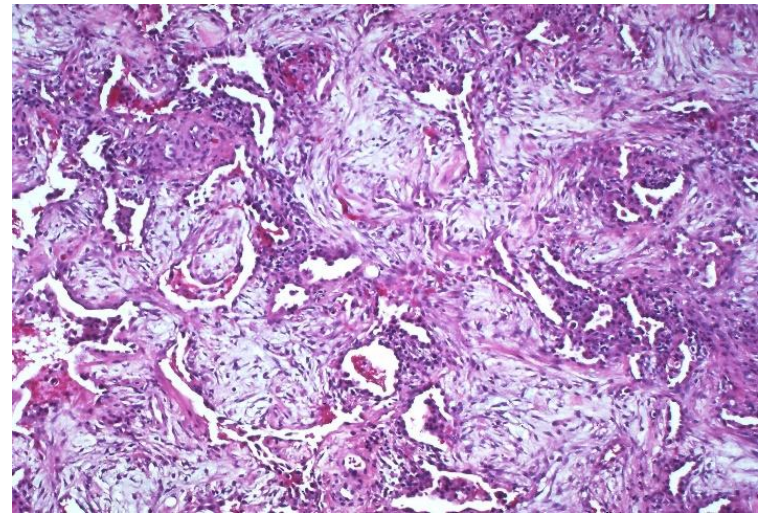
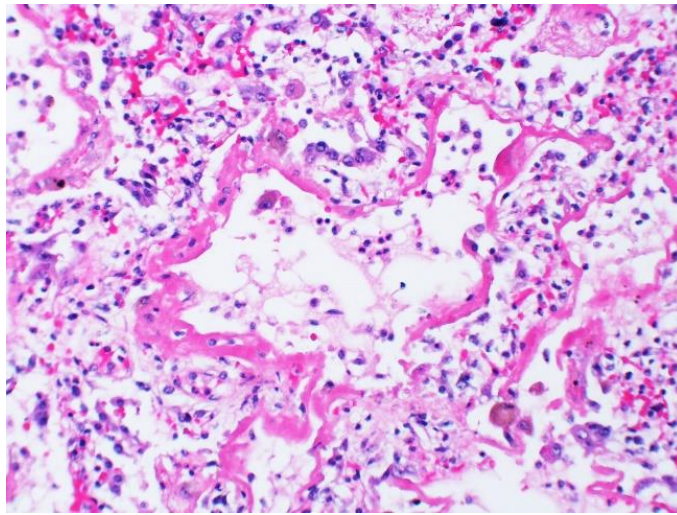
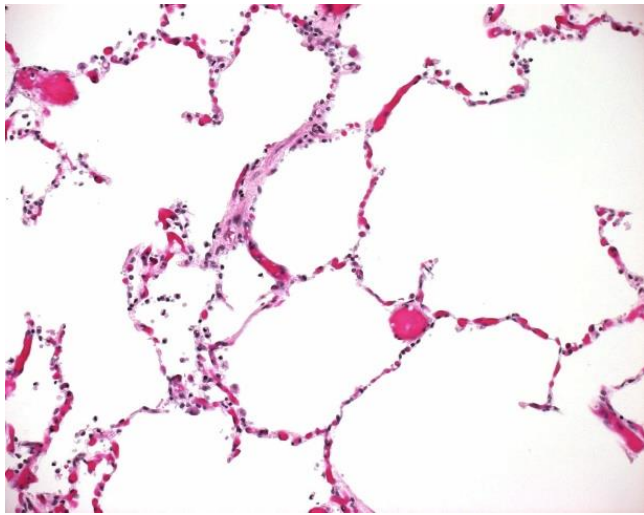
# Multiple injuries in ARDS



**Ventilator induced lung injury**

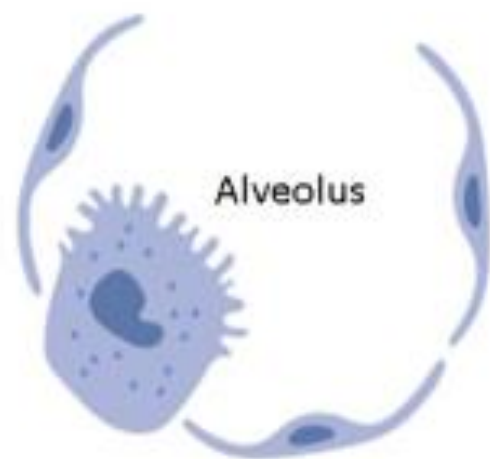
**Fibroproliferative phase**

**MV associated Cx**

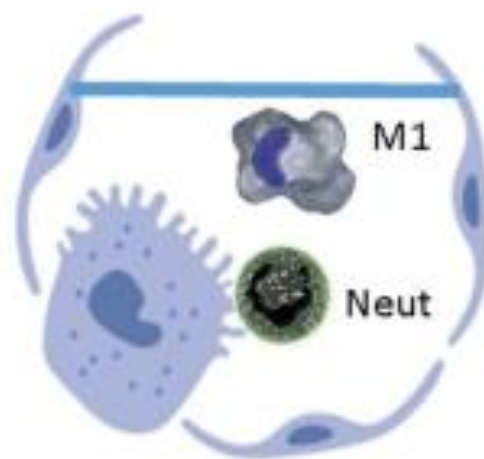


# Pathologic stage of ARDS

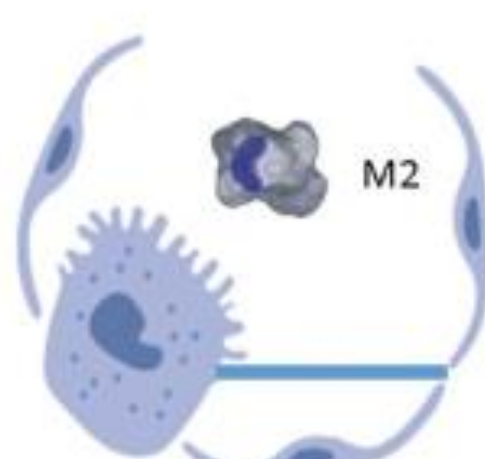
### A Healthy



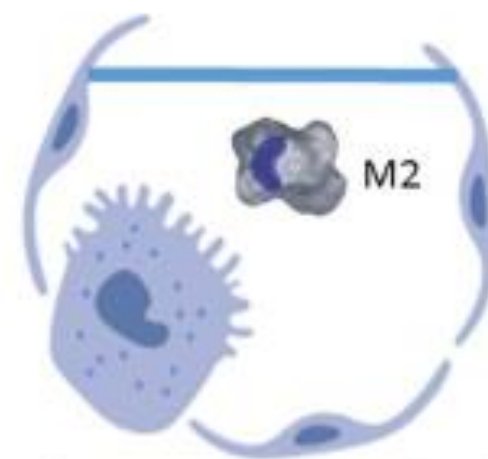
### B Exudative Phase



### C Proliferative Phase



### D Fibrotic Phase



Interstitial fibroblast



Interstitial Flooding  
Coagulation

Capillary endothelium



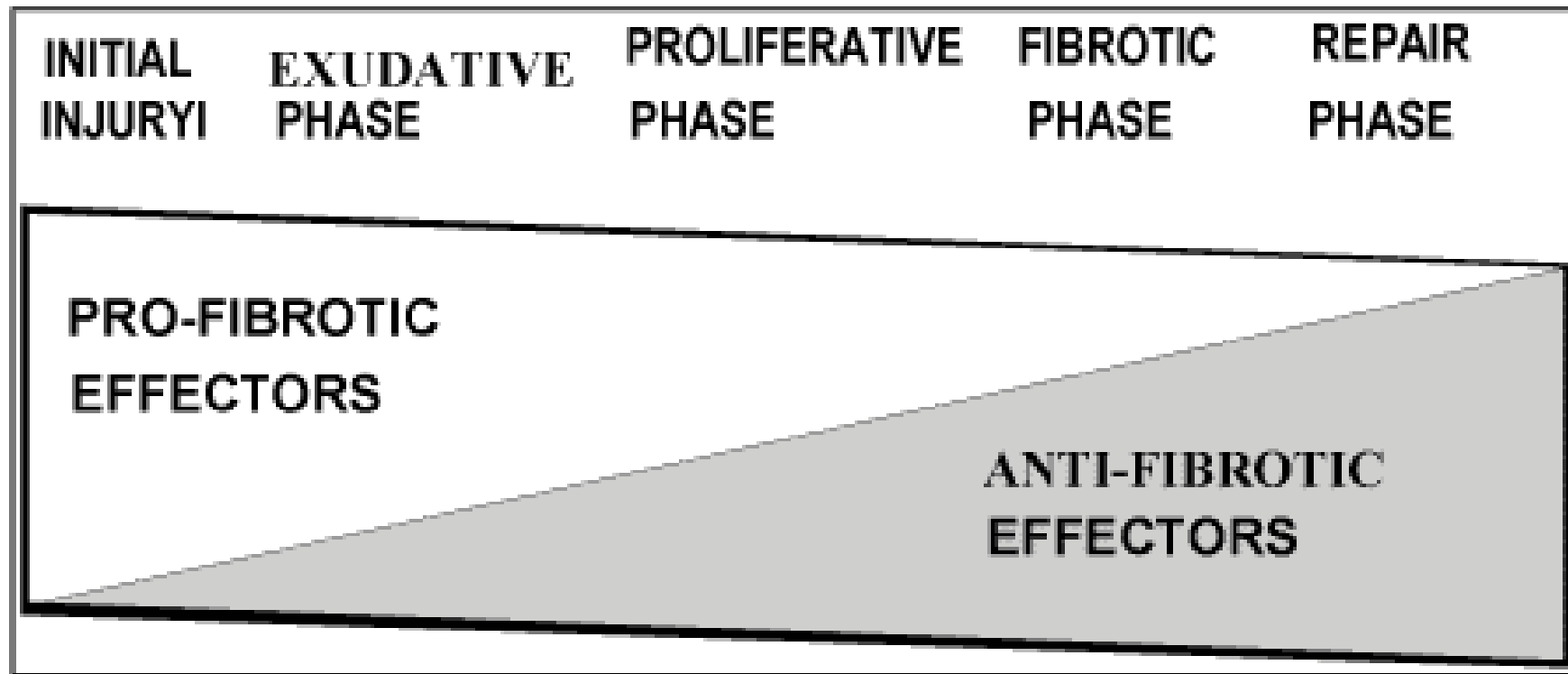
Endothelial barrier destruction  
Migration of neut  
Intravascular coagulation

Proliferation of  
Interstitial fibroblasts

Endothelial proliferation

Interstitial and  
intra-alveolar fibrosis

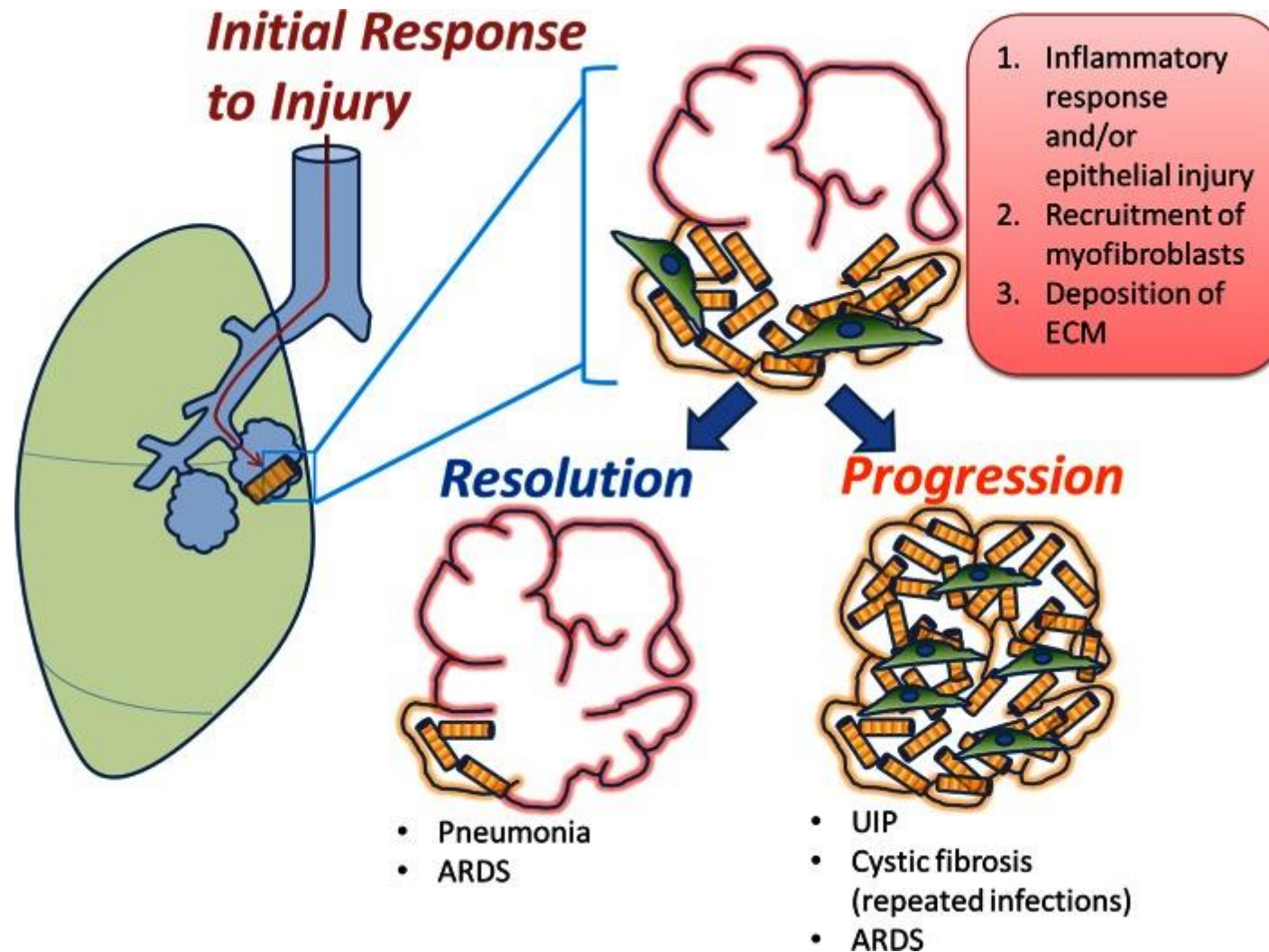
Obliteration of  
microcapillaries



**Figure 1** – Different phases of adult acute respiratory distress syndrome

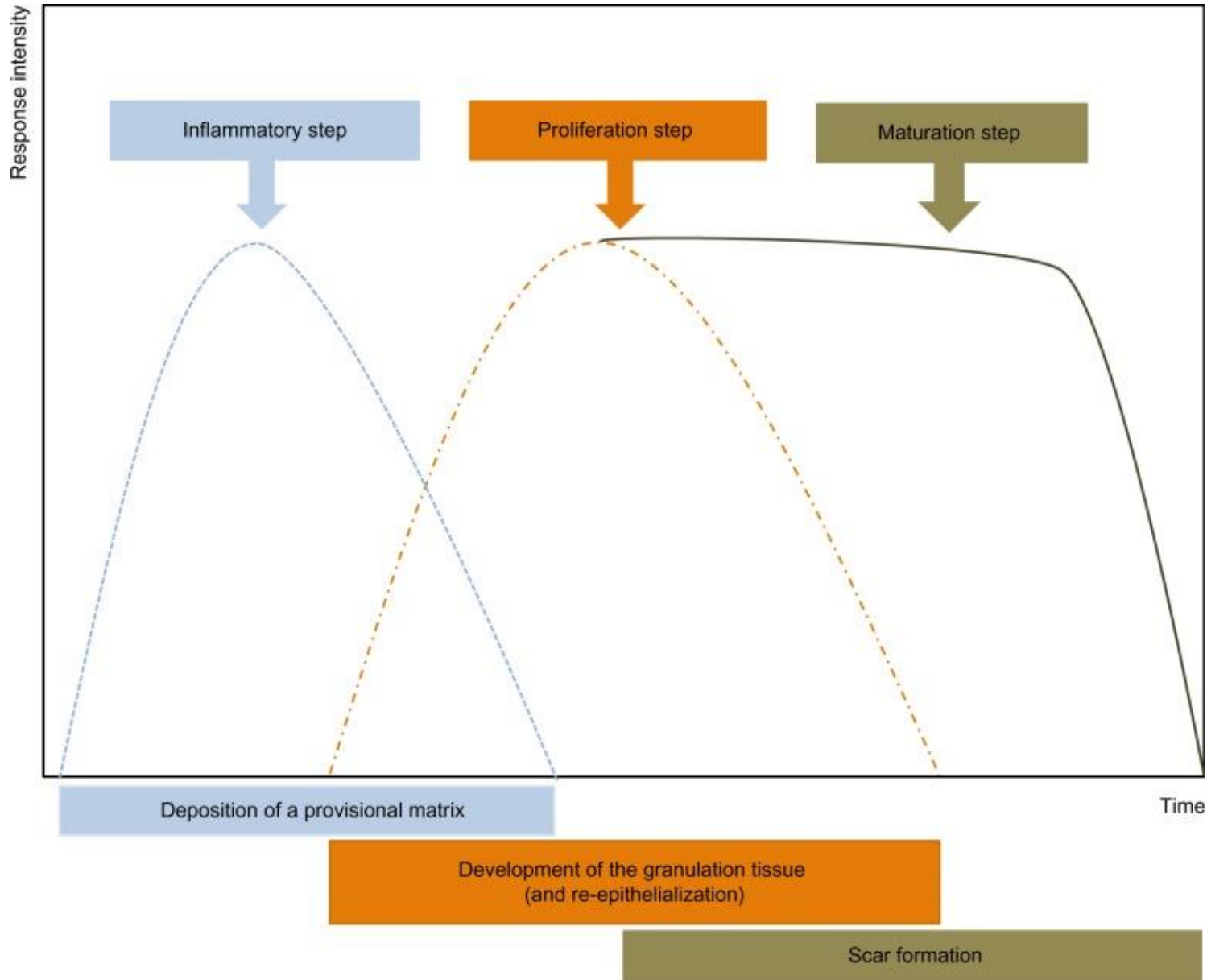
Inflammatory and repair mechanisms initiate in parallel and not in a serial way

# Fibrosis matters in many types of lung injury

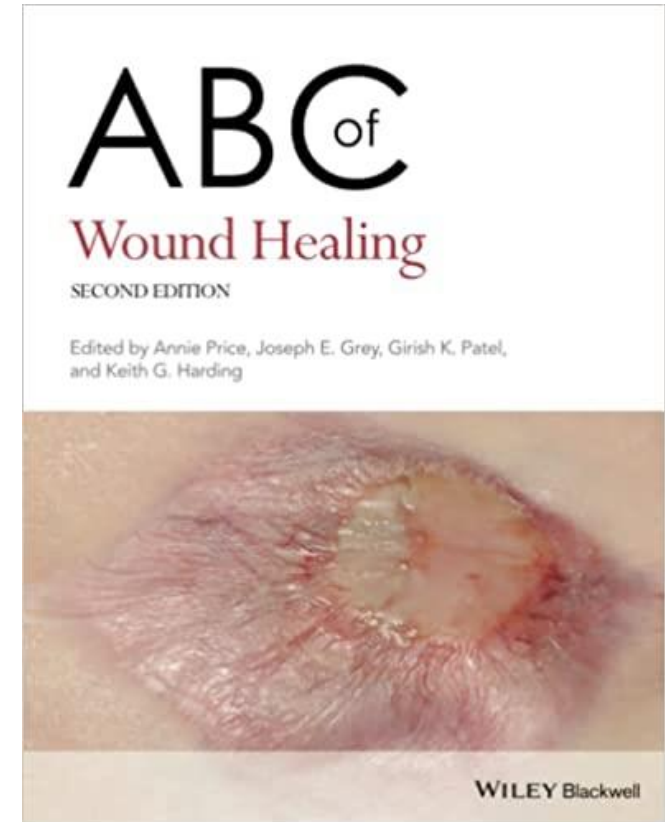


# Current therapeutic approach

- **Do no harm!! No more injury!!**
- Lung protective ventilation; limit the driving pressure
  - Low tidal volume
  - ECMO
  - NO inhalation
- Keep the lung homogenous
  - Prone position
  - Recruitment

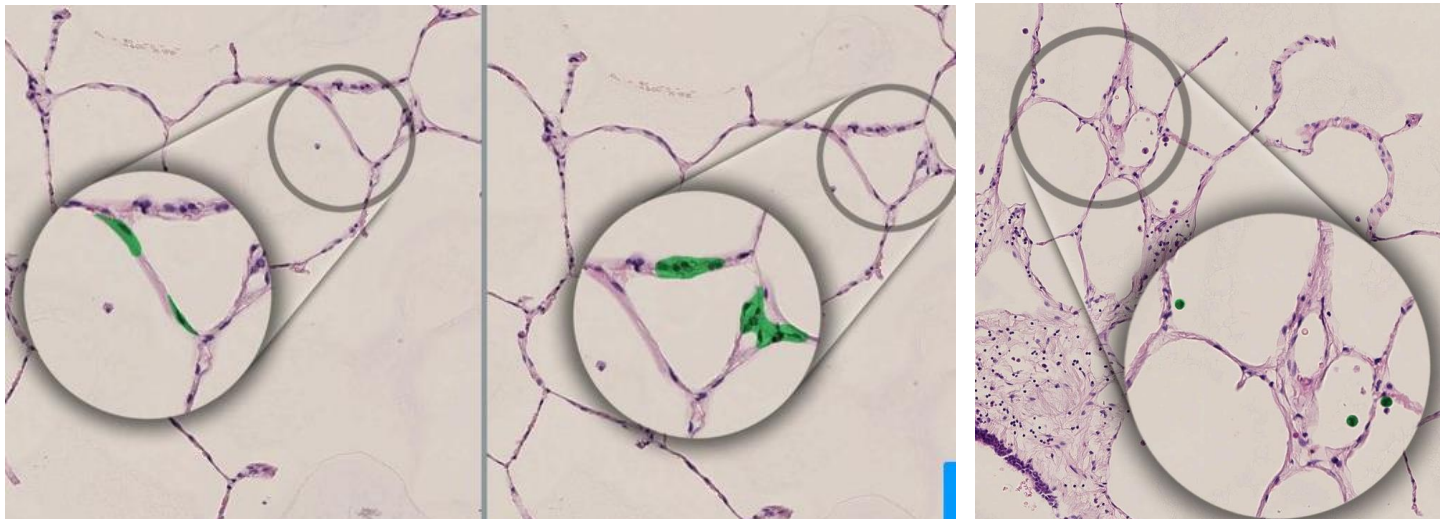


## 3 steps of wound healing



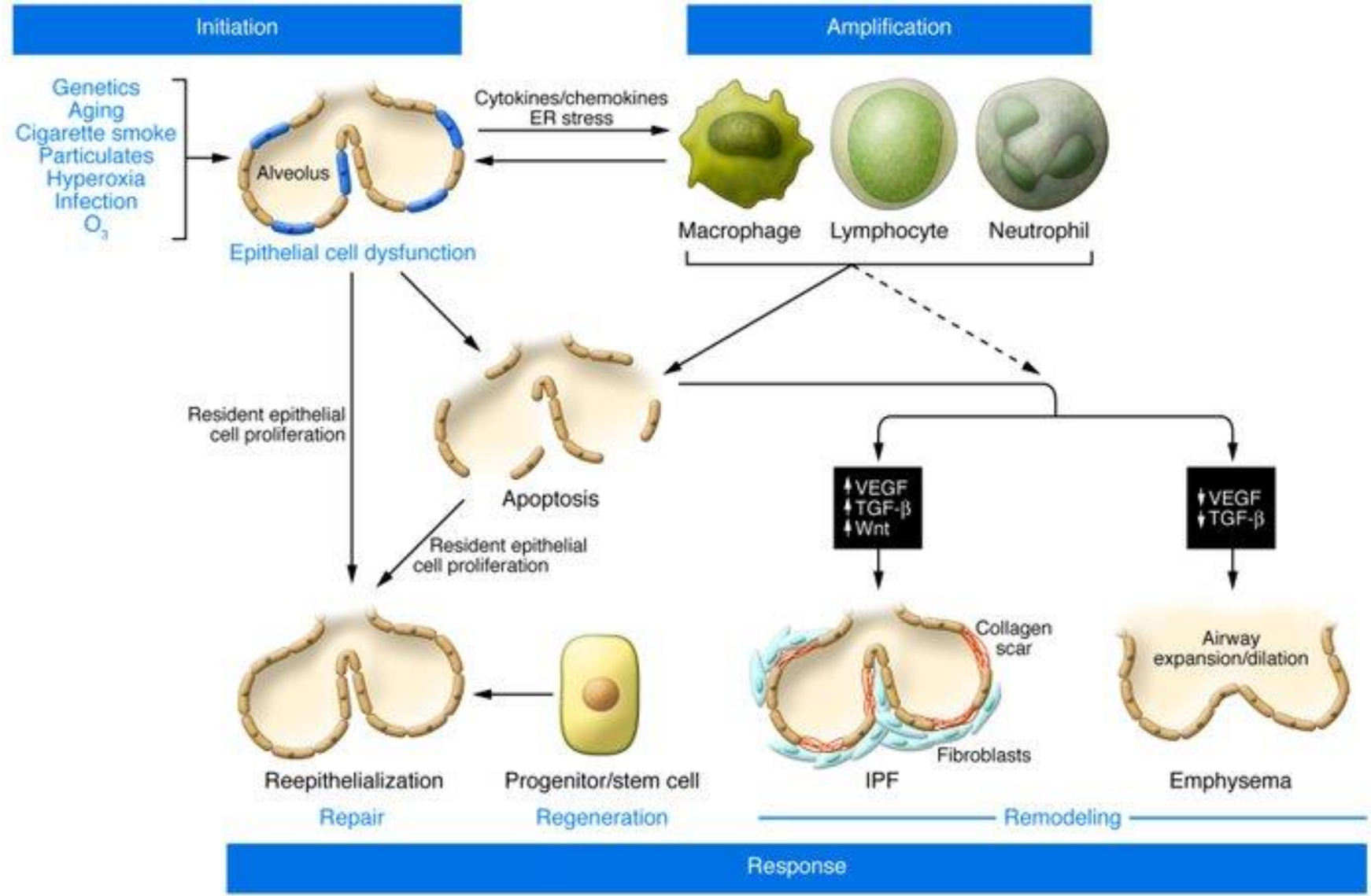
# Fibroproliferative phase

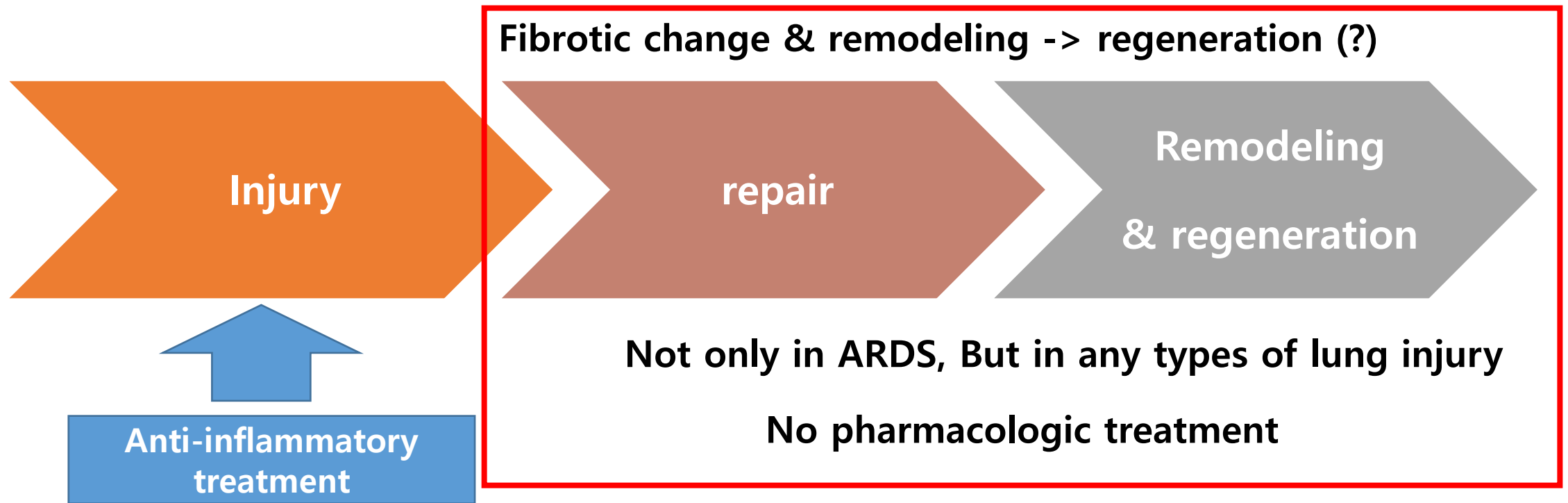
- Migration of mesenchymal cells
- Deposit of connective tissue
- Normal repair & regeneration: AEC II -> AEC I



Type I alveolar cell (AEC I) Type II alveolar cell (AEC II) Alveolar macrophage

# The epithelial-mesenchymal wound model for lung injury and repair





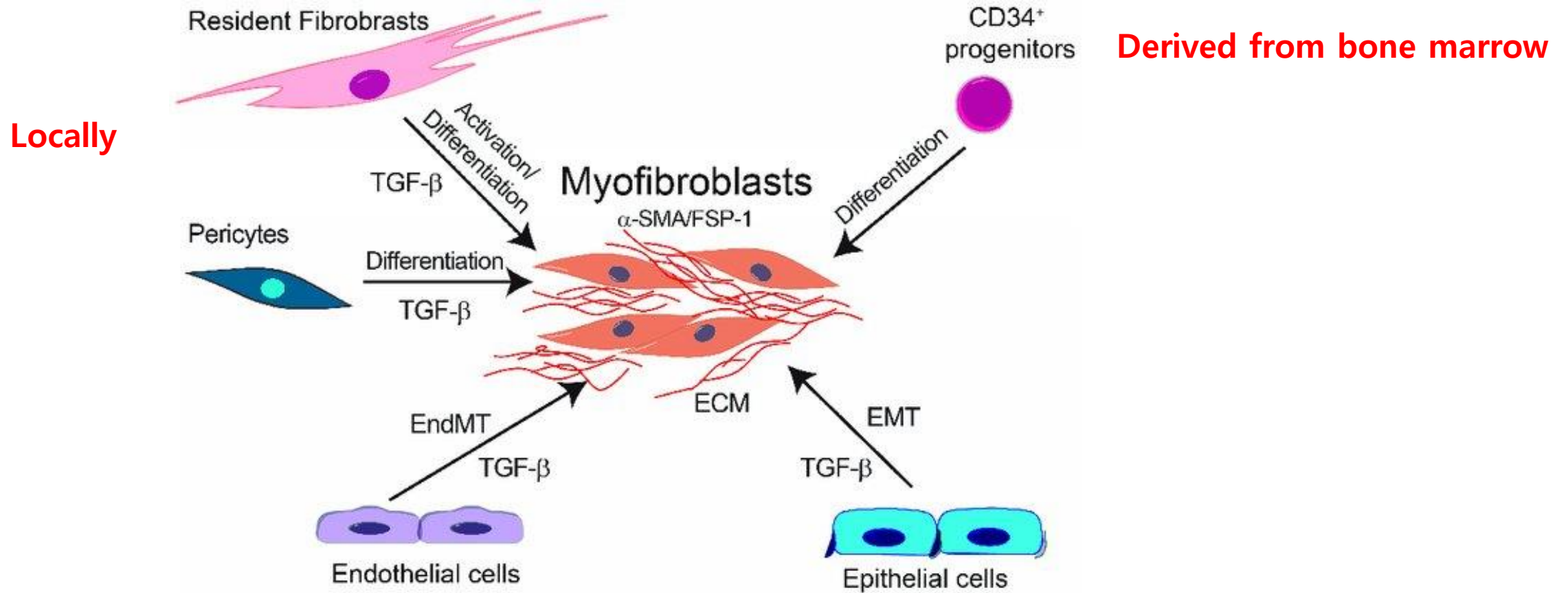
**Cause of aberrant wound healing ?**

**Repetitive injury or defect on healing mechanism**

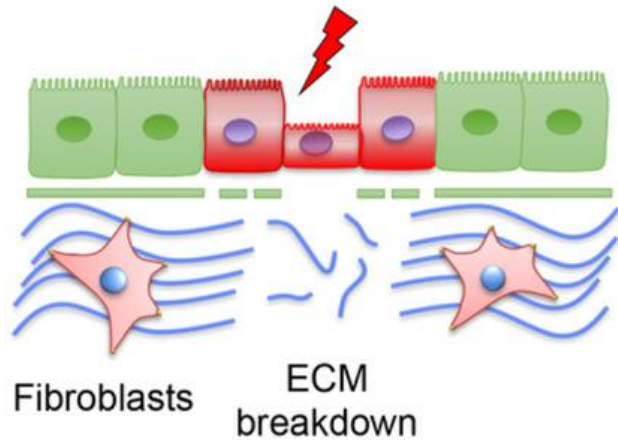
# Defects on remodeling leads to fibrosis ?

- Target : Myofibroblasts
  - a further differentiated subset of fibroblasts
  - acquire the **cytoskeletal characteristics** of contractile smooth muscle cells via their production of  $\alpha$ -smooth muscle actin ( $\alpha$ -SMA)
- Target: Collagen degradation
  - Matrix metalloproteinase (MMP)
  - Plasminogen activator inhibitor-1 (PAI-1)

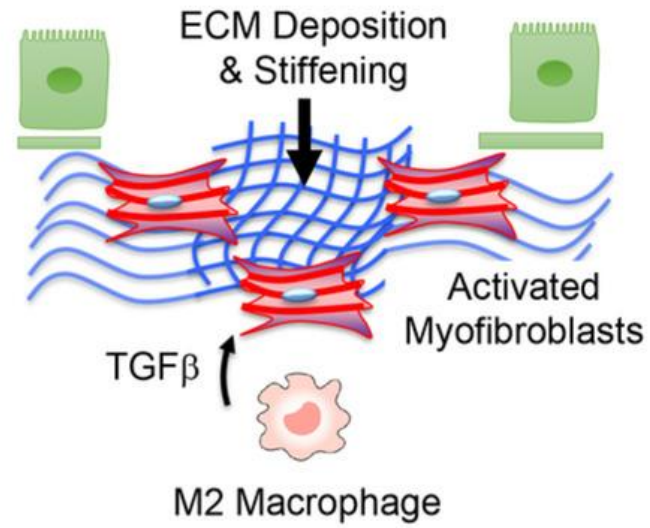
# The origin of myofibroblast in wound healing



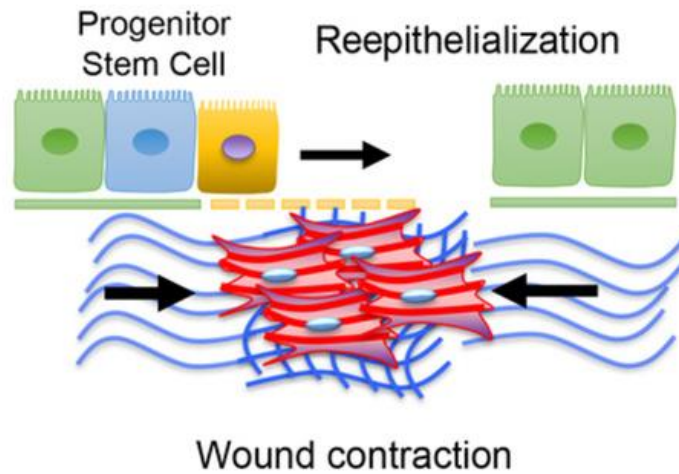
## TISSUE INJURY



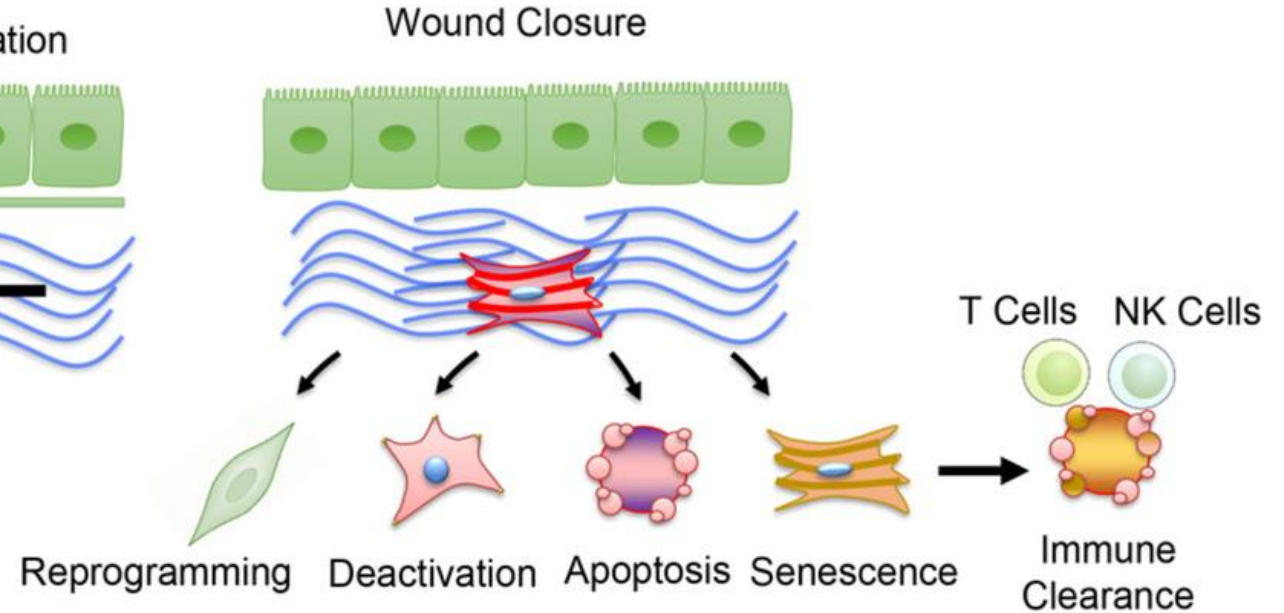
## INFLAMMATION/FIBROPLASIA



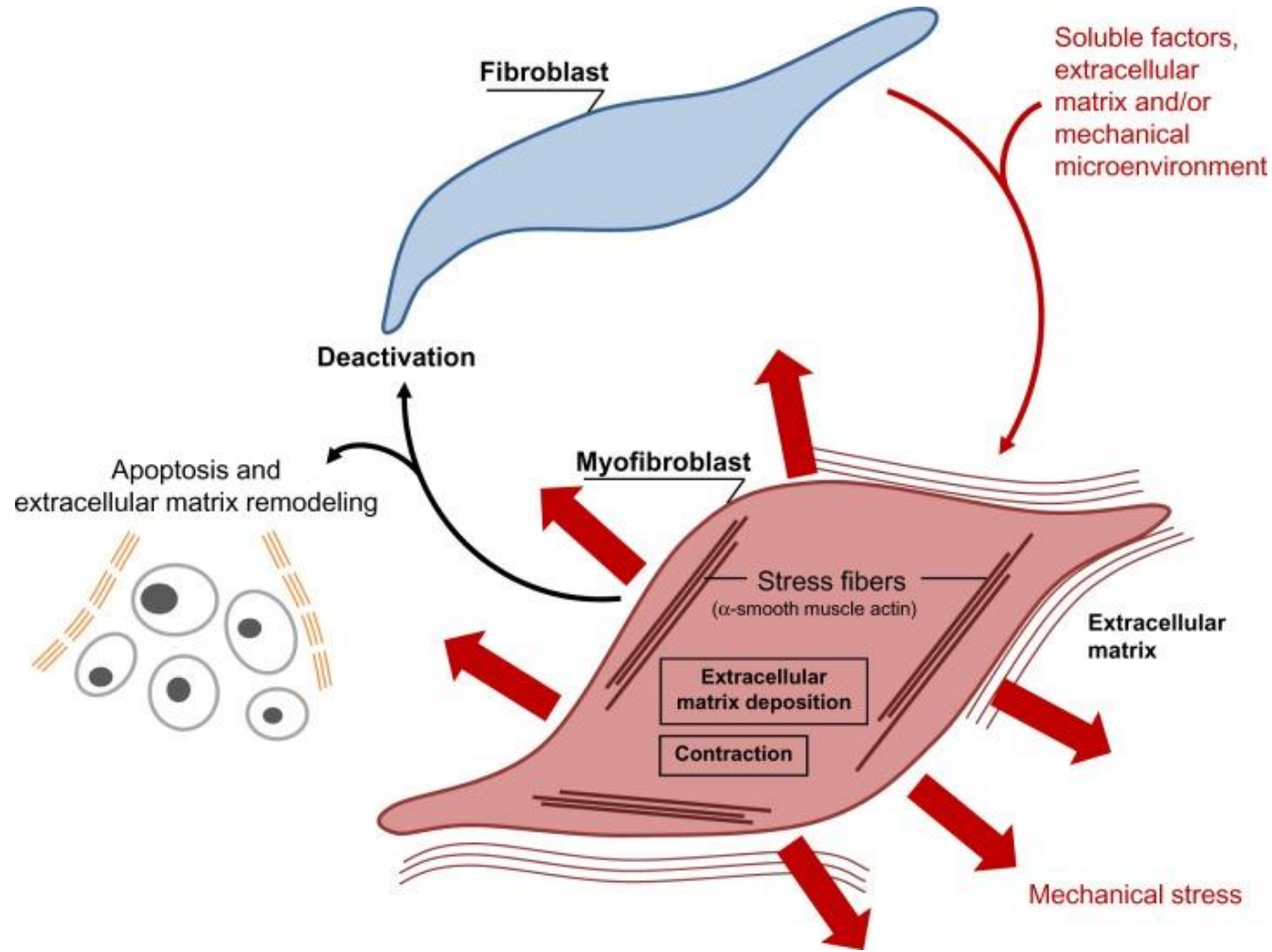
## REMODELLING



## RESOLUTION

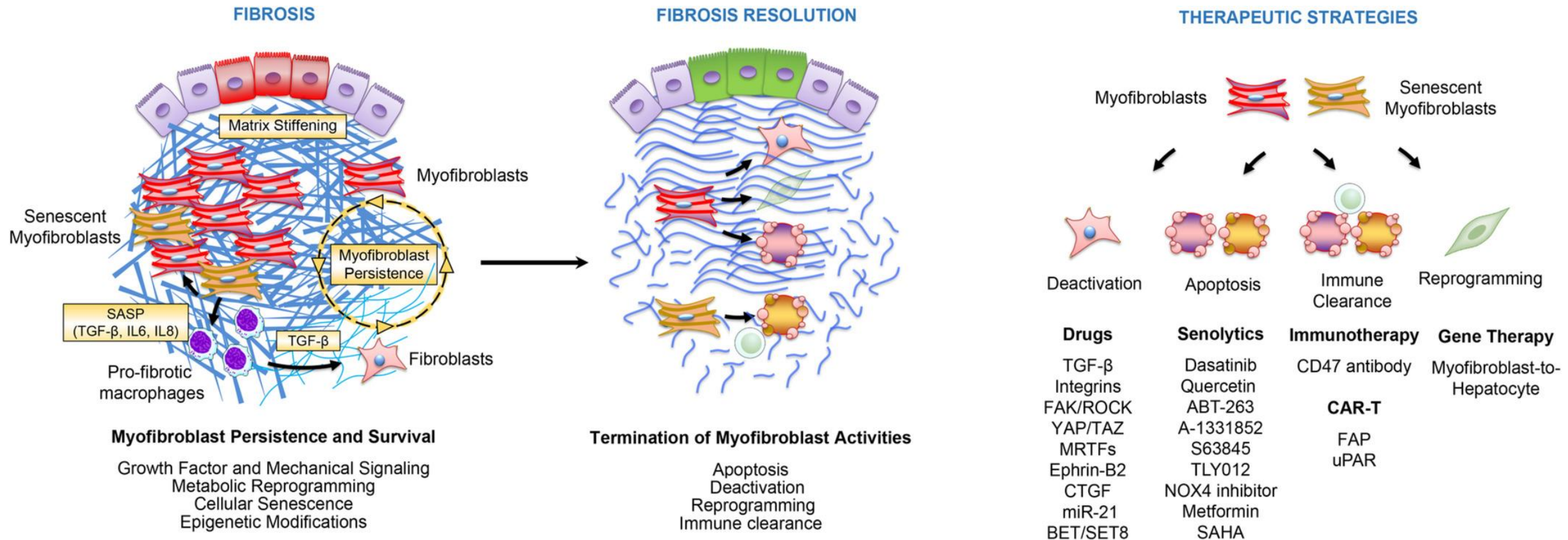


During normal wound healing, myofibroblasts undergo apoptosis when epithelialization has completed.



On the contrary, in the pathological scenario, myofibroblasts persist and continue to synthesize collagen, leading to the fibrotic degeneration.

# Potential therapeutic approach



# Evidence for impaired collagen degradation leading to fibrosis in vivo

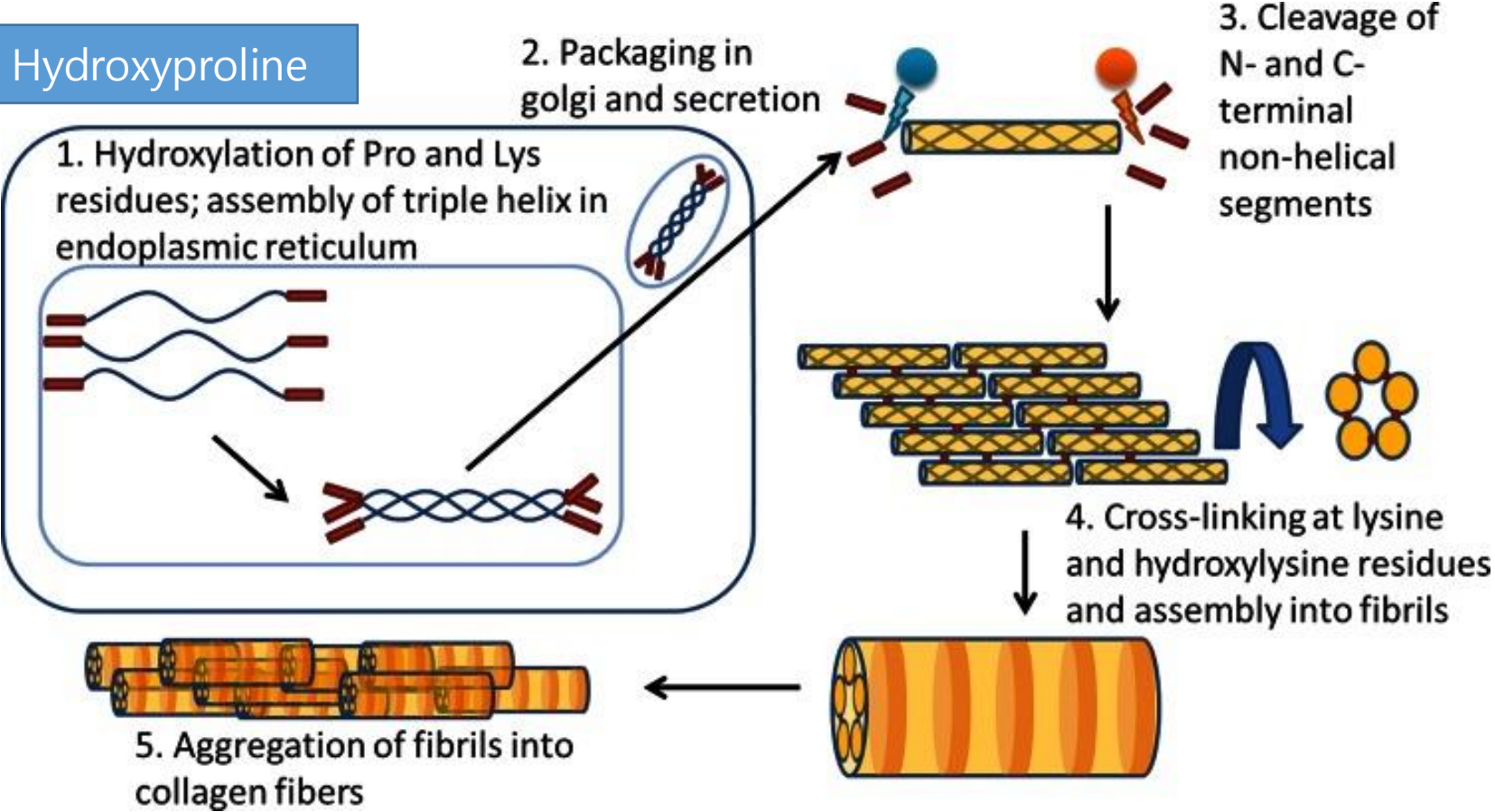
Experimental Population	Mechanism of Impaired Degradation
IPF/UIP	Increase ratio of TIMPs to collagenases Decreased collagenolytic activity
Scleroderma	Decreased collagenolytic activity
ARDS/ALI	Decreased degradation of type I collagen in vivo with more severe disease
bleomycin-induced lung fibrosis (mice)	Collagen accumulation due to impaired collagen binding /phagocytosis

# Extracellular matrix organization in ARDS

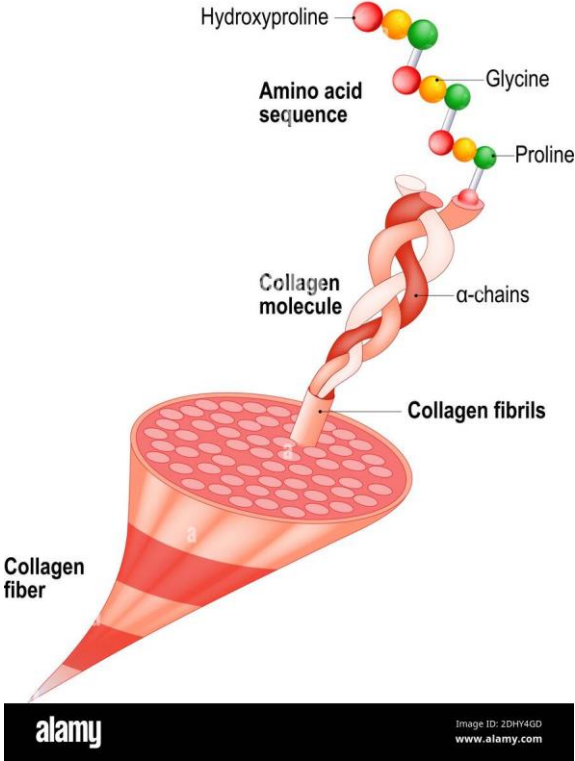
- Three groups of macromolecules are physically associated to form the extracellular matrix:
  - 1) fibrous structural proteins, like **collagen** and elastic fibers
  - 2) glucoproteins, including fibronectin and laminin
  - 3) proteoglycans
- These macromolecules are organized into 2 portions in the tissue:  
**interstitial matrix and basal membrane**

# Collagenous fibers synthesis

Hydroxyproline

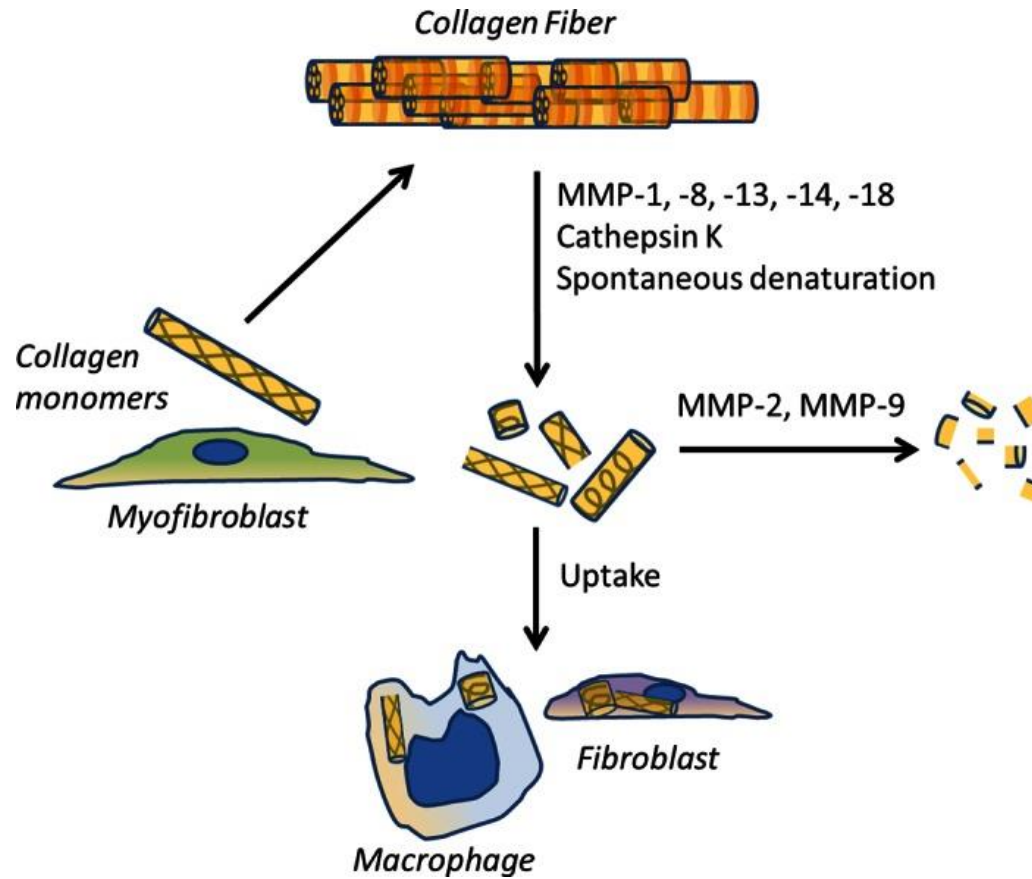


## Collagen



Collagen synthesis begins with the translation of collagen pro- $\alpha$  chains in the rough ER. After these chains form a triple helix, the molecule is secreted from the cell, where it undergoes further processing and aggregation into fibrils and fibers.

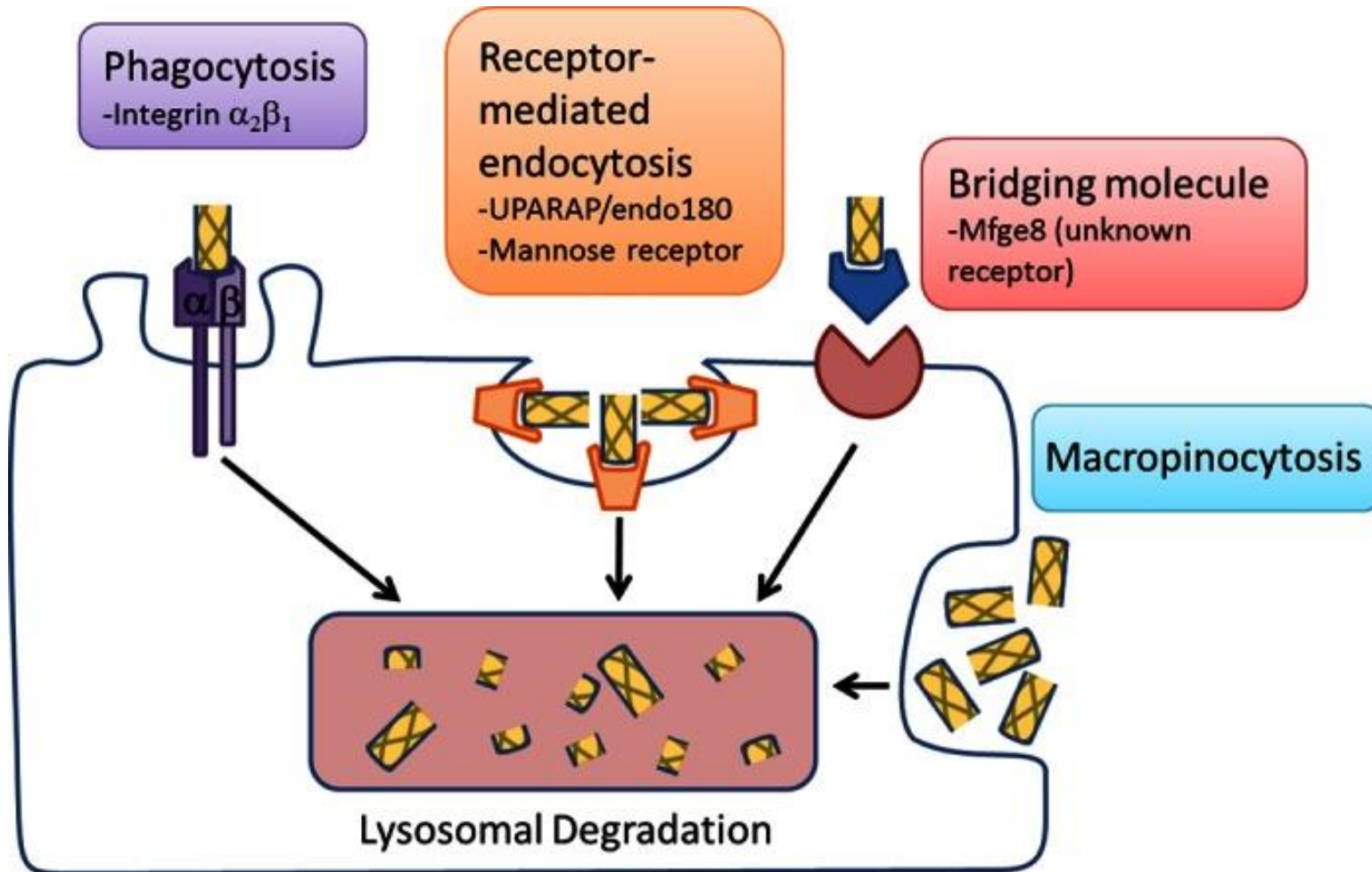
# Collagenous degradation



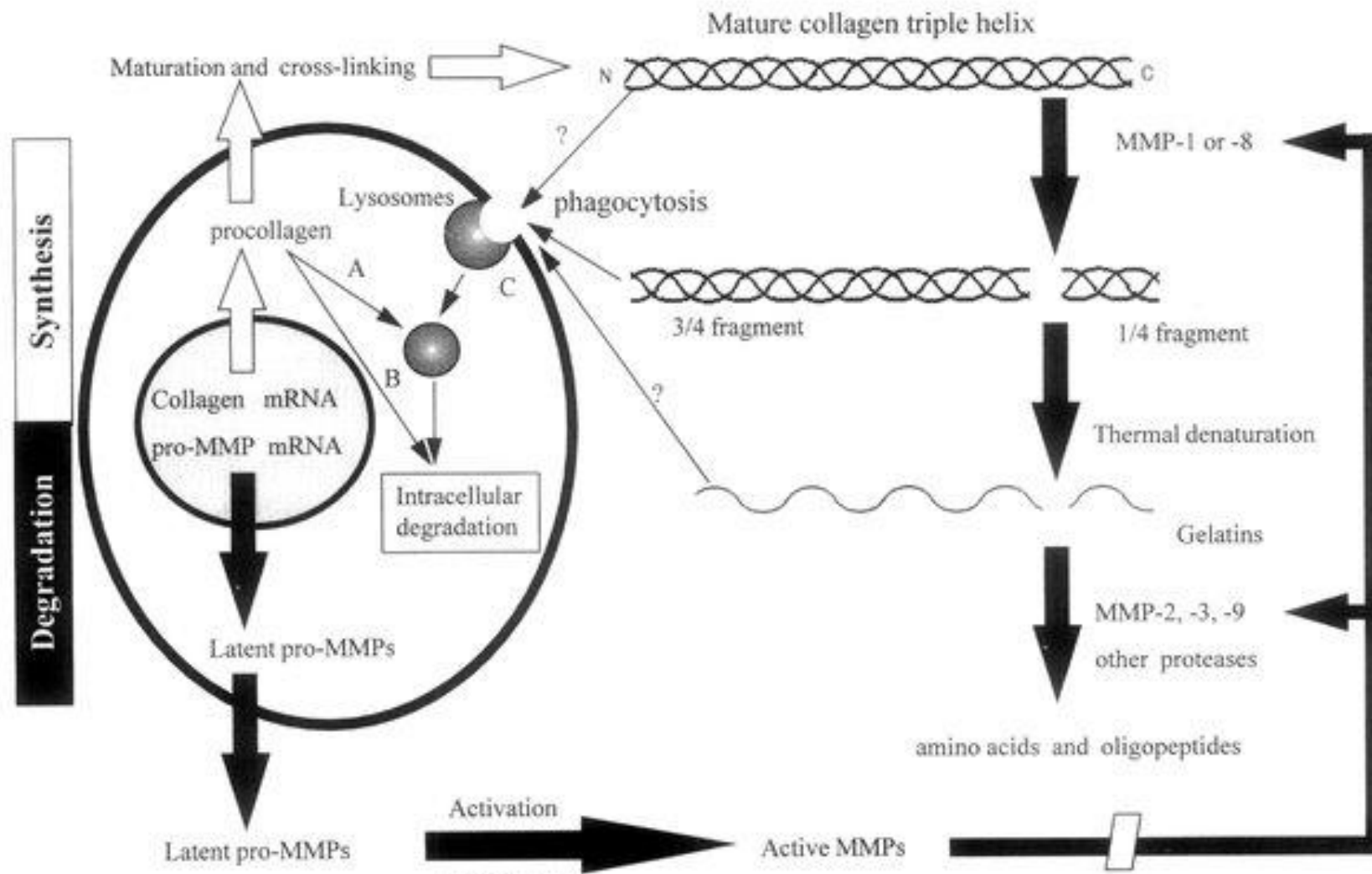
**MMP**, matrix metalloproteinase.

Degradation of collagen fibers involves **cleavage of fibrils by collagenolytic enzymes and uptake of collagen fragments by macrophages and fibroblasts** or further cleavage by gelatinases.

# Degraded collagen fiber



# Collagen turnover pathways

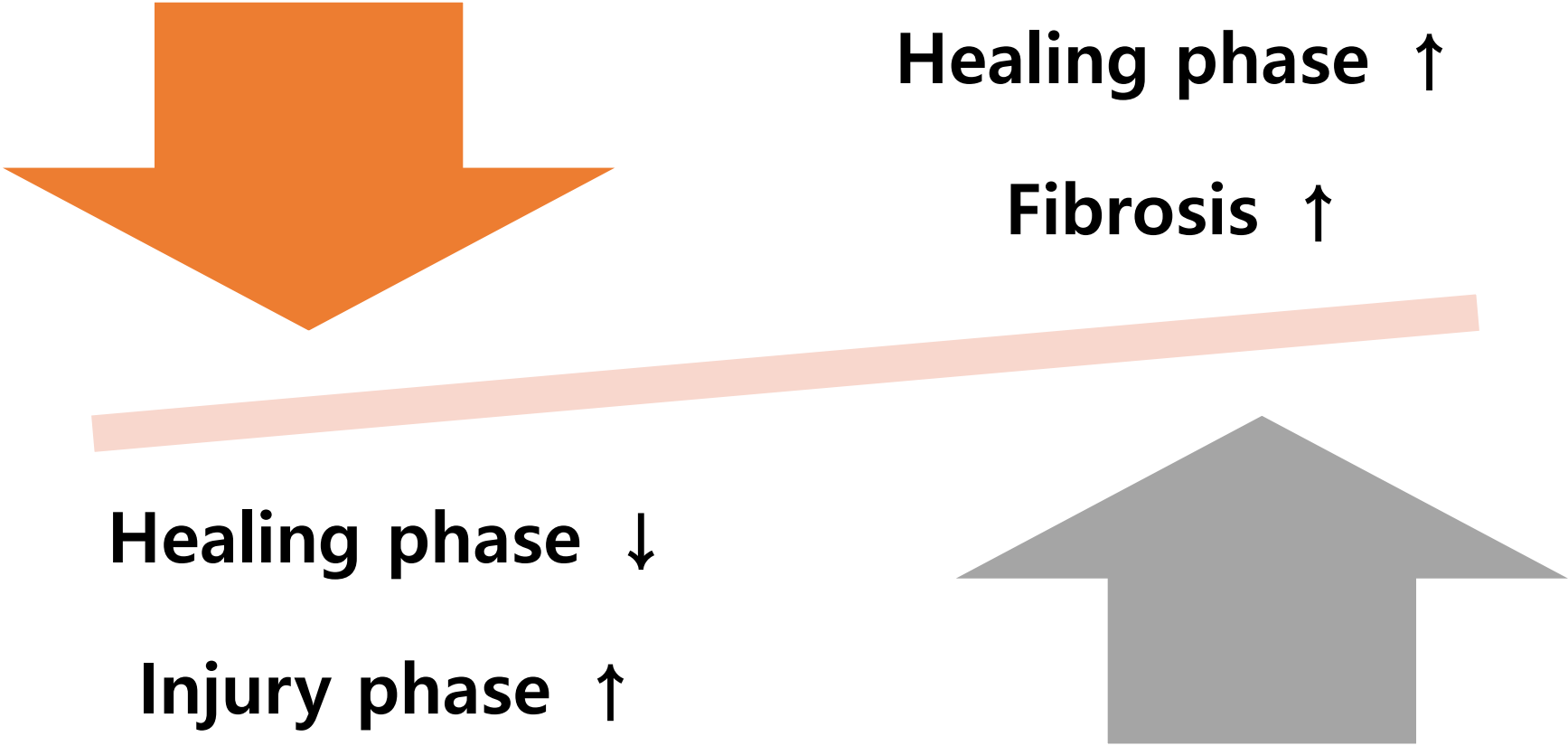


**MMP,**  
**Profibrotic roles?**  
**Net effect ?**

# Changes in Collagen Turnover in Early Acute Respiratory Distress Syndrome

- **Collagen turnover** in the lung is a dynamic process, necessary to maintain normal architecture.
- **Total C-terminal propeptide(PICP), a marker of type I collagen synthesis**, was increased in subjects with ARDS/ALI in comparison with At Risk subjects.
- **COL2-3/4C<sub>short</sub>, a marker of collagen degradation**, was decreased in ARDS compared with At Risk subjects.
- **Balance between synthesis and degradation** in ARDS favors net **type I collagen deposition**.

# Net effect ?



# **Antifibrotics in COVID-19 Lung Disease: Let Us Stay Focused**

Front. Med., 09 September 2020

# **Pulmonary fibrosis and COVID-19: the potential role for antifibrotic therapy**

Lancet Respir Med 2020; 8: 807–15

# Take Home Message

- ARDS is a heterogenous disease, leading to pulmonary fibrosis following serious lung injury.
- The mechanism of remodeling or regeneration of injured lung tissue has not fully revealed.
- The net collagen turnover favors accumulation of collagen in healing process.
- Maybe stopping further injury process is easier than reversing the pathogenic fibrosis to normalized wound healing.