

CT Finding of Lung Cancer and Differential Diagnosis

울산의대 서울아산병원

영상의학과 흉부 Section

김미영

mimowdr@gmail.com



Introduction

- Focusing on CT Imaging, Real Field

- 1) 전암 병변 및 초기 폐암을 시사하는 폐 결절의 영상학적 구분
- 2) 폐암을 시사하는 흉부 CT 영상 소견
- 3) 폐암의 단계별 감별 진단 (8th Edition of staging system).
- 4) 양성과 악성 결절 시사하는 소견
- 5) 임파선 전이를 시사하는 영상학적 소견
- 6) 늑막 전이를 시사하는 영상학적 소견
- 7) EGFR, ALK 등 유전자 돌연변이를 동반하는 폐암의 영상학적 특징
- 8) Nodule management
- 9) PCNB (Percutaneous Lung biopsy) 의 대상 선정과 성적
- 10) Lung cancer의 high risk factor 에 대한 영상학적 고려

- 1) 전암 병변 및 초기 폐암을 시사하는 폐 결절의 영상학적 구분
- 2) 폐암을 시사하는 흉부 CT 영상 소견
- 3) 폐암의 단계별 감별 진단 (8th Edition of staging system).
- 4) 양성과 악성 결절 시사하는 소견
- 5) 임파선 전이를 시사하는 영상학적 소견
- 6) 늑막 전이를 시사하는 영상학적 소견
- 7) EGFR, ALK 등 유전자 돌연변이를 동반하는 폐암의 영상학적 특징
- 8) Nodule management
- 9) PCNB (Percutaneous Lung biopsy) 의 대상 선정과 성적
- 10) Lung cancer의 high risk factor 에 대한 영상학적 고려

CT imaging spectrum of lung cancer

- Pure GGN
- Part-solid GGN (=Subsolid GGN)
- Solid lesion
 - Nodule, <30mm
 - Mass, >30mm

IASLC/ATS/ERS Adenocarcinoma Classification

- **Preinvasive Lesions**

Atypical Adenomatous Hyperplasia (**AAH**)

Adenocarcinoma in situ (**AIS** - formerly BAC)

-Pure GGN

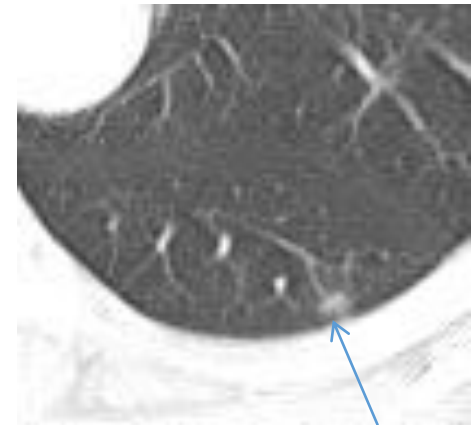
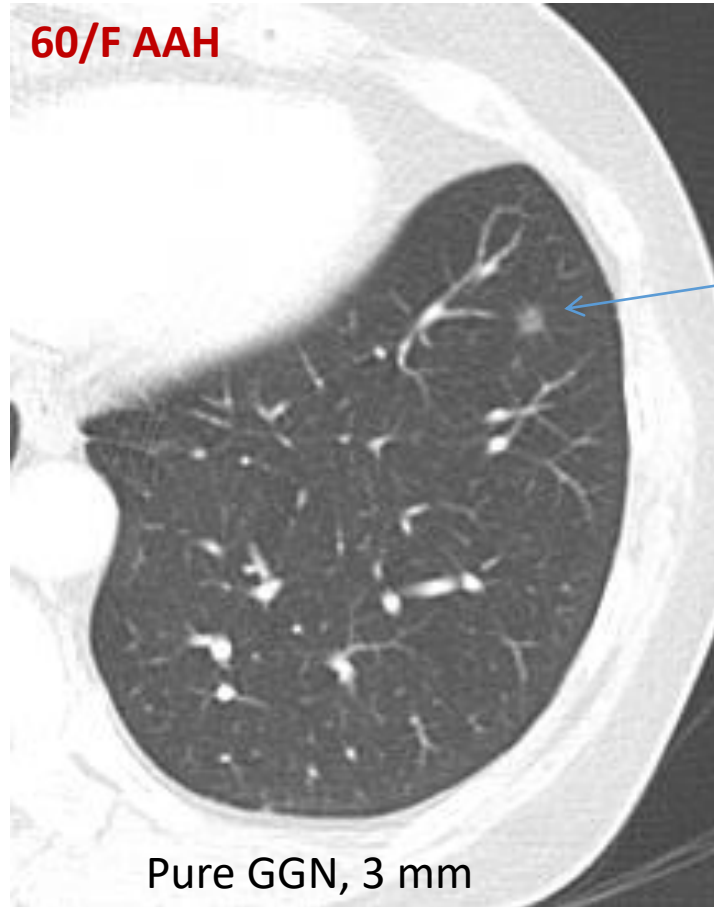
- **Minimally Invasive Adenocarcinoma (MIA)**

Lepidic-predominant tumor with $\leq 5\text{mm}$ or $< 10\%$ invasion

-Subsolid GGN

Pure GGN

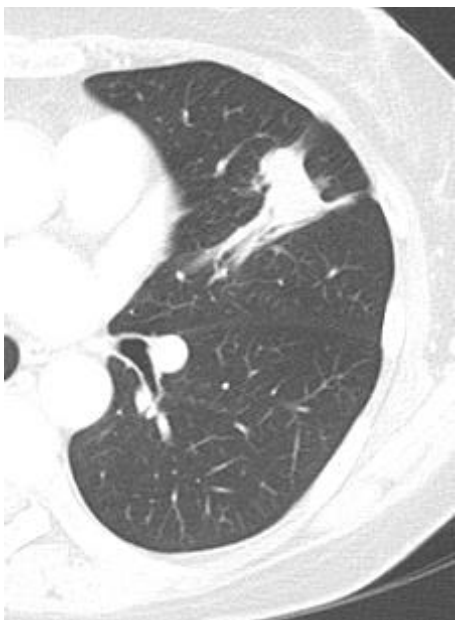- Atypical adenomatoid hyperplasia (AAH)



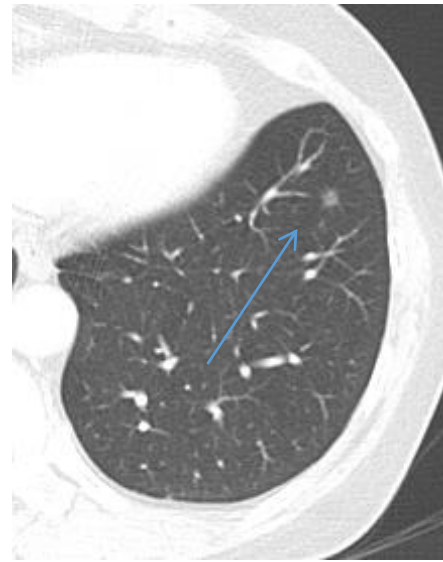
Pure GGN, 5 mm, AAH

- AAH nodules are often smaller (< 6mm) with lower attenuation or pure GGN

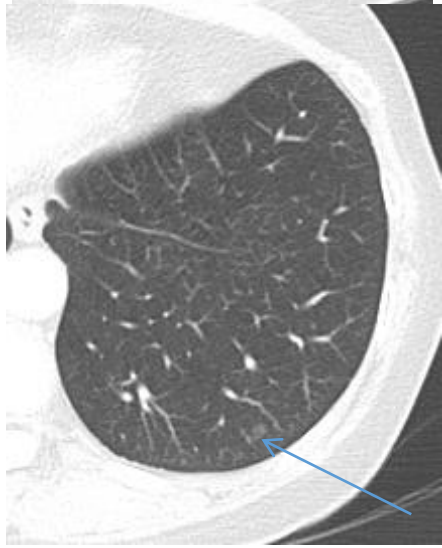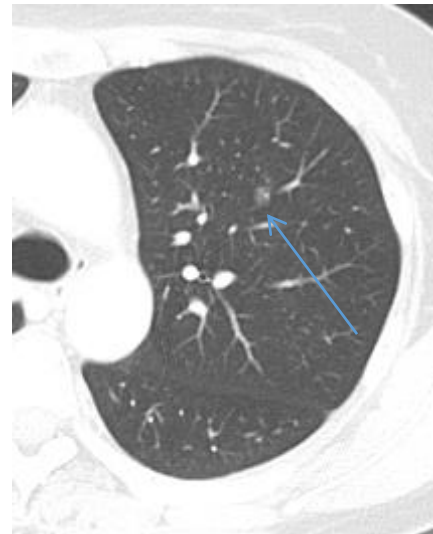60/F Adenocarcinoma in LUL with multicentric AAH




Lung, (left upper lower),
lobectomy:
ADENOCARCINOMA, T1cN0



Combined multiple pure GGNs <5mm,
Wedge resection: AAH



Pure GGN, Adenocarcinoma in Situ

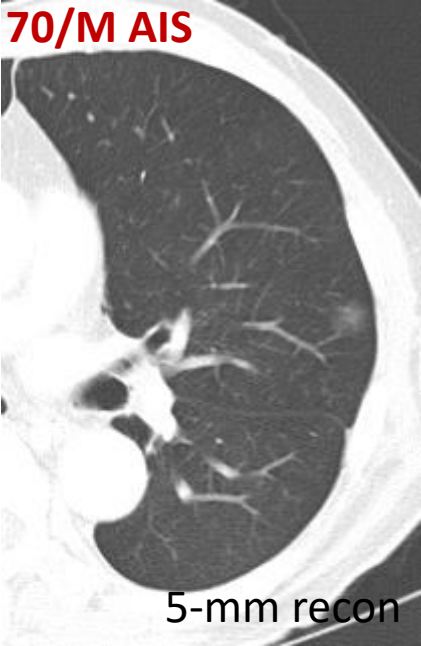

Adenocarcinoma in situ (AIS):

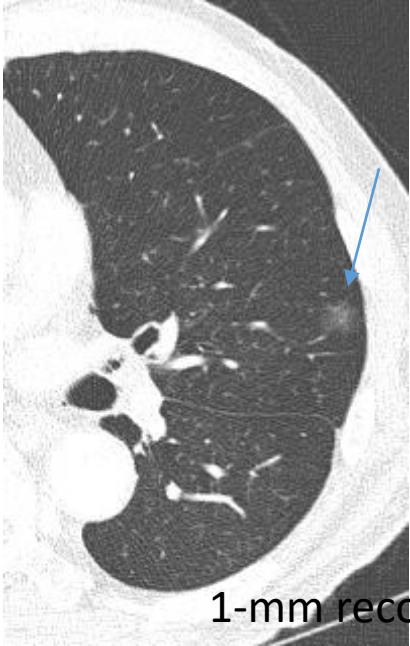- Small (≤ 3 cm)
- Pure lepidic growth
- Usually non mucinous

This phenotype (small, ground-glass or nonsolid nodule) is a surrogate marker for AIS, with excellent prognosis

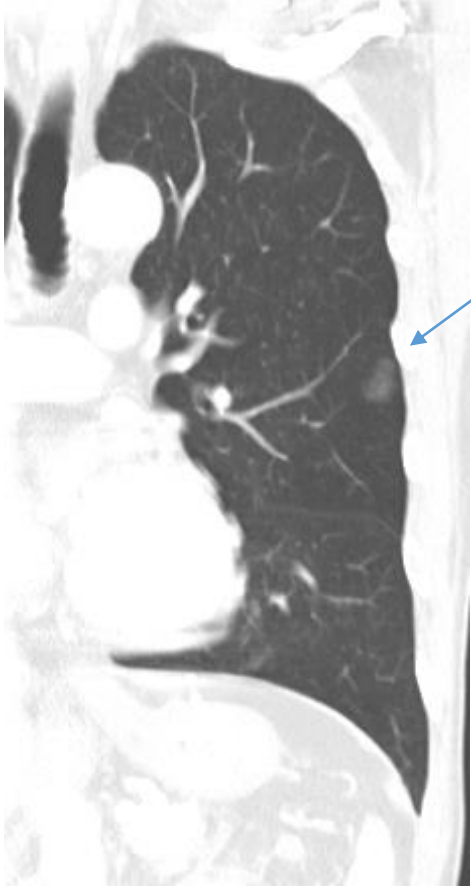70/M AIS



5-mm recon



1-mm recon

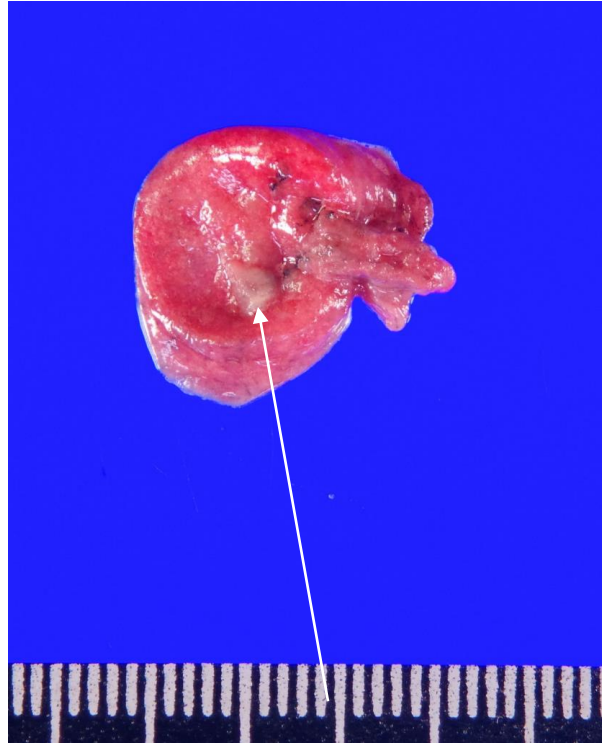
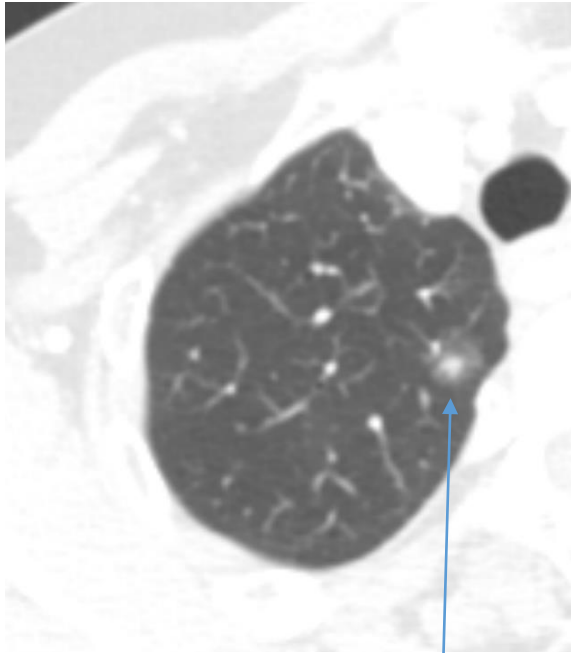


Pure GGN, 15 mm

Subsolid GGN

- Minimally Invasive Adenocarcinoma (MIA)

67/F MIA

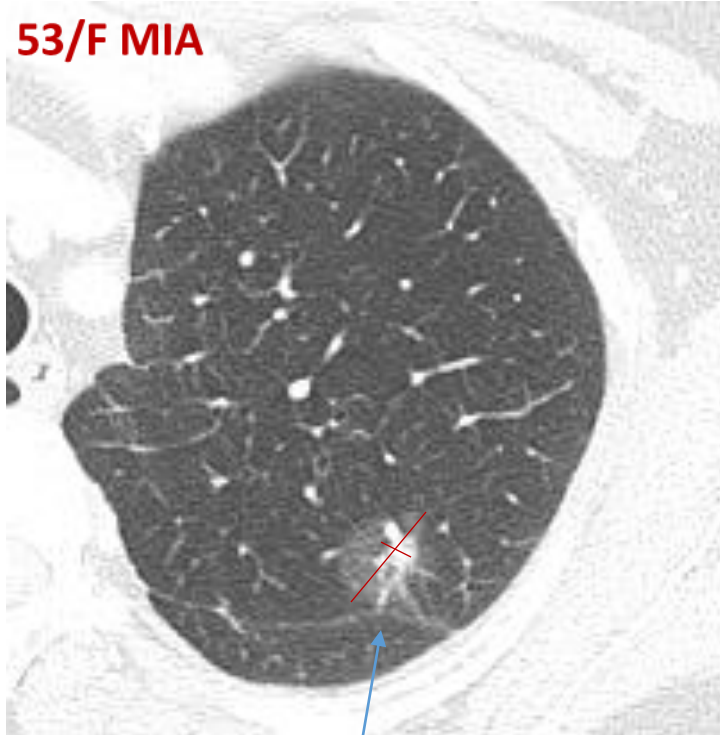


Lung, (right upper lobe),
wedge resection:
MINIMALLY INVASIVE
ADENOCARCINOMA, 6 x 4
x 3 mm, invasive
component size: 6 mm

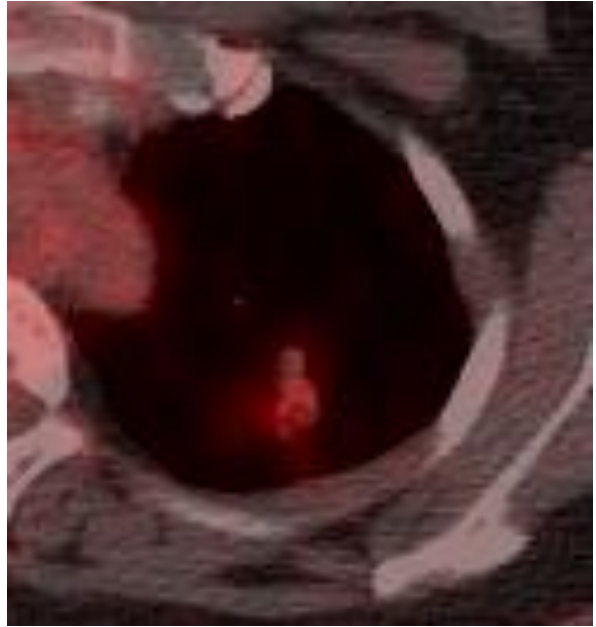
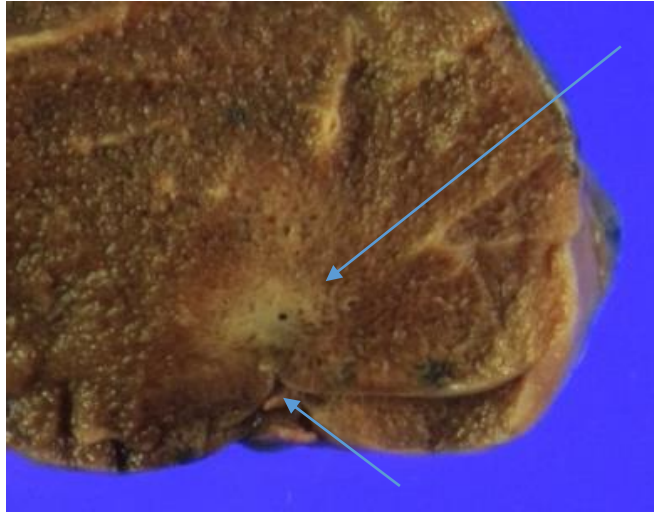
- Small (≤ 3 cm), usually solitary
- A phenotype of mainly ground-glass (lepidic tumor growth), plus a small (≤ 5 mm) central solid component (collapsed alveoli or fibroblastic proliferation)

Subsolid GGN
- Minimally Invasive Adenocarcinoma (MIA)

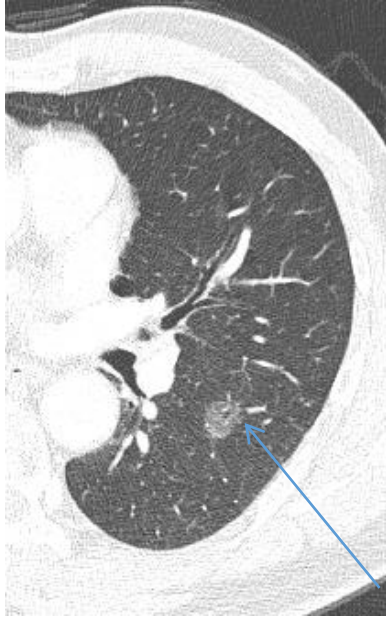53/F MIA



Part solid GGN
(GGO: 18 mm,
central solid portion: 8mm)
No significant metabolism

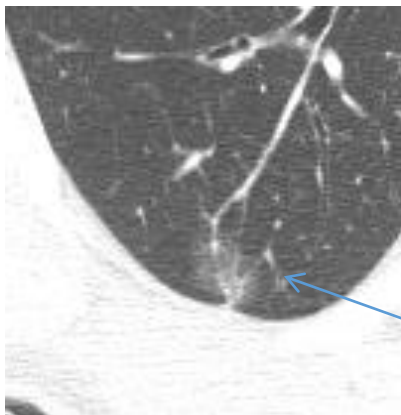


Variable MIA



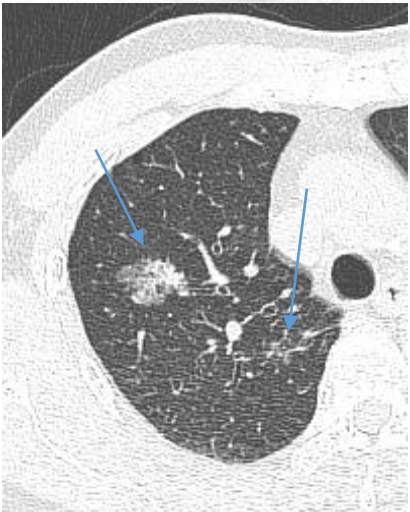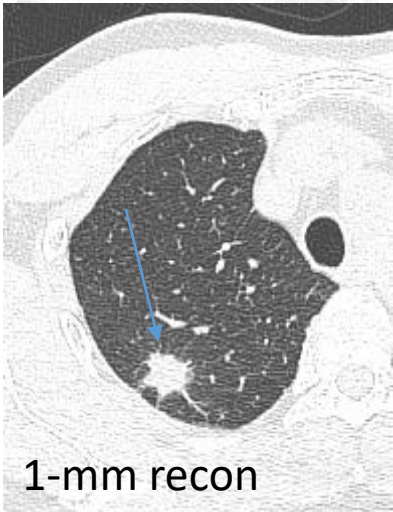
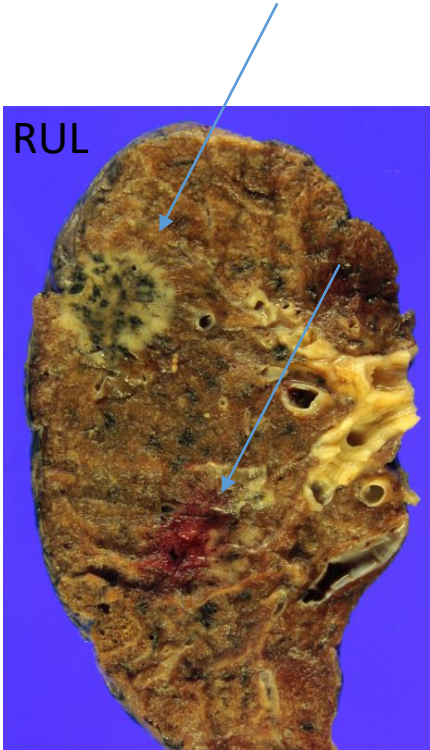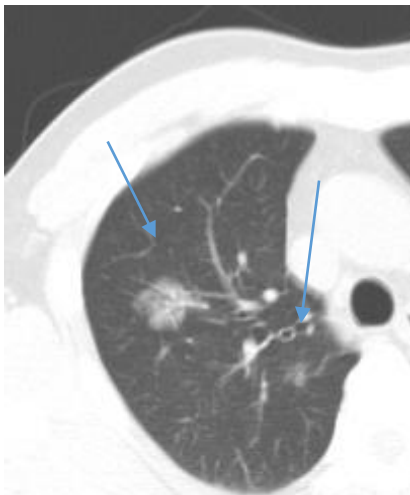
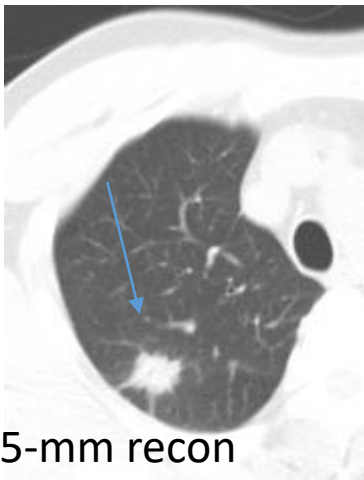
Pure GGN, 12mm, MIA

- PET-negative AIS/MIA (<5mm invasive focus on histopathology)
- initially read as benign on frozen section

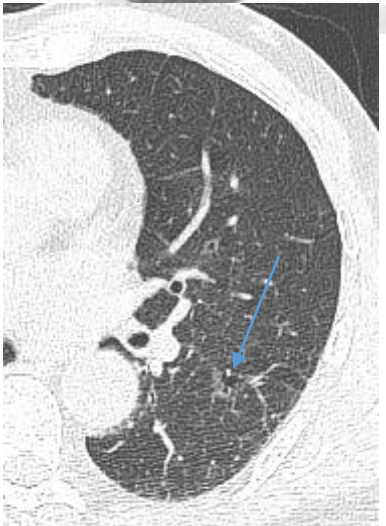
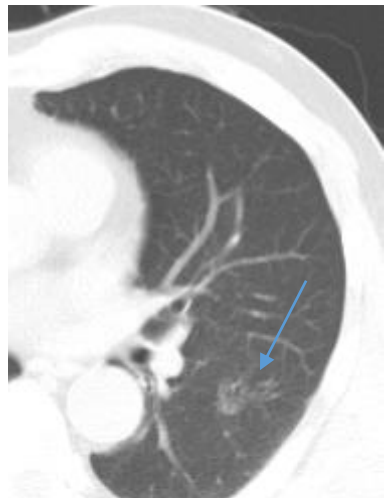
Part solid GGN, 18mm (<6mm solid), MIA

61/M Three multicentric ADC in RUL



One MIA in LLL

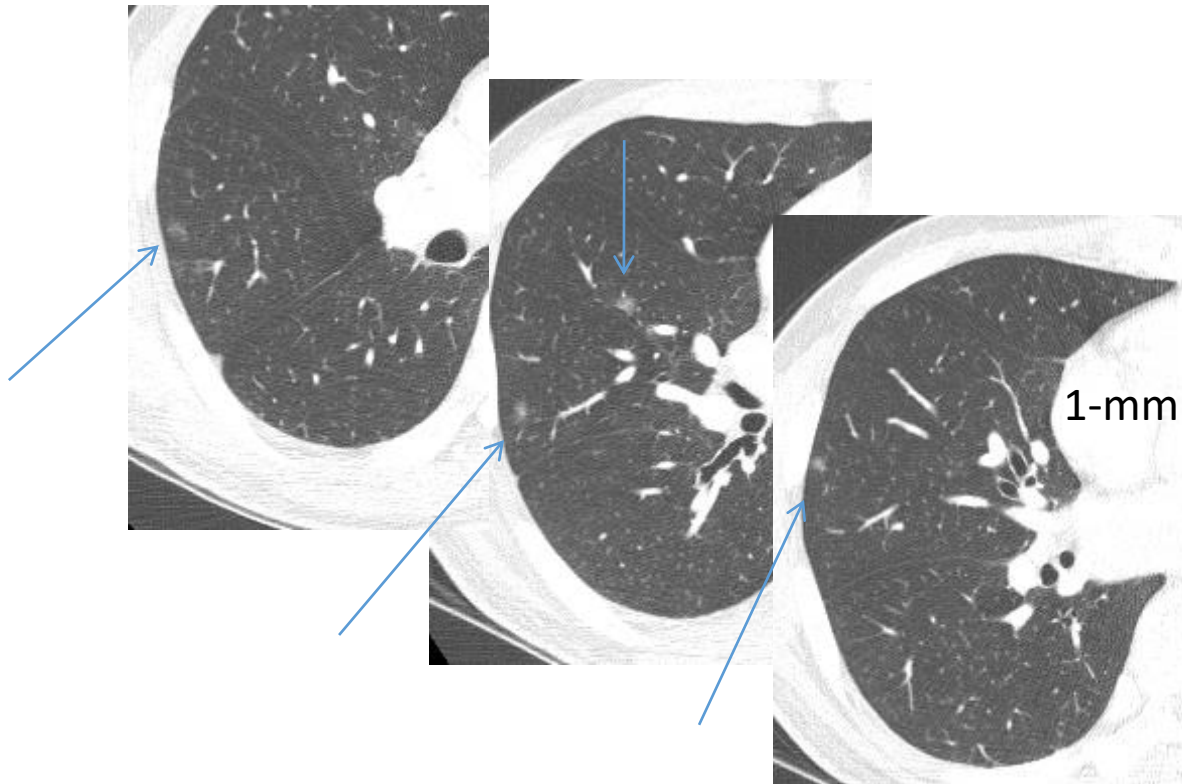


Solid: ACINAR PREDOMINANT TYPE on RUL lobectomy

Part-solid: PAPILLARY PREDOMINANT TYPE x2 on RUL lobectomy

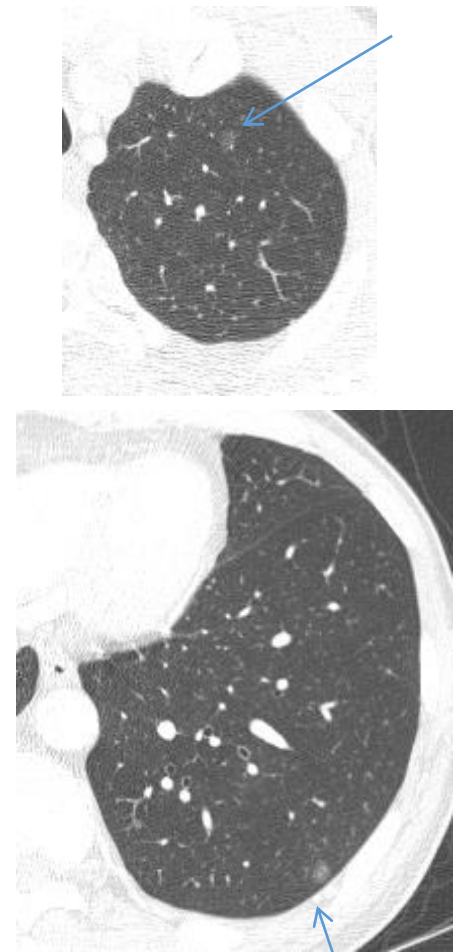
Pure GGN, MIA, wedge resection of LLL, LEPIDIC, 100 %

50/M AAH, AIS, MIA, Multicentric



Lung, (right middle lobe), wedge resection:

- AAH, < 5mm, multifocal
- AIS, 6 mm
- MIA, 8 mm



Pure GGNs

Stage I or Stage IV ?

- Multiple nodules are reported in 15 to 30 % cases
- AAH, often associated with malignancy

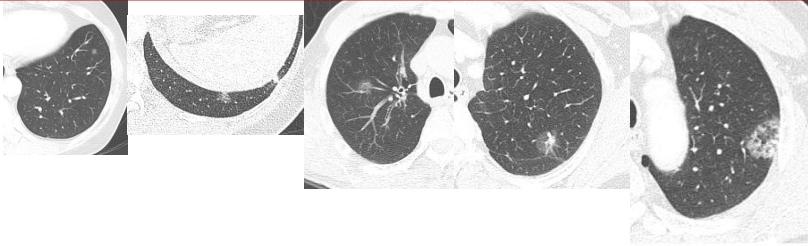
Table 5. Schematic Summary of Patterns of Disease and TNM Classification of Patients with Lung Cancer with Multiple Pulmonary Sites of Involvement

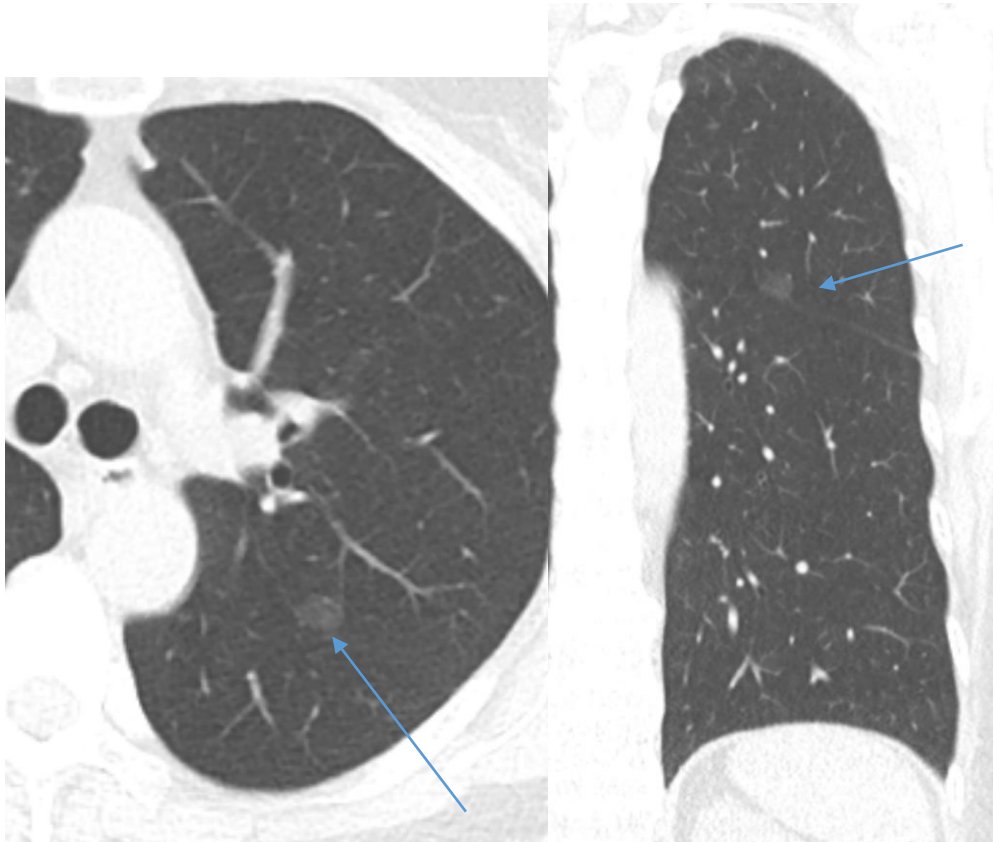
	Second Primary Lung Cancer	Multifocal GG/L Nodules	Pneumonic-Type Adenocarcinoma	Separate Tumor Nodule
Imaging features	Two or more distinct masses with imaging characteristic of lung cancer (e.g., spiculated)	Multiple ground glass or part-solid nodules	Patchy areas of ground glass and consolidation	Typical lung cancer (e.g., solid, spiculated) with separate solid nodule
Pathologic features	Different histotype or different morphologic features by comprehensive histologic assessment	Adenocarcinomas with prominent lepidic component (typically varying degrees of AIS, MIA, LPA)	Same histologic features throughout (most often invasive mucinous adenocarcinoma)	Distinct masses with the same morphologic features by comprehensive histologic assessment
TNM classification	Separate cTNM and pTNM for each cancer	T based on highest T lesion with (#/m) indicating multiplicity; single N and M	T based on size or T3 if in single lobe, T4 or M1a if in different ipsilateral or contralateral lobes; single N and M	Location of separate nodule relative to primary site determines if T3, T4, or M1a; single N and M
Conceptual view	Unrelated tumors	Separate tumors, albeit with similarities	Single tumor, diffuse pulmonary involvement	Single tumor, with intrapulmonary metastasis

AIS, adenocarcinoma in situ; c, clinical; GG/L, ground glass/lepidic; LPA, lepidic-predominant adenocarcinoma; MIA, minimally invasive adenocarcinoma; p, pathological; TNM, tumor, node, and metastasis.

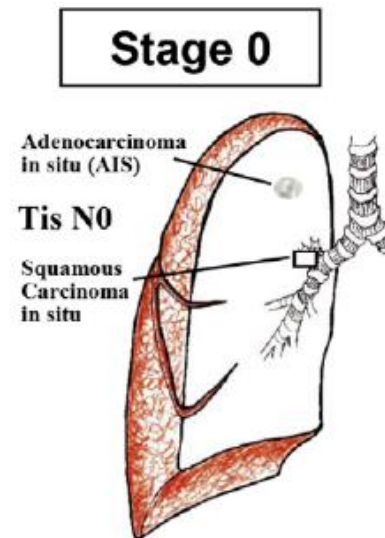
Lung cancer — major changes in the American Joint Committee on Cancer eighth edition cancer staging manual

cT*	CT image on HRCT						
	Solid part Total tumor size including GG Pathologic Differential Diagnosis	0 ≤0.5 cm AAH‡, AIS, MIA	0 cm 0.6-3.0 cm AIS, MIA, LPA	≤0.5 cm† ≤3.0 cm†† MIA, LPA, AIS	0.6-1.0 cm† 0.6-3.0 cm†† LPA, Invasive AD, MIA	1.1-2.0 cm† 1.1-3.0 cm†† LPA, Invasive AD	2.1-3.0 cm† 2.1-3.0 cm†† Invasive AD
Clinical Stage*			cTis	cT1mi	cT1a	cT1b	cT1c
pT	Invasive part	0	0 cm	≤0.5 cm†	0.6-1.0 cm†	1.1-2.0 cm†	2.1-3.0 cm†
	Total tumor size including lepidic growth part	Usually ≤0.5 cm‡	≤3.0 cm	≤3.0 cm	0.6-3.0 cm††	1.1-3.0 cm††	2.1-3.0 cm††
	Pathology	AAH	AIS	MIA	Lepidic predominant AD or Invasive AD with lepidic component	Invasive AD with a lepidic component or lepidic predominant AD	Invasive AD with lepidic component
Pathologic Stage			pTis	pT1mi	pT1a	pT1b	pT1c

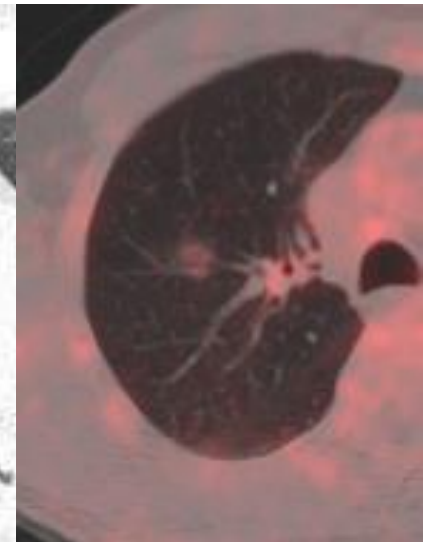
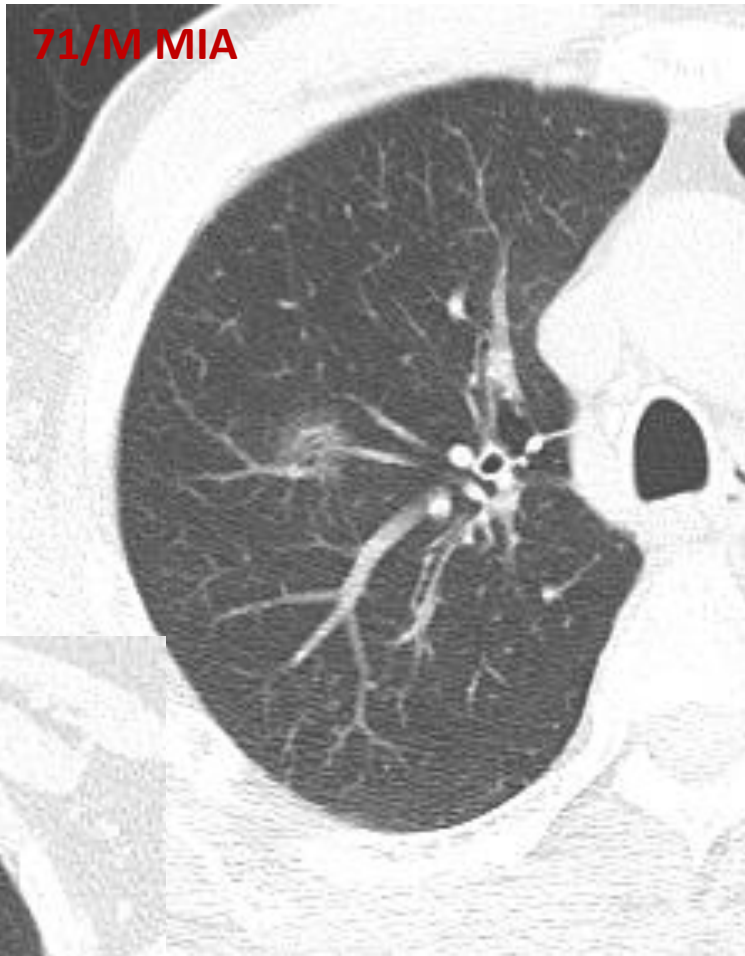




Pure GGN, 6 mm, AIS,
TisN0

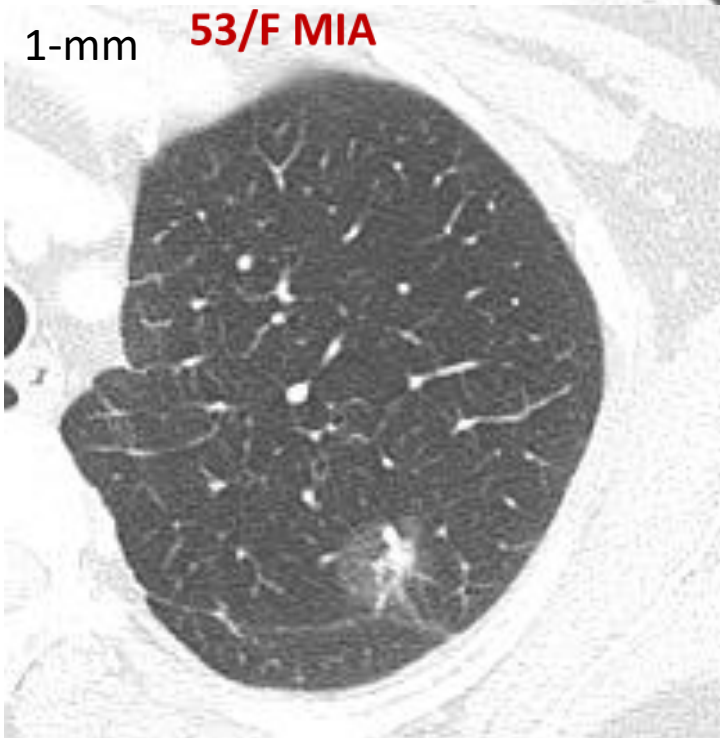


71/M MIA



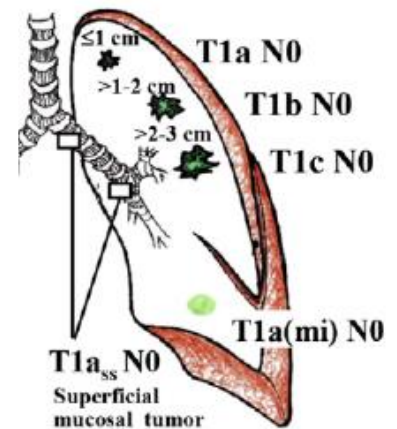
Part solid GGN, **T1miN0**
(GGO: 11 mm with
<5mm solid portion)

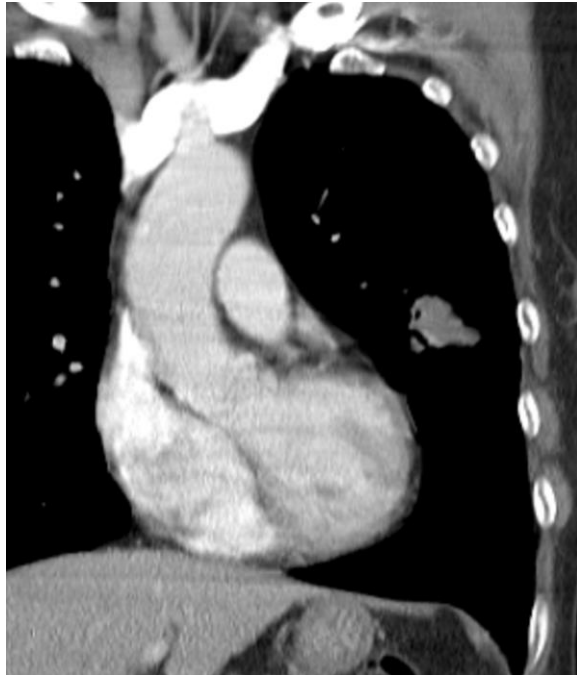
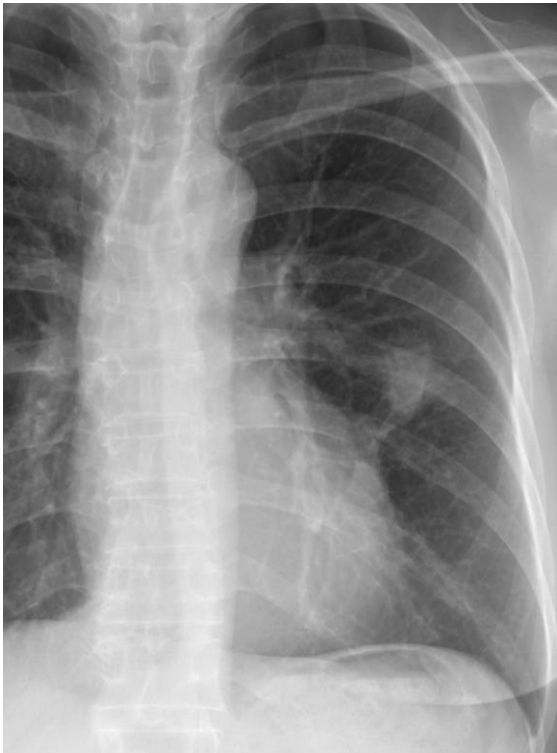1-mm **53/F MIA**



Part solid GGN, **T1aN0**
(GGO: 18 mm with
central solid 8mm)

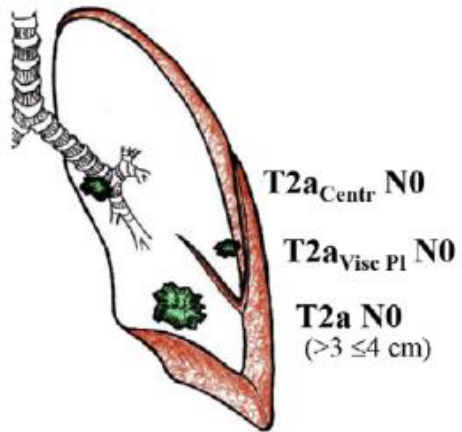
Stage IA



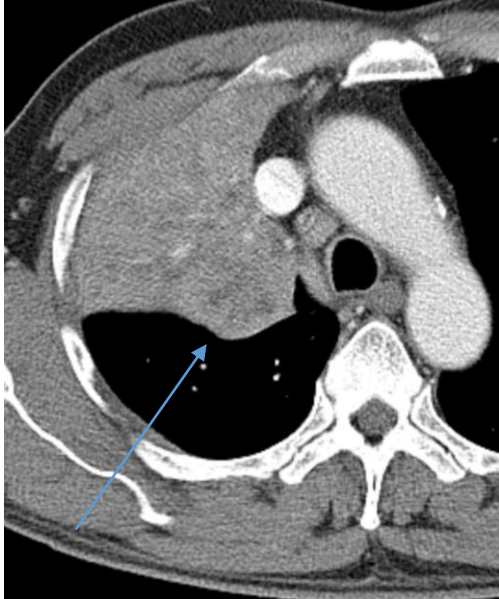


Lung, (left upper lower), lobectomy:
- ADENOCARCINOMA, 31mm, T2aN0

Stage IB

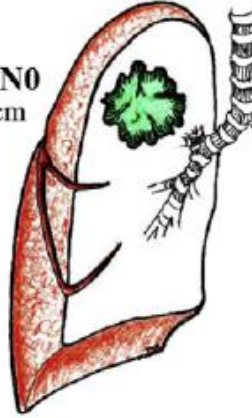


58/M Squamous Cell Cancer, 4.5cm, T2bN0



Stage IIA

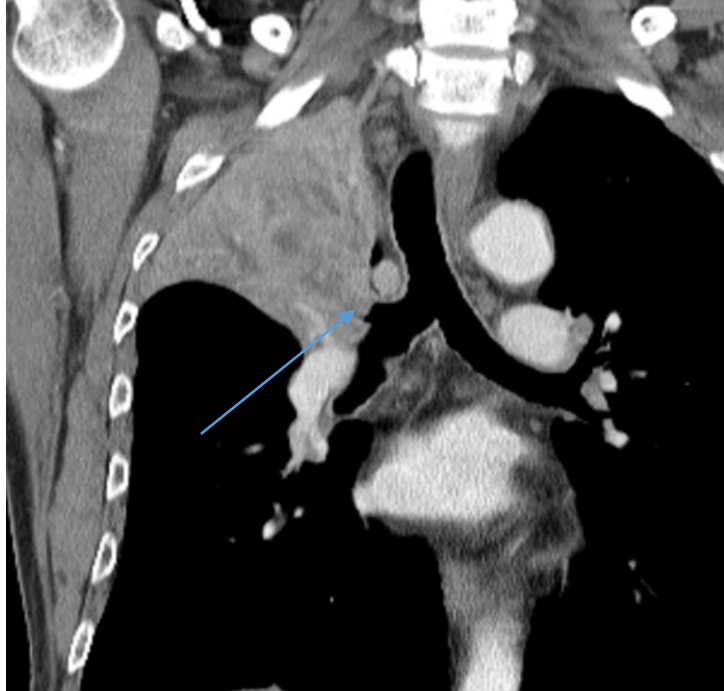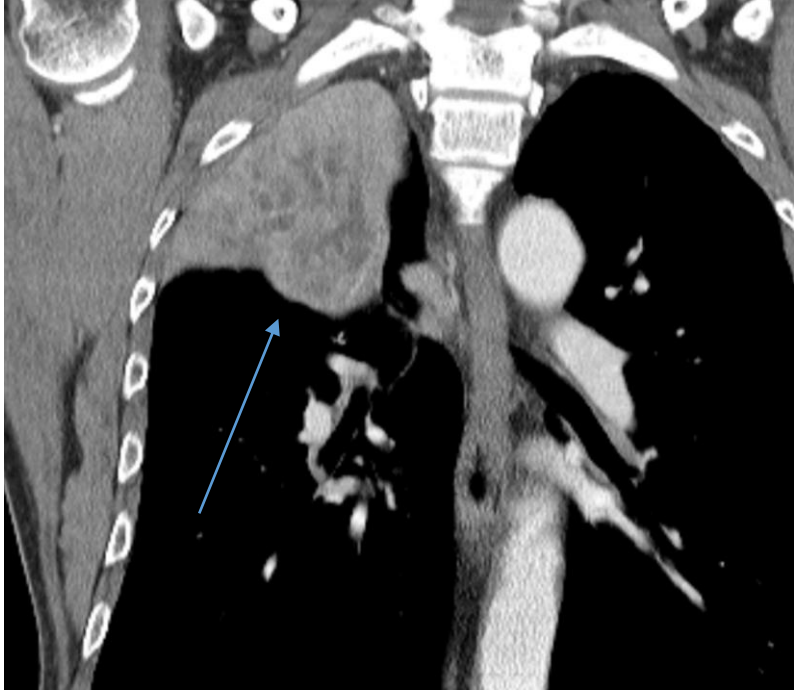
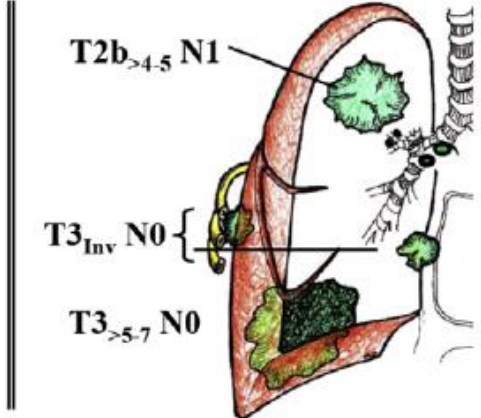
T2bN0
>4 ≤5cm



T2b_{>4.5} N1

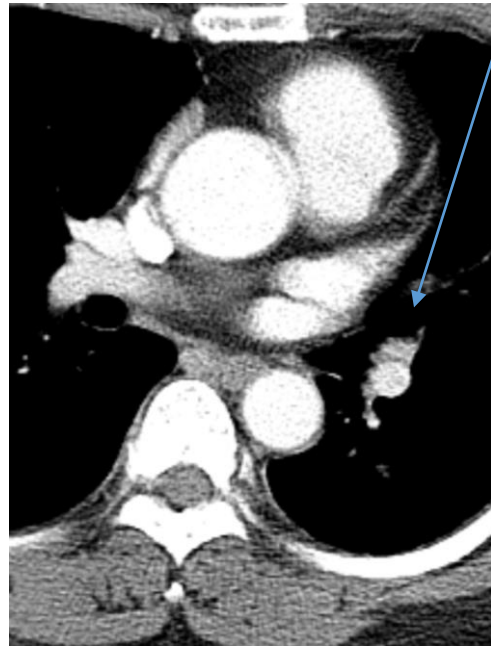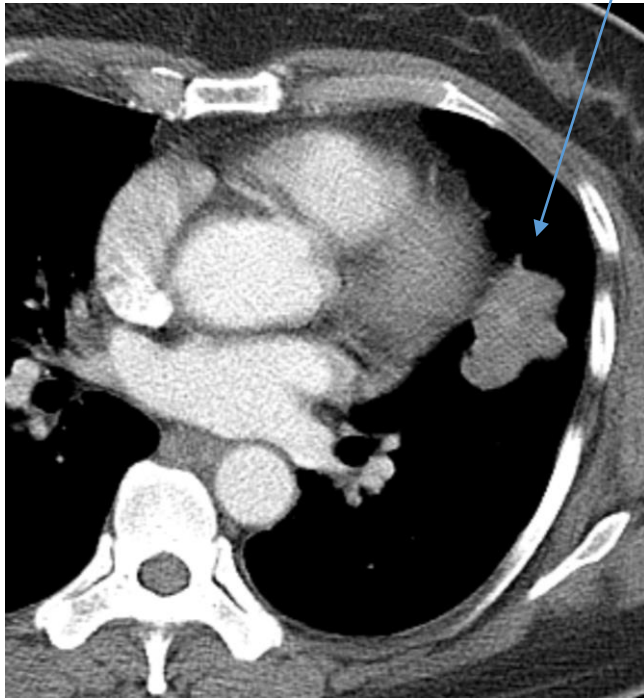
T3_{Inv} N0

T3_{>5.7} N0

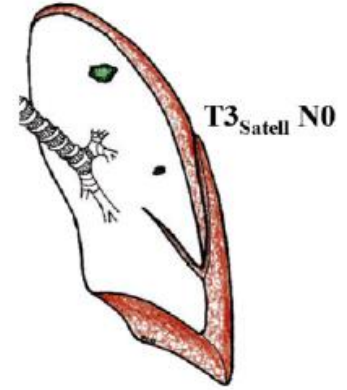
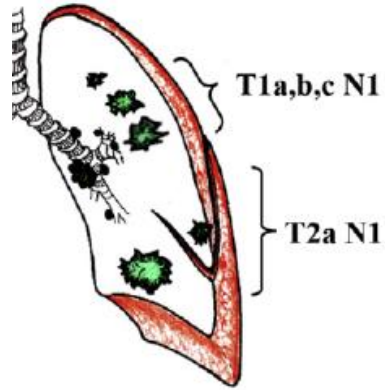


51/F Lung, (left upper lobe), lobectomy:

- ADENOCARCINOMA, 35mm
- 10L (+)
- T2aN1



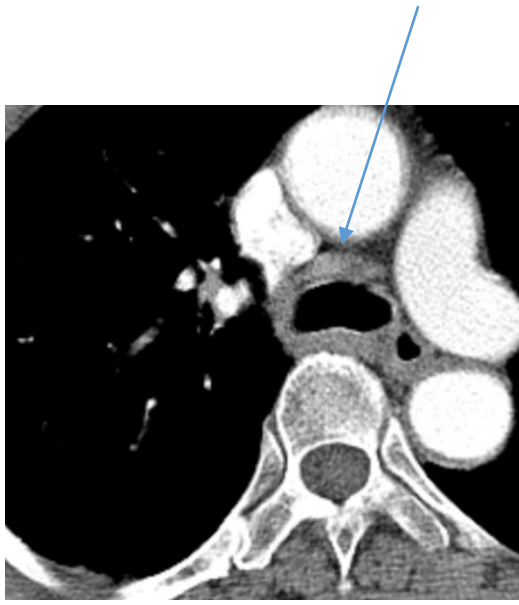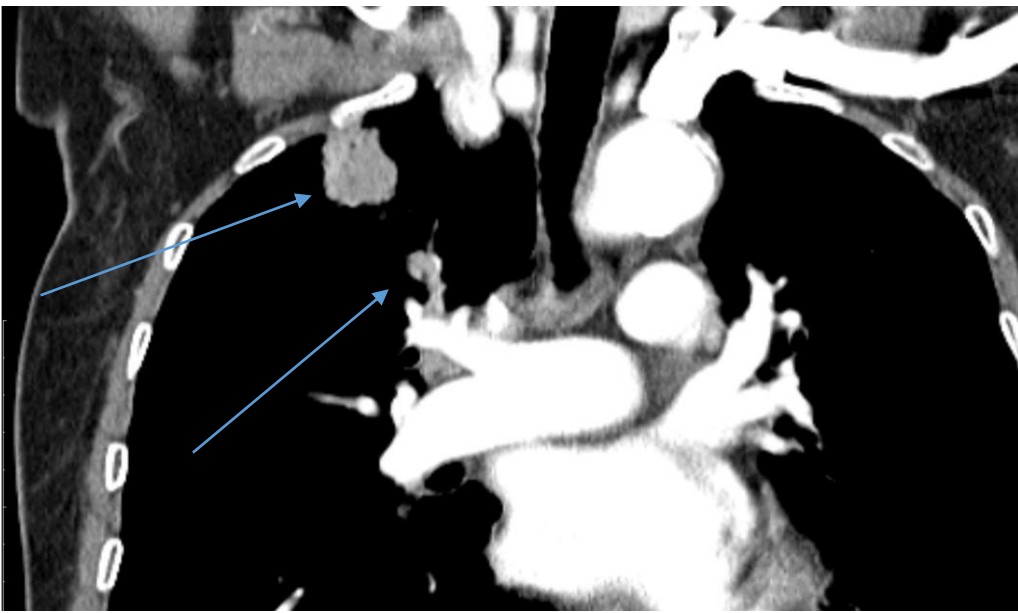
Stage IIB



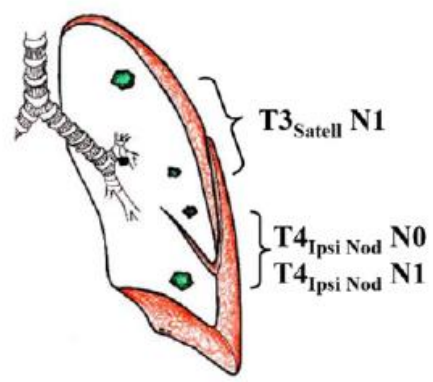
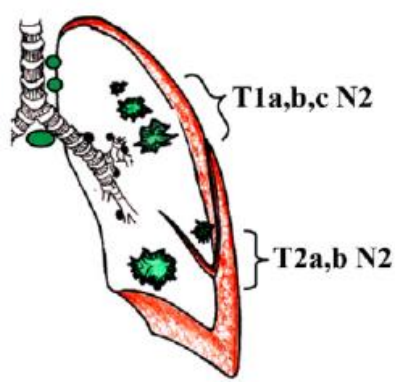
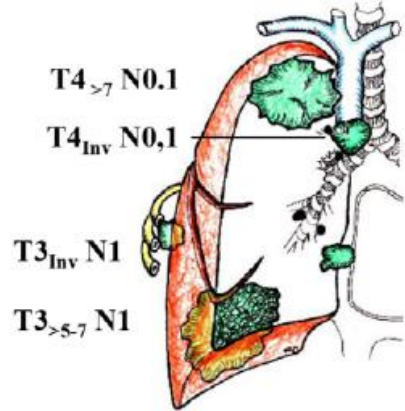
73/F: Lung, (right upper lobe), lobectomy:

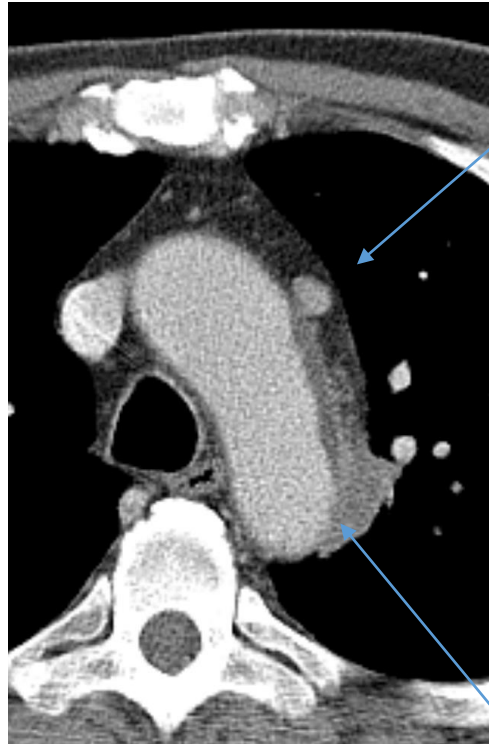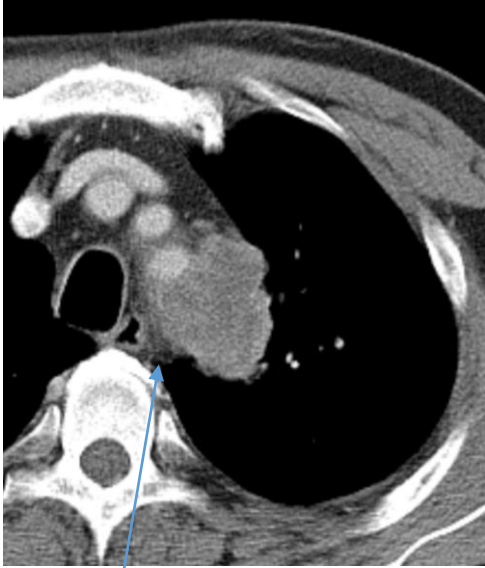- ADENOCARCINOMA, 33mm, 4R LAP

- T2aN2

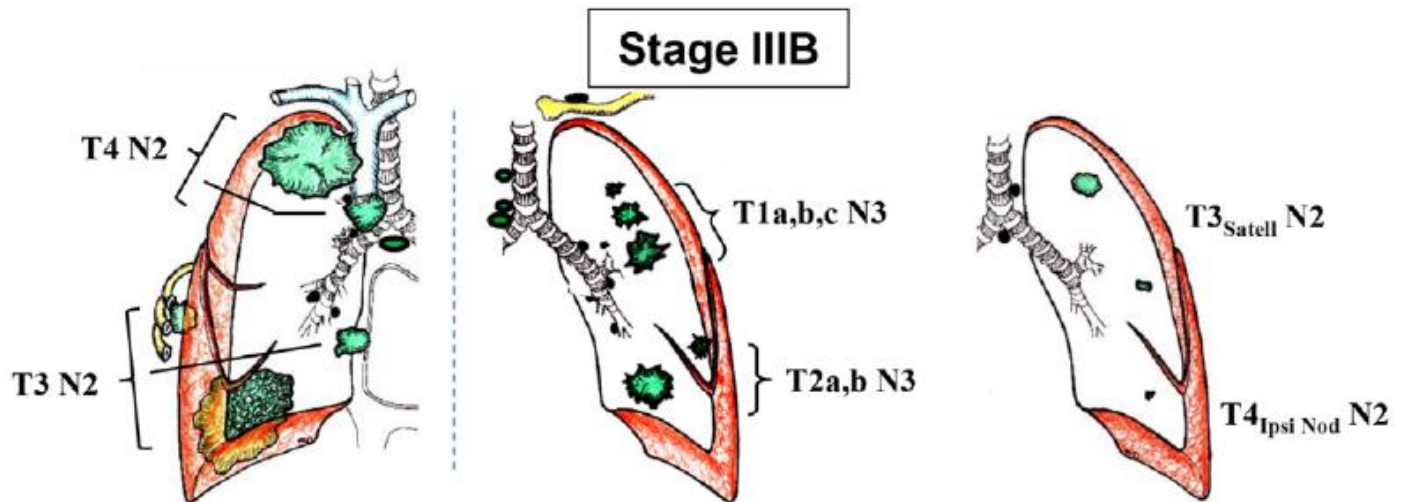


Stage IIIA



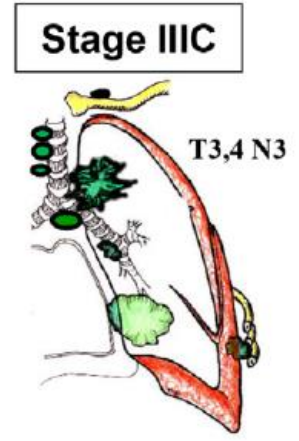
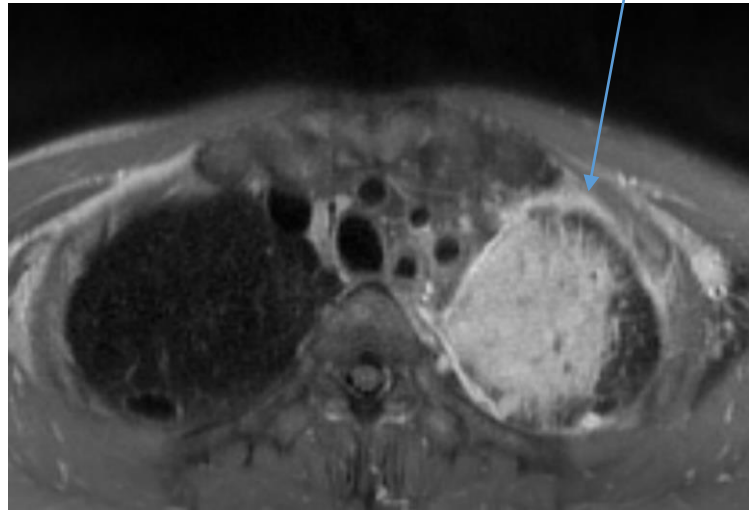
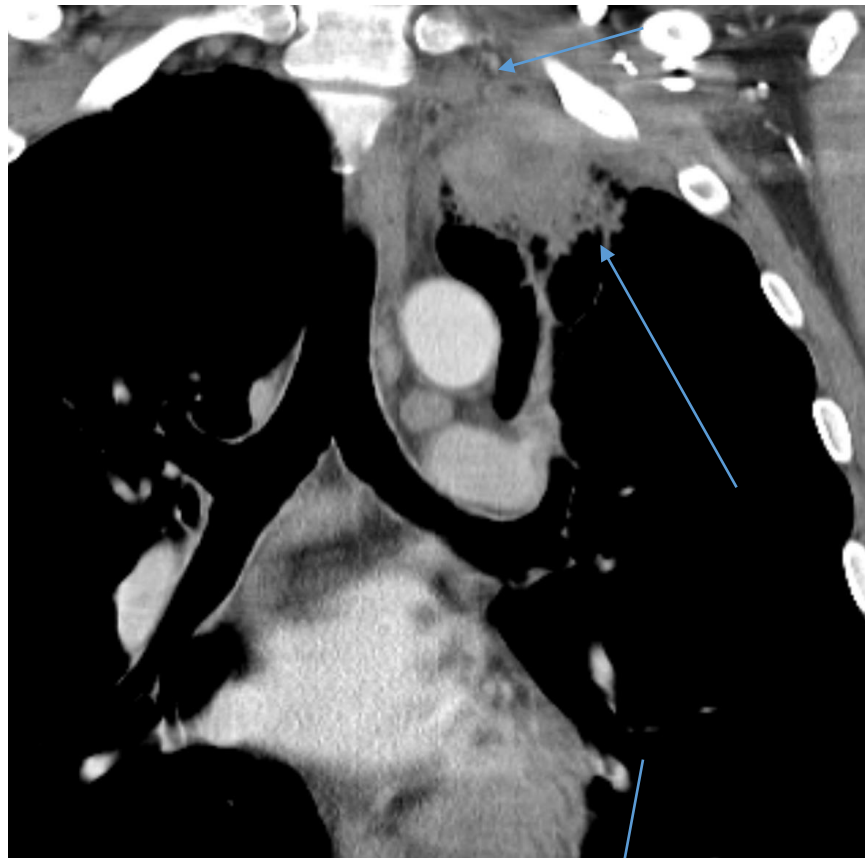


Lung, (left upper lobe), lobectomy:
- LARGE CELL CARCINOMA
- 50mm
- Mediastinal invasion
- **T4N2**



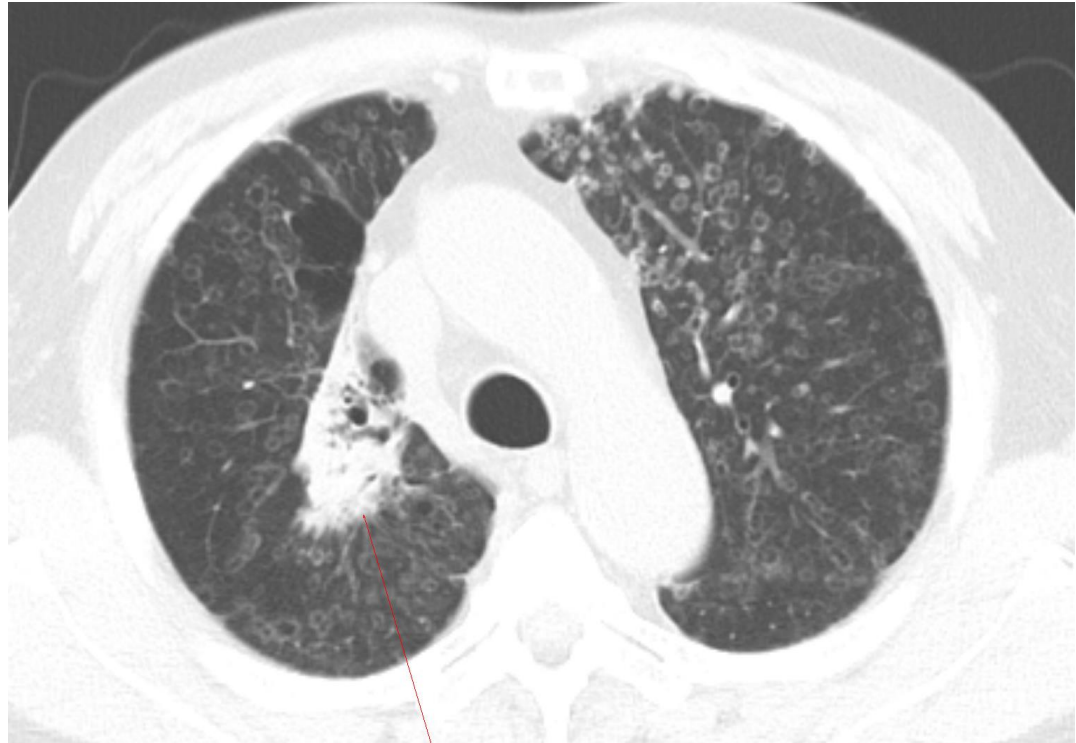51/M Pancoast tumor

- Squamous cell cancer
- Pleural and chest wall invasion
- T4N3

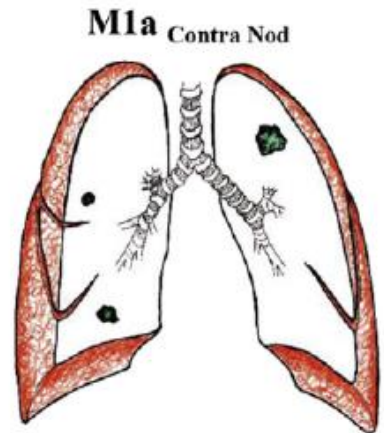
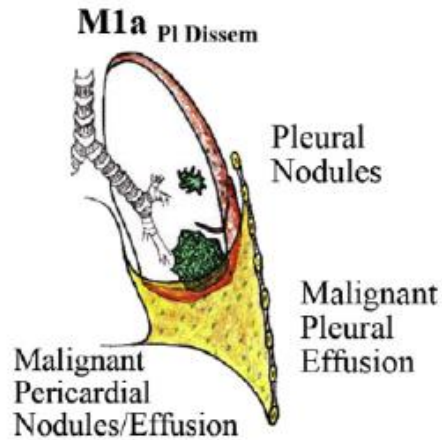


67/M ADENOCARCINOMA

- lung to lung metastasis
- T2aN0M1a

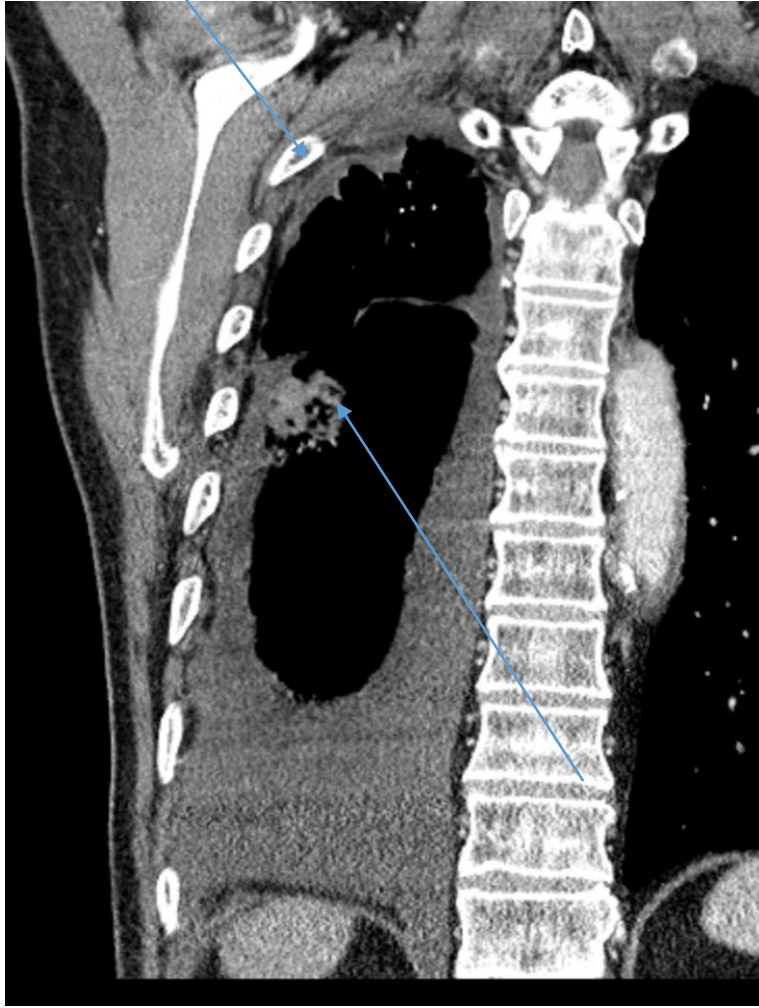
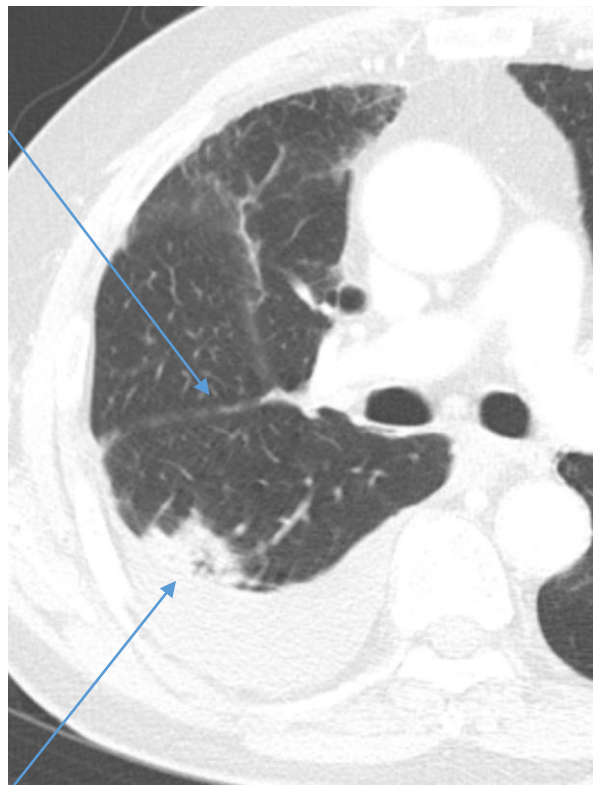


Stage IVA

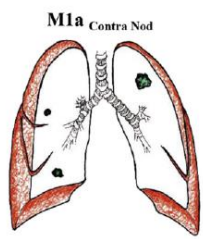
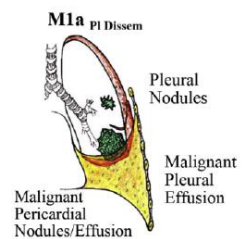


84/M

- Malignant Pleural Fluid : METASTATIC CARCINOMA
- T2aN0M1a

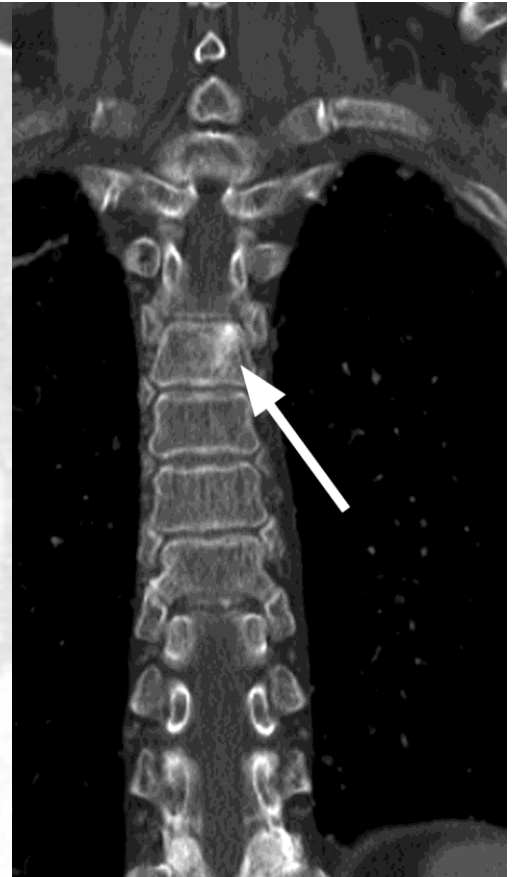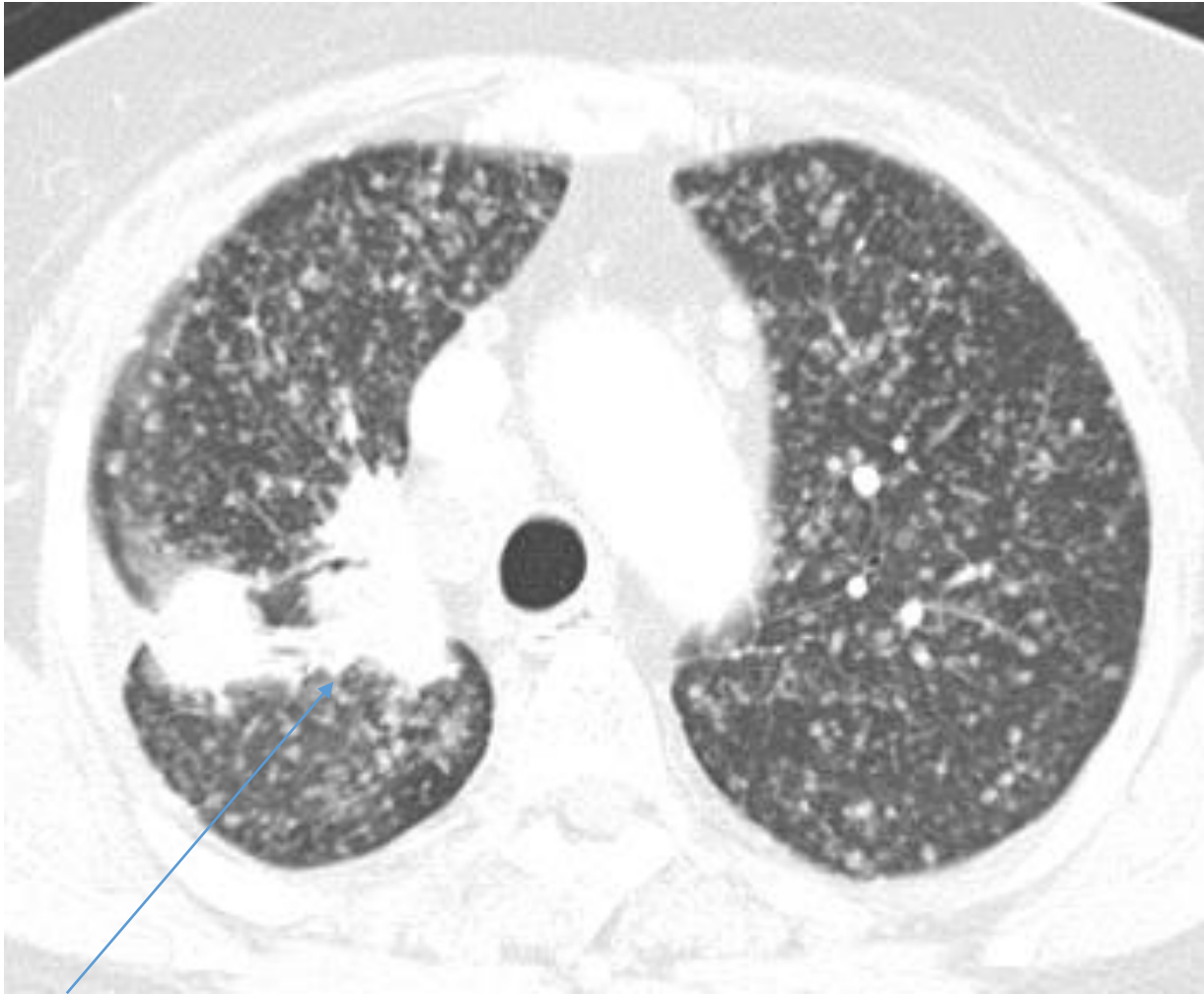


Stage IVA

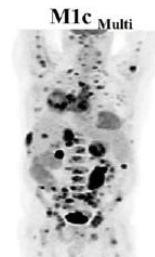
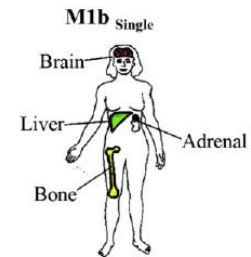


79/F Adenocarcinoma (21Del) EGFR and lung and bone metastasis

T3N2M1c

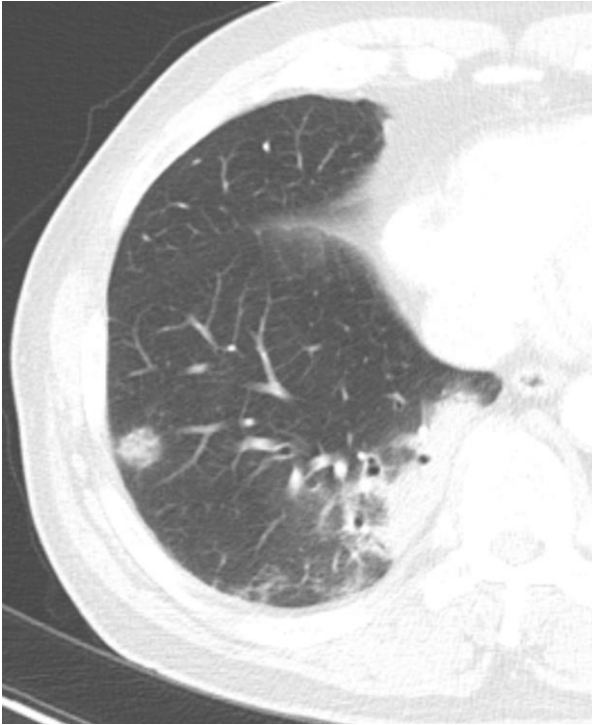

Stage IVB

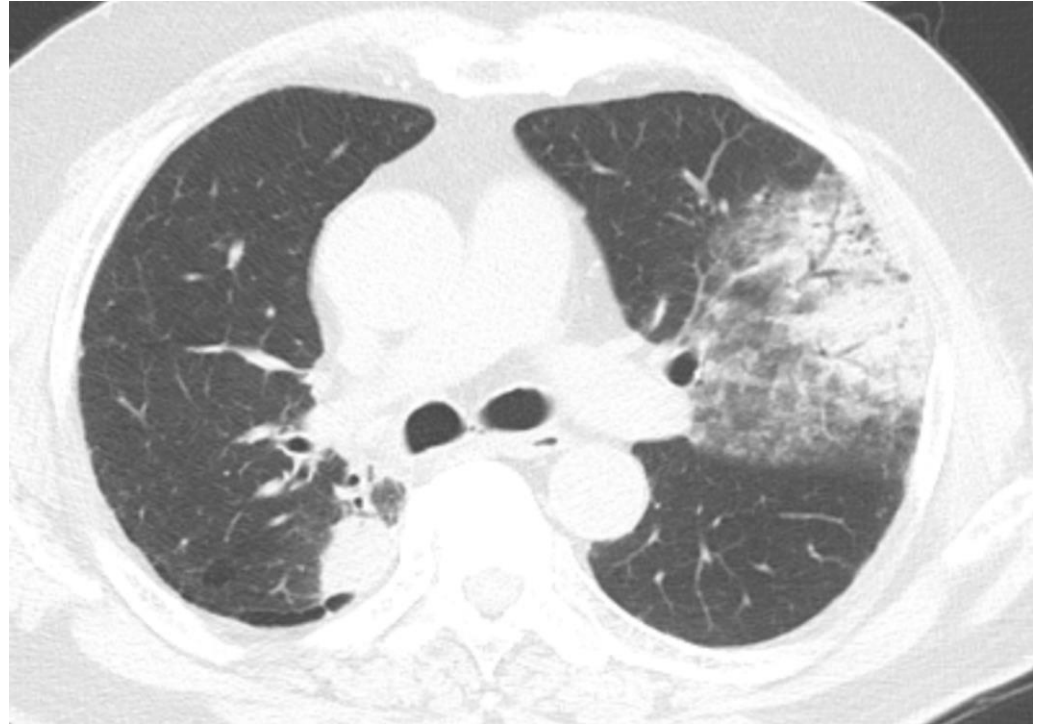


68/M Lung, (right lower lobe), lobectomy:

- **MUCINOUS ADENOCARCINOMA**
- 94mm
- Consolidative cancer with separate nodule



Pre OP, **T3N0**

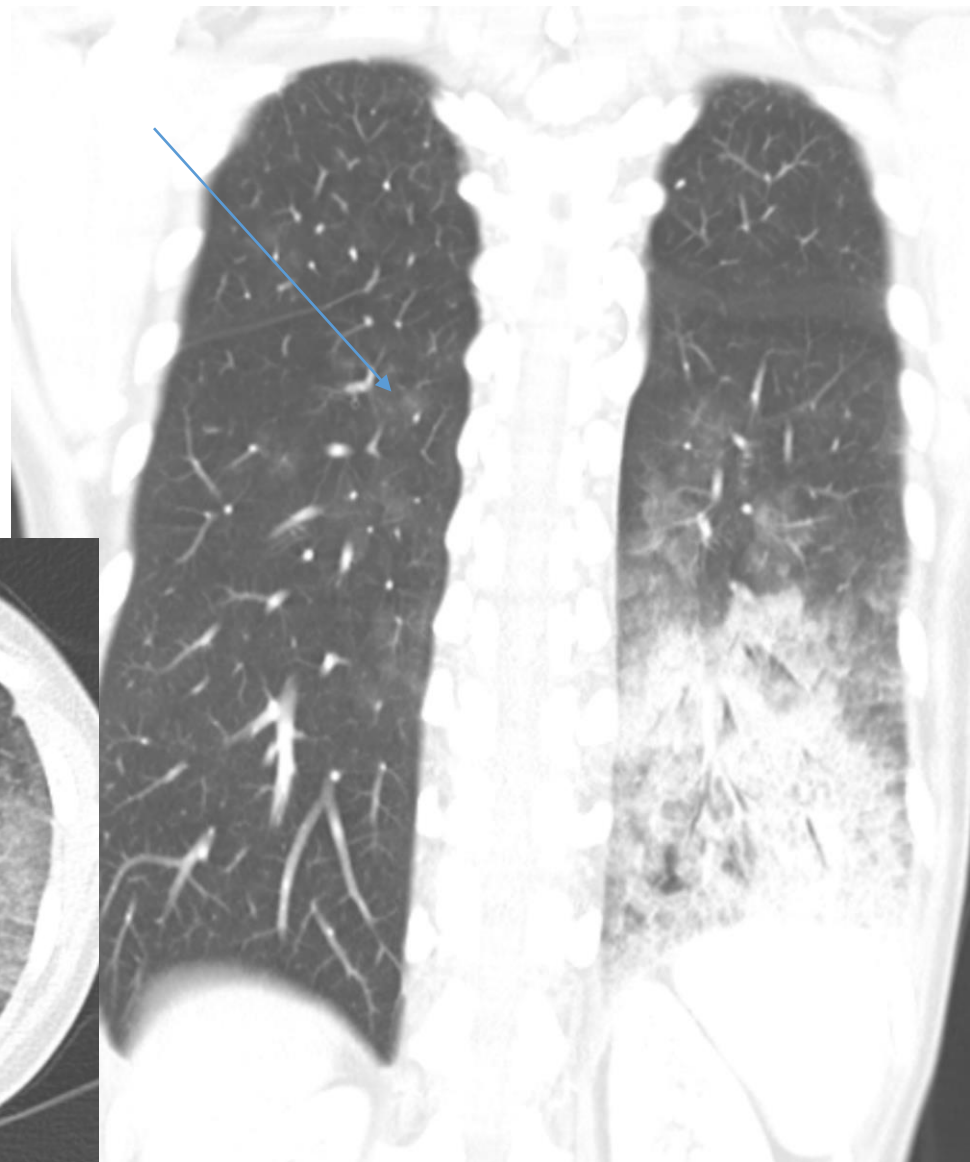
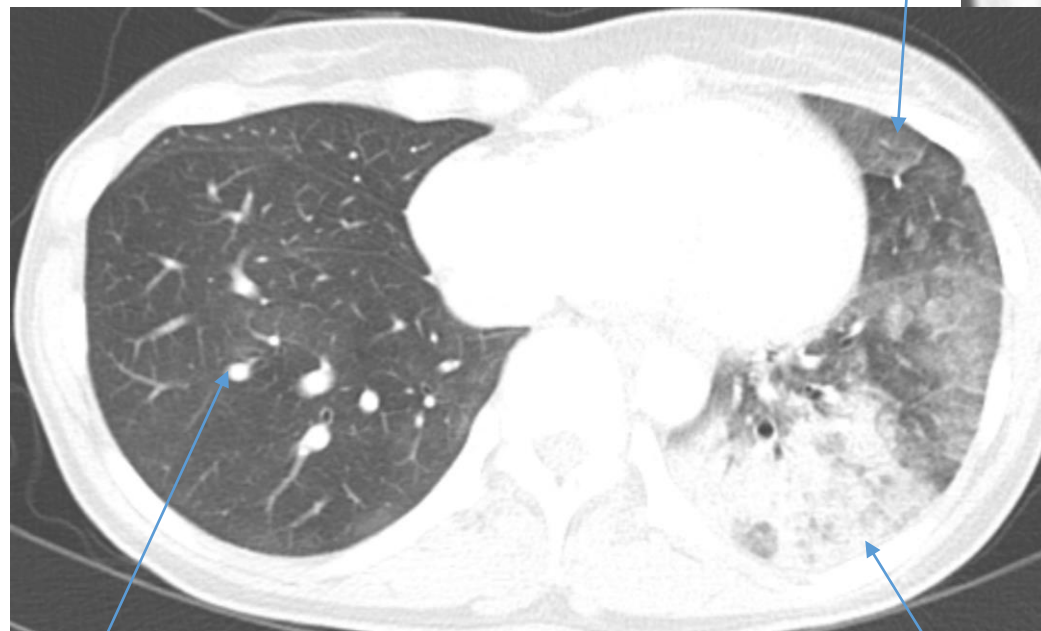


7 years later

50/F ADENOCARCINOMA in LLL

- with aerogenic spread (air-space pattern)

- T4N0M1a



Introduction

- Focusing on CT Imaging, Real Field

- 1) 전암 병변 및 초기 폐암을 시사하는 폐 결절의 영상학적 구분
- 2) 폐암을 시사하는 흉부 CT 영상 소견
- 3) **폐암의 단계별 감별 진단 (8th Edition of staging system).**
- 4) 양성과 악성 결절 시사하는 소견
- 5) 임파선 전이를 시사하는 영상학적 소견
- 6) 늑막 전이를 시사하는 영상학적 소견
- 7) EGFR, ALK 등 유전자 돌연변이를 동반하는 폐암의 영상학적 특징
- 8) Nodule management
- 9) PCNB (Percutaneous Lung biopsy) 의 대상 선정과 성적
- 10) Lung cancer의 high risk factor 에 대한 영상학적 고려

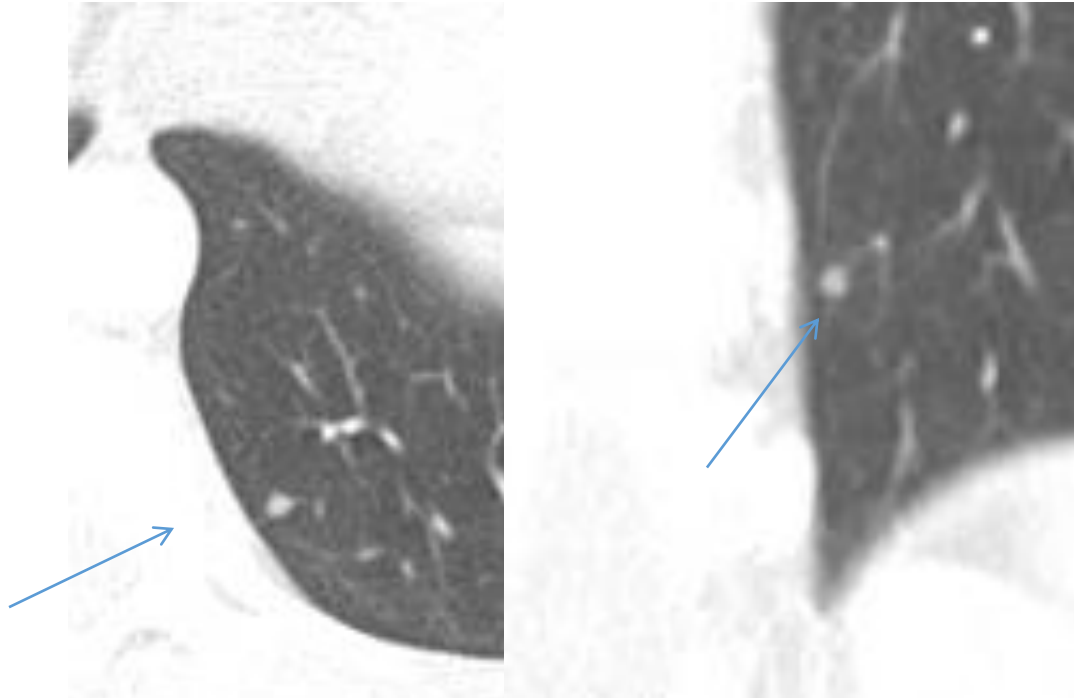
Differential Diagnosis

- **GGN**

- Intrapulmonary LN
- Focal fibrosis
- Focal inflammation or inflammatory nodule
- Focal atelectasis
- BALT (MALT) lymphoma

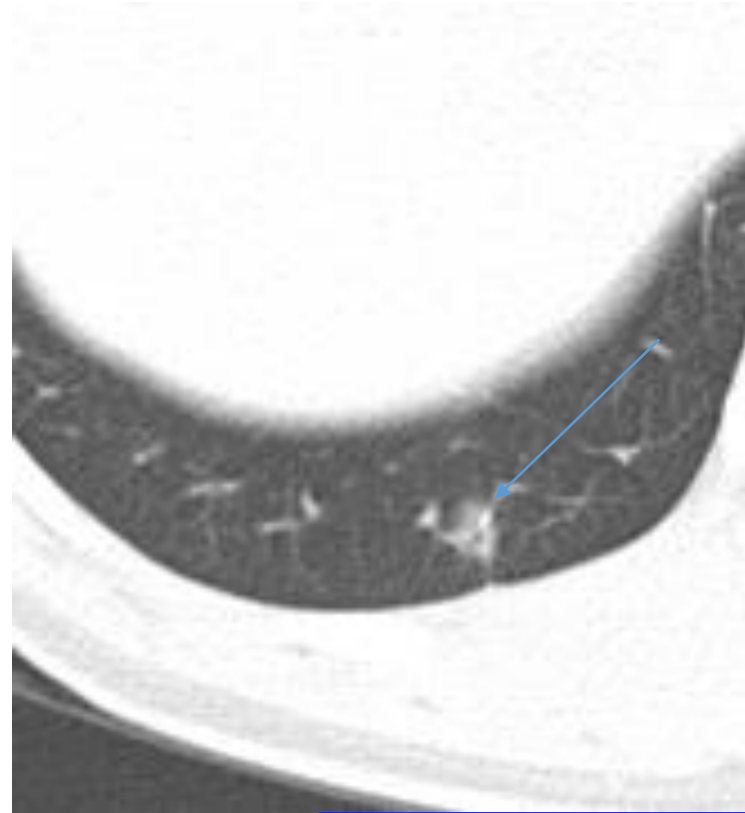
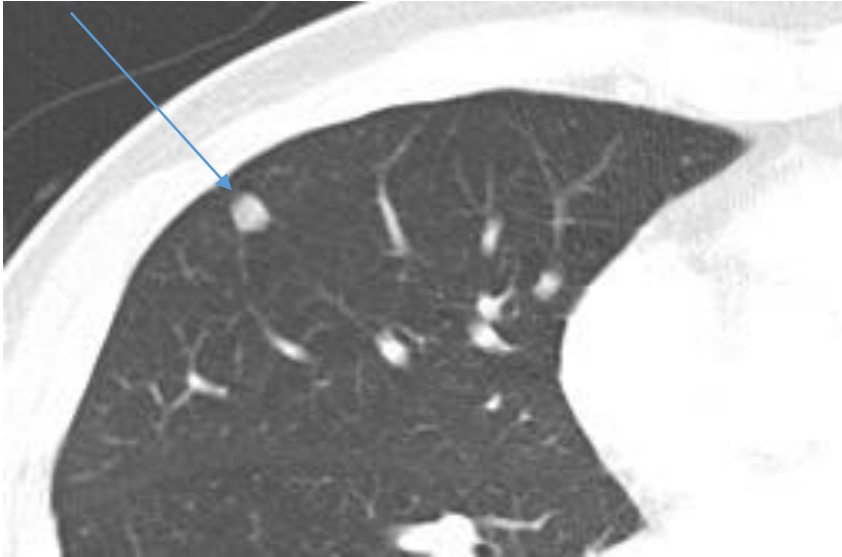
- **Solid nodule or Mass**

- Granuloma
- Benign tumor such as hamartoma, sclerosing pneumocytoma
- Anthracofibrotic nodule

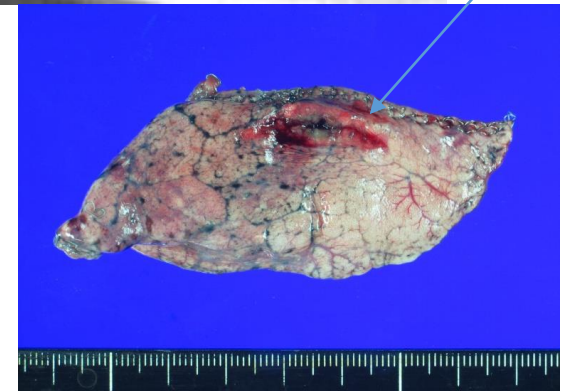

Intrapulmonary LN

- Lower lobes
- Subpleural or peri-fissural location (median 4.6mm distance)
- Angular or polygonal
- 3~9mm length (median 6mm)
- Convergence of interlobular septum
- Linear densities, ectatic lymphoid channels

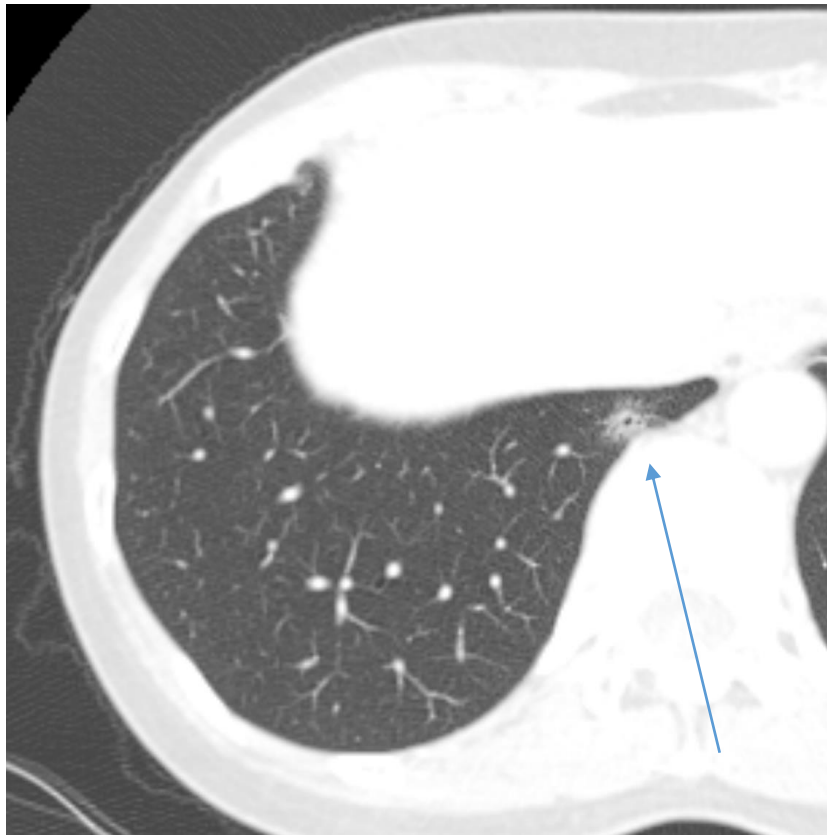


- S/P wedge resection for nodule in right middle lobe, proven **fibrotic nodule**.
- S/P wedge resection for right lower lobe posterior basal segment nodule, proven **bronchiolar metaplasia**.

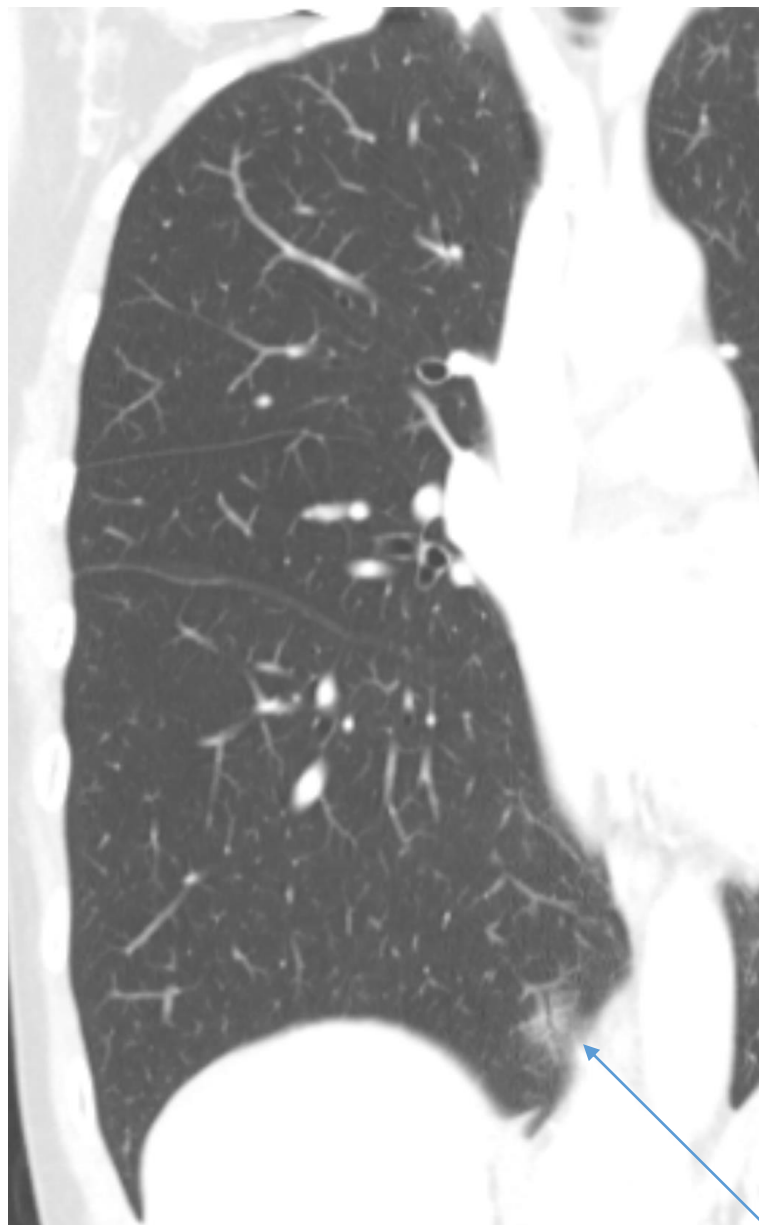


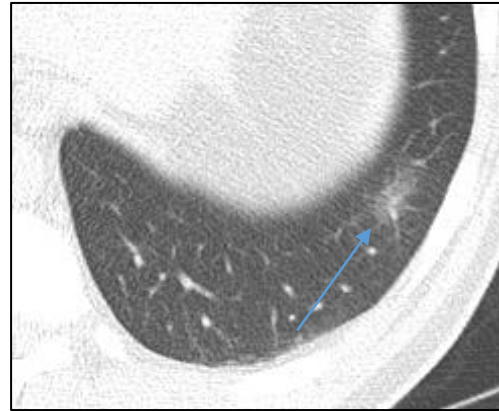
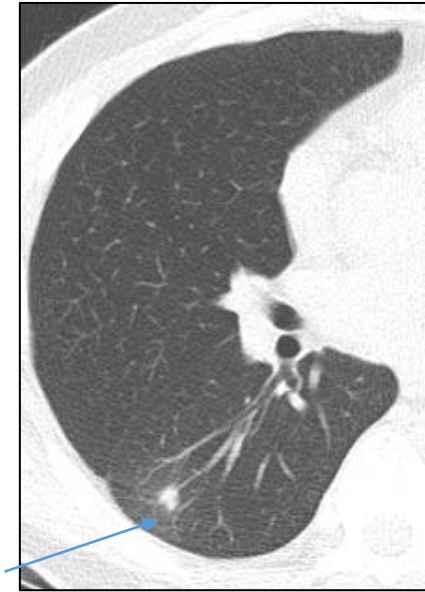GGN D/Dx

51/F focal atelectasis or focal inflammatory lesion

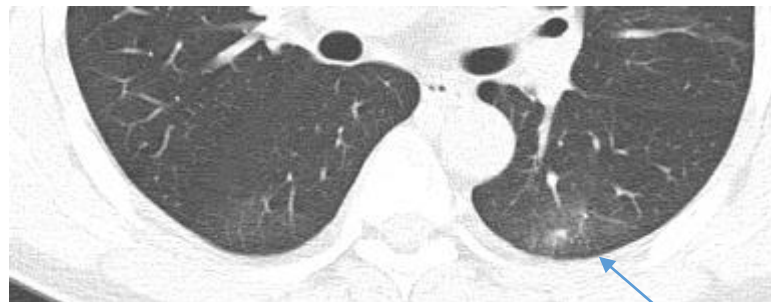
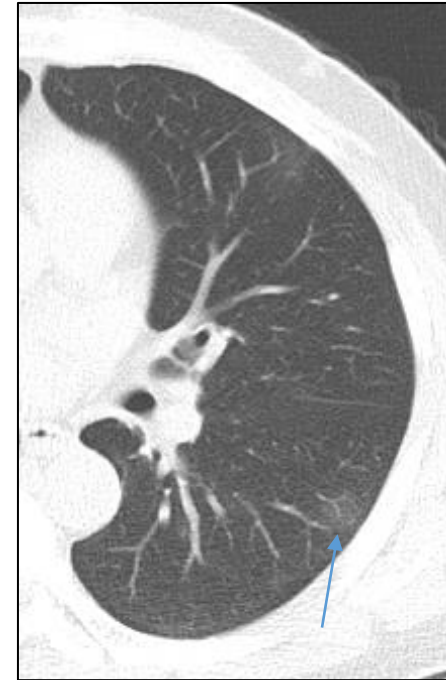
Disappeared 6 months later



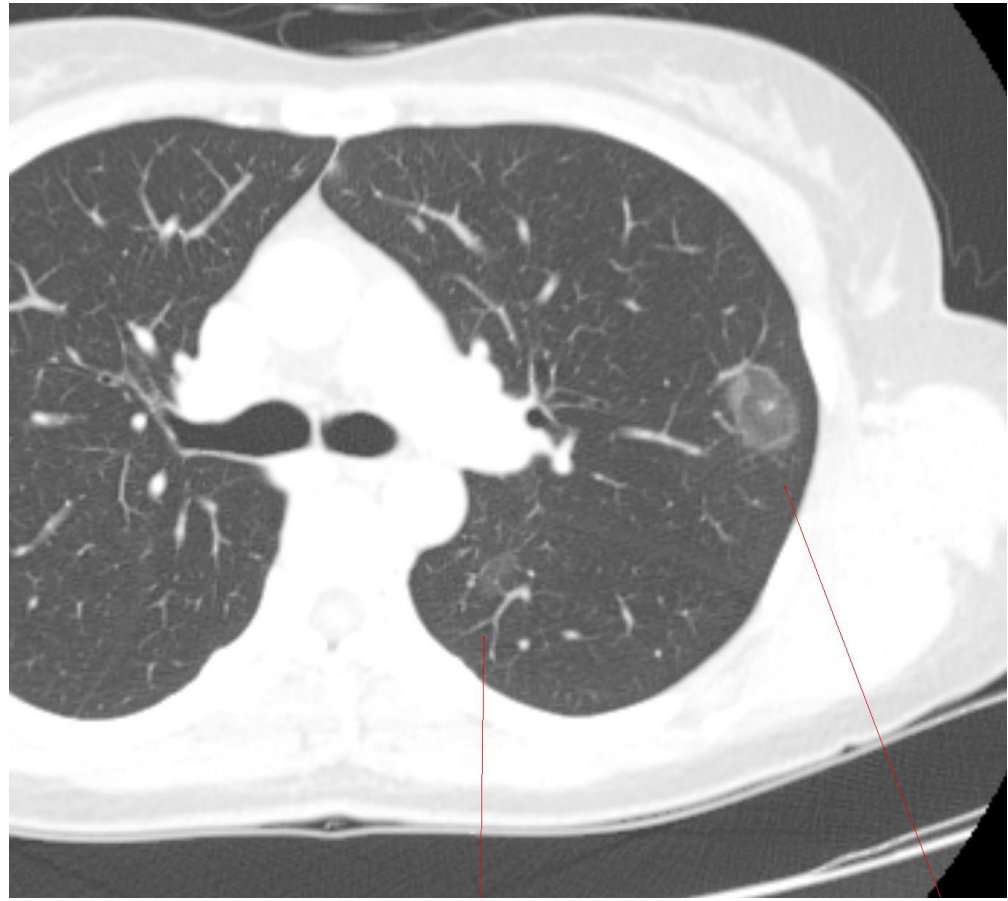


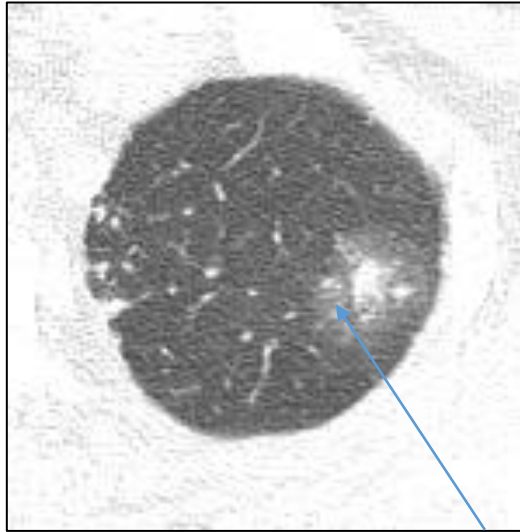
Initial CT



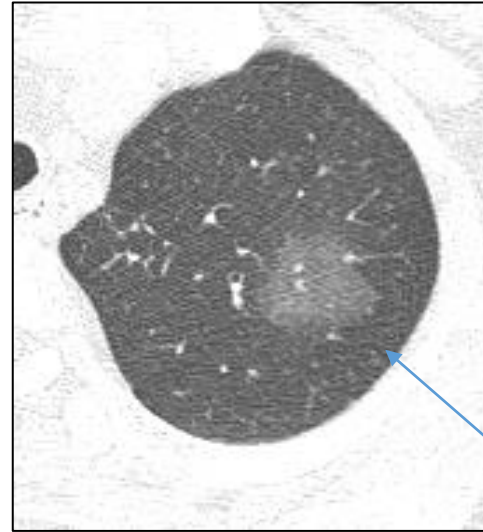
3 months later

- young patient age
- detection of the SPN at f/u
- blood eosinophilia
- lesion multiplicity
- large solid portion
- ill-defined lesion border

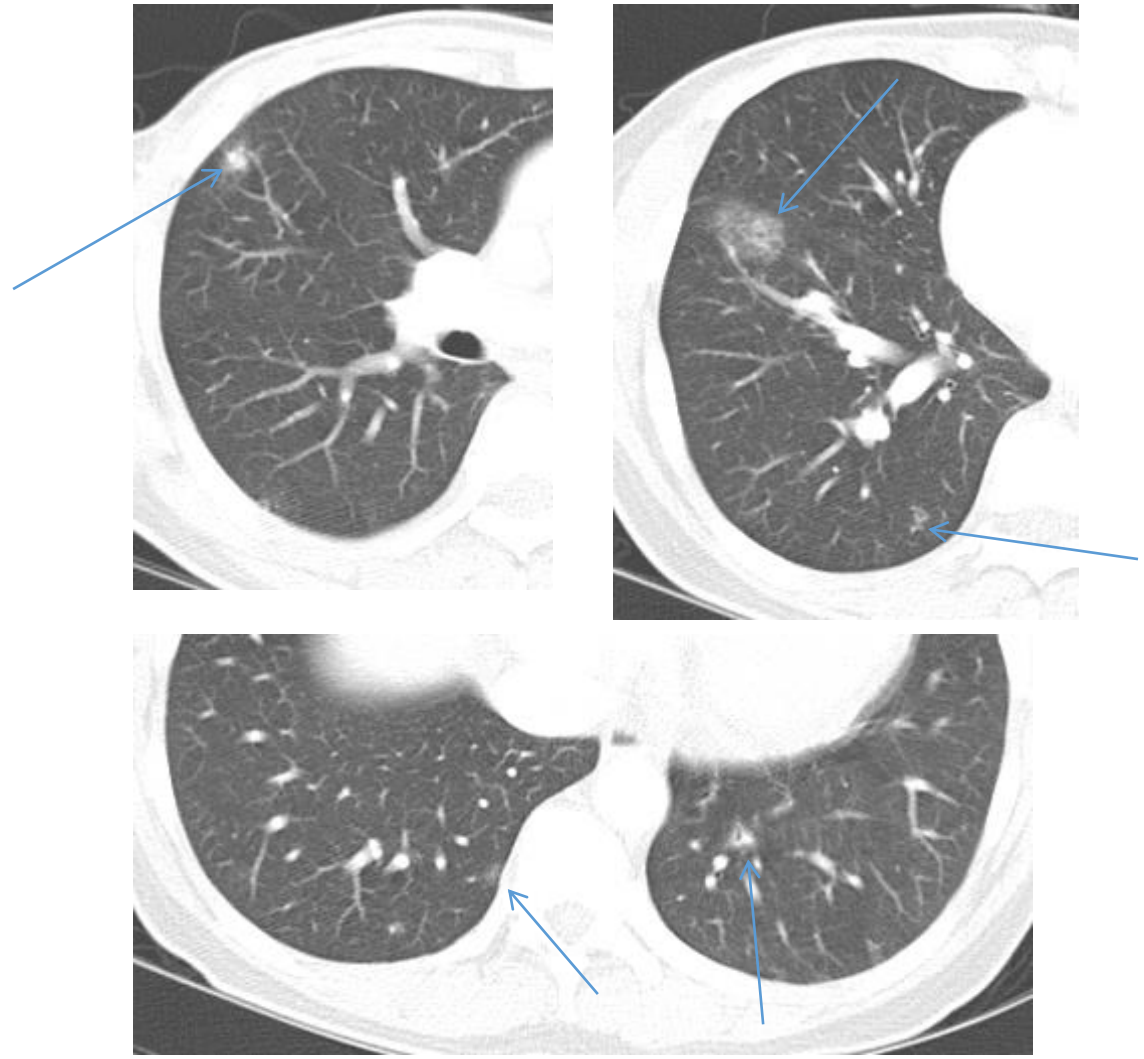




Initial CT



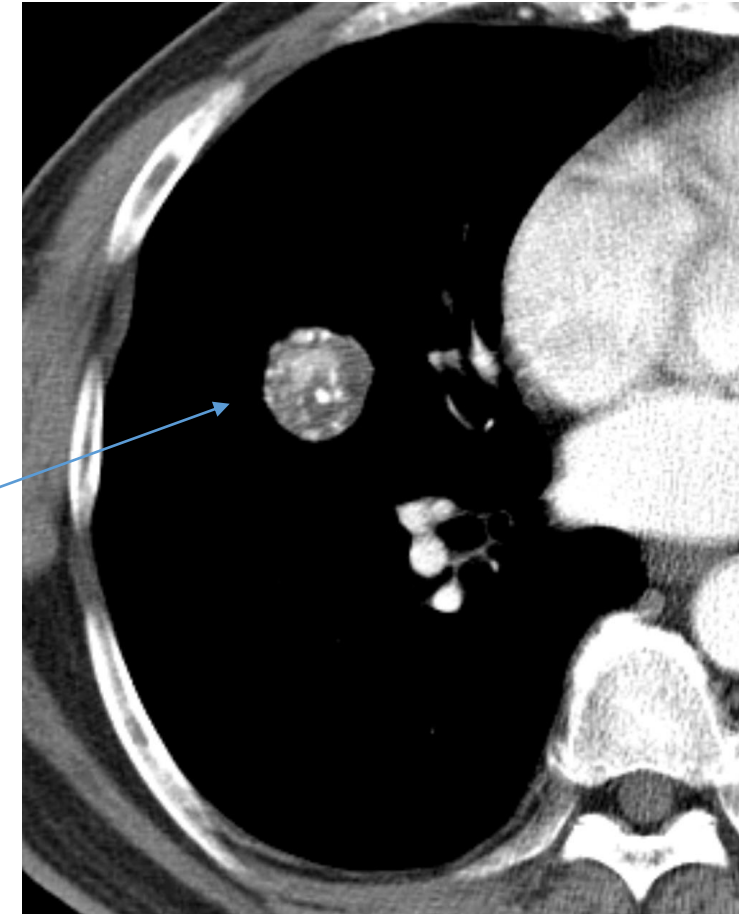
F/U CT on month later



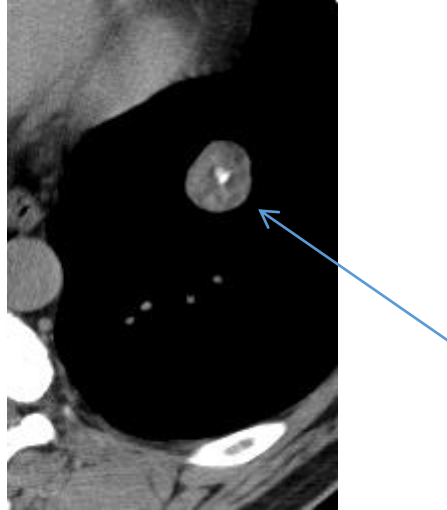
Solid nodule D/Dx

Hamartoma

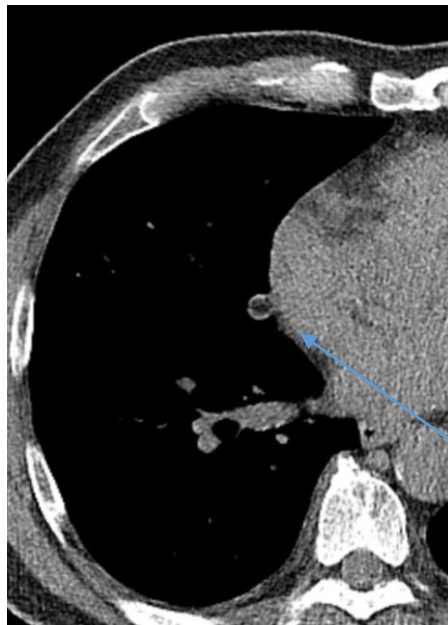
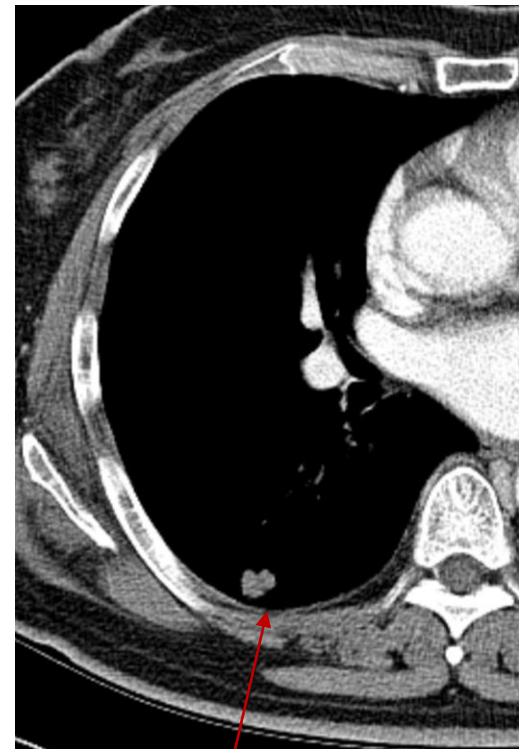
68/M OP proven



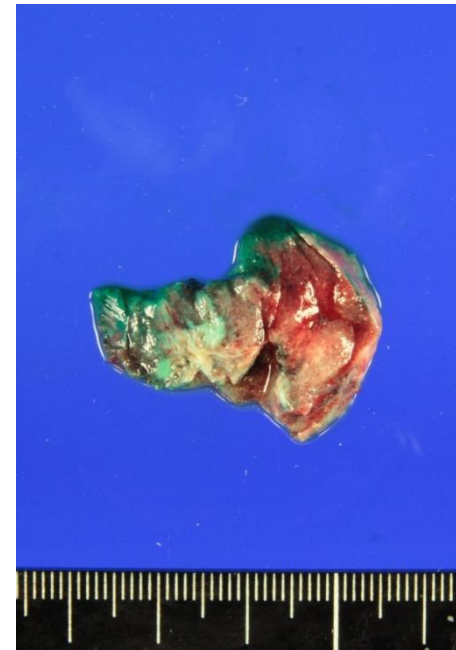
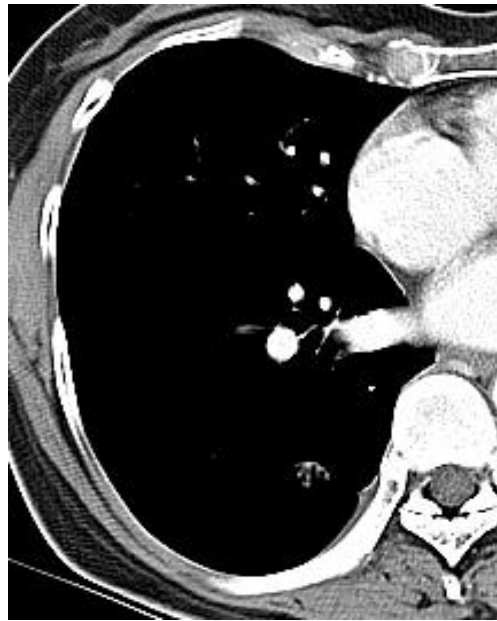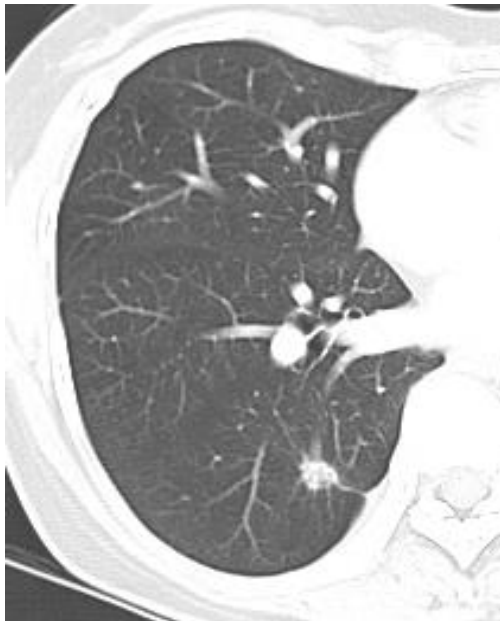62/M OP proven



76/F OP proven



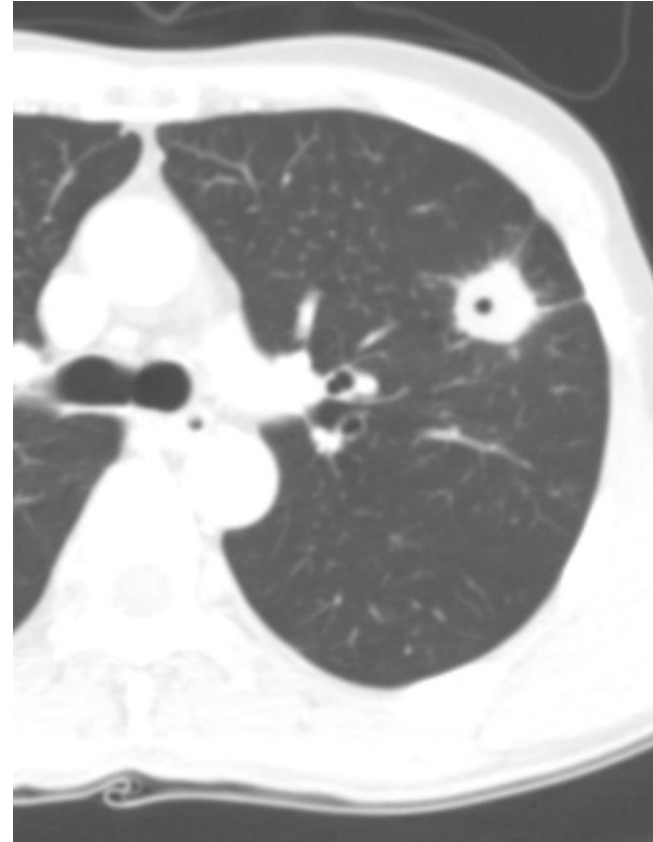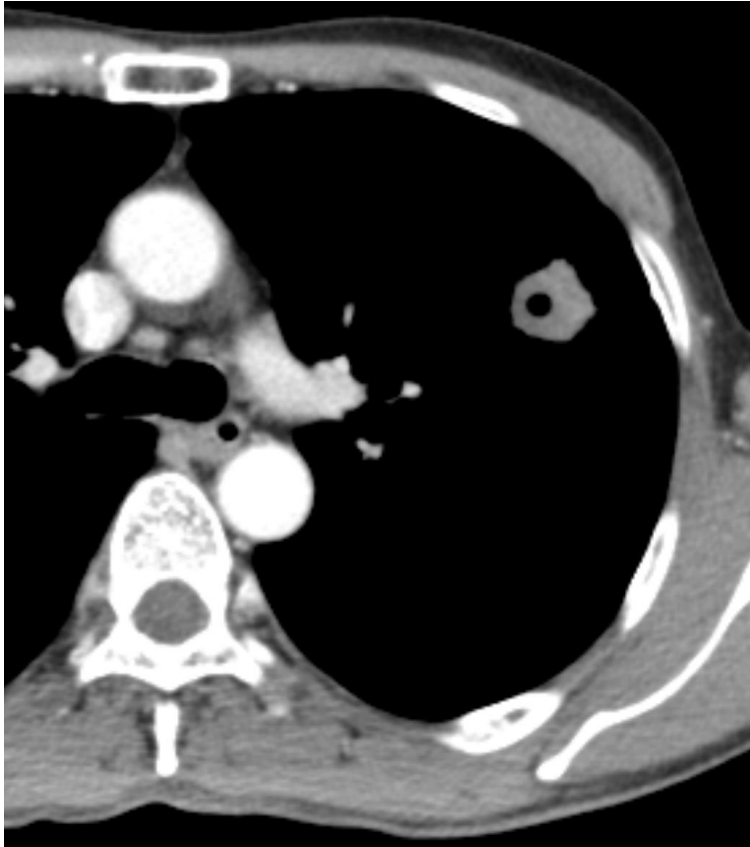
67/M, -60 HU



Our CT report: 10mm, solid, lung cancer

Differential diagnosis of small solid nodule

- Inflammatory granuloma
- anthracofibrosis



• Focusing on CT Imaging, Real Field

- 1) 전암 병변 및 초기 폐암을 시사하는 폐 결절의 영상학적 구분
- 2) 폐암을 시사하는 흉부 CT 영상 소견
- 3) 폐암의 단계별 감별 진단 (8th Edition of staging system).
- 4) **양성과 악성 결절 시사하는 소견**
- 5) 임파선 전이를 시사하는 영상학적 소견
- 6) 늑막 전이를 시사하는 영상학적 소견
- 7) EGFR, ALK 등 유전자 돌연변이를 동반하는 폐암의 영상학적 특징
- 8) Nodule management
- 9) PCNB (Percutaneous Lung biopsy) 의 대상 선정과 성적
- 10) Lung cancer의 high risk factor 에 대한 영상학적 고려

양성과 악성 결절 시사하는 소견

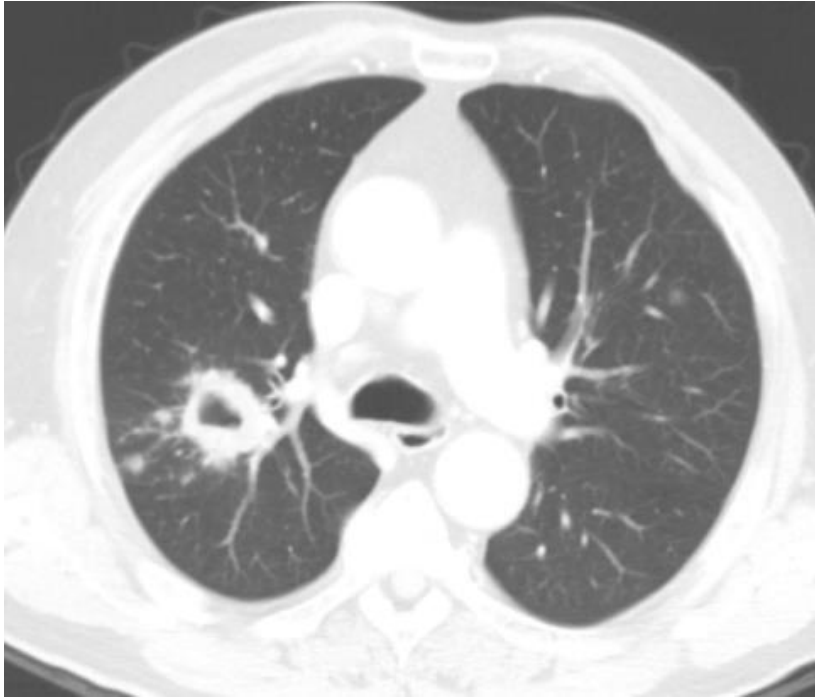악성

- Spiculated margin
- Lobulated or irregular margin
- Internal bubble lucency
- Pleural or fissural tag or retraction
- Irregular internal cavity
- Interval growing

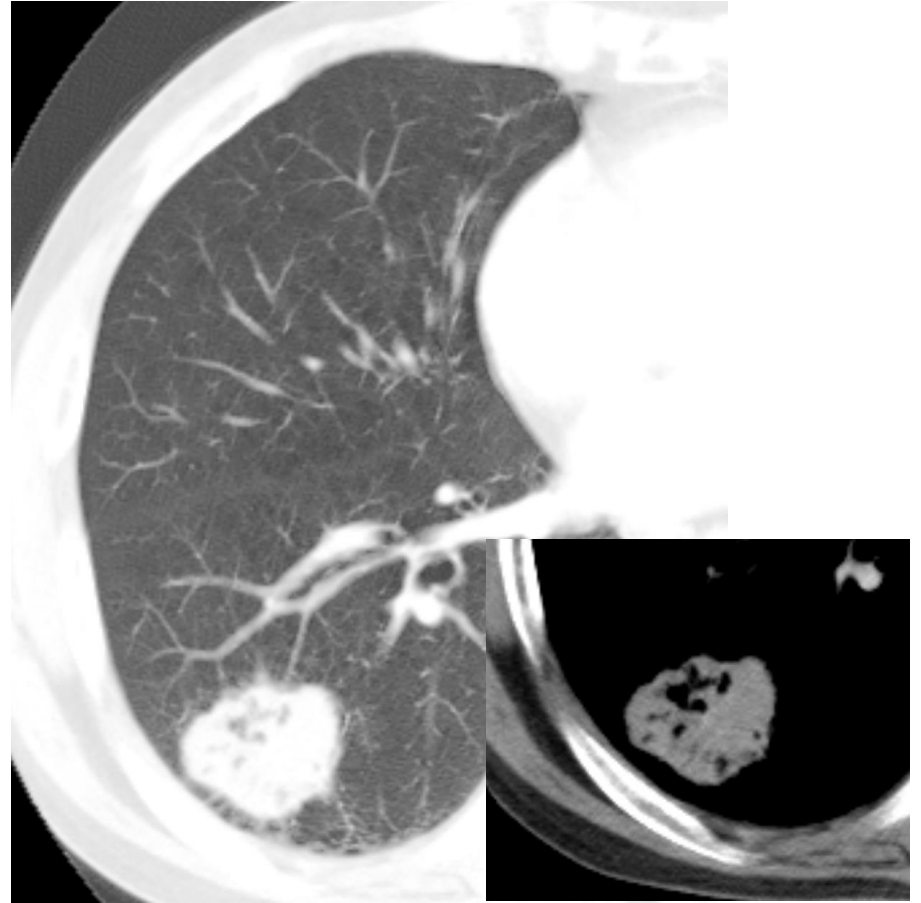
양성

- Well defined margin
- Internal calcification
- Internal fat
- Migrating
- Smooth internal cavity
- Interval no change or decreased size over 2 years

Cavitary nodule D/Dx



Lung, (right upper lobe), core needle biopsy: **Chronic granulomatous inflammation.**



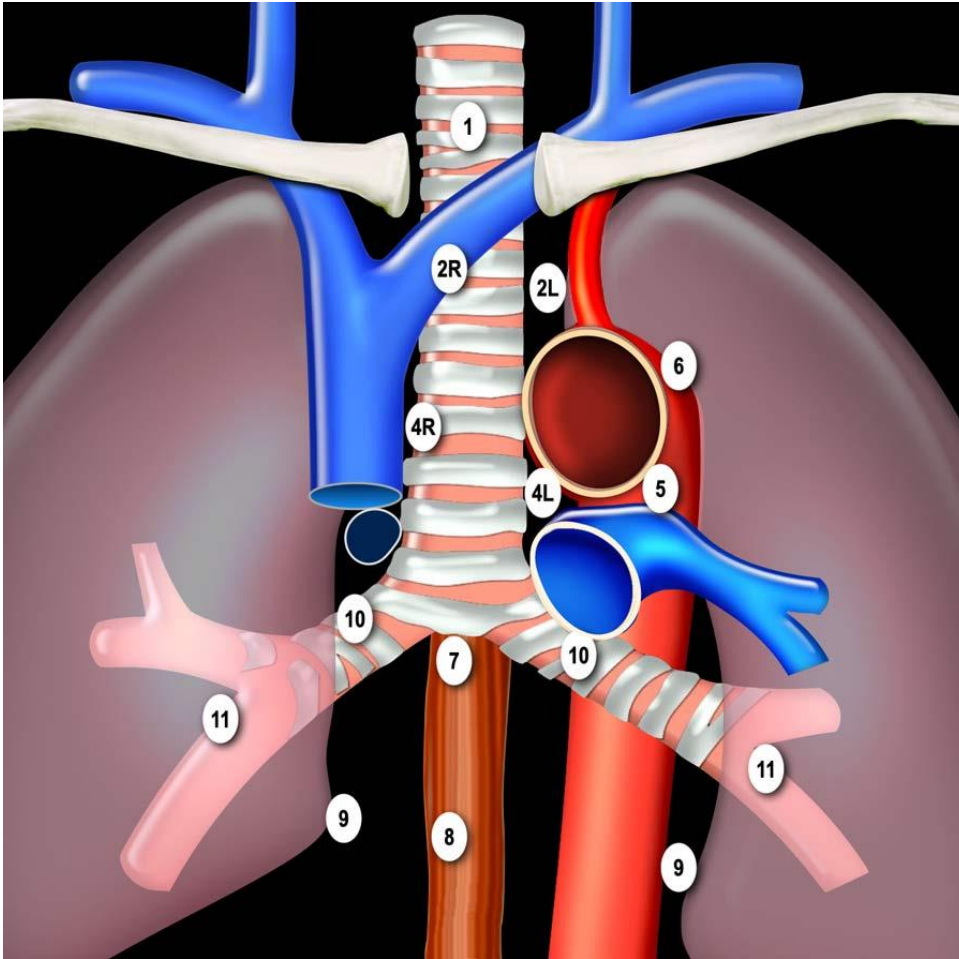
Lung, (right lower lobe), lobectomy:
- **LARGE CELL NEUROENDOCRINE CARCINOMA**

Introduction

- Focusing on CT Imaging, Real Field

- 1) 전암 병변 및 초기 폐암을 시사하는 폐 결절의 영상학적 구분
- 2) 폐암을 시사하는 흉부 CT 영상 소견
- 3) 폐암의 단계별 감별 진단 (8th Edition of staging system).
- 4) 양성과 악성 결절 시사하는 소견
- 5) 임파선 전이를 시사하는 영상학적 소견**
- 6) 늑막 전이를 시사하는 영상학적 소견
- 7) EGFR, ALK 등 유전자 돌연변이를 동반하는 폐암의 영상학적 특징
- 8) Nodule management
- 9) PCNB (Percutaneous Lung biopsy) 의 대상 선정과 성적
- 10) Lung cancer의 high risk factor 에 대한 영상학적 고려

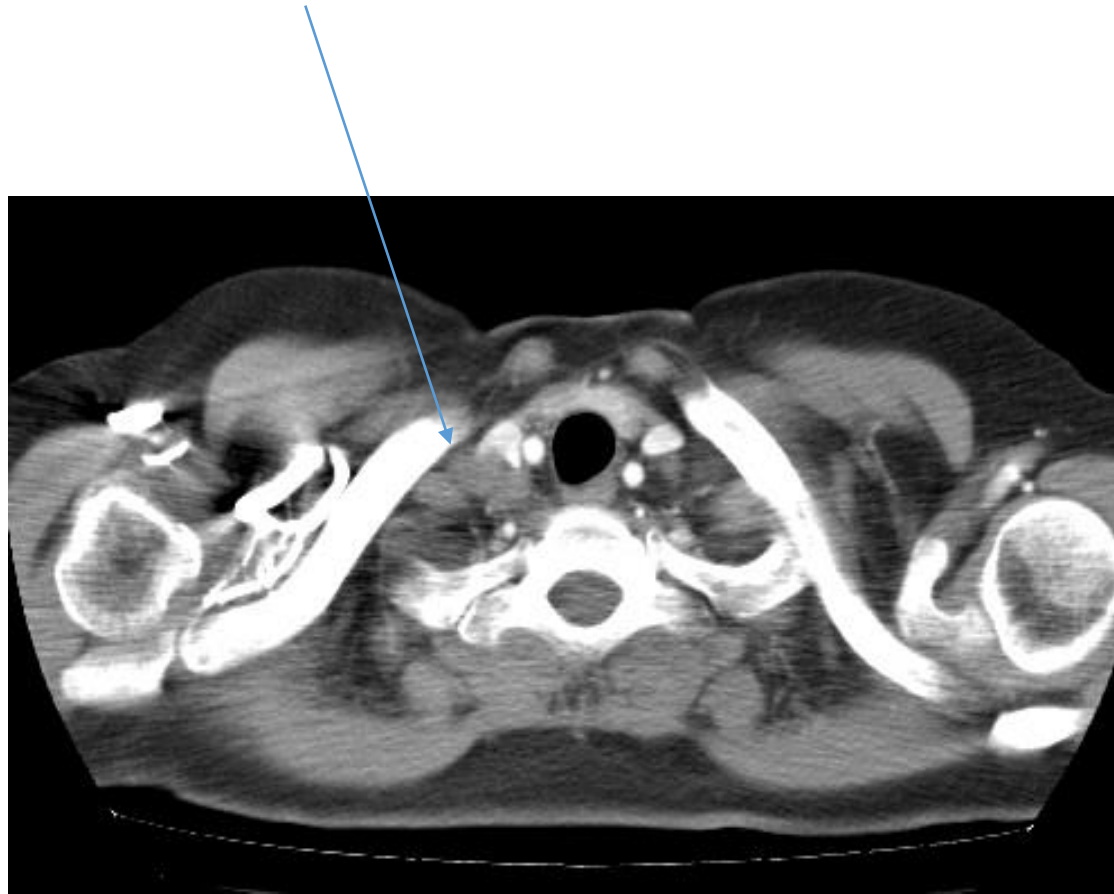
Lung cancer — major changes in the American Joint Committee on Cancer eighth edition cancer staging manual



Favor malignant LN:

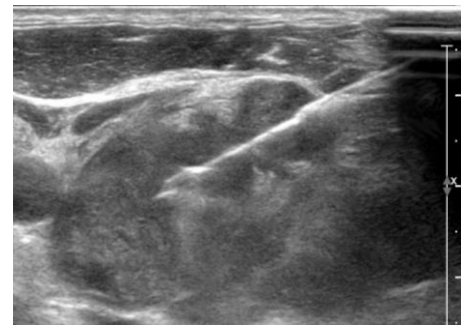
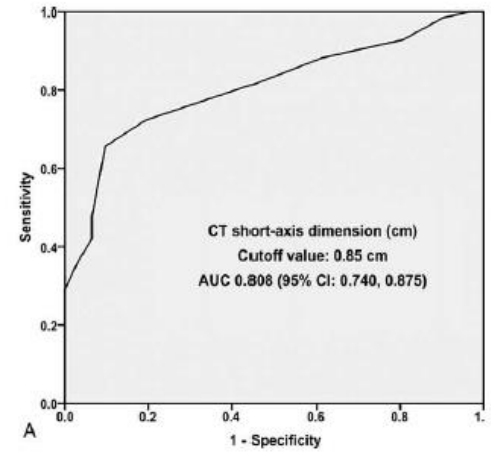
- Short dimension, >10mm
- Loss of fat hilum
- Enhancing node
- Small but multiple aggregated
- Peri-nodal fat infiltration
- PET positive

83/F Adenocarcinoma



Short dimension 10-mm
Long dimension 20-mm

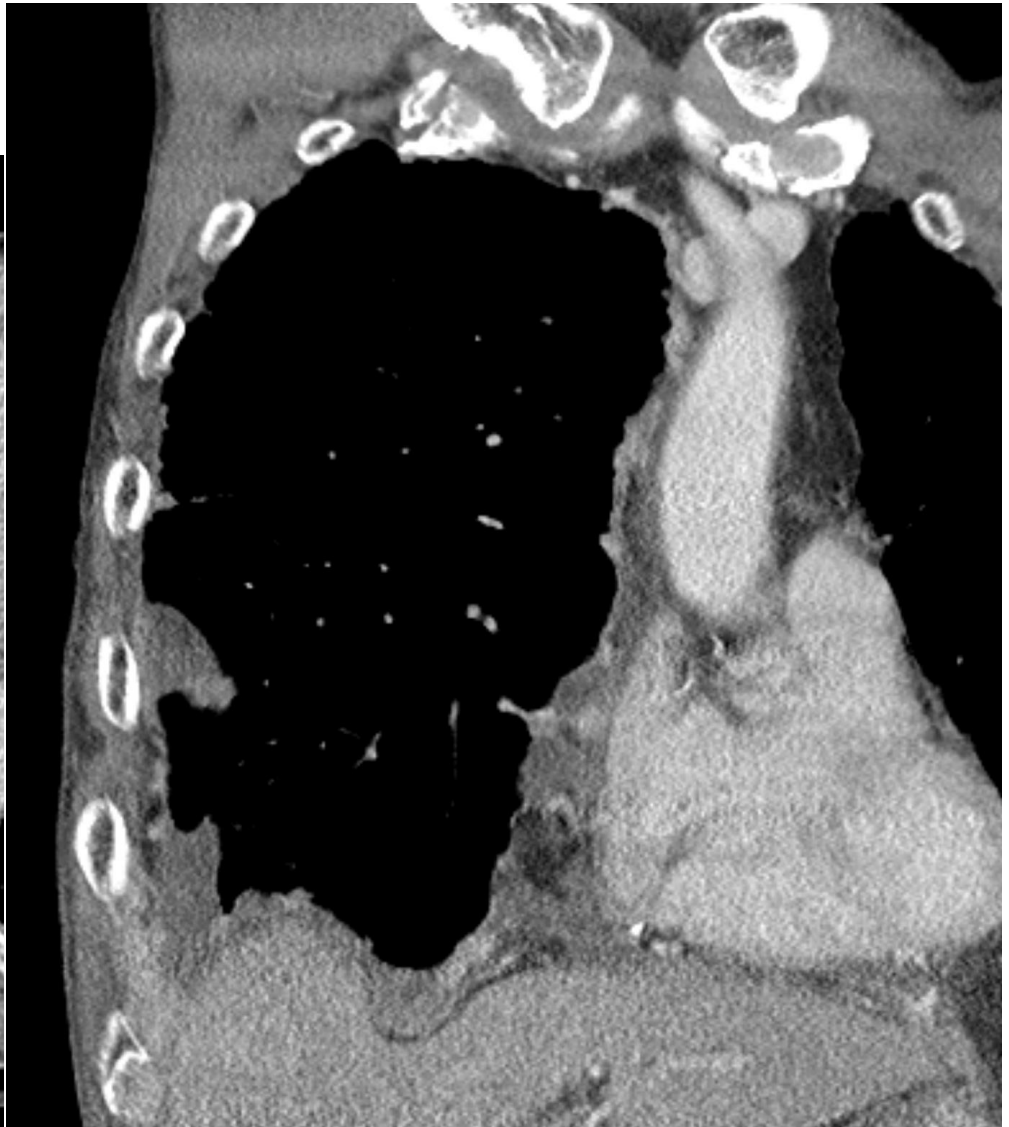
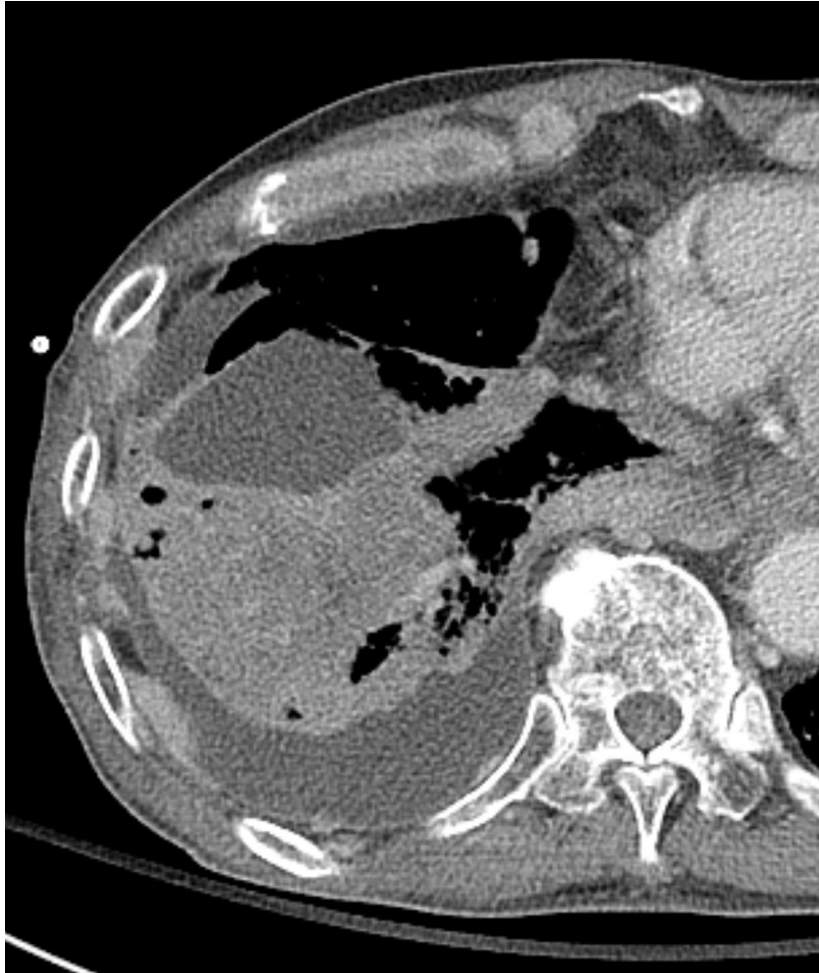Short dimension 8.5mm



- Focusing on CT Imaging, Real Field

- 1) 전암 병변 및 초기 폐암을 시사하는 폐 결절의 영상학적 구분
- 2) 폐암을 시사하는 흉부 CT 영상 소견
- 3) 폐암의 단계별 감별 진단 (8th Edition of staging system).
- 4) 양성과 악성 결절 시사하는 소견
- 5) 임파선 전이를 시사하는 영상학적 소견
- 6) 늑막 전이를 시사하는 영상학적 소견**
- 7) EGFR, ALK 등 유전자 돌연변이를 동반하는 폐암의 영상학적 특징
- 8) Nodule management
- 9) PCNB (Percutaneous Lung biopsy) 의 대상 선정과 성적
- 10) Lung cancer의 high risk factor 에 대한 영상학적 고려

72/M Malignant effusion with seeding, SCLC

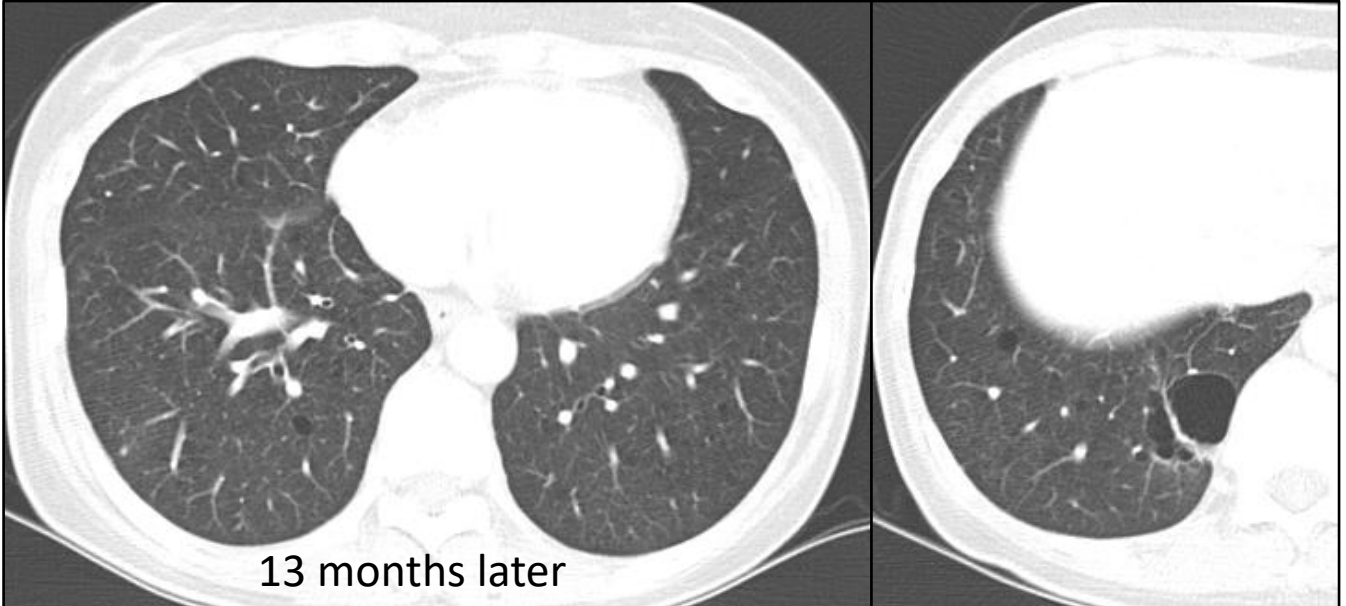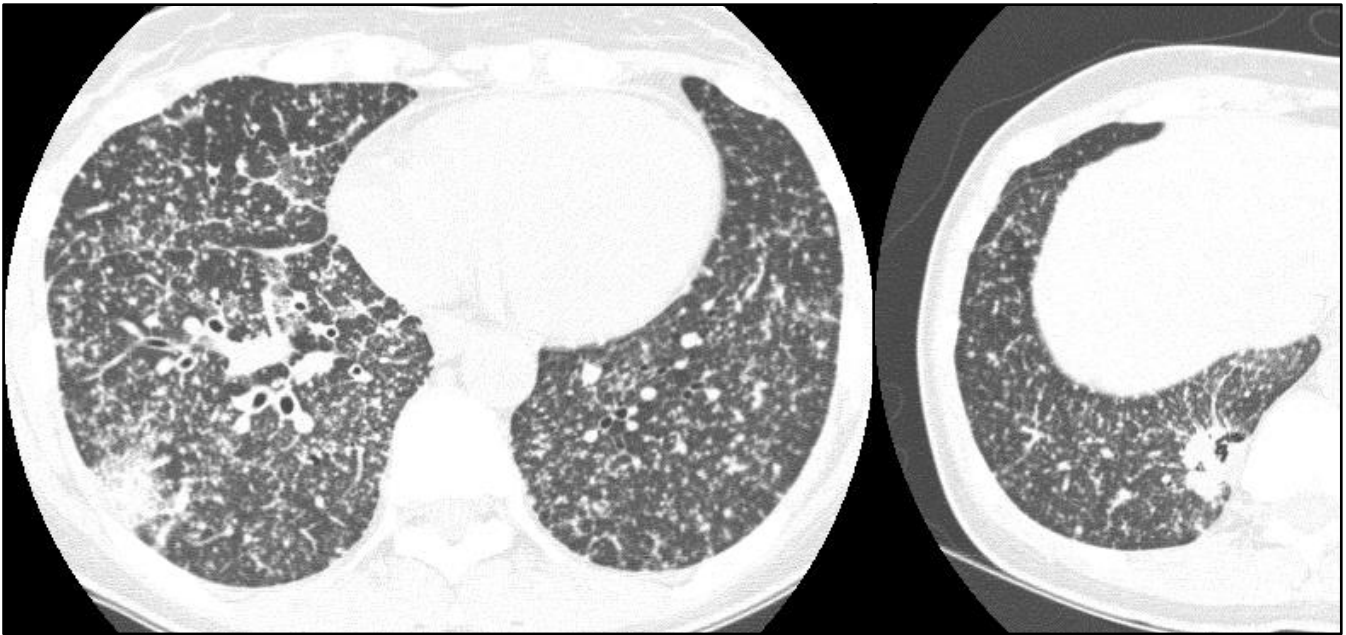


Pleural fluid : METASTATIC CARCINOMA

- Focusing on CT Imaging, Real Field

- 1) 전암 병변 및 초기 폐암을 시사하는 폐 결절의 영상학적 구분
- 2) 폐암을 시사하는 흉부 CT 영상 소견
- 3) 폐암의 단계별 감별 진단 (8th Edition of staging system).
- 4) 양성과 악성 결절 시사하는 소견
- 5) 임파선 전이를 시사하는 영상학적 소견
- 6) 늑막 전이를 시사하는 영상학적 소견
- 7) EGFR, ALK 등 유전자 돌연변이를 동반하는 폐암의 영상학적 특징**
- 8) Nodule management
- 9) PCNB (Percutaneous Lung biopsy) 의 대상 선정과 성적
- 10) Lung cancer의 high risk factor 에 대한 영상학적 고려

45/F ADC (19Del), never smoker

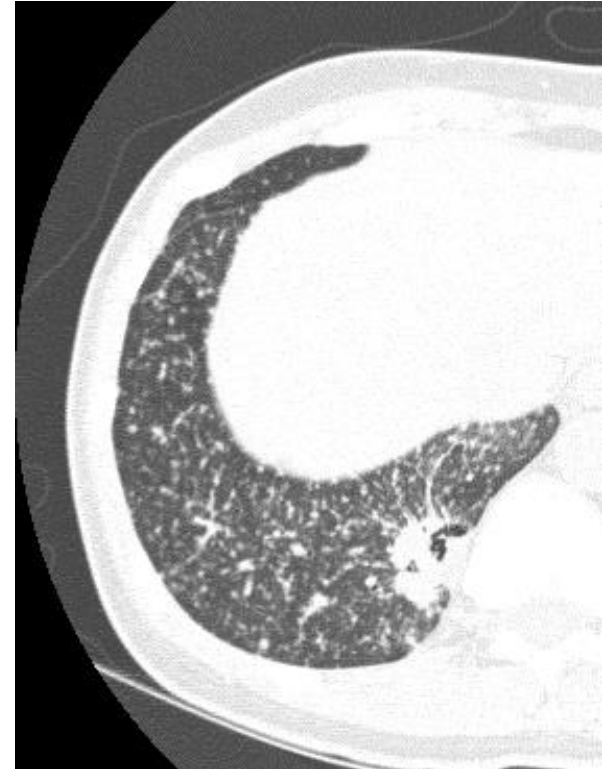


13 months later

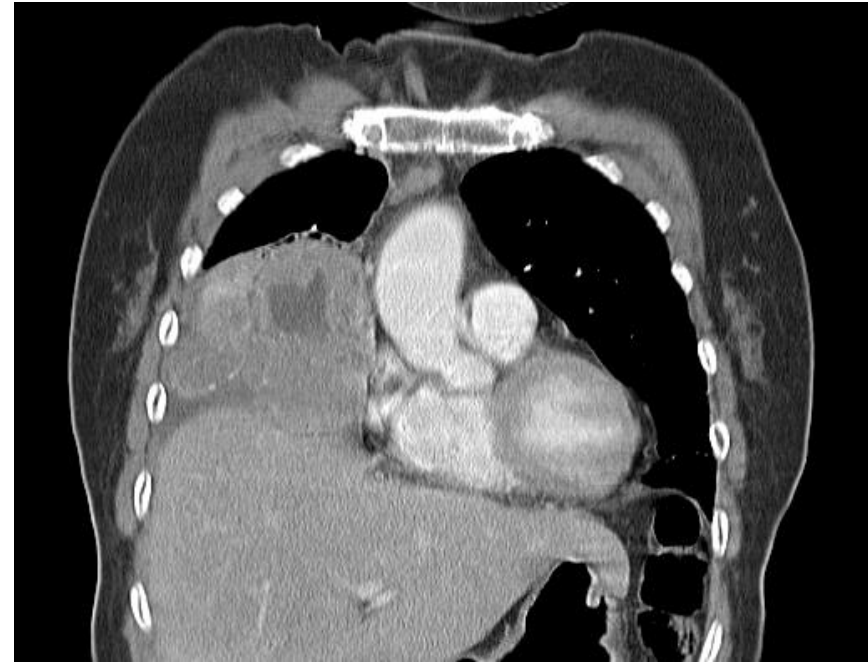
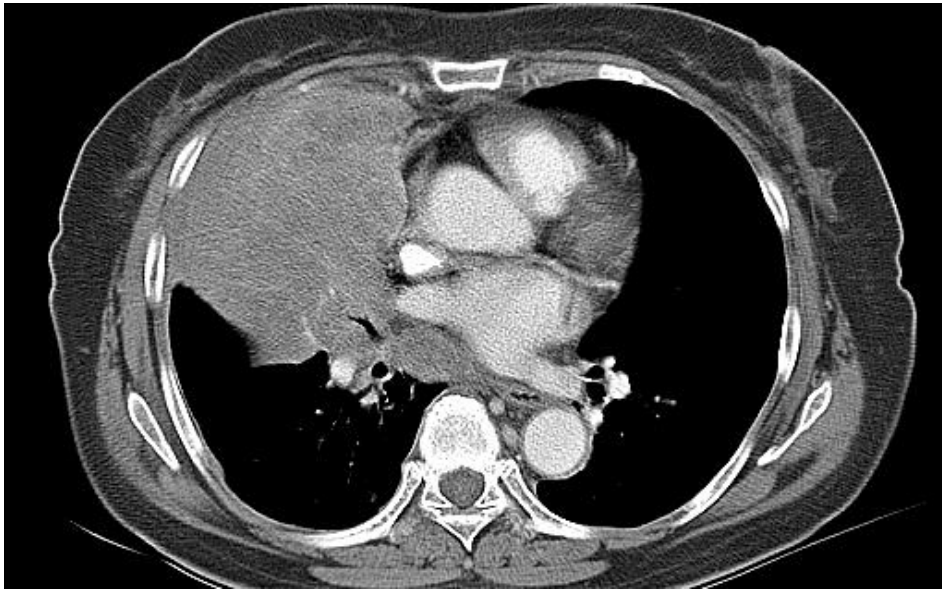


[Laack E. et al J Thorac Oncol. 2011;6:199](#)
Never smoking adenoCa
EGFR (+), a deletion in exon 19
Miliary mets.
→ Dramatic response to EGFR TKI
→ Upfront Tx

- Small nodule size
 - Nodule-type main tumor
 - Peripheral location of the nodule
 - 19, 21 del mutation in EGFR
- Better responders to EGFR TKI



70/F ADC (21 Del) and PD

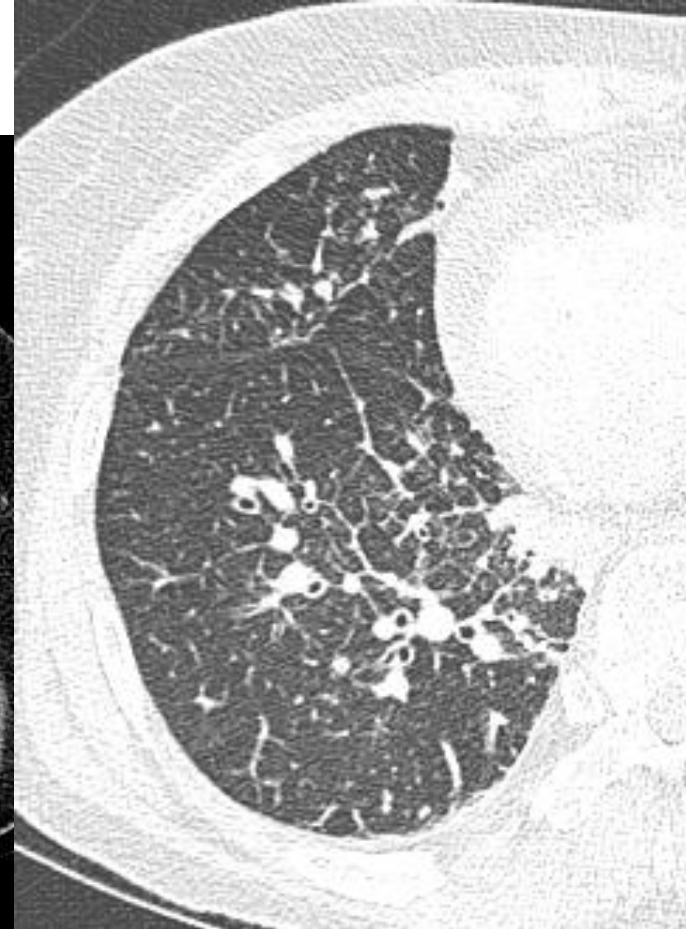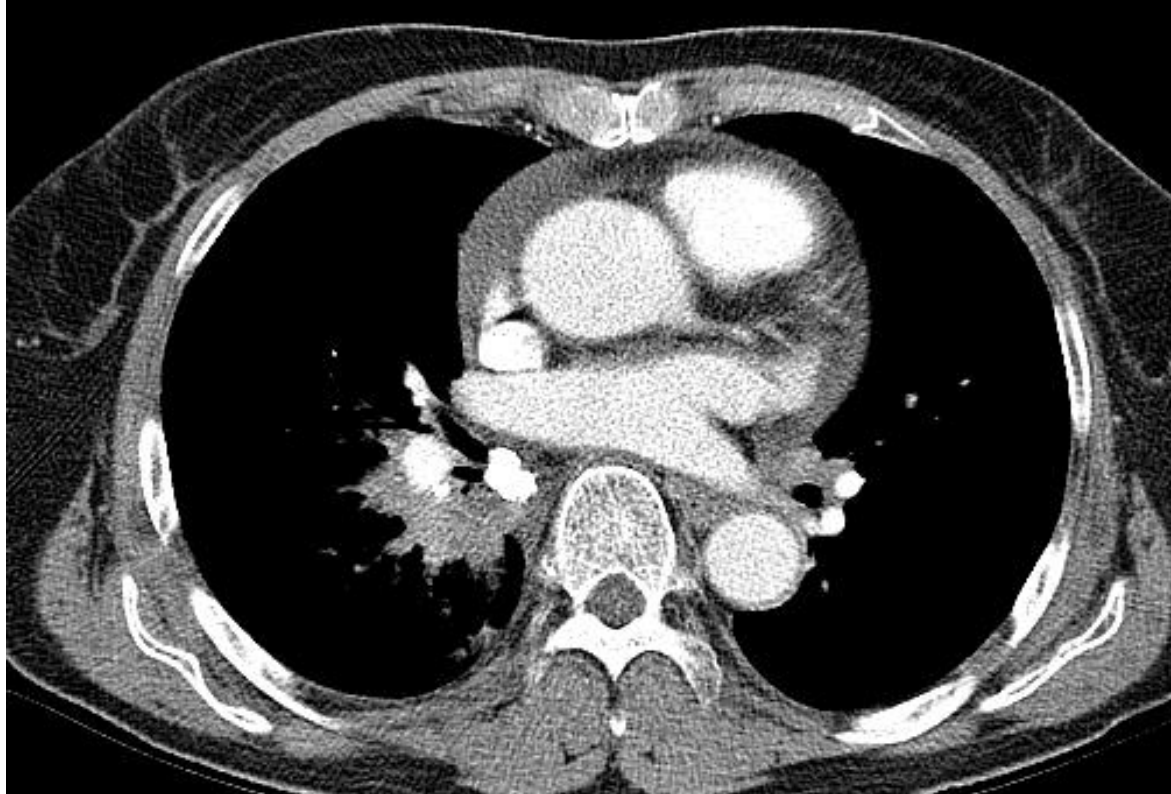


Large size

Mass-type tumors

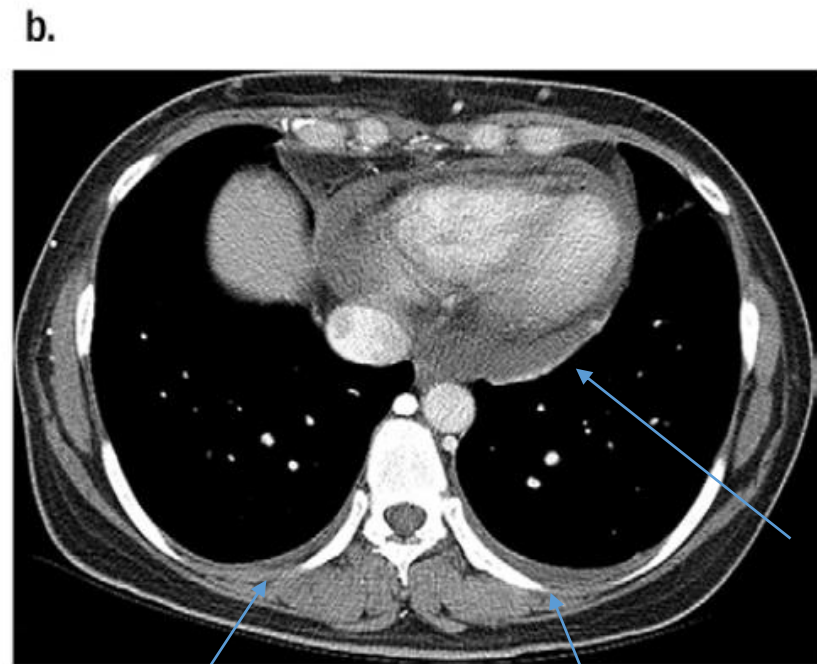
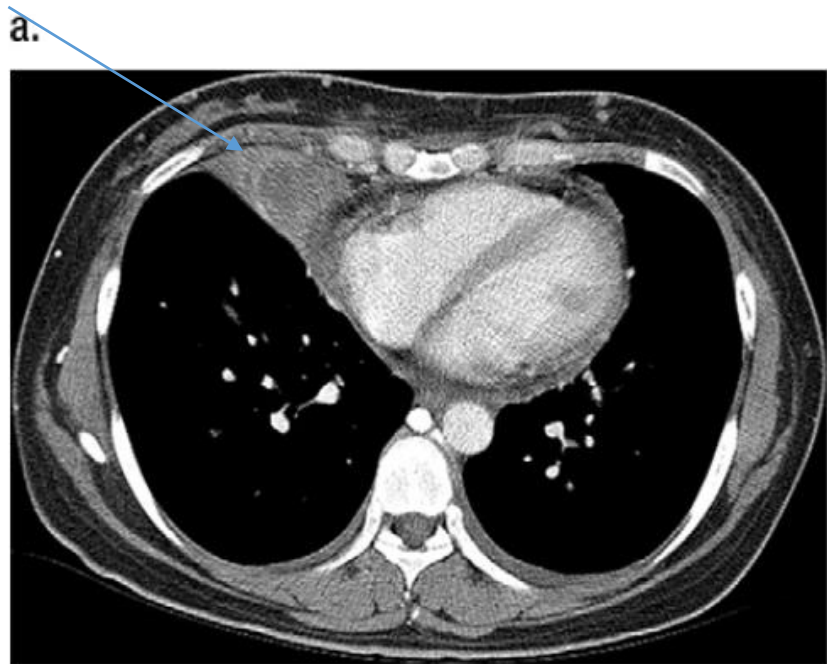
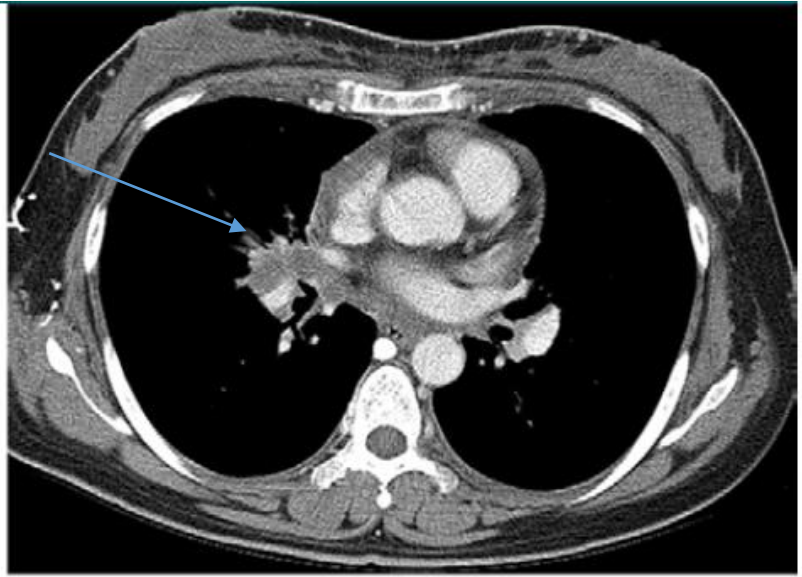
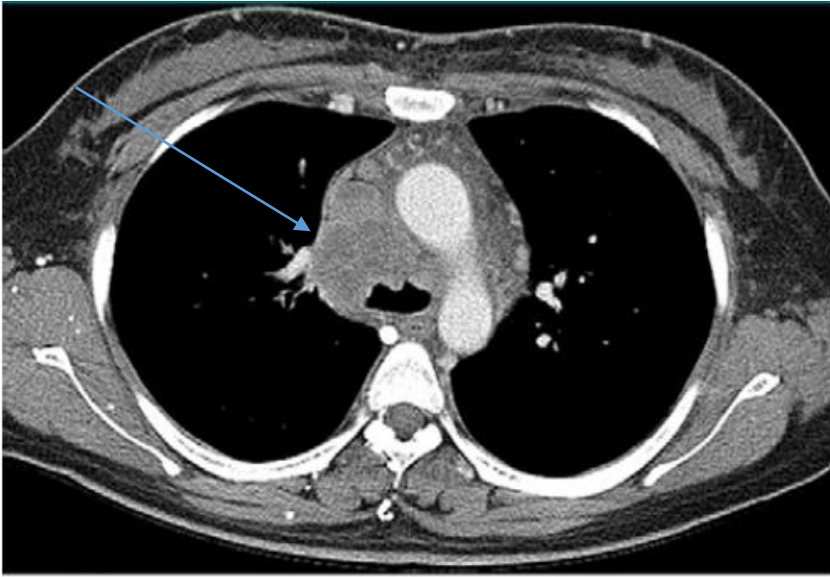
→ Poorer responders to EGFR TKI

70F ADC (EGFR 19Del) and SD



Central location of the mass
Lung (lymphangitic) or pleural metastasis
→ Poorer responders to EGFR TKI

41/M ADC, ALK rearrangement



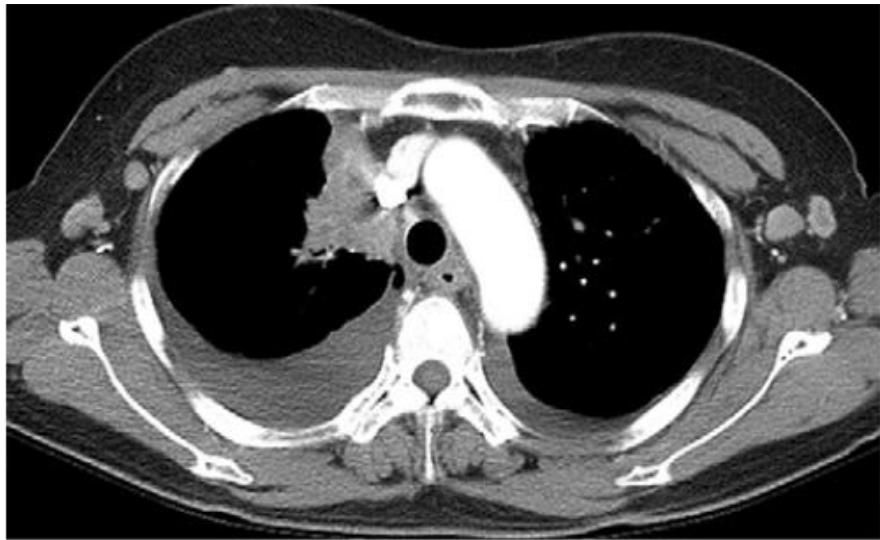a.

b.

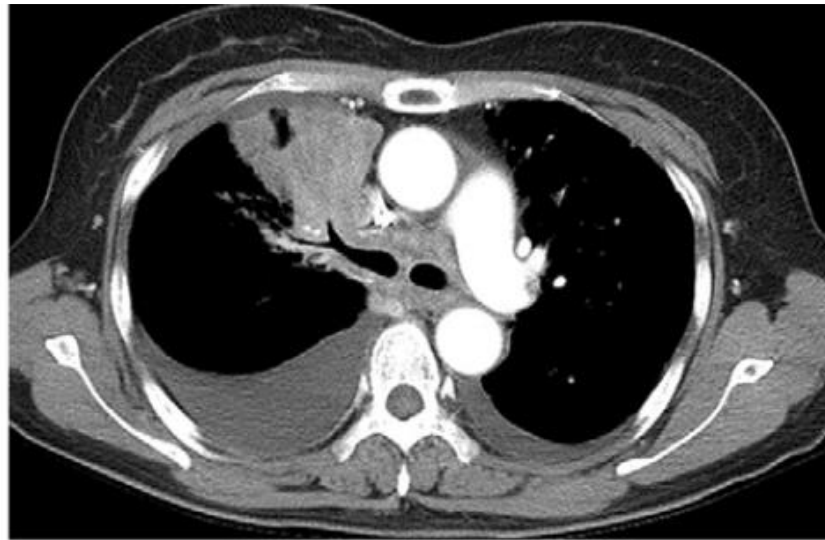
c.

d.

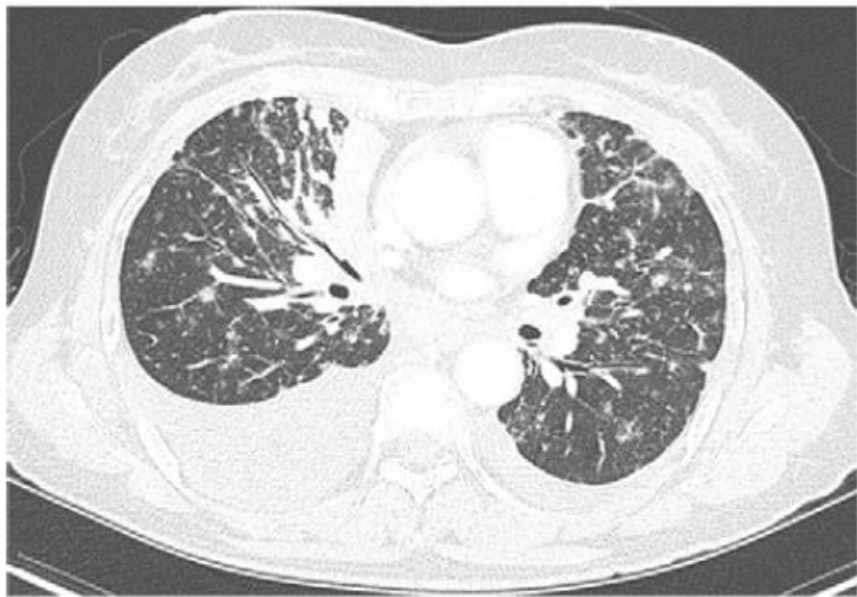
56/F ADC, ALK rearrangement



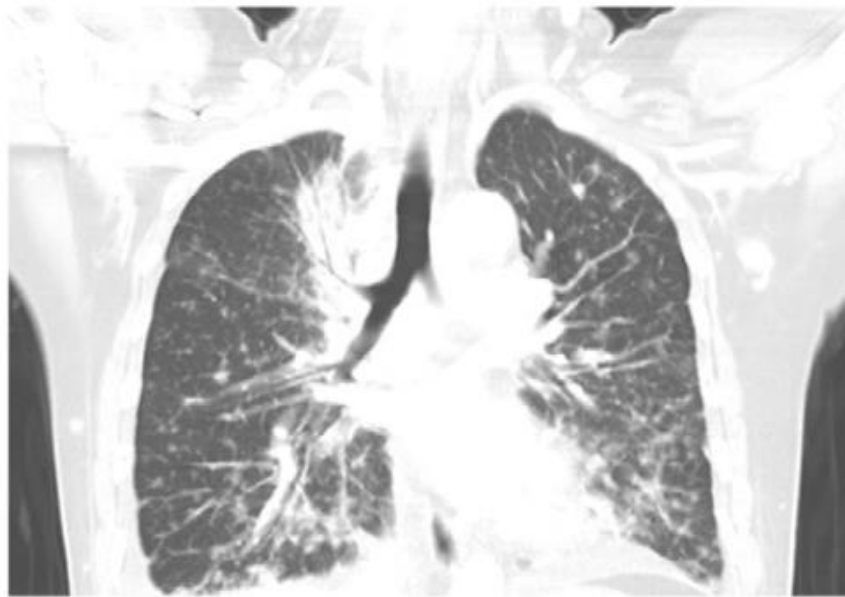
a.



b.



c.



d.

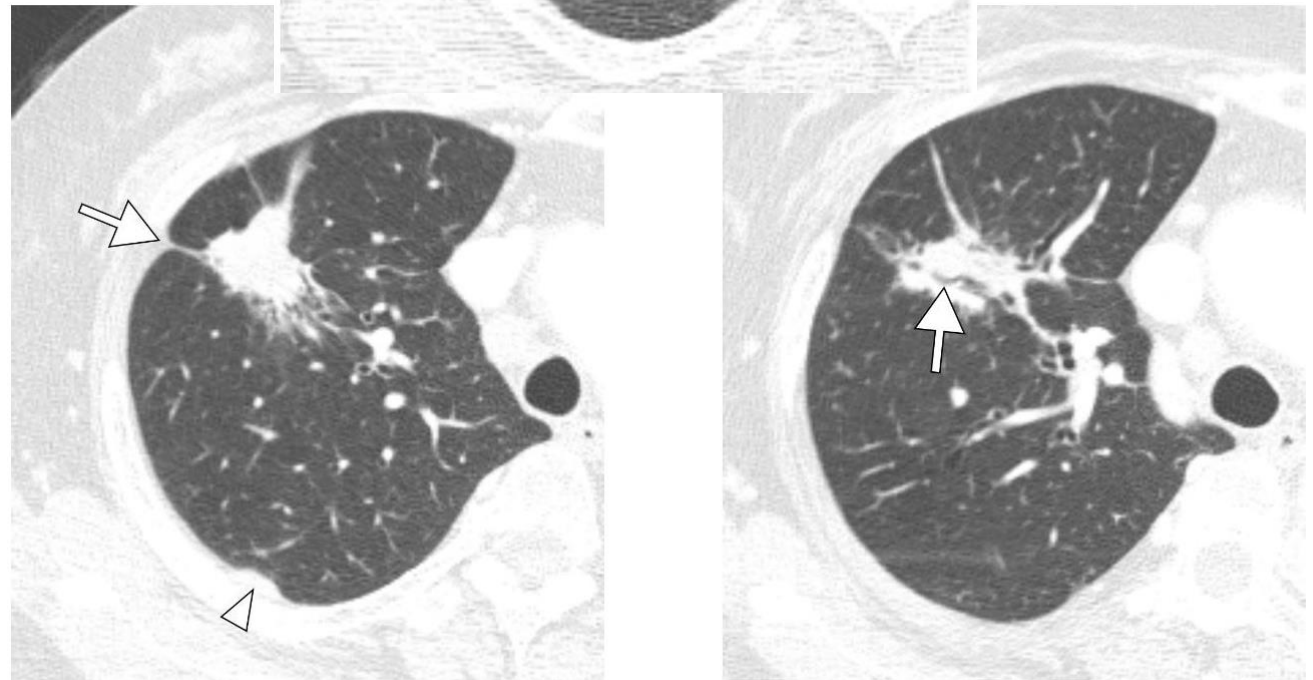
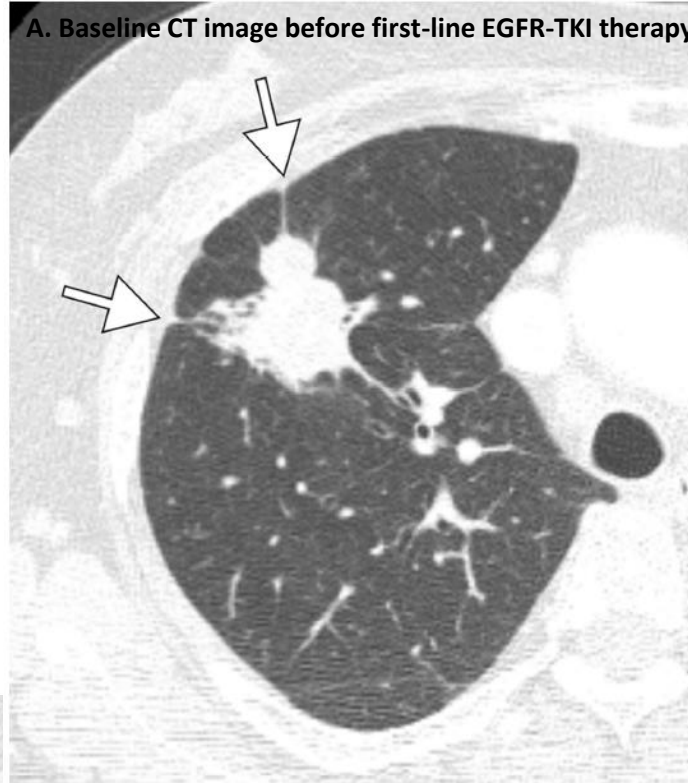Advances in Knowledge

- Patients with anaplastic lymphoma kinase gene rearrangement were younger (odds ratio [OR], 0.954; 95% confidence interval [CI]: 0.922, 0.986; $P = .006$) and more likely to be men (OR, 3.691 [95% CI: 1.564, 8.712]; $P = .003$) than were those with an epidermal growth factor receptor mutation.
- Lymphangitic lung metastasis (OR, 8.485 [95% CI: 2.238, 32.170]; $P = .002$) and N2 or N3 lymph node involvement (OR, 2.445 [95% CI: 1.005, 5.950]; $P = .049$) were more common in patients with adenocarcinoma and anaplastic lymphoma kinase gene rearrangement than in those with an epidermal growth factor receptor mutation.

63/F ADC, T790M-positive mutation

- Peripheral location
- Pleural tag
- Air bronchogram

A. Baseline CT image before first-line EGFR-TKI therapy



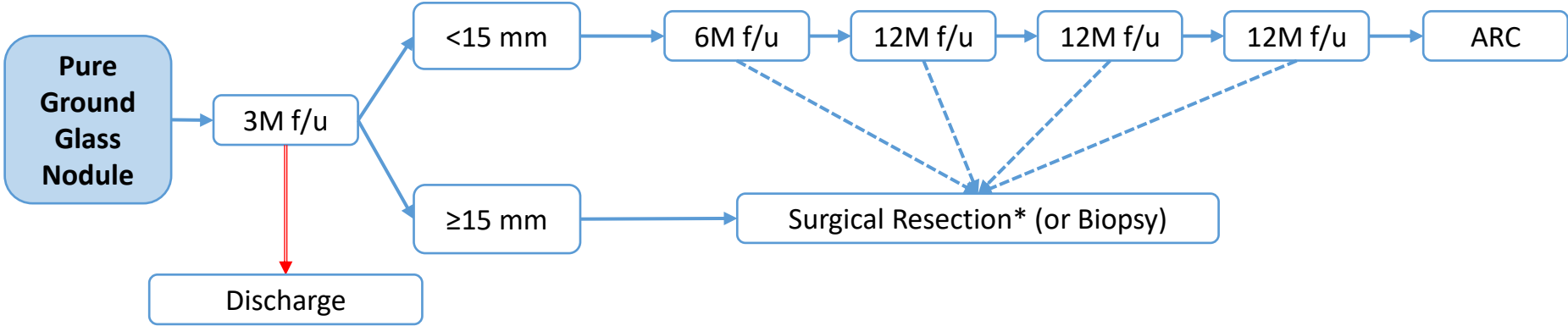
B. C. CT images at the time of re-biopsy in a 63-year-old female with non-small cell lung cancer showing **T790M-positive mutation on re-biopsy.**

- Focusing on CT Imaging, Real Field

- 1) 전암 병변 및 초기 폐암을 시사하는 폐 결절의 영상학적 구분
- 2) 폐암을 시사하는 흉부 CT 영상 소견
- 3) 폐암의 단계별 감별 진단 (8th Edition of staging system).
- 4) 양성과 악성 결절 시사하는 소견
- 5) 임파선 전이를 시사하는 영상학적 소견
- 6) 늑막 전이를 시사하는 영상학적 소견
- 7) EGFR, ALK 등 유전자 돌연변이를 동반하는 폐암의 영상학적 특징
- 8) Nodule management**
- 9) PCNB (Percutaneous Lung biopsy) 의 대상 선정과 성적
- 10) Lung cancer의 high risk factor 에 대한 영상학적 고려

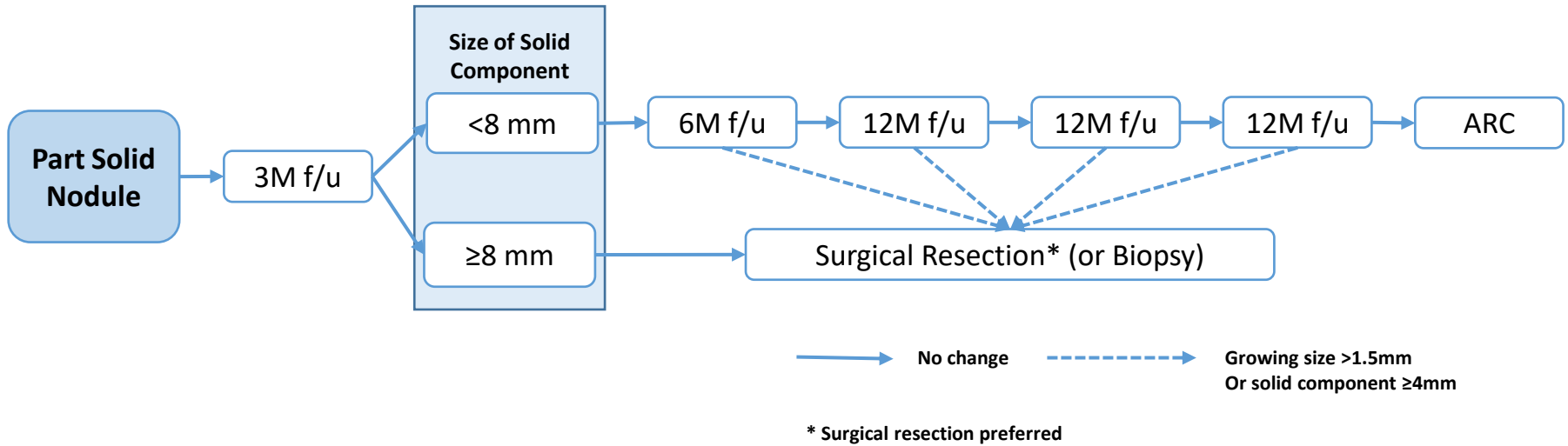
Asan Lung Cancer Research Team

American College of Radiology and the Society of Thoracic Radiology (ACR-STR) guideline
National Comprehensive Cancer Network (NCCN) guideline
Fleishner society guideline
ACCP guideline
Lung RADS

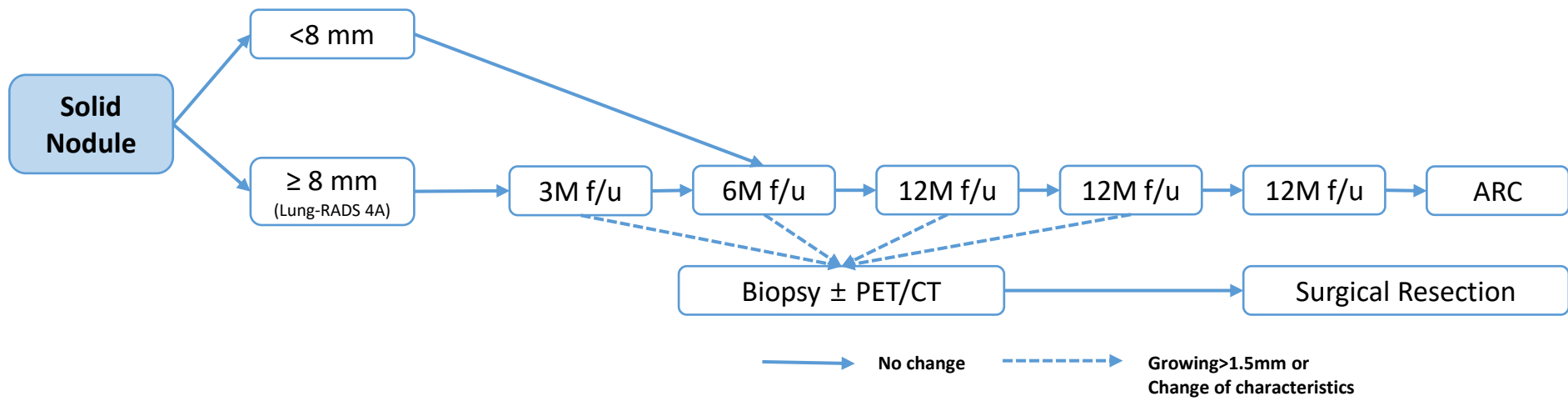


—————> No change - - - - -> Growing > 1.5mm
Or Change of characteristics
(Solid component) ———> Disappeared

* Surgical resection preferred



❖ Individualized surgical techniques are required depending on the location and pulmonary function



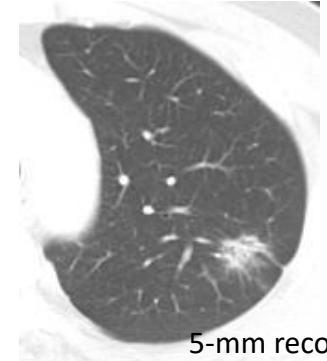
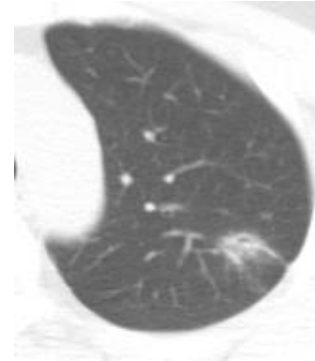
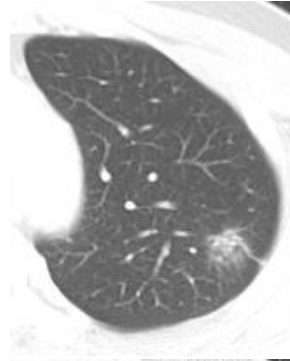
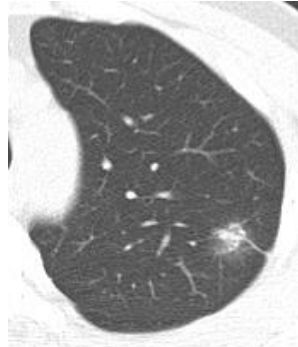
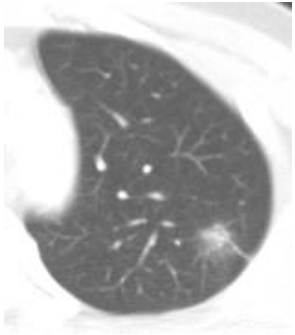
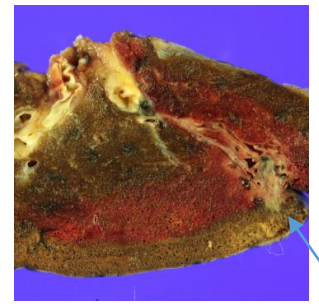
❖ Individualized approaches are needed according to nodule characteristics

Summary

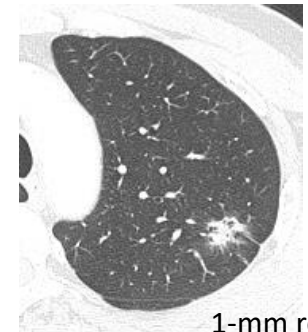
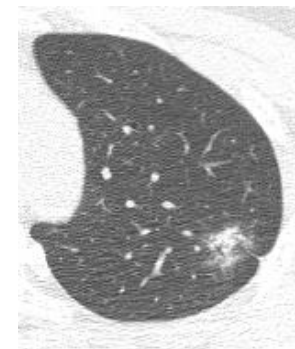
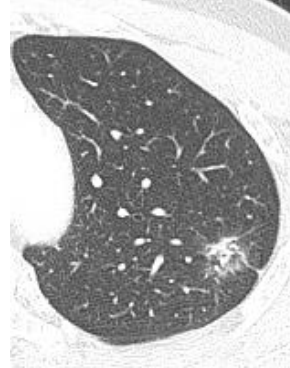
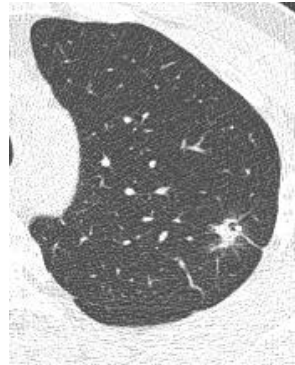
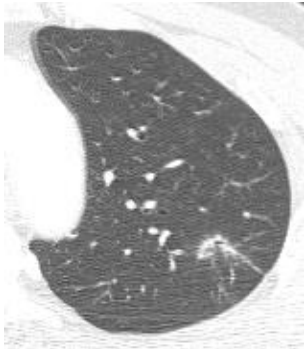
- Basic rule for lung nodule
 - ✓ 3-6-12-12-12-ARC rule
- Highly suspicious (Lung-RADS 4B) nodule
 - ✓ Biopsy first strategy : Solid nodule
 - ✓ Surgical resection preferred strategy : part solid nodule
- Measurement rule of nodule size
 - ✓ Average of long and short axis, rounded to the nearest millimeter
- Multiple pulmonary nodules
 - ✓ Subsequent management based on most suspicious nodules

62M MIA

- T1aN0Mx
- Lung, (left upper lobe), lobectomy:
- MINIMALLY INVASIVE ADENOCARCINOMA



5-mm recon



1-mm recon

2010-05-31

2010-09-12

2011-10-21

2012-11-30

2013-10-15
18mm
Subsolid GGN

• Focusing on CT Imaging, Real Field

- 1) 전암 병변 및 초기 폐암을 시사하는 폐 결절의 영상학적 구분
- 2) 폐암을 시사하는 흉부 CT 영상 소견
- 3) 폐암의 단계별 감별 진단 (8th Edition of staging system).
- 4) 양성과 악성 결절 시사하는 소견
- 5) 임파선 전이를 시사하는 영상학적 소견
- 6) 늑막 전이를 시사하는 영상학적 소견
- 7) EGFR, ALK 등 유전자 돌연변이를 동반하는 폐암의 영상학적 특징
- 8) Nodule management
- 9) **PCNB (Percutaneous Lung biopsy) 의 대상 선정과 성적**
- 10) Lung cancer의 high risk factor 에 대한 영상학적 고려

PCNB (Percutaneous Needle Lung Biopsy)

Indications

- pulmonary lesion inaccessible to bronchoscopy
- prior bronchoscopic biopsys nondiagnostic
- mediastinal or pleural mass

- Peripheral location
- Solid nodule > subolid GGN
- Larger mass
- Upper and middle lobe

Contraindication

- poor respiratory function or reserve
- uncooperative patient
- lack of safe access
- uncorrectable bleeding diathesis (abnormal coagulation indices)

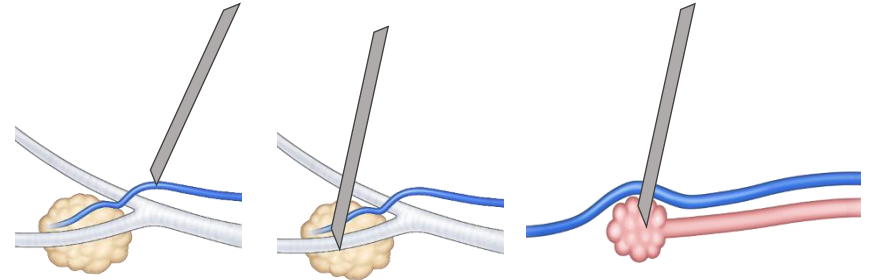
Complications

- **Pneumothorax**
most common
the reported rate of pneumothorax varies widely from 8-64%
- **Alveolar hemorrhage**
may be seen in ~10% (range 5-16.9%)
hemoptysis: occurs in 1-5% of patients
- **Air embolism**
extremely rare (0.02 – 0.7%) but
potentially fatal complication

PTNB and Air Embolism

Proposed Mechanism

1. Placing the needle tip in the pulmonary vein: direct communication between the atmosphere and the pulmonary vein
2. Formation of direct broncho-venous fistula
3. Formation of alveolar-venous fistula



Risk Factors

1. Coughing during PTNB
2. Cavitary or cystic lesions
3. Large needle size
4. Parenchymal hemorrhage

Symptoms

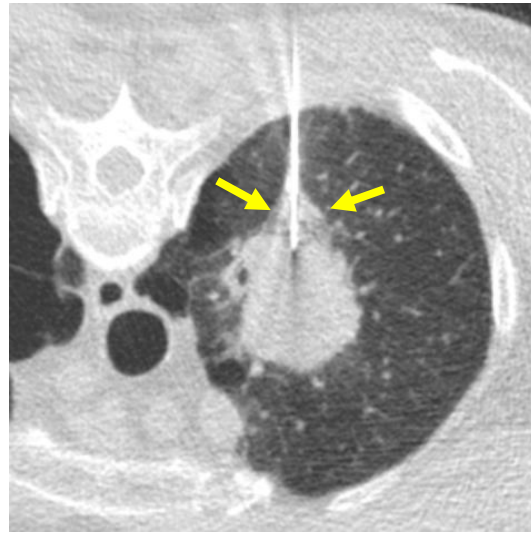
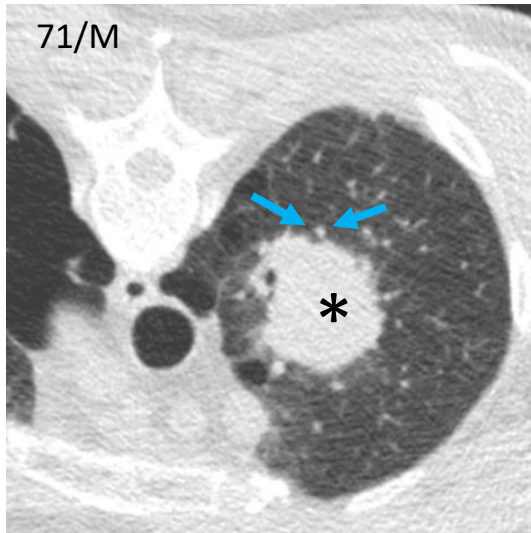
1. Cardiac ischemia
2. Cerebral infarction or seizure
3. Hypotension
4. Loss of consciousness
5. Muscle weakness

Treatment (Not established)

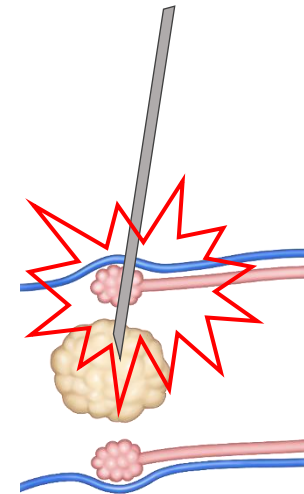
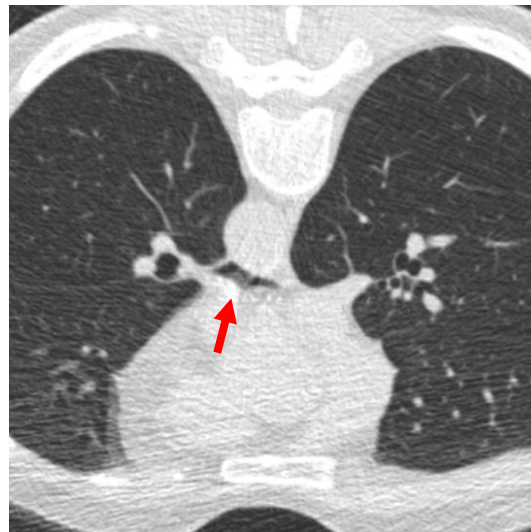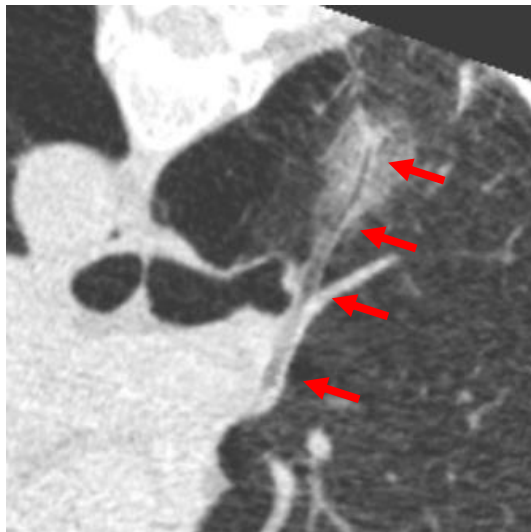
1. Hyperbaric oxygen
2. Trendelenburg position

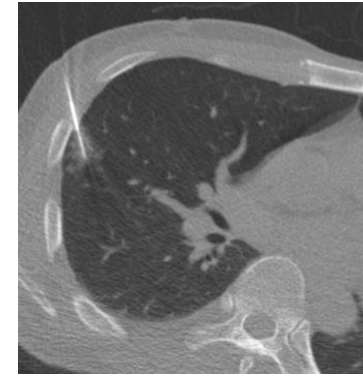
AJR Am J Roentgenol. 2017;208(5):W184-w91
CVIR 2014; 37:1312-1320
Cardiovasc Intervent Radiol. 2014;37(5):1312-20.
Br J Radiol. 2002;75(897):731-5.
Chest. 2007;132(2):684-90.
Eur J Radiol. 2006;59(1):60-4.
Circulation. 2014;129(9):1046-7.

Pulmonary Vein Injury (before coaxial needle)



A 58-mm solid mass in LUL. Core biopsy was performed in the prone position. Pulmonary vein located behind the mass and was penetrated by coaxial needle. Infiltration around the pulmonary vein developed during the procedure. 3D-reconstructed post-procedural CT shows air density along the pulmonary vein extending to LA. Diagnosis of specimen was adenocarcinoma.



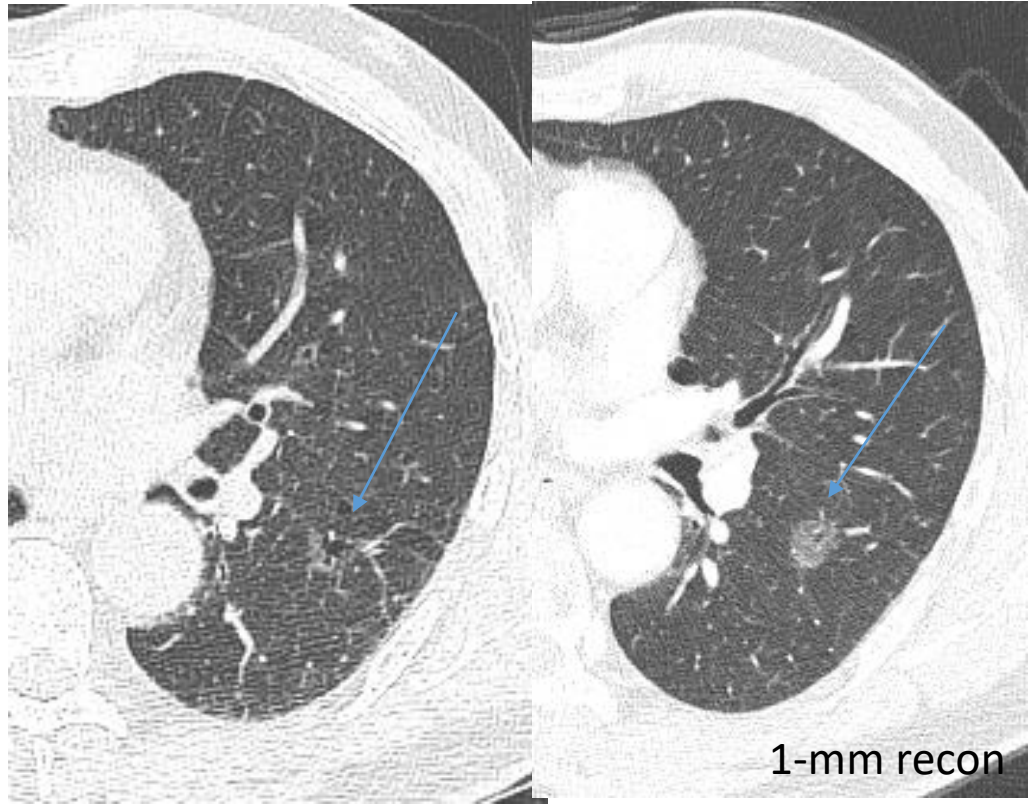


Core biopsy Yield

The use of CT-guided aspiration and core biopsy resulted in a high diagnostic yield for pulmonary nodules smaller than 1 cm

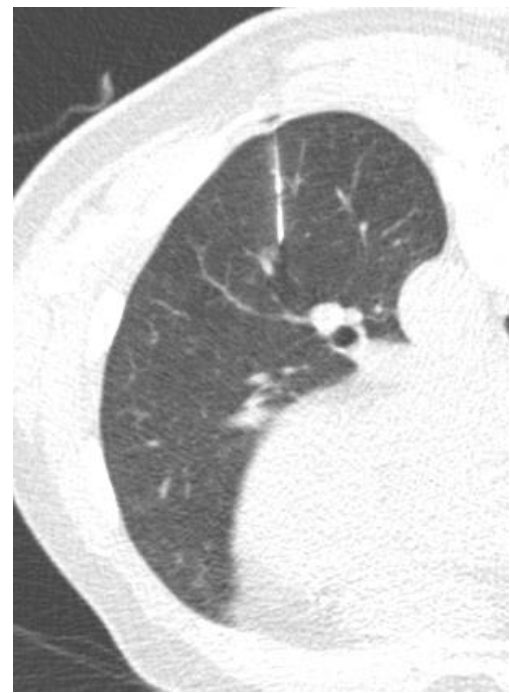- ✓ Sensitivity 93.1% (148 of 159 lesions)
- ✓ Specificity 98.8% (81/82),
- ✓ Positive predictive value 99.3% (148/149)
- ✓ Negative predictive value 88.0% (81/92)
- ✓ **Diagnostic accuracy was 95.0% (229/241)**
- ✓ Aspiration alone was a significant independent risk factor associated with diagnostic failure (odds ratio, 3.199; $p = 0.001$).

61/M proven MIA on wedge resection, Surgical biopsy, Sublobar resection



Initial
Pure GGN, 9mm

Pure GGN, 12mm
: interval growing two
years later

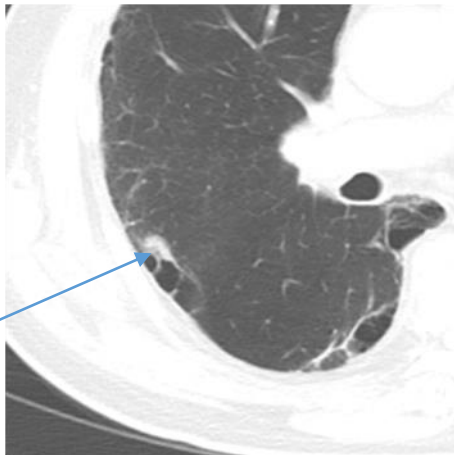


CT guided localization, wedge resection
- deep, central
- small, GGN

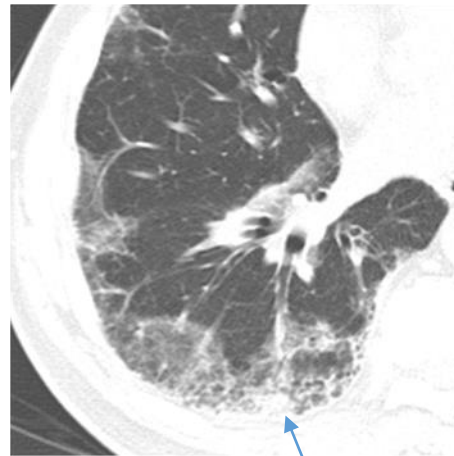
• Focusing on CT Imaging, Real Field

- 1) 전암 병변 및 초기 폐암을 시사하는 폐 결절의 영상학적 구분
- 2) 폐암을 시사하는 흉부 CT 영상 소견
- 3) 폐암의 단계별 감별 진단 (8th Edition of staging system).
- 4) 양성과 악성 결절 시사하는 소견
- 5) 임파선 전이를 시사하는 영상학적 소견
- 6) 늑막 전이를 시사하는 영상학적 소견
- 7) EGFR, ALK 등 유전자 돌연변이를 동반하는 폐암의 영상학적 특징
- 8) Nodule management
- 9) PCNB (Percutaneous Lung biopsy) 의 대상 선정과 성적
- 10) Lung cancer의 high risk factor 에 대한 영상학적 고려

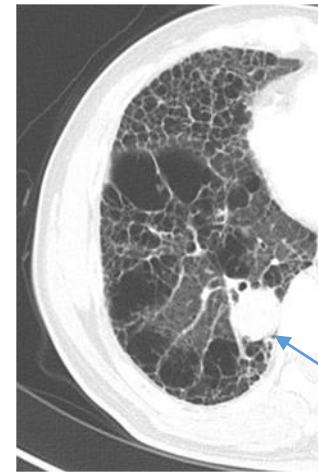
- Lung cancer, high risk factor (> 65%)
 → old age, heavy smoking; emphysema, chronic bronchitis, larger lung nodule, irregular or speculated margin, upper location



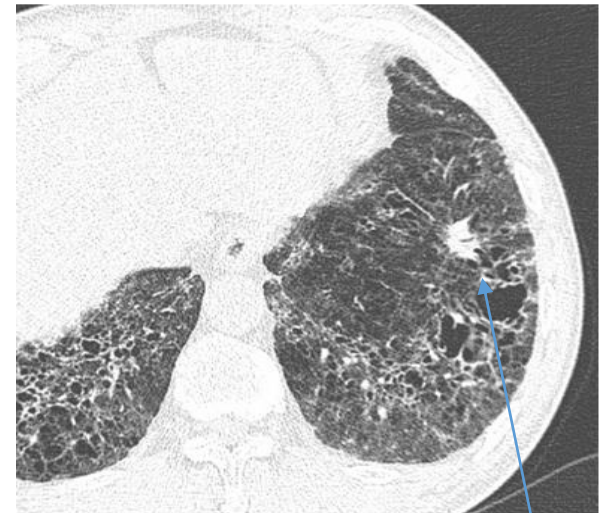
Emphysema and bullae



IIP, NSIP pattern



IIP, UIP pattern



New lung cancers identified during CT follow-up of IIP usually appear as small round or oval solid nodules. Most cancers are located at the interface of or in the midst of fibrotic cysts of the lower lobes of subpleural lung.

Conclusion: Multidisciplinary Approach, Lung Cancer

