



제264회 KATRD 심포지엄
- 기관지경연구회 증례



Case 2

삼성서울병원 호흡기내과
R4. 강노을

2019.02.18

Patient information

- F/36
- Chief complaint
 - Chest discomfort and dyspepsia (Onset : 3MA)

Present illness

- 평소에 소화가 잘 안 되던 분으로 내원 3개월 전 부터 chest discomfort, dyspepsia 심해져 위 내시경 시행하러 동네 의원 방문하였고 이후 시행한 검사 결과 상 이상 소견으로 본원 외래 내원함
- V/S 126/74 mmHg – 83/min – 18/min – 36.7°C

Past history

- HTN/DM/Tbc/Hepatitis (-/-/-/-)
- No current medication
- Social history
 - Alcohol (-)
 - Never smoker
- Operation history (-)
- Family history (-)

Review of system

<p>General</p>	<p>General weakness (-) Weight loss (-) Fever / Chill (-/-) Headache / Dizziness(-/-)</p>
<p>Respiratory</p>	<p>Cough / Sputum / Rhinorrhea (-/-/-) Dyspnea / Orthopnea (-/-) <u>Chest discomfort (+)</u></p>
<p>Cardiovascular</p>	<p>Chest pain (-) Palpitation (-)</p>
<p>GI / GU</p>	<p><u>Dyspepsia (+)</u> Abdominal pain (-) Poor oral intake (-) Anorexia / Nausea / Vomiting (-/-/-) Diarrhea / Constipation (-/-) Melena / Hematochezia / Hematemesis (-/-/-) Dysuria / Frequency / Nocturia / Hematuria (-/-/-/-)</p>
<p>Musculoskeletal</p>	<p>Myalgia / Arthralgia (-/-)</p>

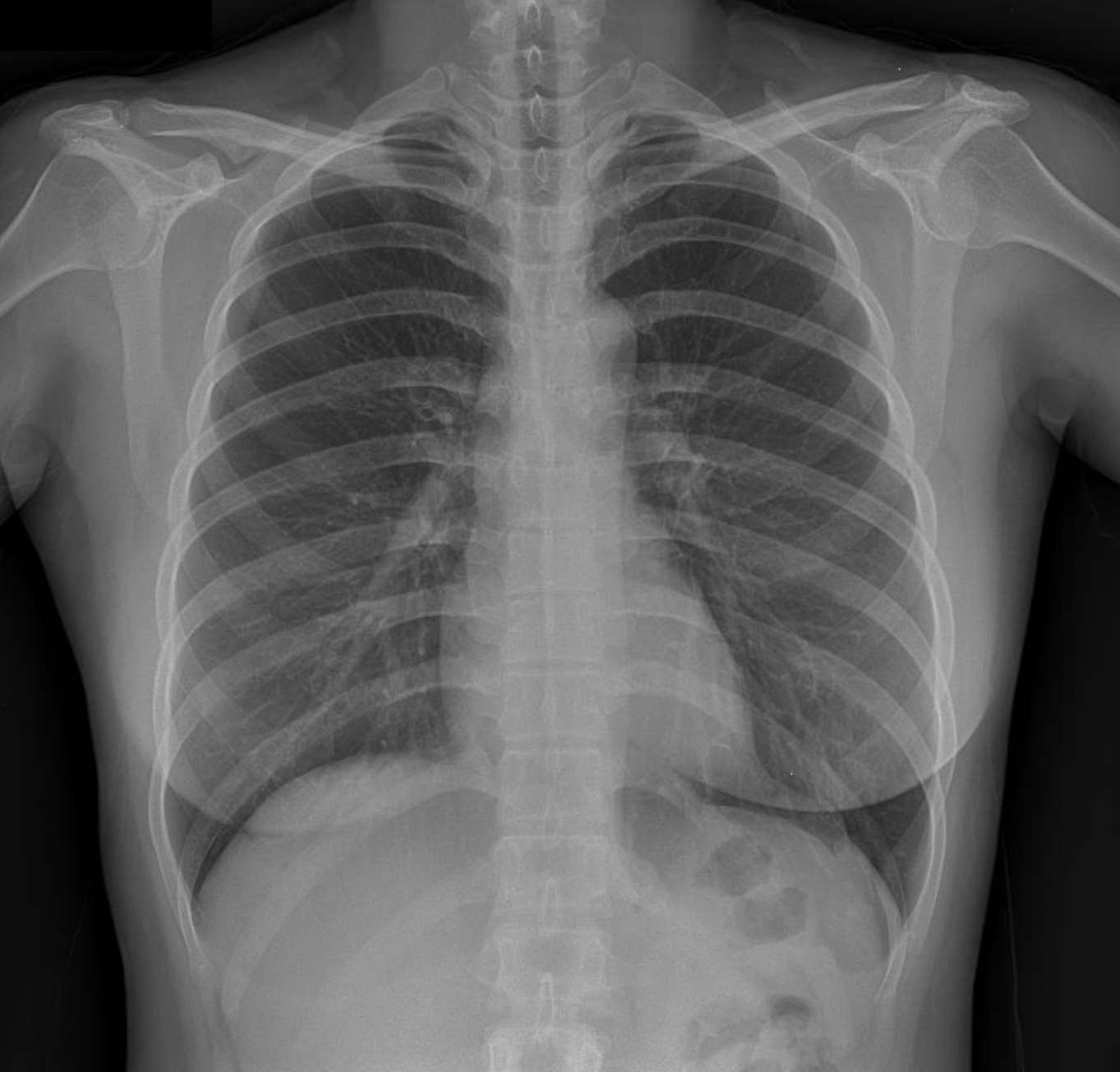Physical examination

General	Not so ill-looking Alert & oriented
HEENT	Non- anemic conjunctivae, Anicteric sclerae Pharyngeal injection (-) Tonsillar enlargement (-)
Chest	Vesicular breathing sound s crackle, wheezing Regular heart beat s murmur Axillary LNE (-/-)
Abdomen	Soft and flat, Normoactive bowel sound Tenderness (-) Rebound tenderness (-)
Extremity	Pretibial pitting edema (-/-)

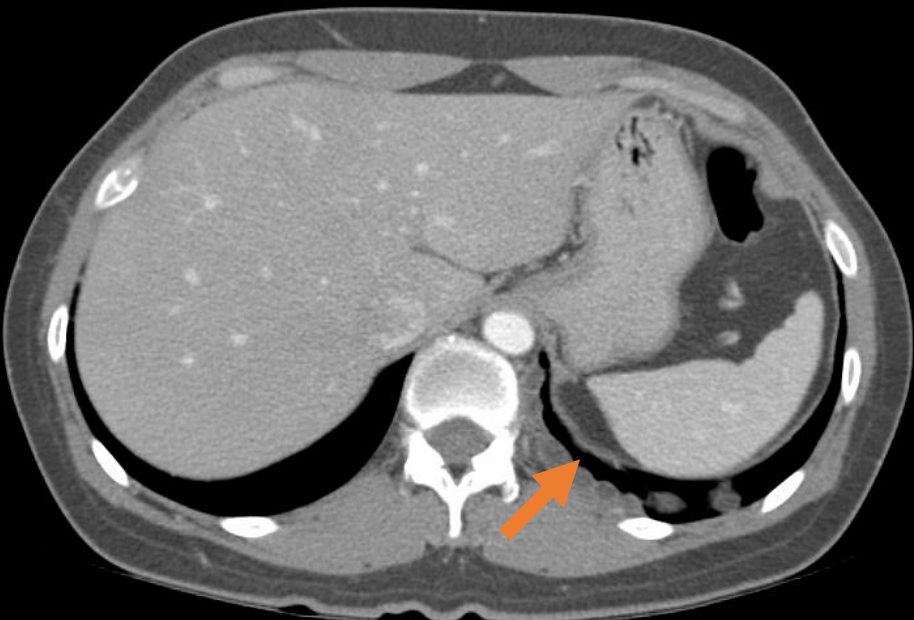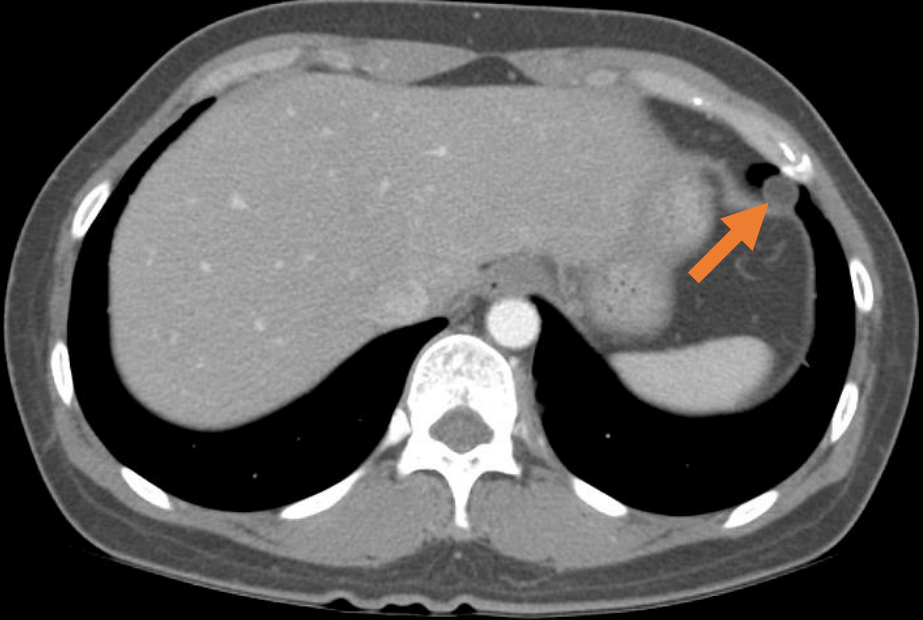
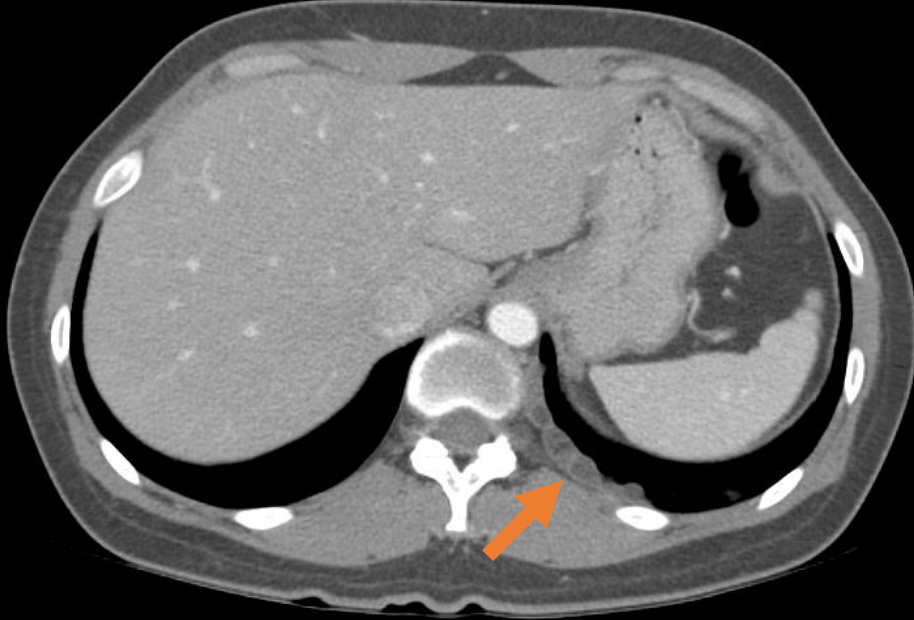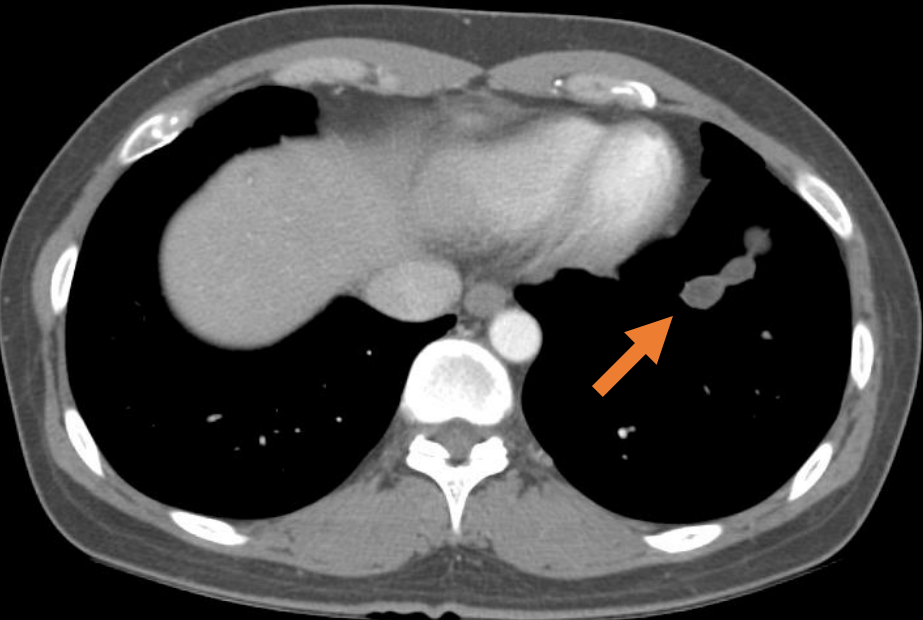
Laboratory findings

- CBC 4550 – 12.8 – 302K
- PT / APTT 0.97 / 36.9
- Protein / Albumin 7.3 / 4.6
- Electrolyte 141 – 4.2 - 102
- Total bilirubin 0.5
- AST/ALT/ALP 42 / 46 / 51
- BUN/Creatinine 11.8 / 0.68
- Cholesterol 187
- ESR/CRP 6 / 0.03

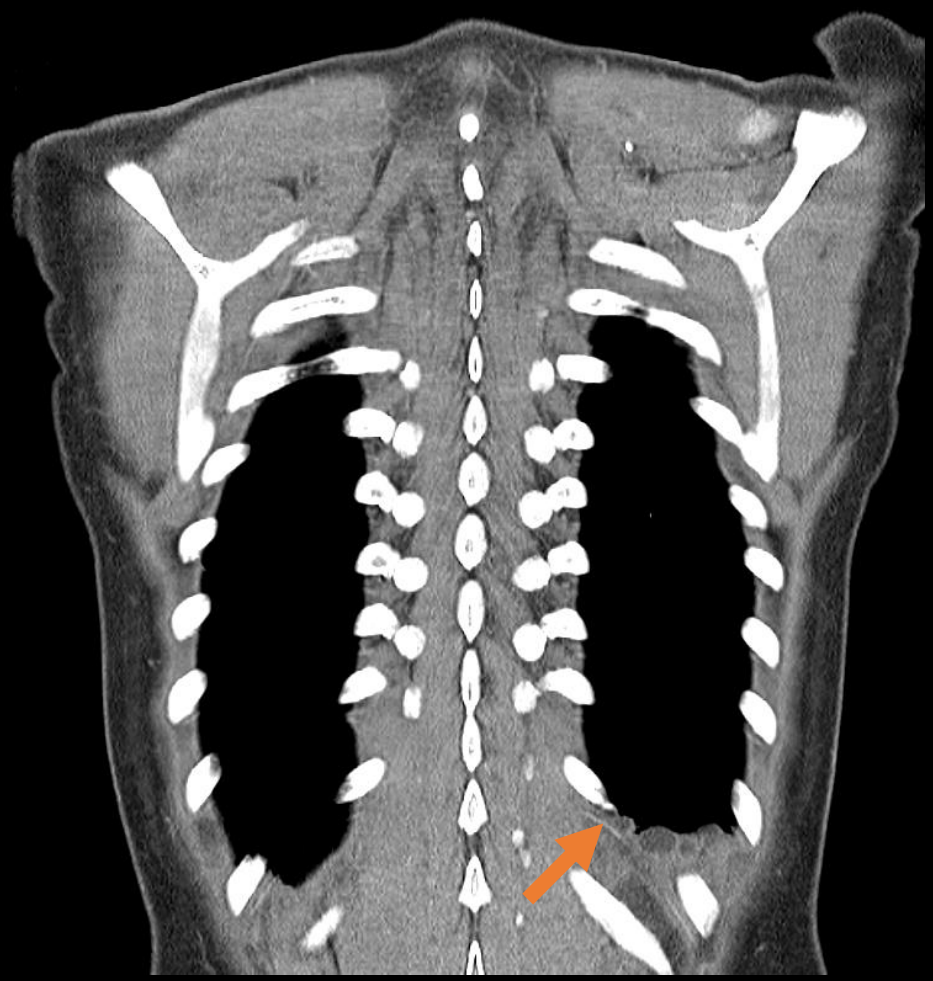
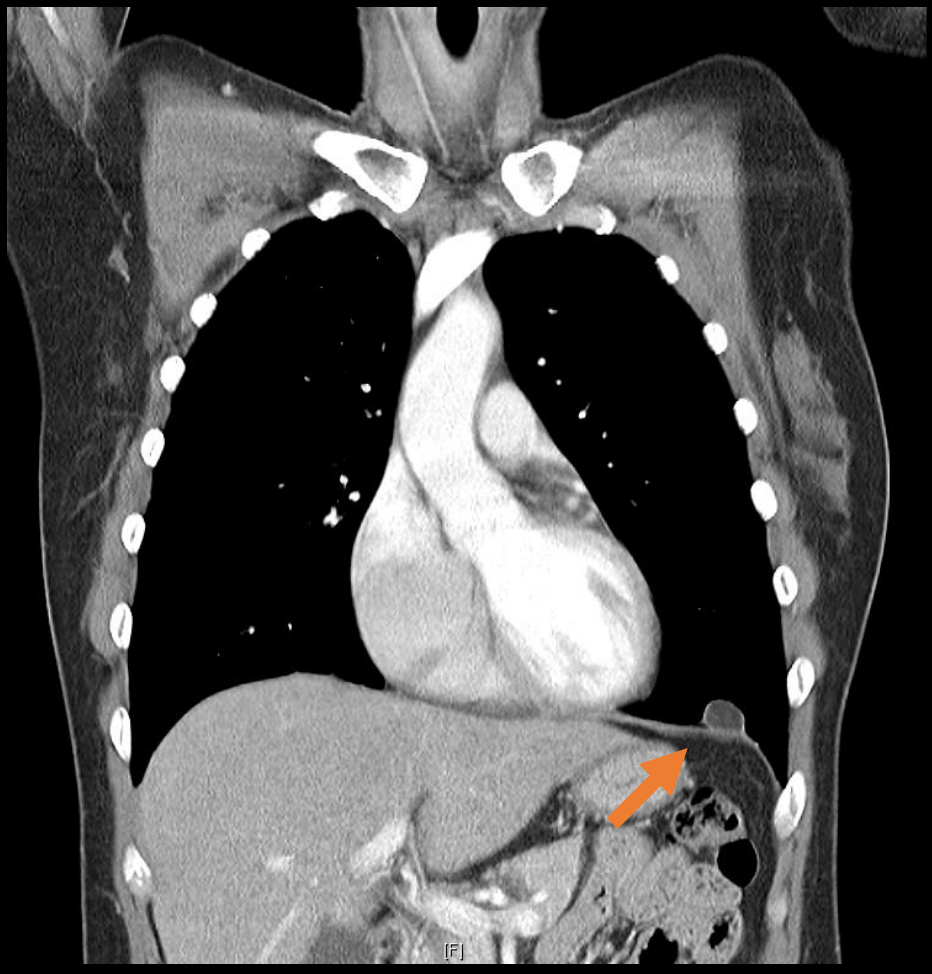
Chest X-ray 2016.10.24



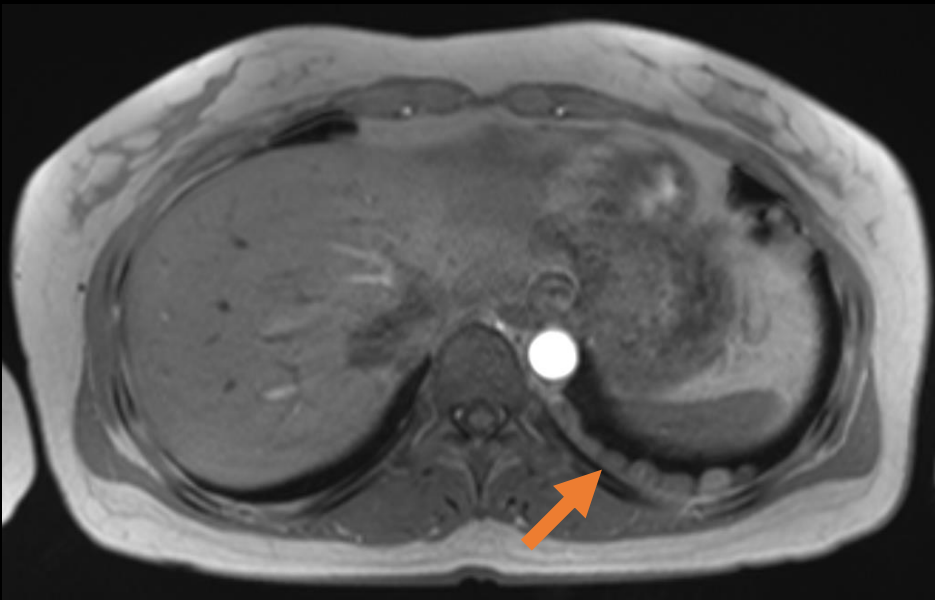
Chest contrast CT 2016.10.24



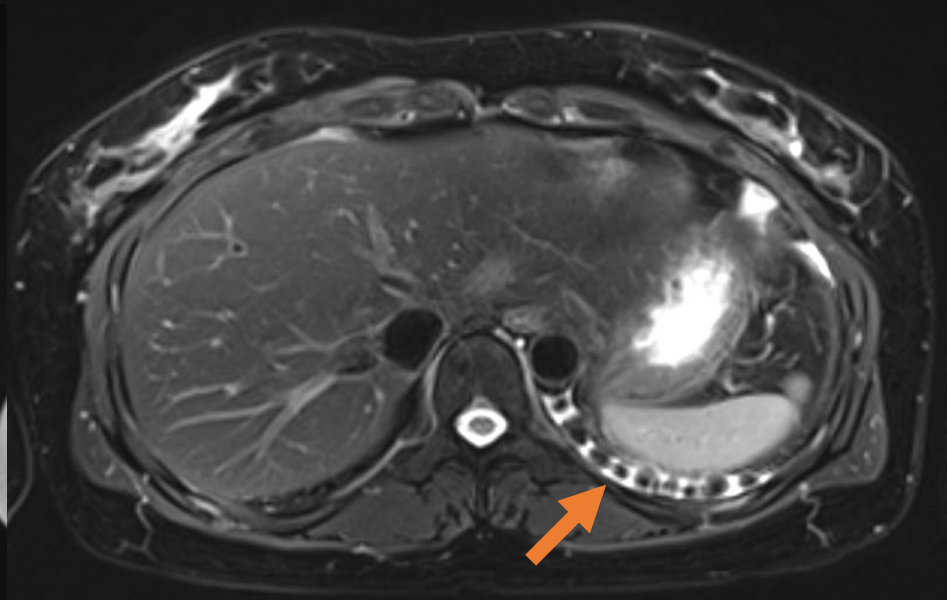
Chest contrast CT 2016.10.24



Chest MRI 2016.10.26

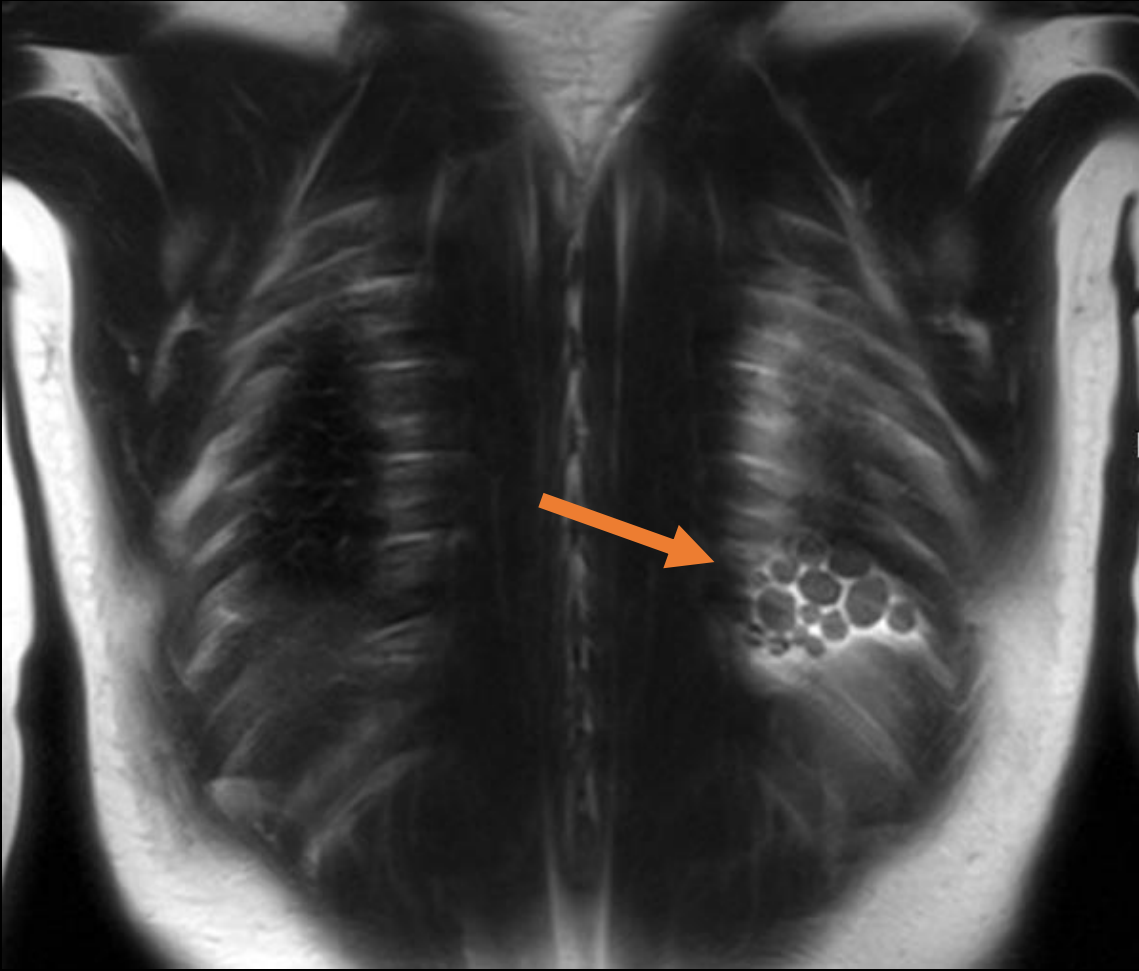


T1WI

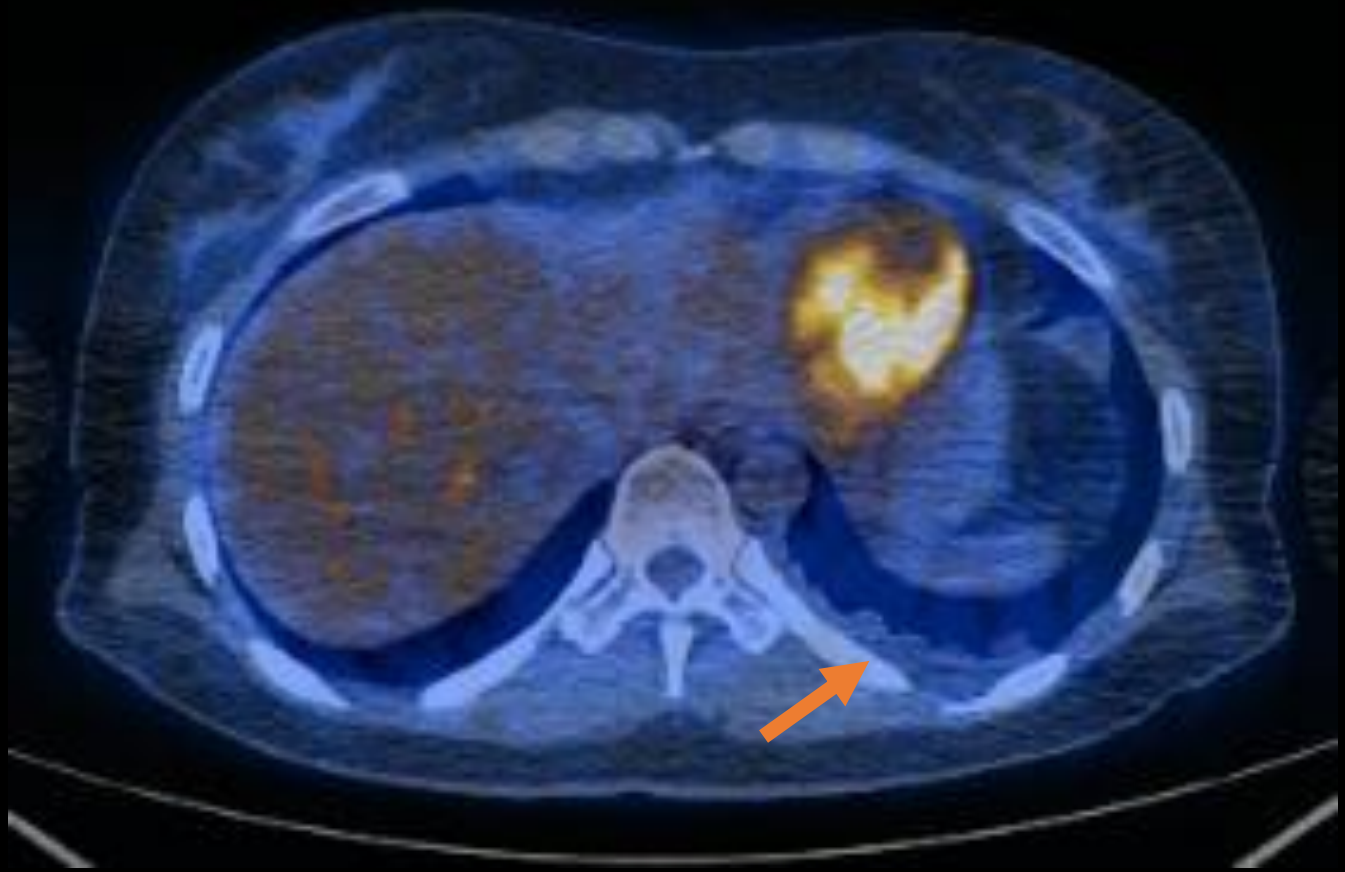


T2WI

Chest MRI 2016.10.26



PET-CT 2016.11.09



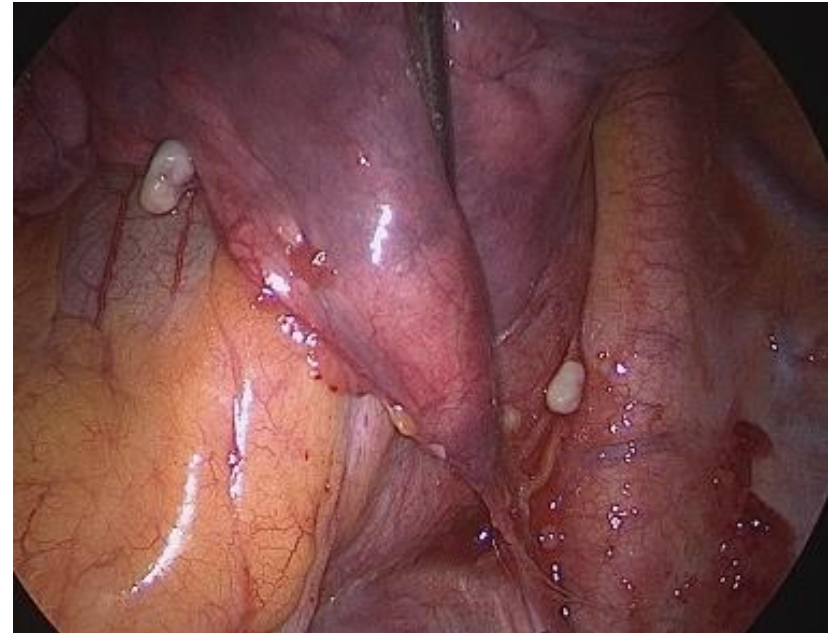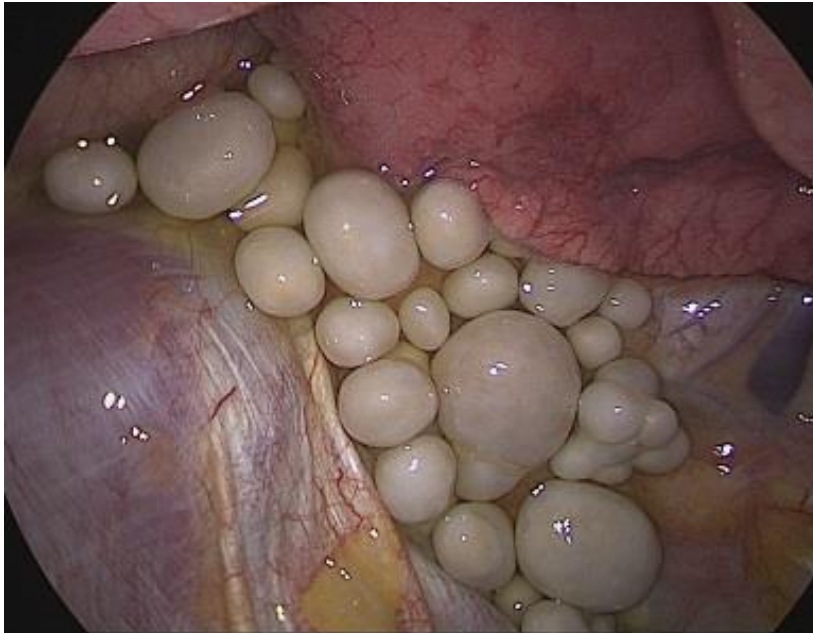
Assessment & Plan

- Pleural mass, Lt
 - R/O Lipomatosis
 - R/O Pleural fibroma
 - R/O Plexiform neurofibromatosis
 - R/O Mesothelioma


→ **VATS Pleural exploration**

Intra OP finding

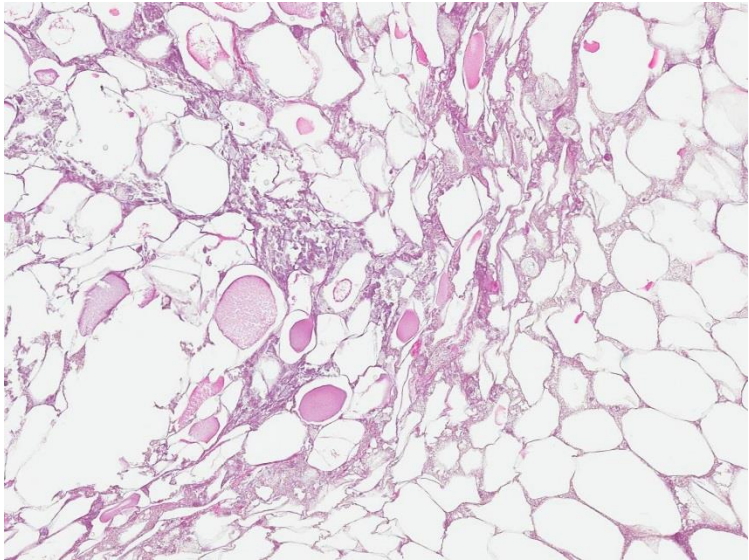
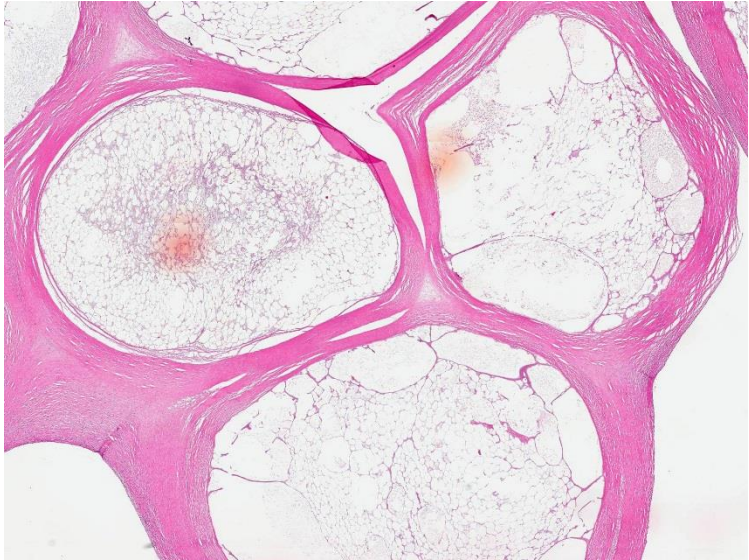
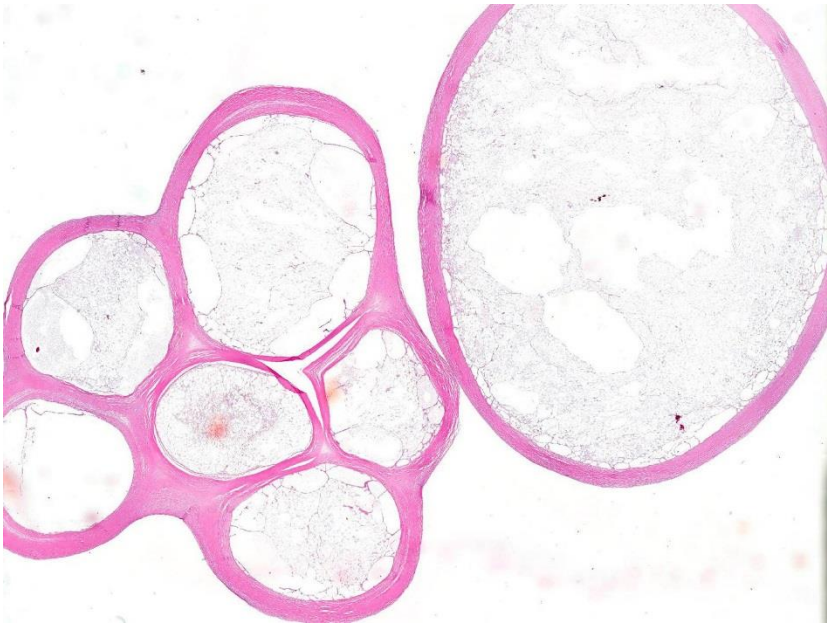
- VATS Pleural exploration 2016.12.15



Gross specimen



Histopathology



Diagnosis

- Thoracolithiasis
- Clinical course
 - Symptom free after removal of thoracolithiasis
 - F/U every year since → No evidence of recurrence

Discussion

Thoracolithiasis

- Very rare benign condition
- No age or sexual predilection
- Variable size with or without calcification
 - Fibrous tissue and a central core
 - Consisted of fatty tissue with or without necrosis
- Mobility on sequential imaging

Etiology

- Unclear but some hypothesis ...
 - Pericardial fat necrosis tearing off in the pleural cavity
 - Old tuberculous foci
 - Aggregation of macrophages phagocytizing dust

Role of thoracoscopy

- Lack of distinctive radiological findings
 - Non-calcified or enlarge at follow up
- Transthoracic or endobronchial biopsy
 - Often fails : hard consistency and mobility
- Thoracoscopy : minimally invasive and useful

**Thank you for
listening.**