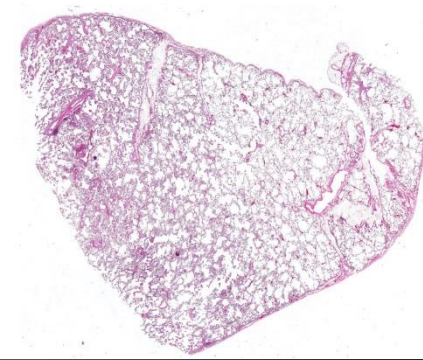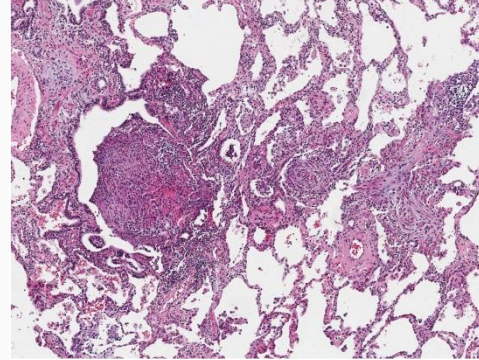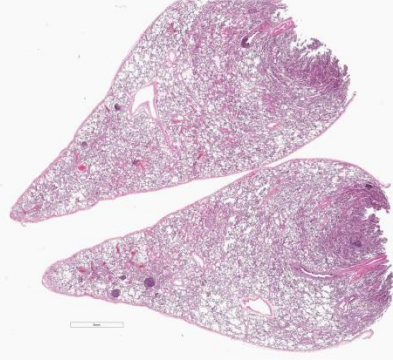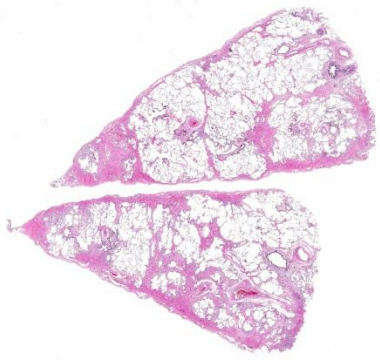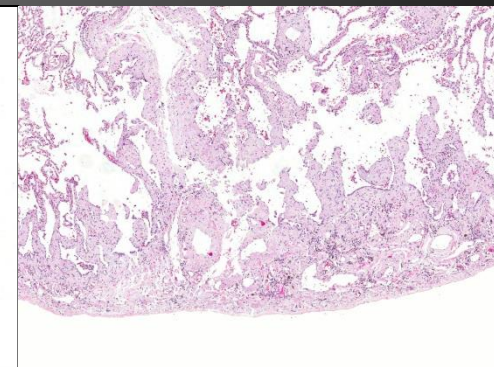
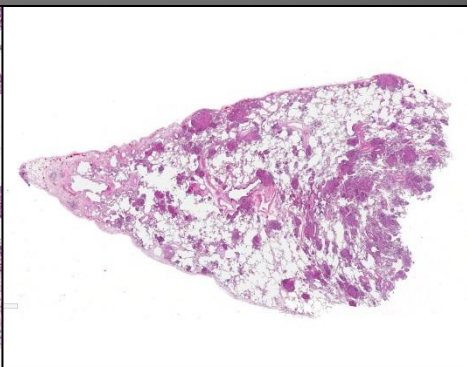
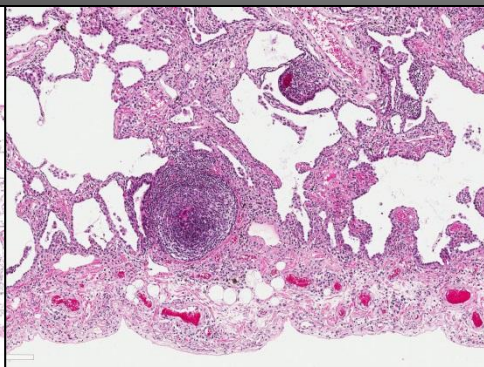
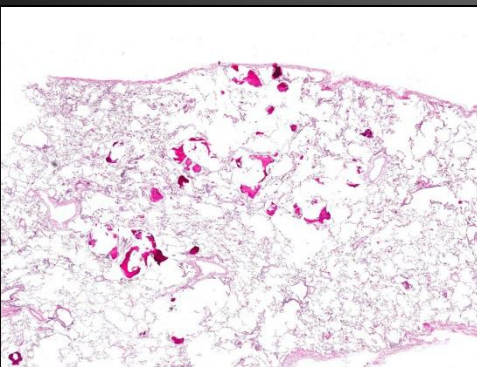


ILD School 2014

General Histopathological Approach to ILD

Joungho Han

Department of Pathology, Samsung Medical Center,
Sungkyunkwan University School of Medicine

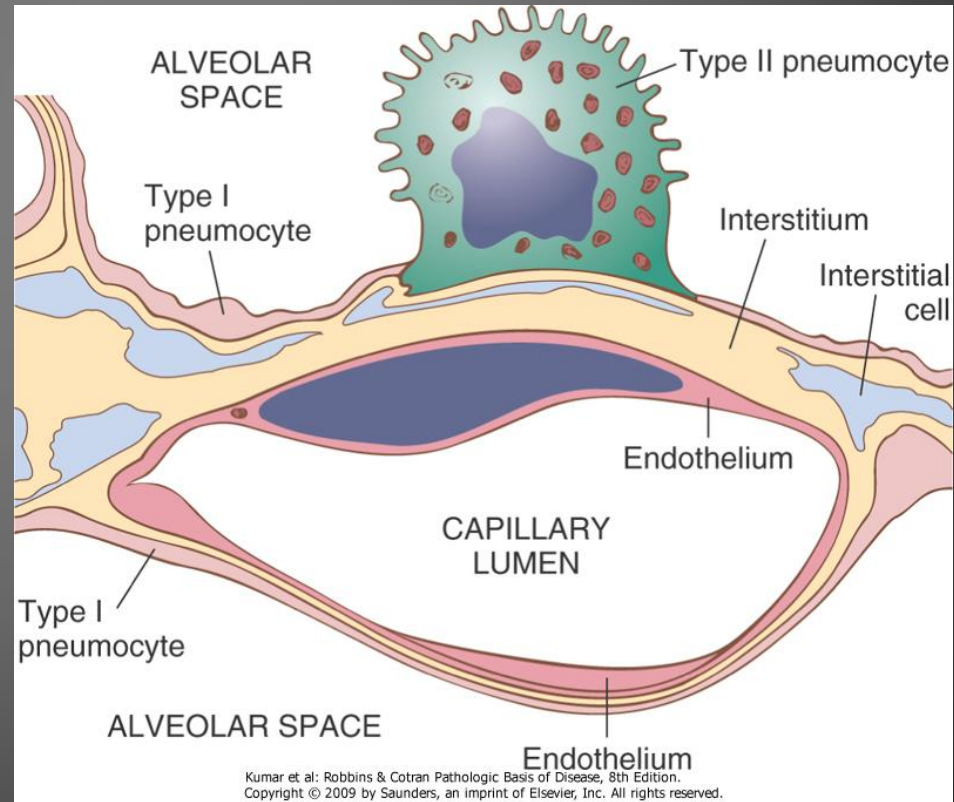
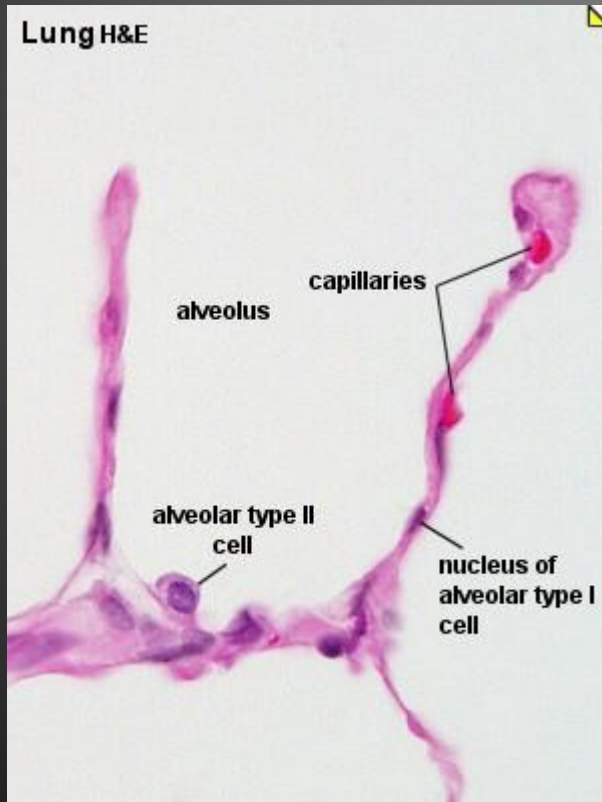


Definition:

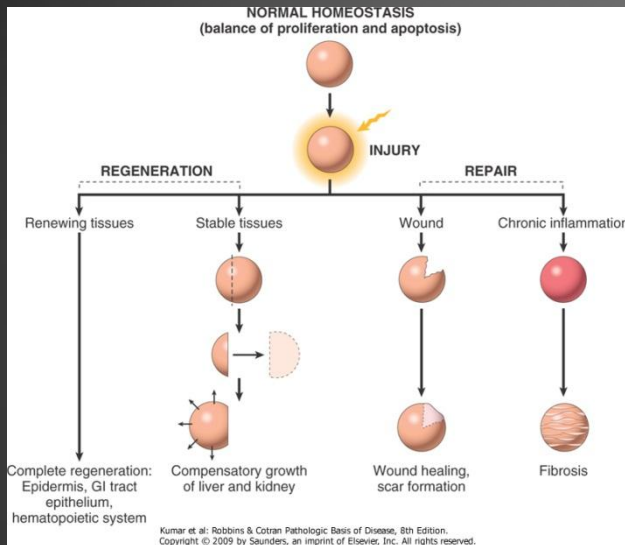
Interstice: a small interval, space, or gap in a tissue or structure

Pulmonary interstitium: space around the air sacs of the lungs (space between alveolar epithelium and endothelium of capillary)

Interstitial lung disease: refers to a group of lung diseases affecting the interstitium.



Tissue Renewal, Regeneration, and Repair



- Repair most often consists of a combination of regeneration and scar formation by the deposition of collagen.
- ECM components are essential for wound healing, because they provide the framework for cell migration, maintain the correct cell polarity for the re-assembly of multilayer structures, and participate in the formation of new blood vessels (angiogenesis).
- Cells in the ECM (fibroblasts, macrophages, and other cell types) produce growth factors, cytokines, and chemokines that are critical for regeneration and repair.

structural modifications of collagen fibers (cross-linking, increased fiber size)

Smoking-related

Acute IP

Idiopathic, Cryptogenic

Desquamative IP

Bronchiolitis Obliterans OP

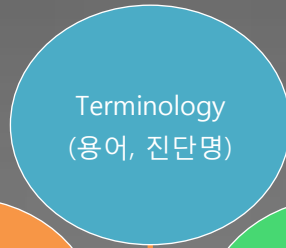Respiratory Bronchiolitis ILD

Nonspecific IP

Bronchiolar metaplasia

Usual IP

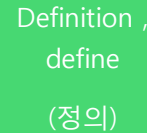
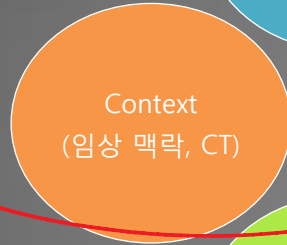Airway centered



Lymphoid follicles

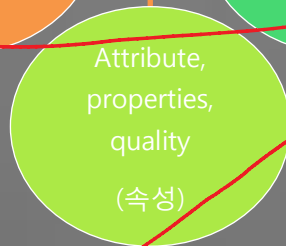Granulomatous

Amyloid



Asbestosis

Follicular bronchiolitis



Architectural distortion

Acute

Patchy

Subacute

Fibroblastic proliferation

Exacerbation

Variegated

Chronic

Fibroblastic foci

Fibroblastic plugs

Uniform

fibrosis

Proteinaceous exudates

Regional

End-Stage fibrosis, honeycombing

Heterogeneous

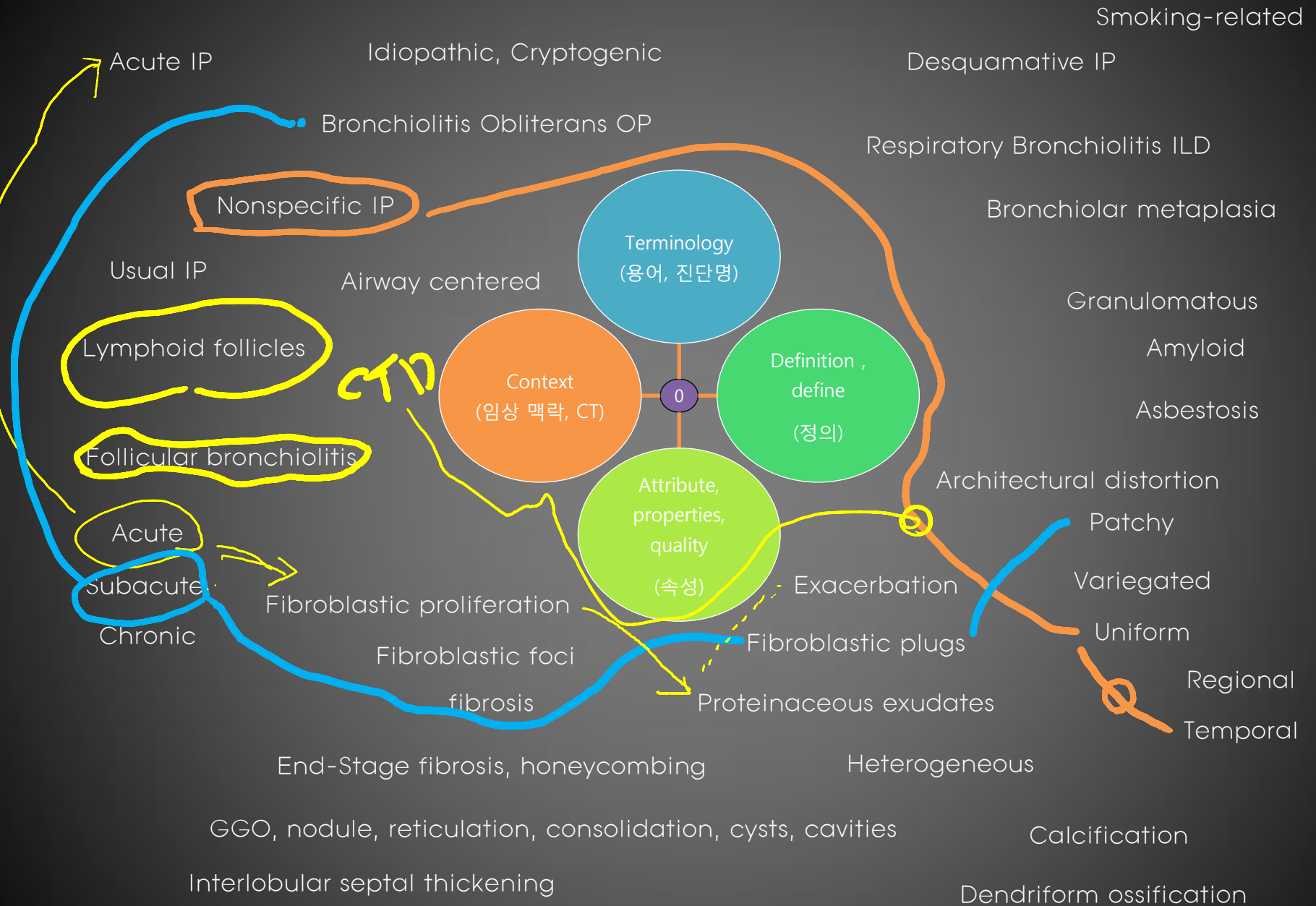
Temporal

GGO, nodule, reticulation, consolidation, cysts, cavities

Calcification

Interlobular septal thickening

Dendriform ossification



Smoking-related

Acute IP

Idiopathic, Cryptogenic

Desquamative IP

Bronchiolitis Obliterans OP

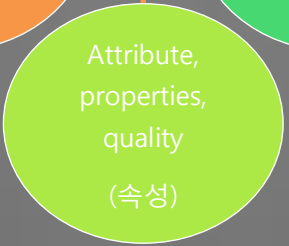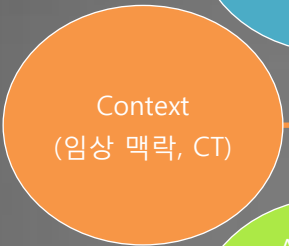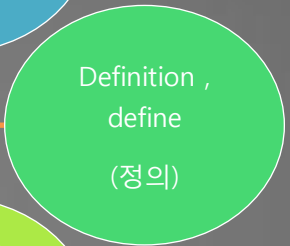
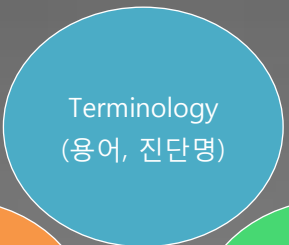Respiratory Bronchiolitis ILD

Nonspecific IP

Bronchiolar metaplasia

Usual IP

Airway centered



- Granulomatous
- Amyloid
- Asbestosis

Lymphoid follicles

Follicular bronchiolitis

Architectural distortion

Acute

Patchy

Subacute

Fibroblastic proliferation

Exacerbation

Variegated

Chronic

Fibroblastic foci

Fibroblastic plugs

Uniform

fibrosis

Proteinaceous exudates

Regional

End-Stage fibrosis, honeycombing

Heterogeneous

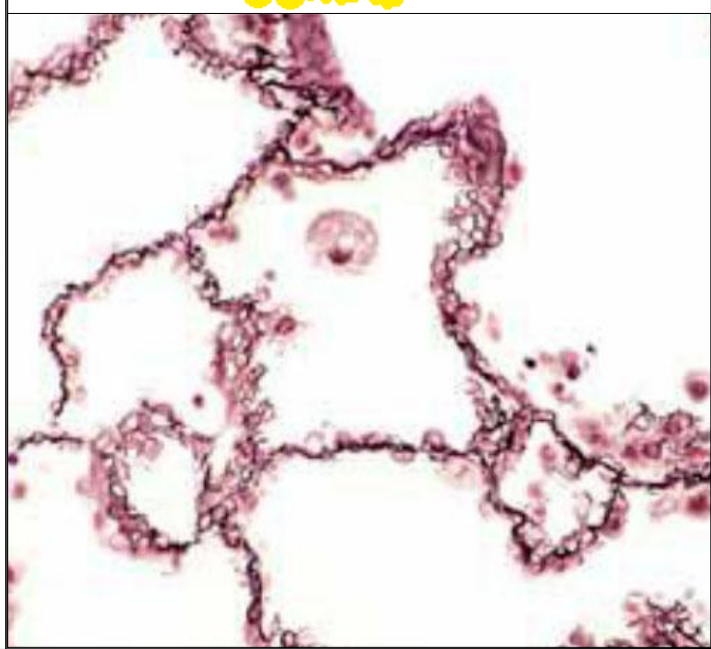
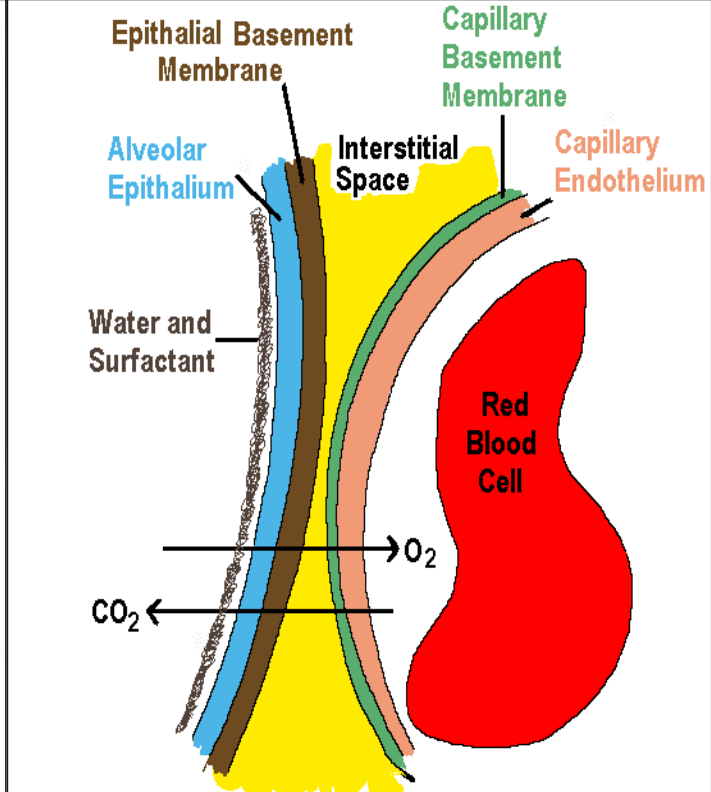
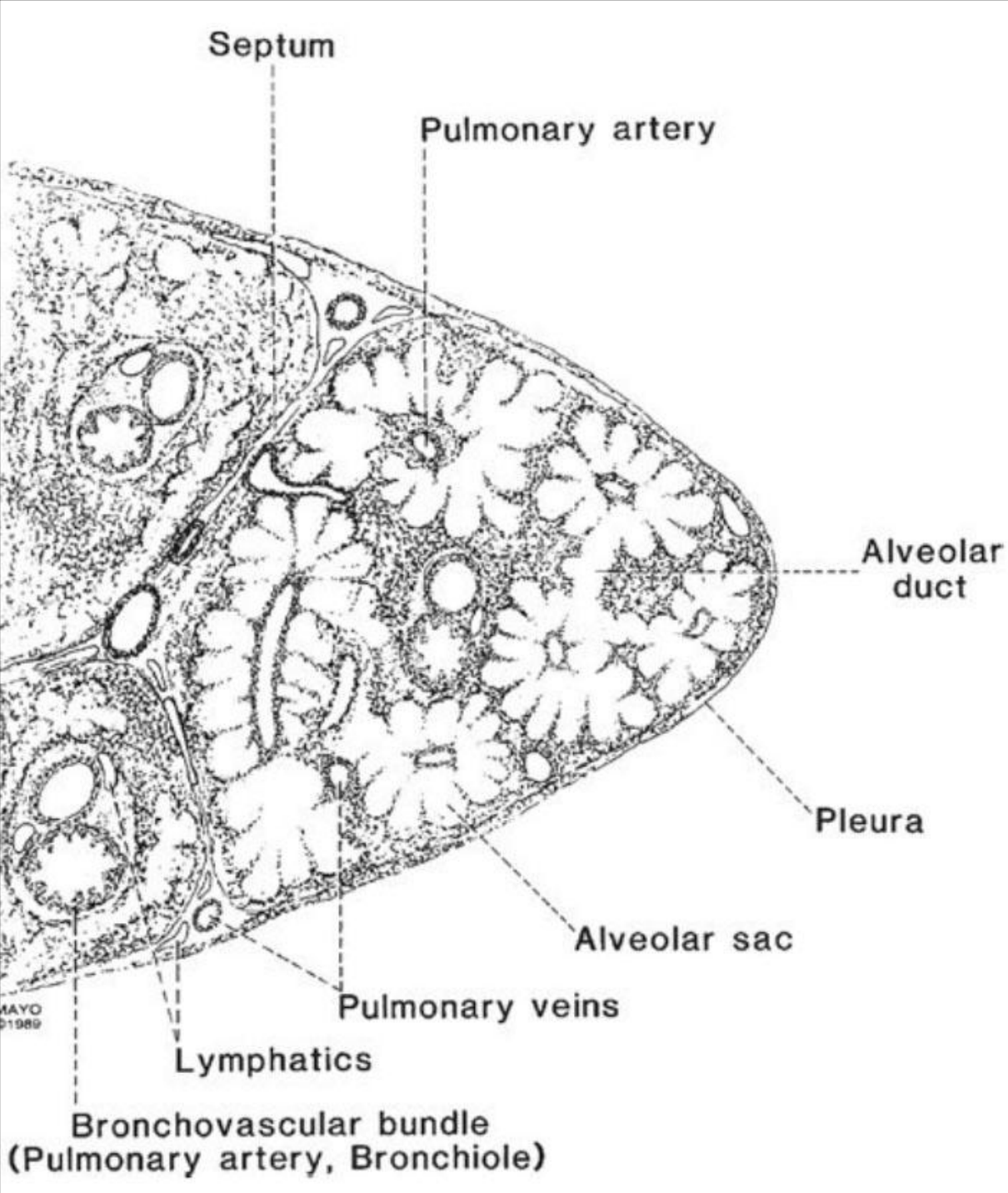
Temporal

GGO, nodule, reticulation, consolidation, cysts, cavities

• Calcification

Interlobular septal thickening

• Dendriform ossification



Site for Biopsy;

Diffuse ILD:

- Multiple lobes
- Moderately abnormal parenchyme while avoiding areas of end-stage scarring or honeycomb change (CT can be useful.)
- Inappropriate for biopsy site; tip of any lobe and lingula

Patchy lung disease:

- Most abnormal zone



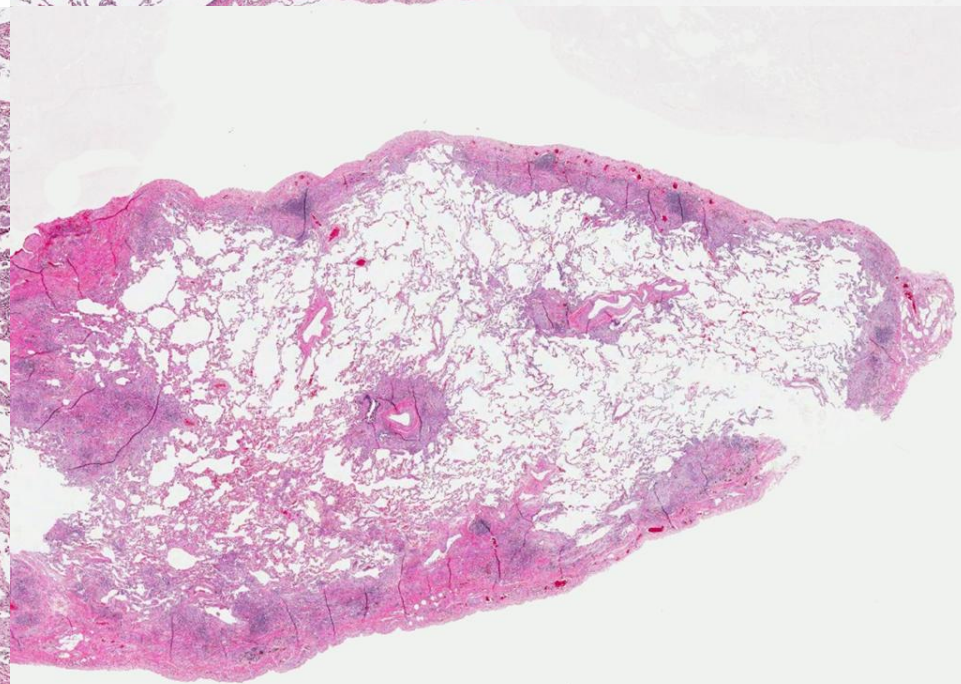
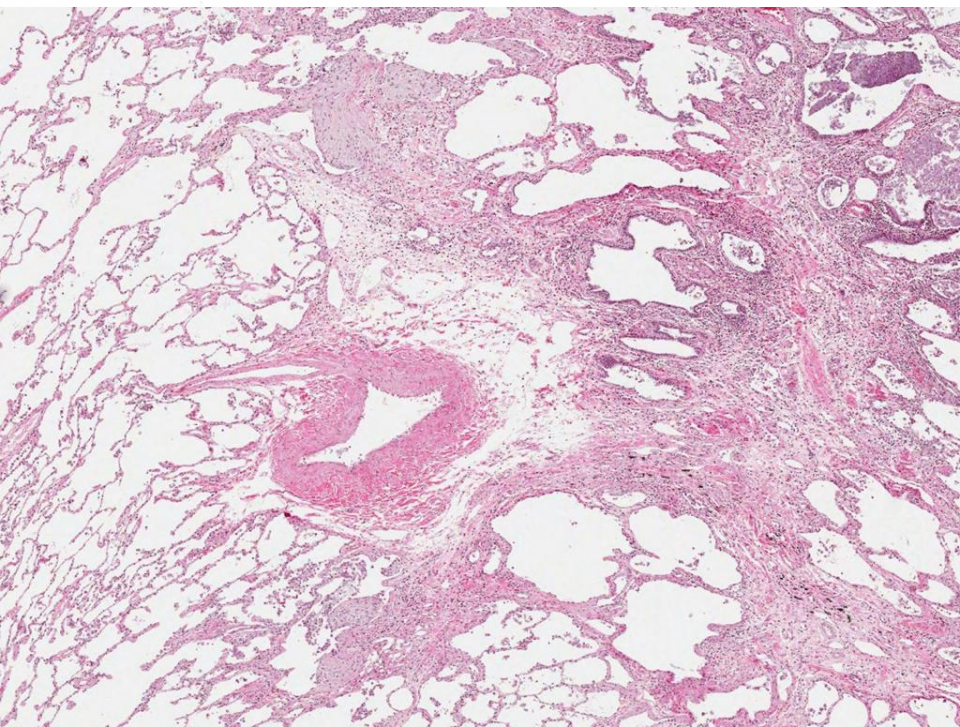
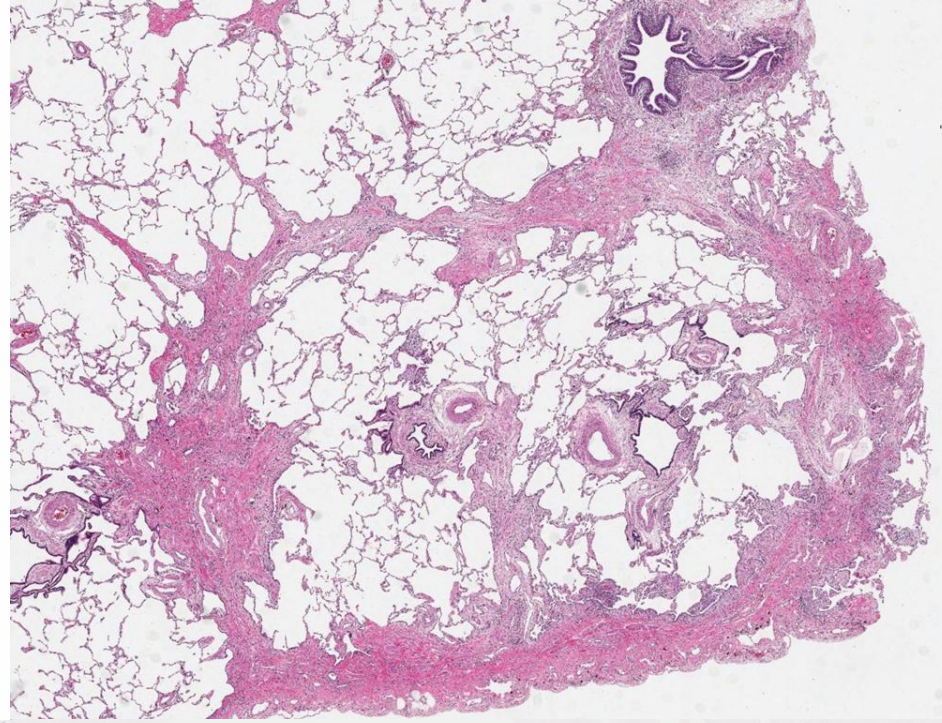
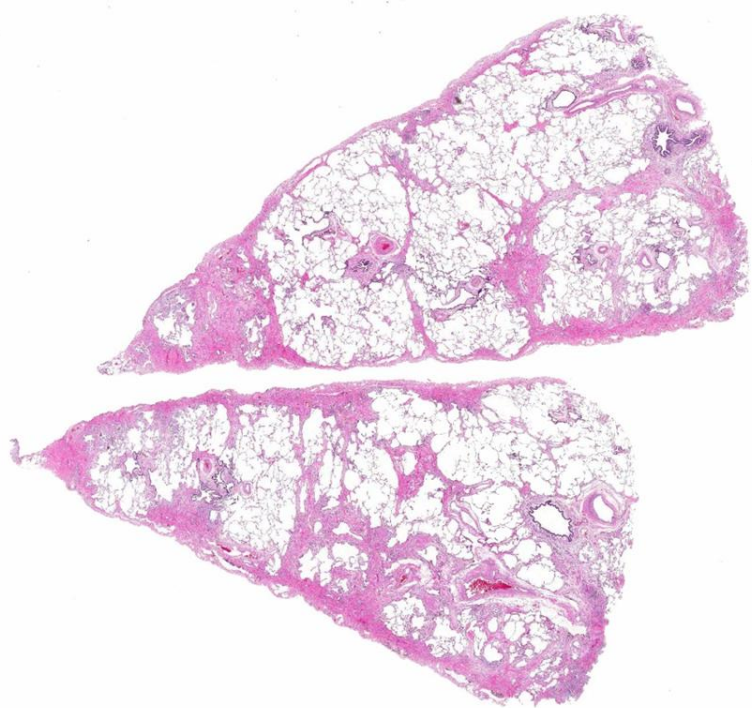
Tissue inflated for 1 to 2 hours with formalin

Usual, Fibroblastic foci, Subpleural and/or paraseptal,
Temporally heterogeneous, Dense scarring and
honeycombing, Alternating areas of normal lung, Airway-
centered

Fibroblastic foci consists of a loose type fibrosis, containing myofibroblasts
with in stroma, having few collagen fiber at the edges of dense scar
Temporally heterogeneous; fibroblastic foci and dense fibrosis →
remodeling of the lung architecture → formation of cystic spaces or
honeycombing



UIP pattern



Nonspecific, Temporally uniform, homogeneous

Cellular and Fibrosing pattern

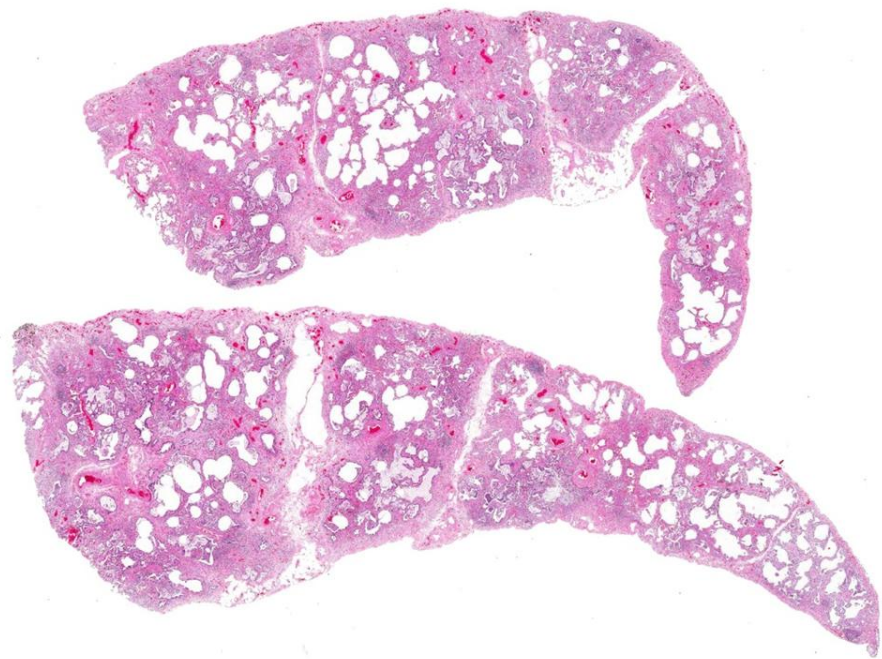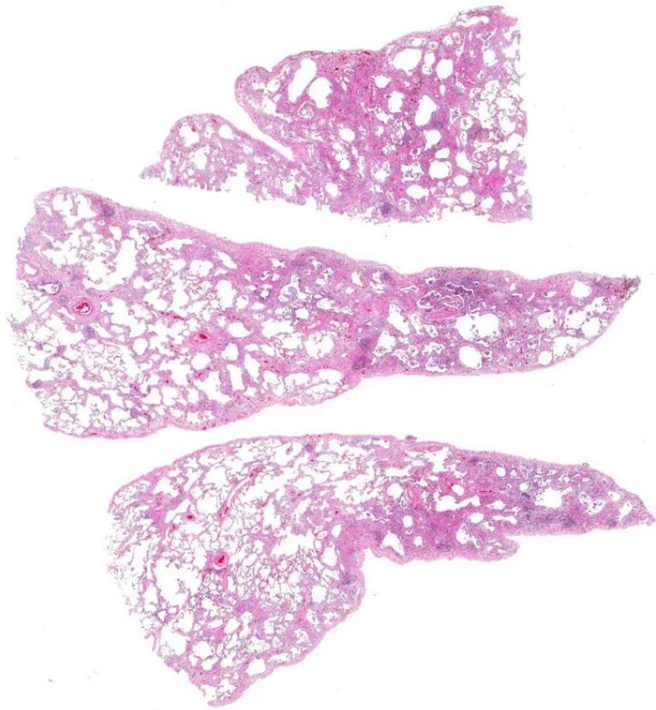
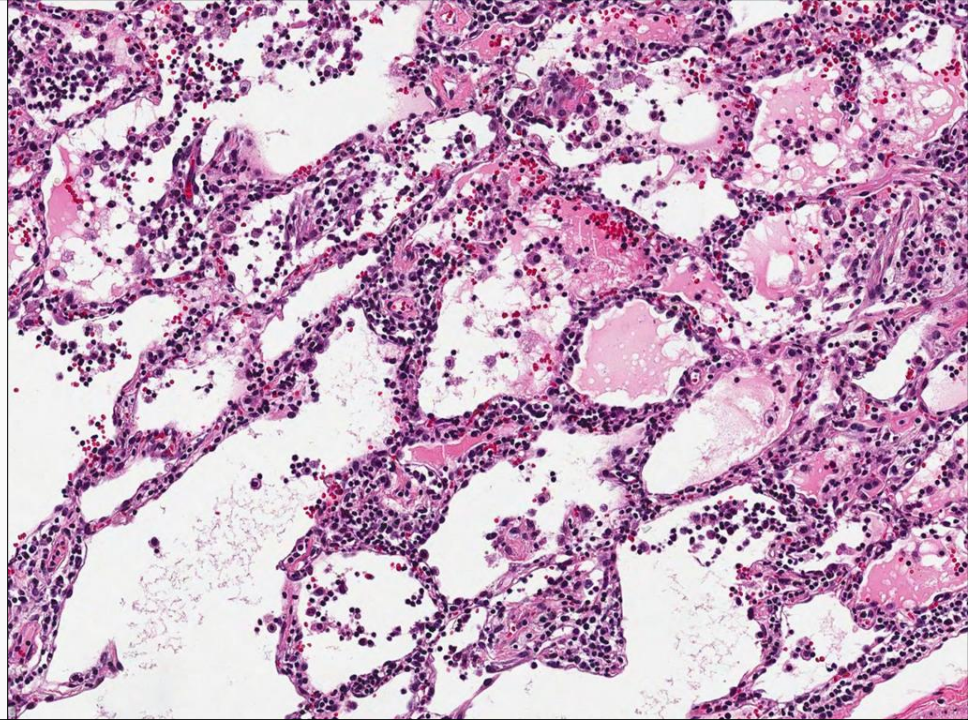
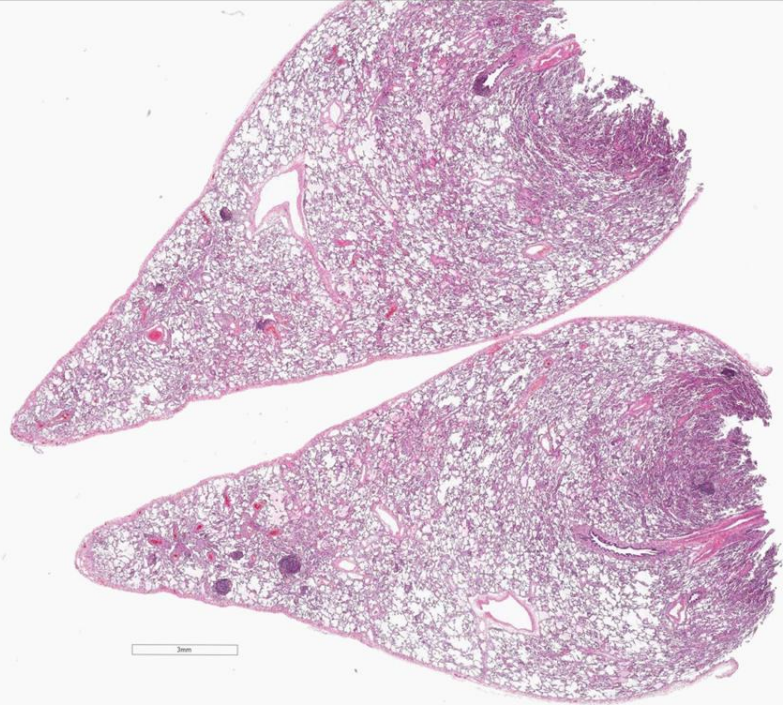
Lung architecture, often preserved

Lacking the temporal heterogeneity and patchy feature

Negative findings: fibroblastic foci, airway centricity, granuloma, eosinophils



NSIP pattern



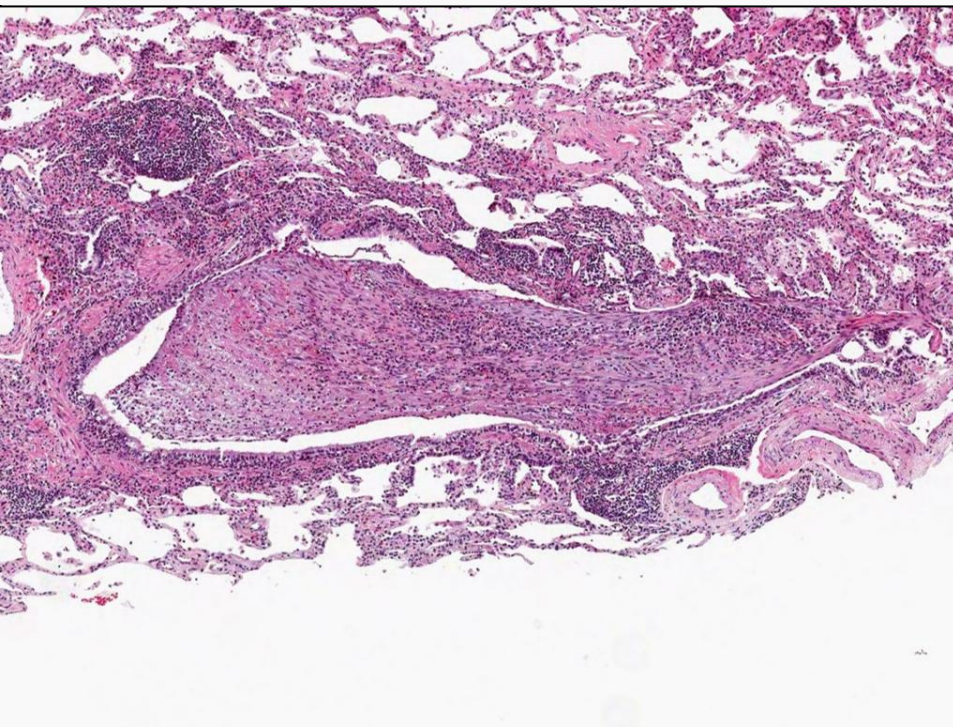
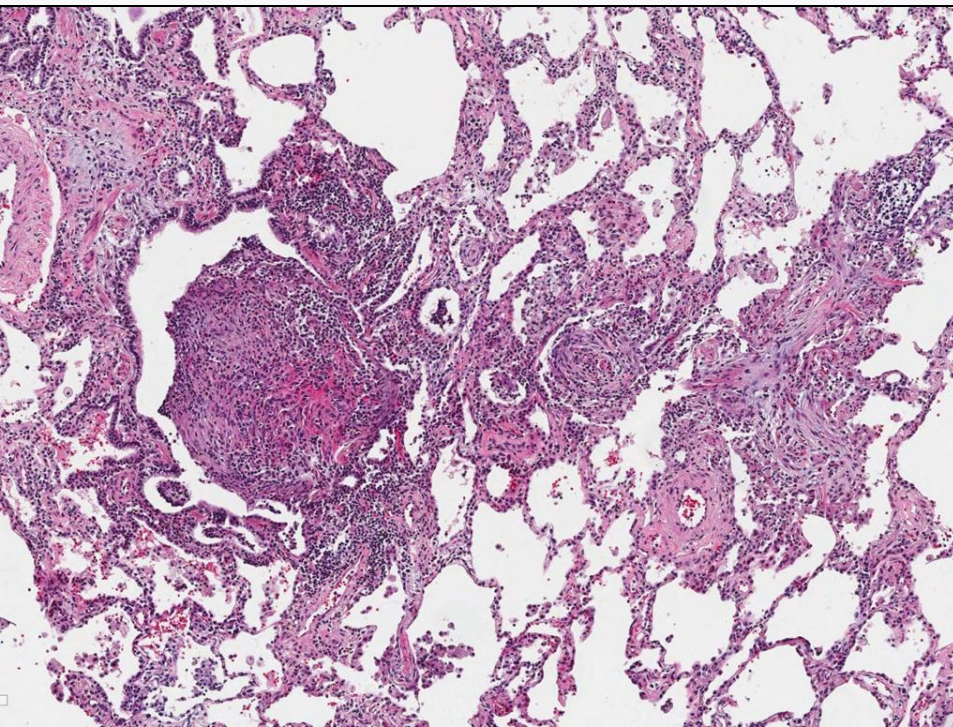
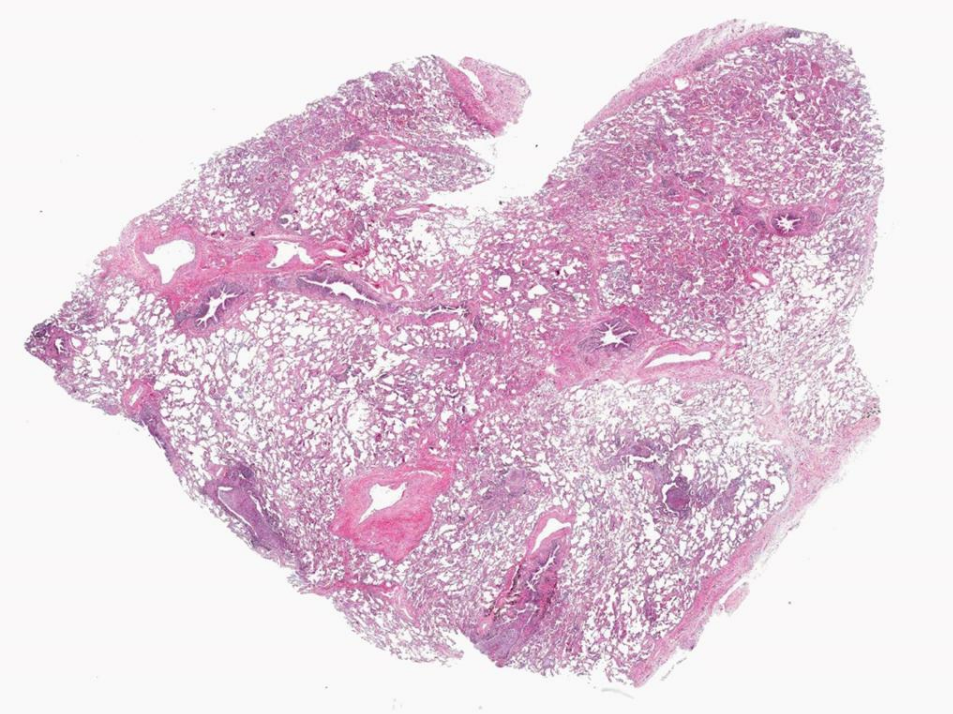
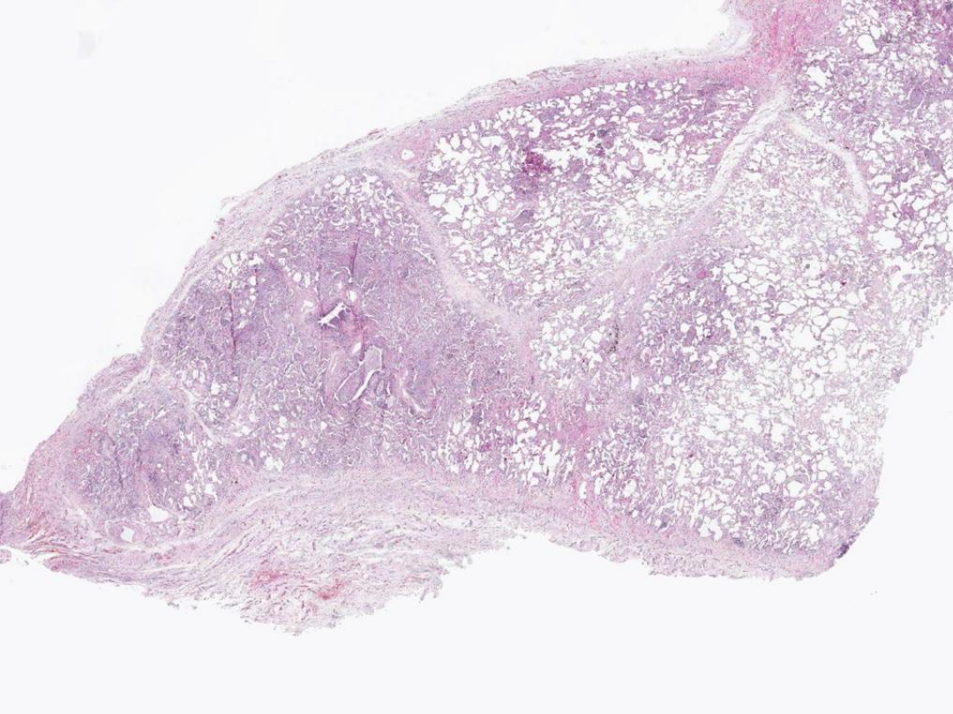
Excessive proliferation of granulation tissue within small airways and alveolar duct, patchy, temporal uniform, subacute

Preservation of lung architecture

Negative findings: interstitial fibrosis, granuloma, Eosinophils, necrosis, neutrophils (abscess), hyaline membranes, vasculitis



COP pattern



Acute, edema, hyaline membrane, endothelial injury,
myofibroblastic proliferation, temporally uniform

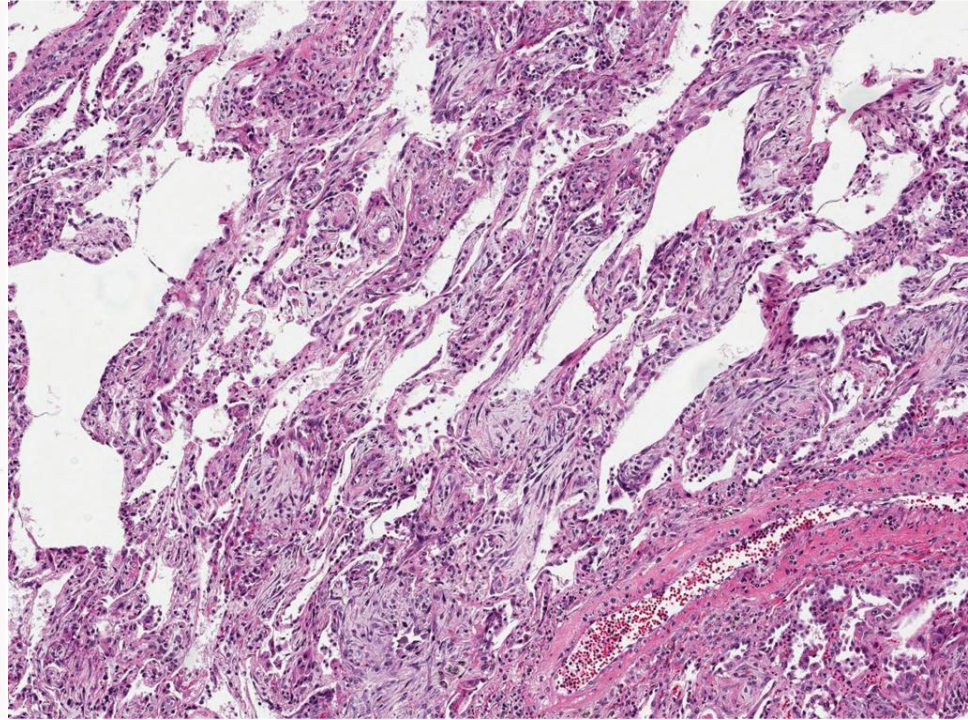
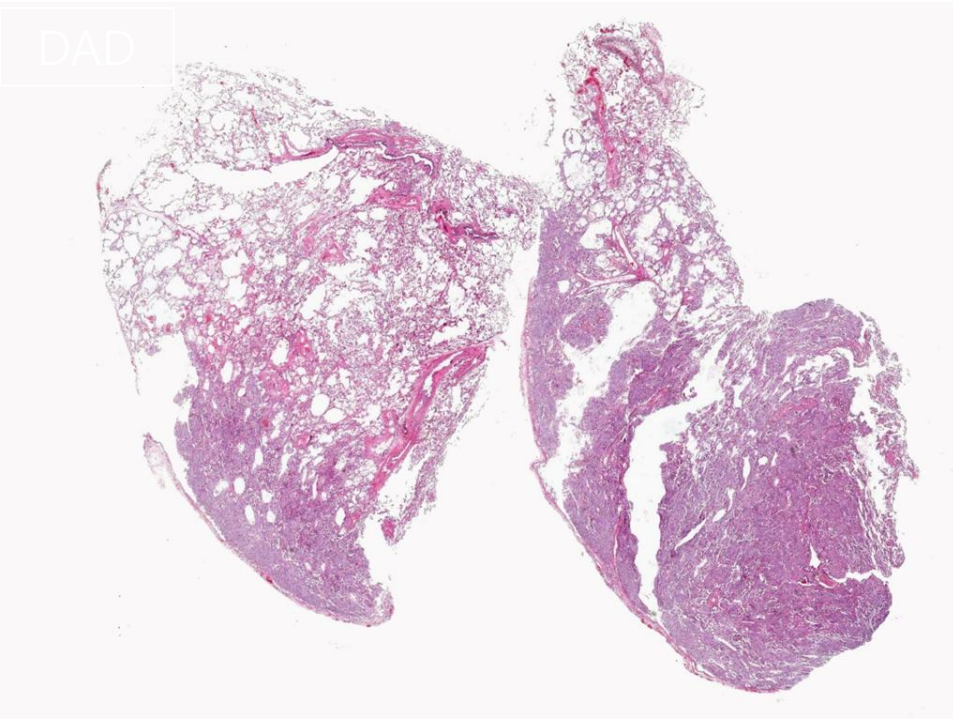
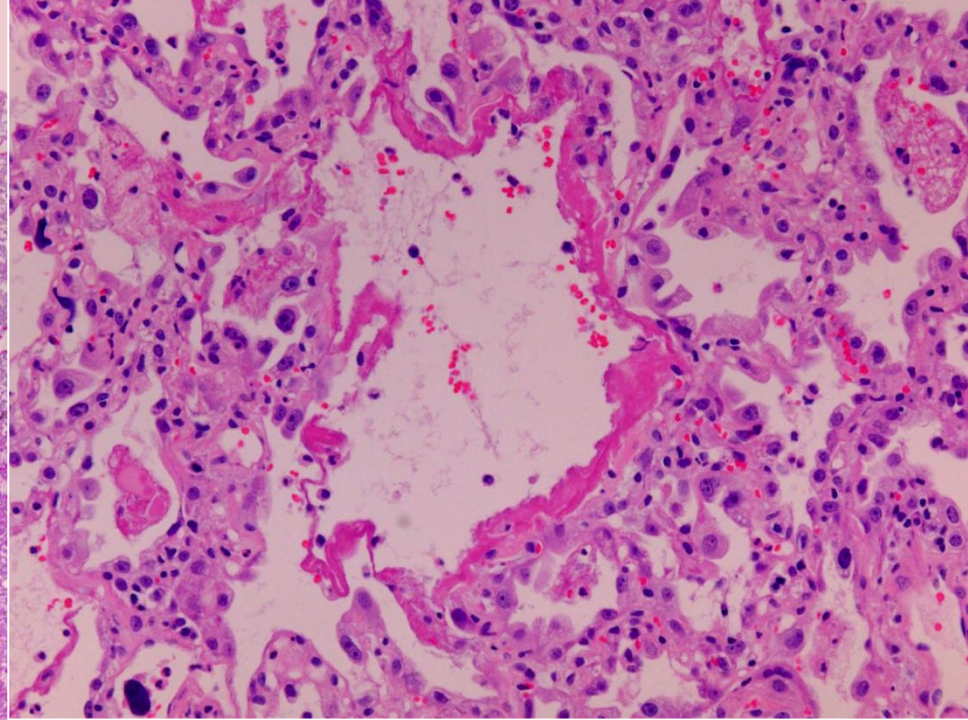
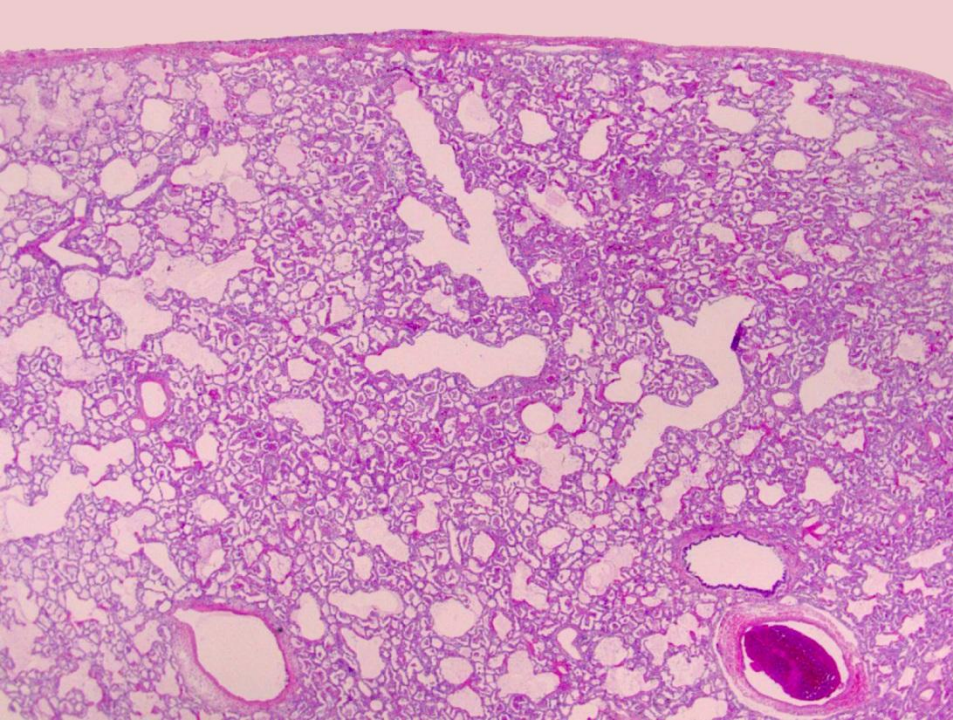
Preservation of lung architecture

Exudative (acute), proliferative (organizing), and fibrotic (chronic) phase

Negative findings: patchy lesion, heterogeneous



DAD pattern



Pigmented macrophages accumulate in RB and alveolar spaces, cigarette smoker



RB pattern



+
mild chronic inflammation
with interstitial fibrosis
extending along the
surrounding alveolar wall

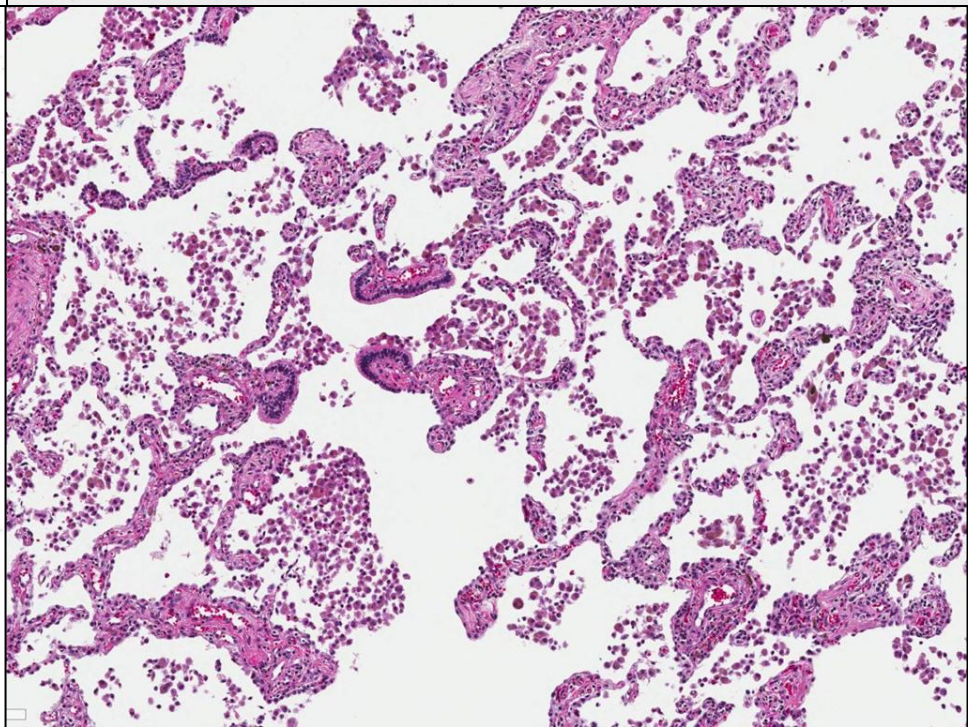
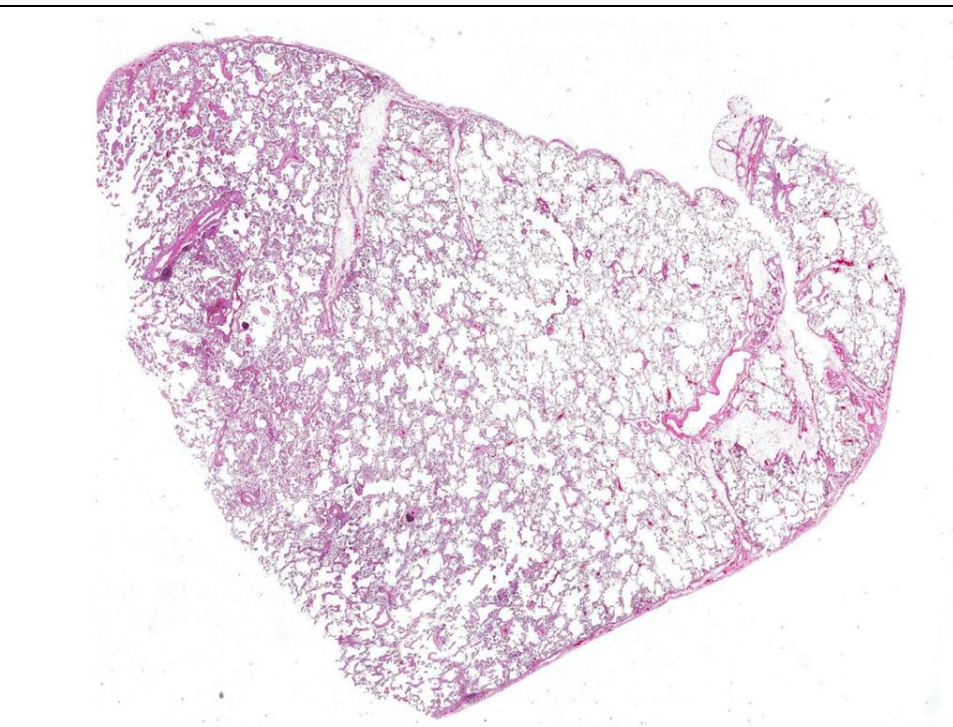
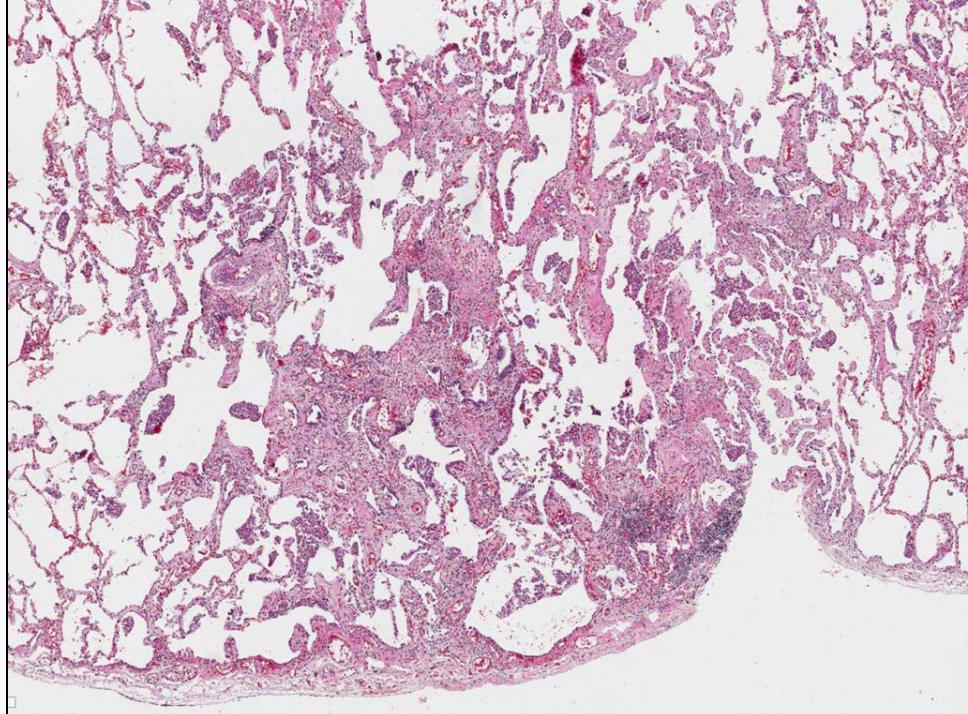
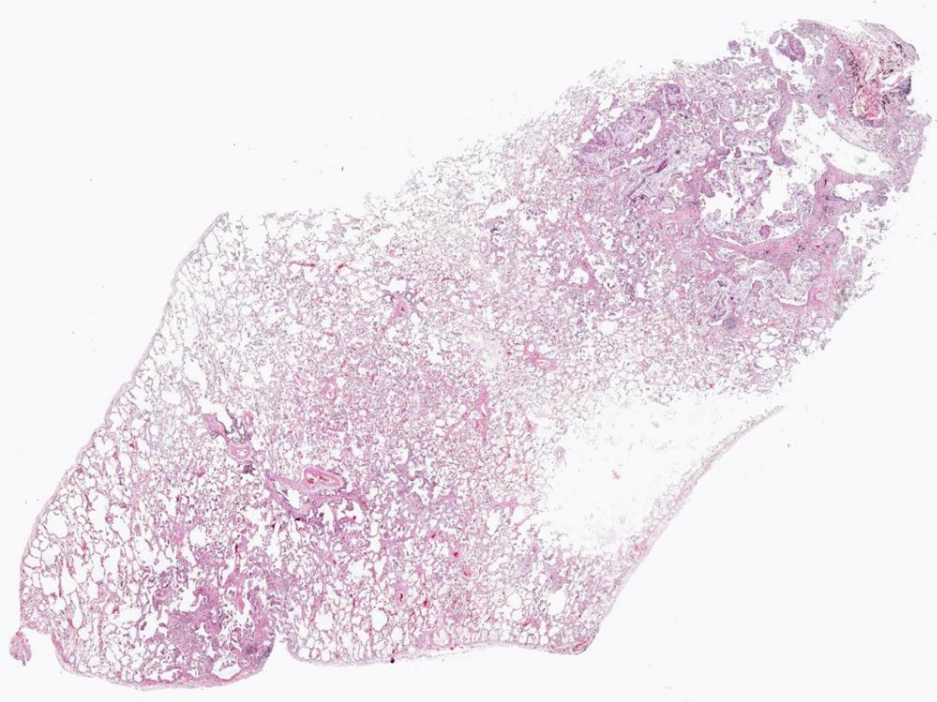
+
Diffuse, marked, little fibrosis
or inflammation



RB-ILD



DIP



Lymphoid follicles, follicular bronchiolitis, diffuse lymphocytic infiltration, NSIP pattern

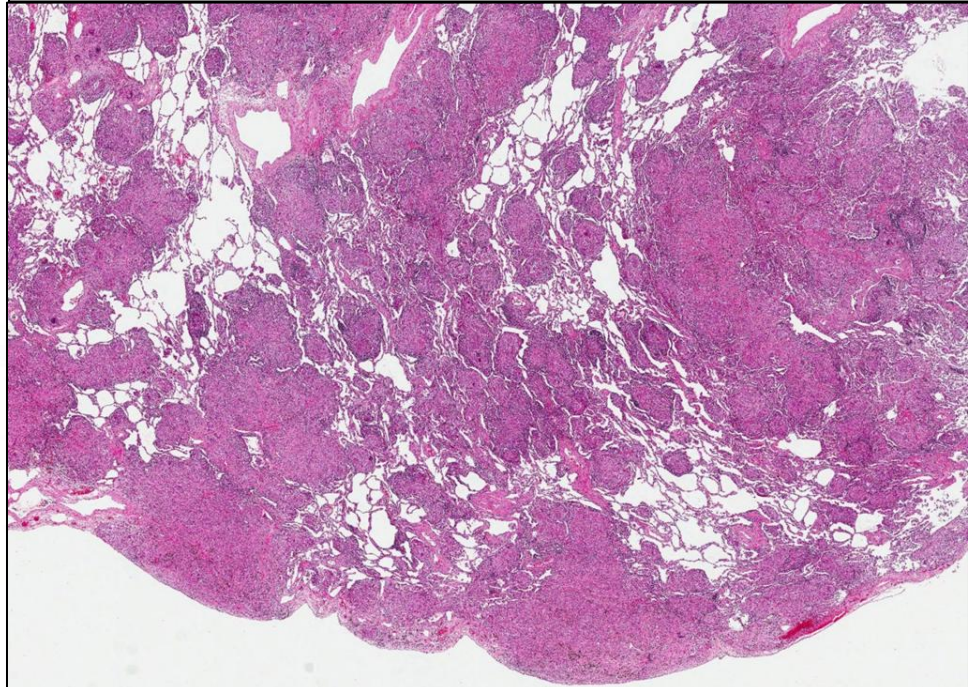
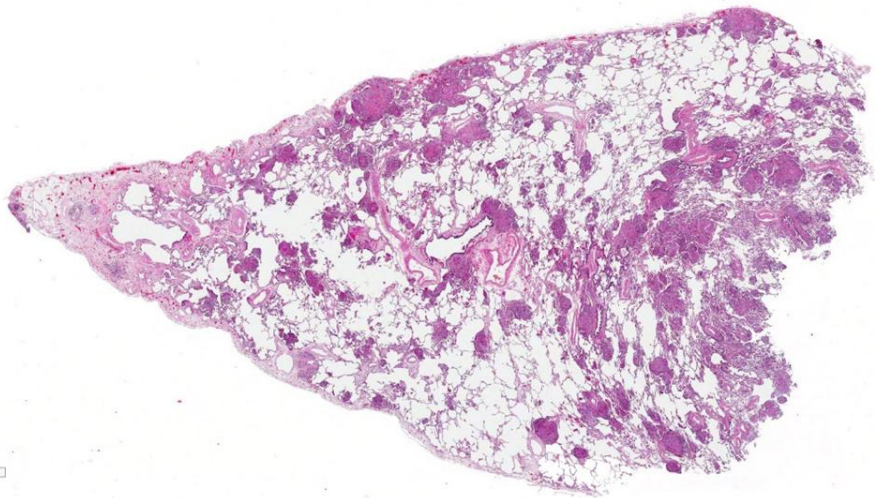
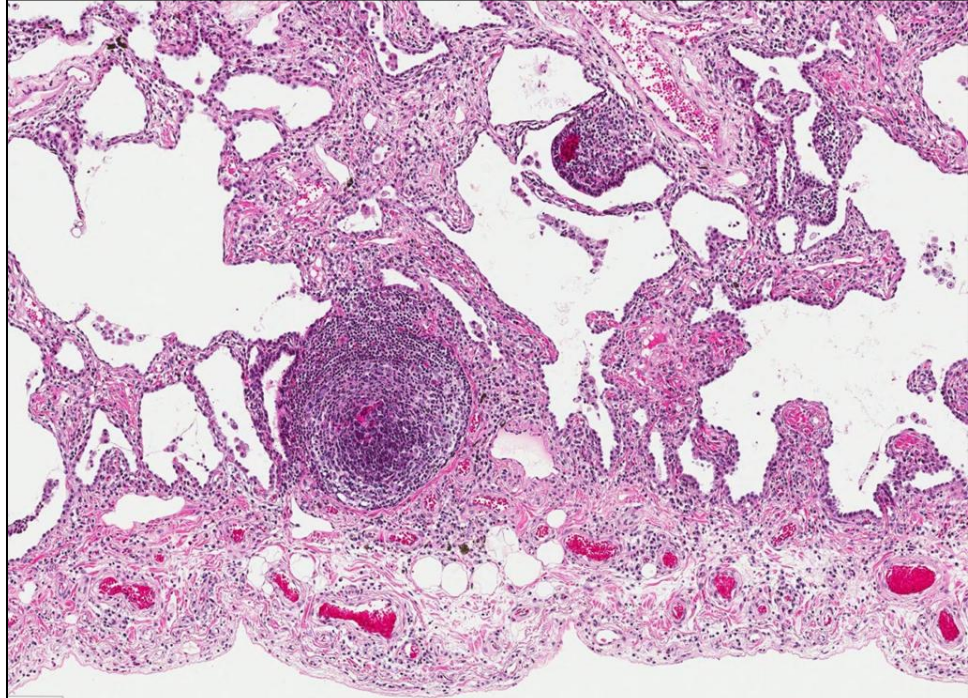
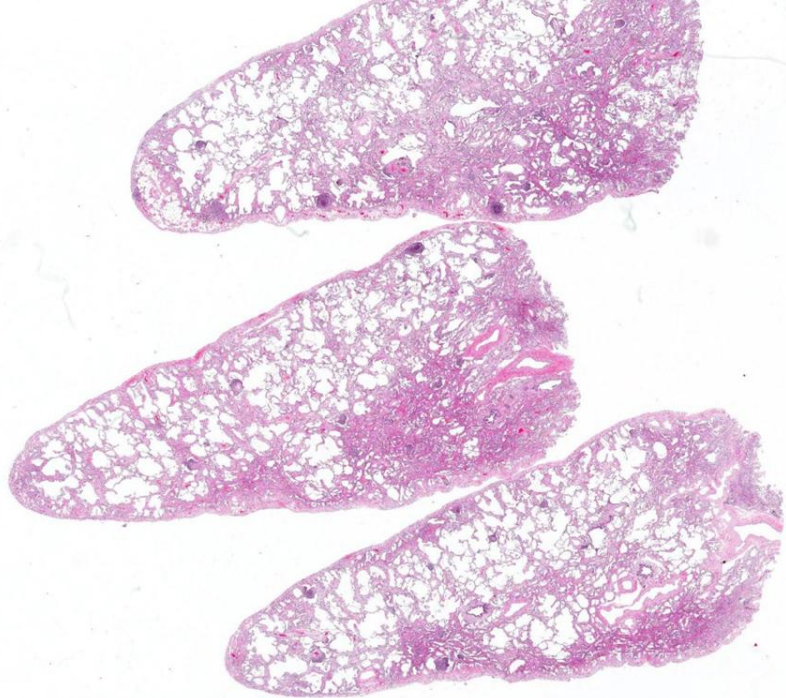


R/O CTD

Granuloma, noncaseating, concentric fibrosis, pleura and bronchovascular distribution



Sarcoidosis



Diffuse, homogeneous

+

Amylod → Amyloidosis

Calcification → diffuse metastatic calcification

Ossification → dendriform ossification

Lymphocytes → LIP, lymphoma, Cellular NSIP

Plasma cells → IgG4 disease

Macrophages → Sinus histiocytosis or other histiocytic disorder

Hemosiderin-laden macrophages and fibrosis → hemochromatosis

Smooth muscle and cysts → LAM

Patchy, focal

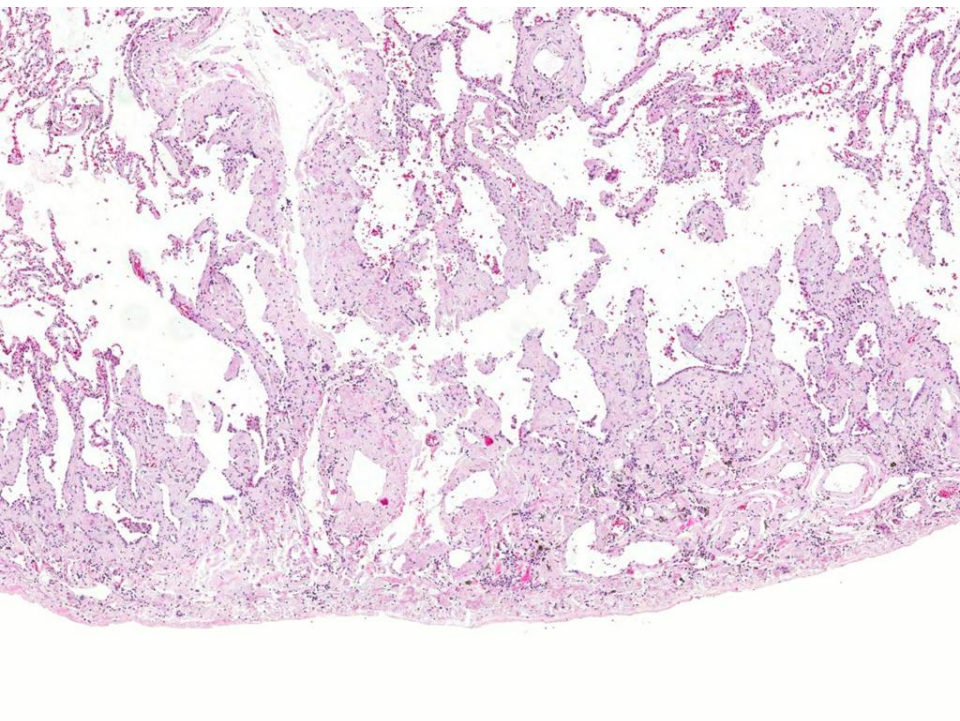
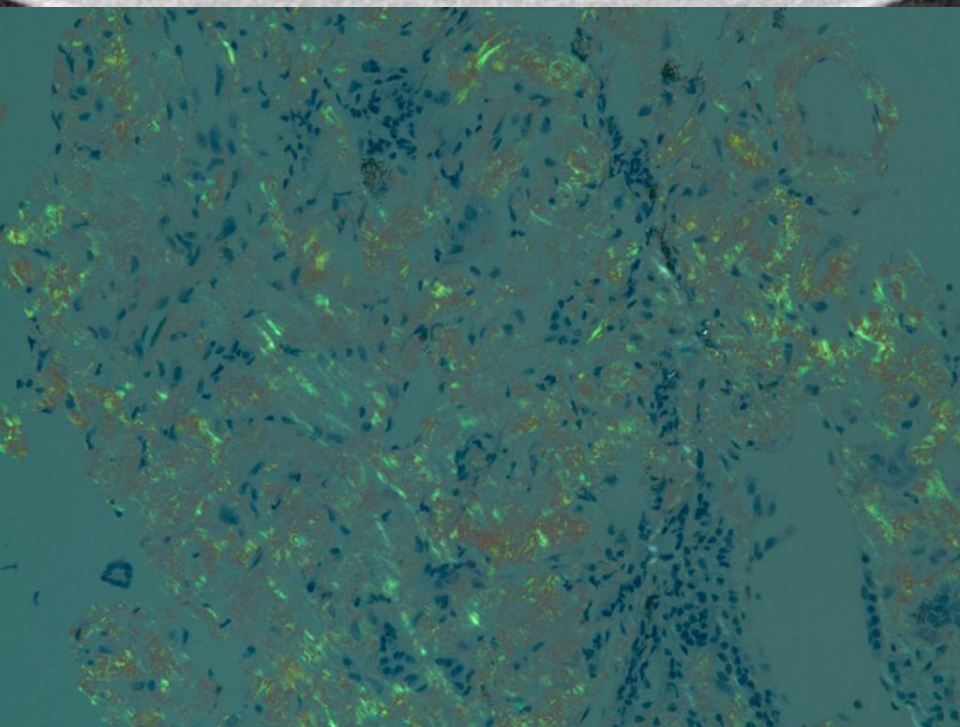
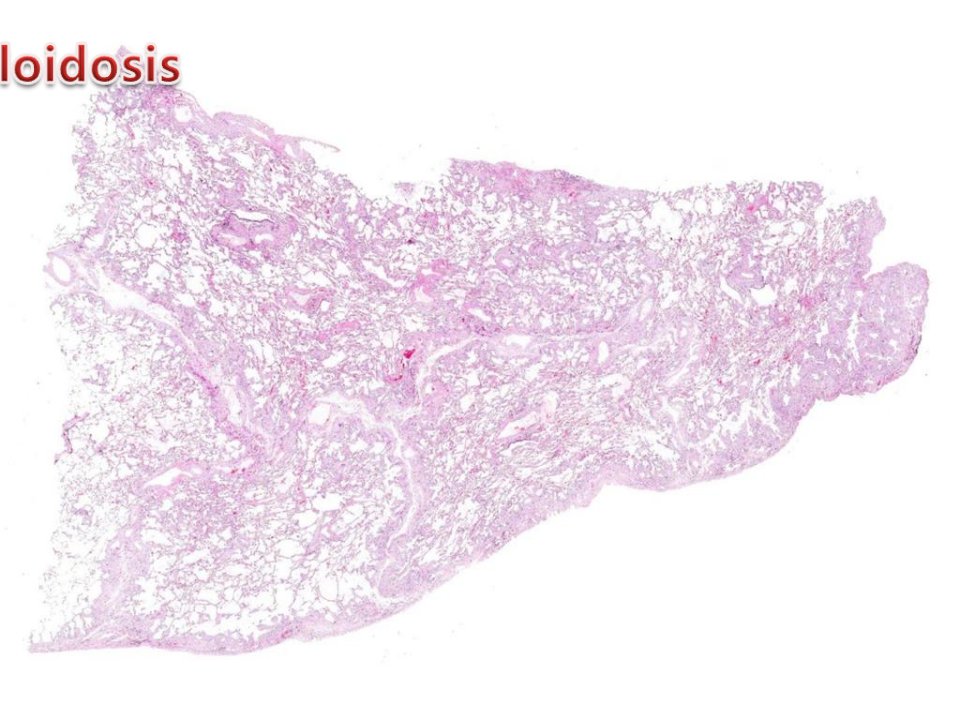
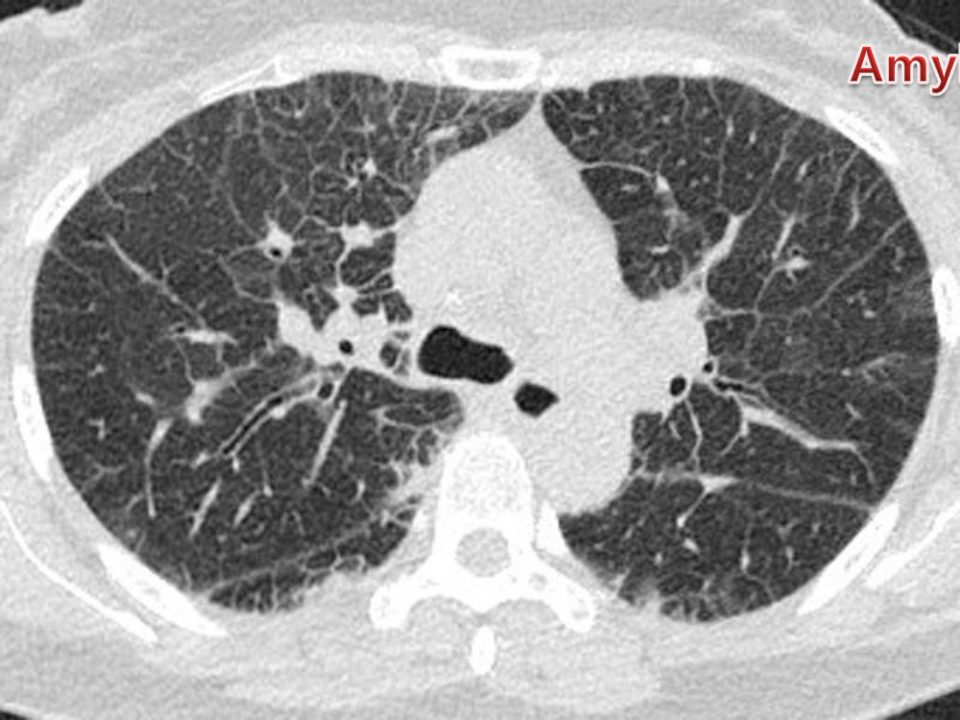
+

Poorly formed granulomas, peribronchiolar CI, allergic → HP

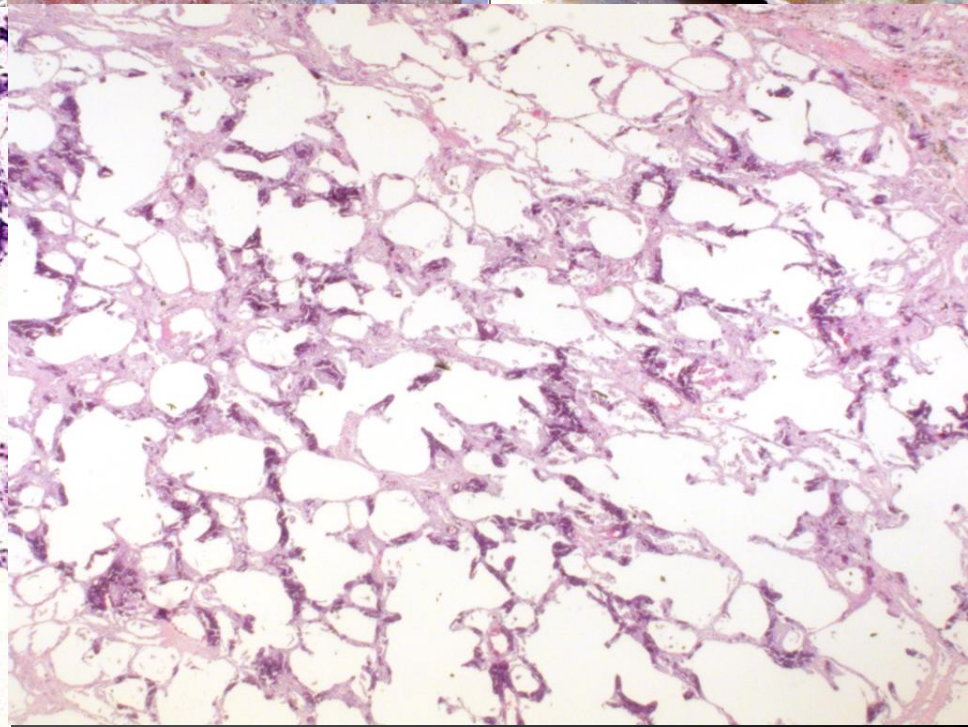
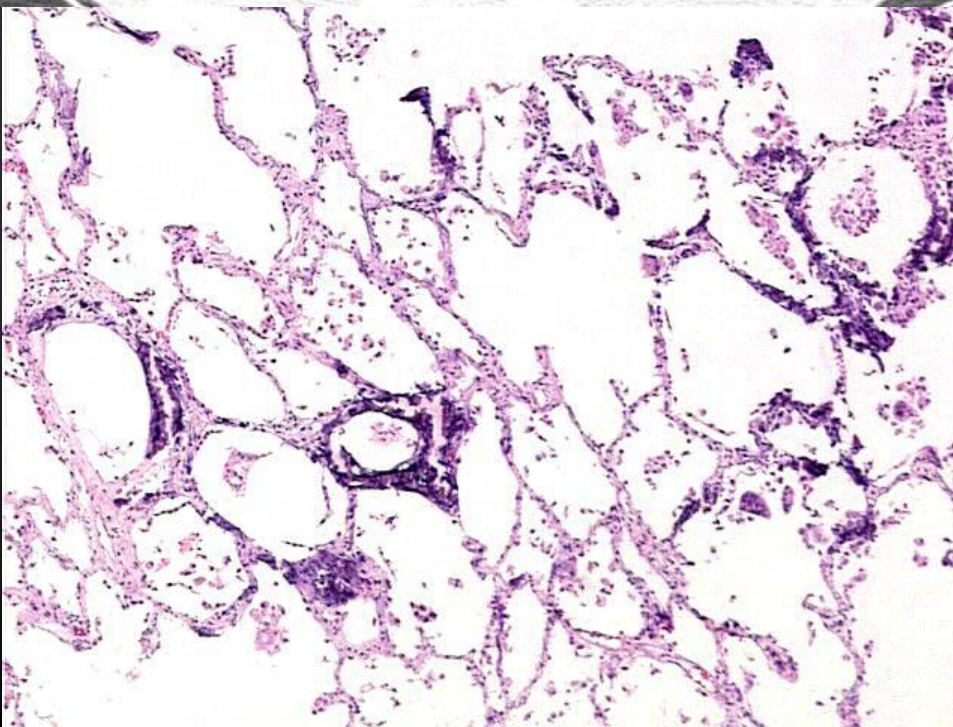
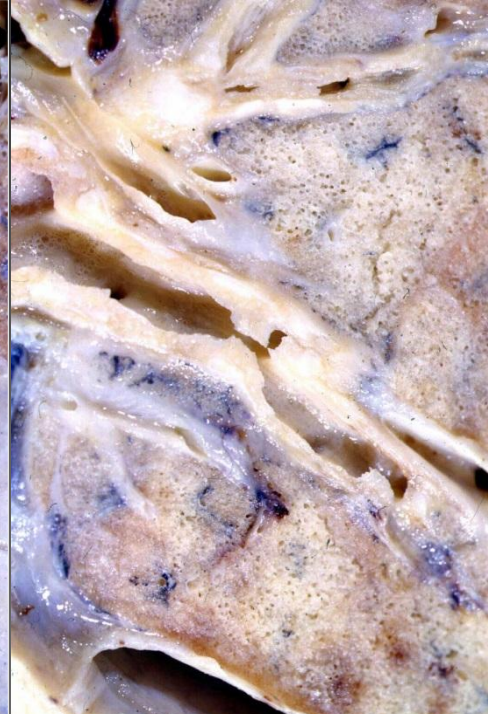
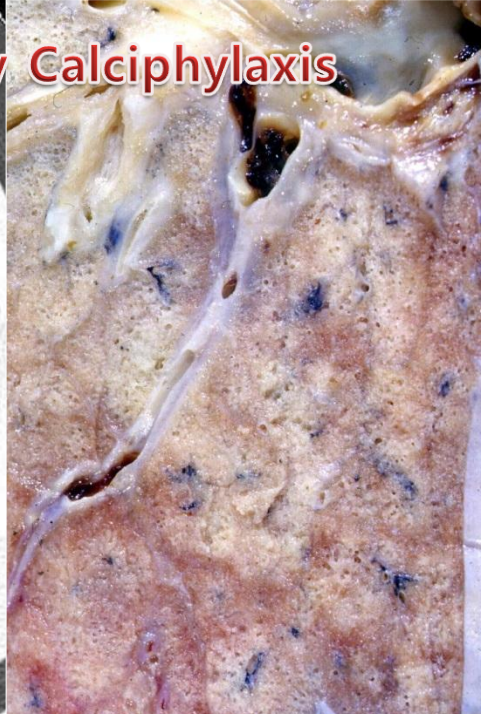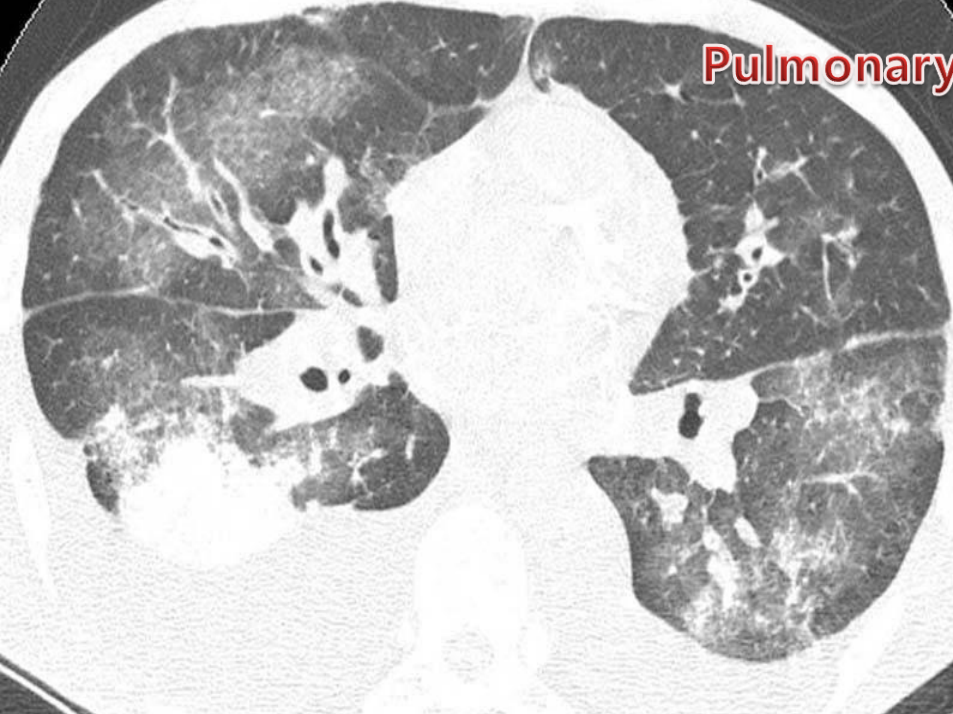
Interstitial foam cells, centering on bronchioles → DPB

Langerhans cell, eosinophils and cyst → PLCH

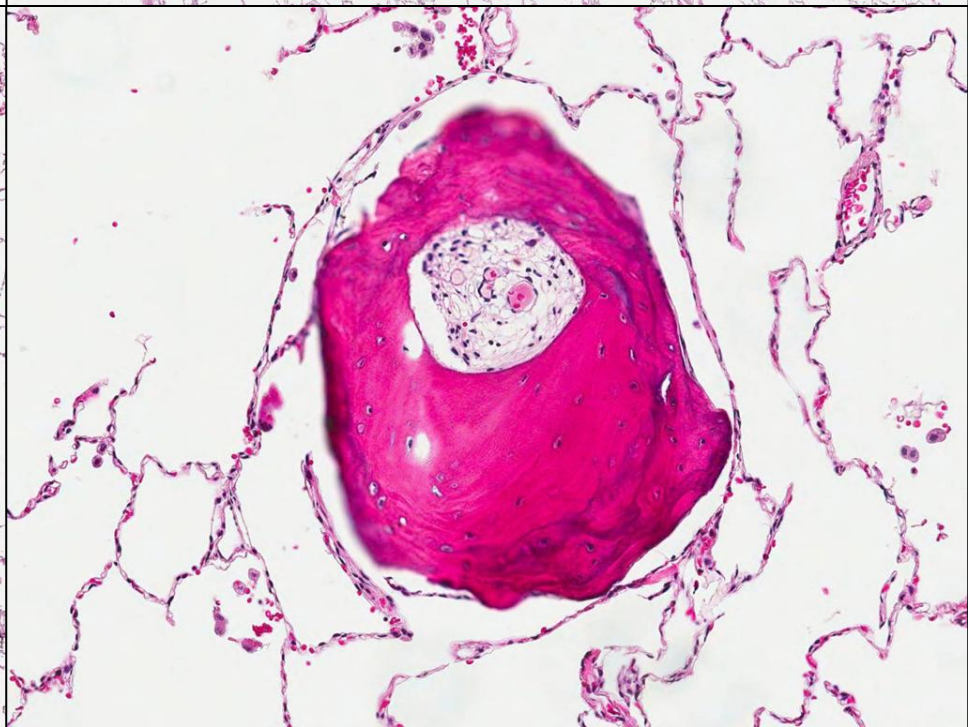
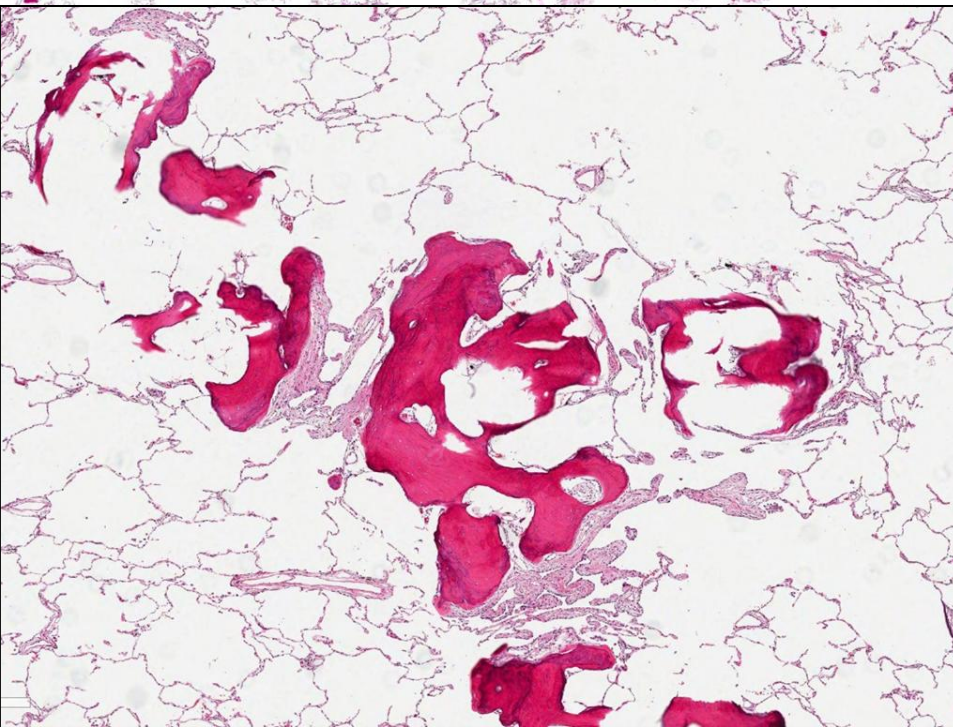
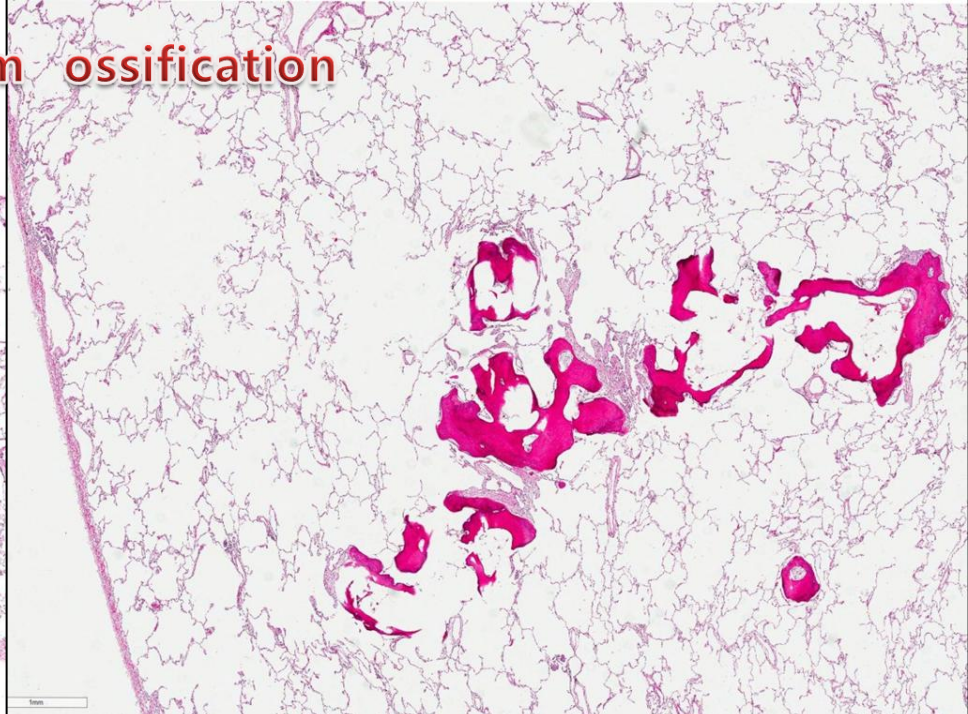
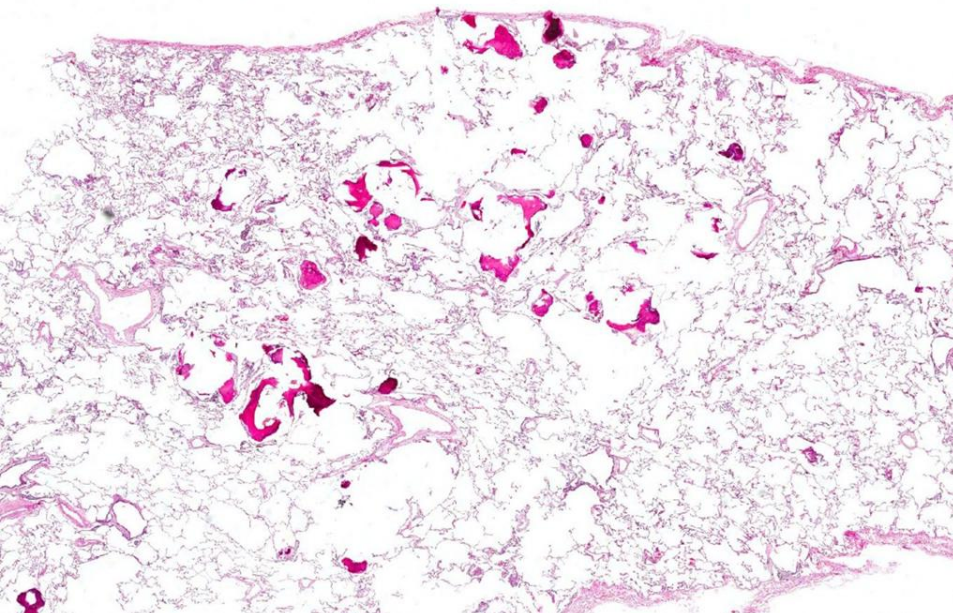
Amyloidosis



Pulmonary Calciphylaxis



Dendriform ossification



경청해 주셔서 감사합니다.

www.pathol.net