



YONSEI
UNIVERSITY

How to perform Thoracic Ultrasound

Kyungsoo Chung

Severance

*Associate Professor
Pulmonary and Critical Care Medicine
Department of Internal Medicine
Yonsei University College of Medicine*

How to perform Thoracic Ultrasound


흉부 초음파 원리와 기본 사용법

흉부 초음파 적용

흉부 초음파 해석

001

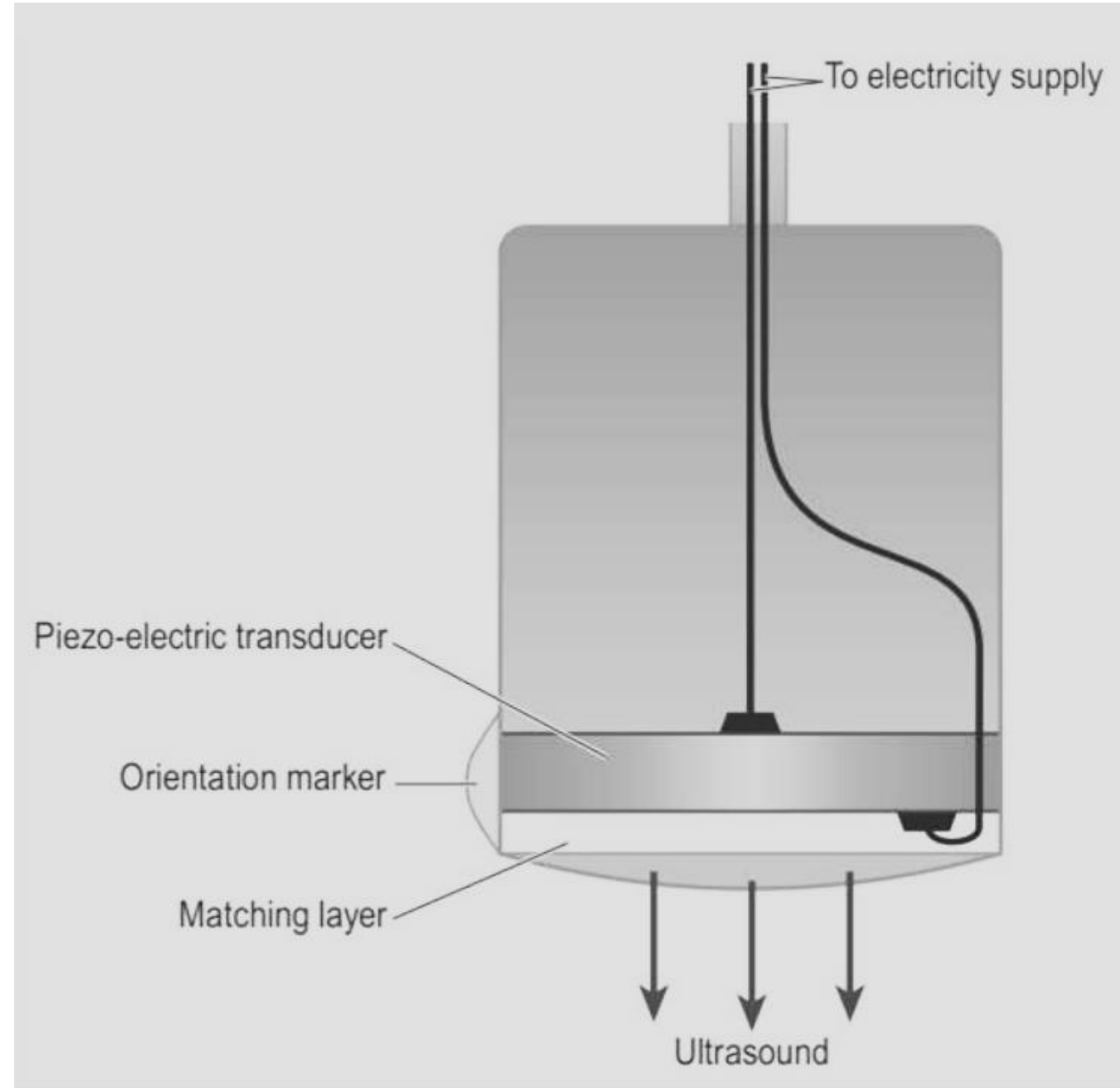
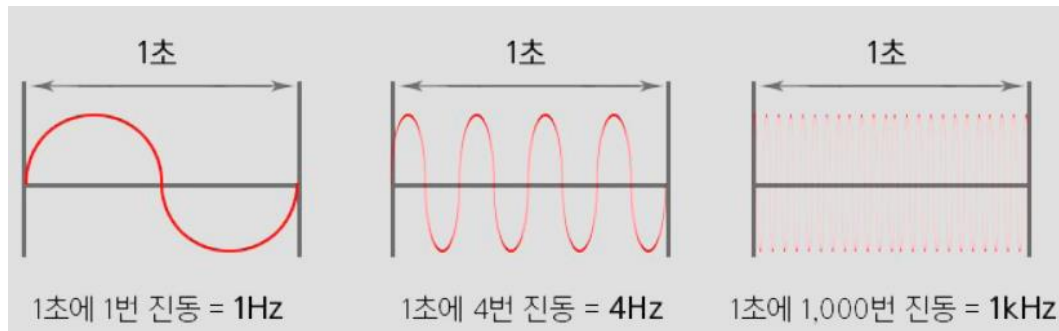
흥부 초음파의 원리와 기본 사용법

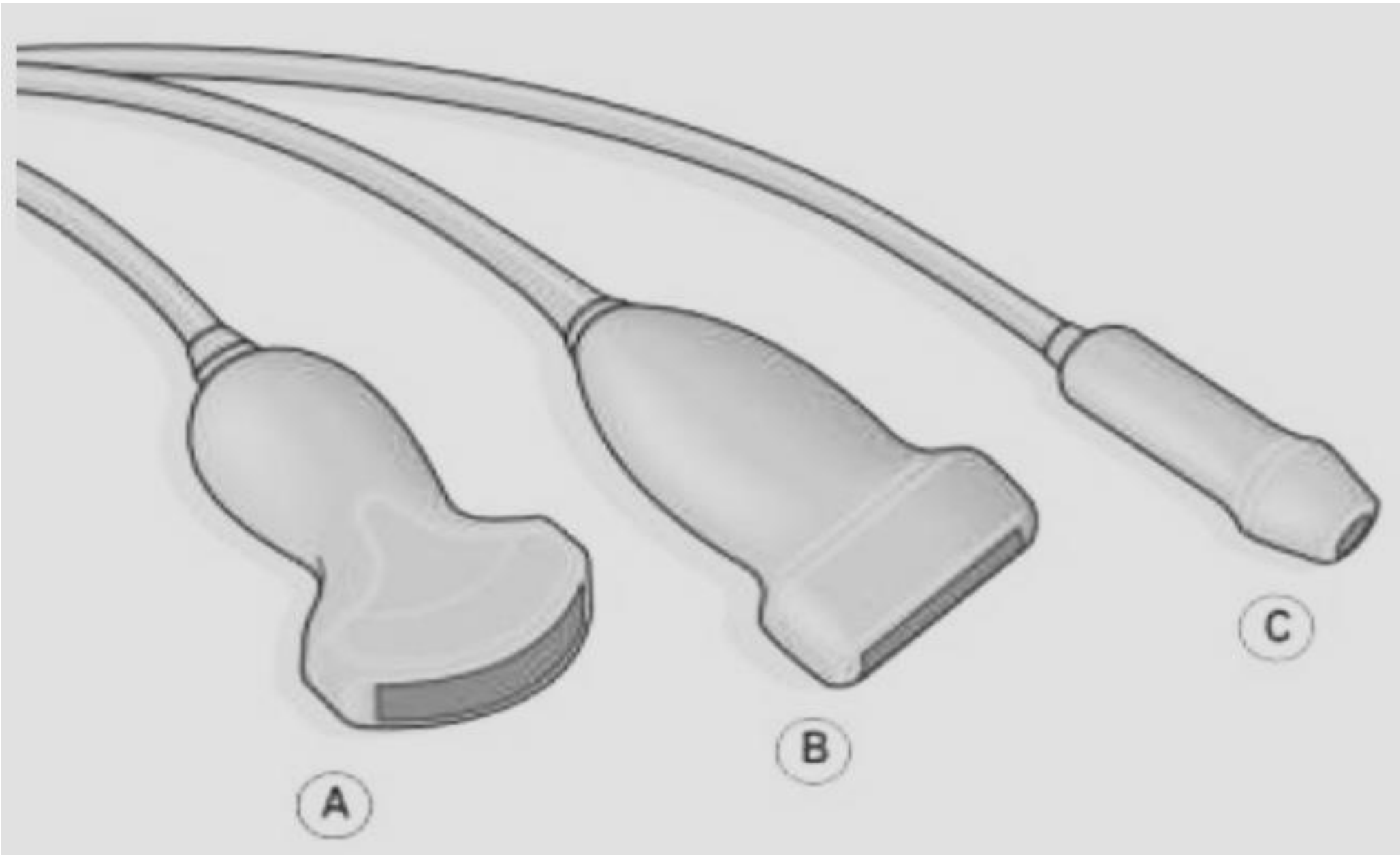



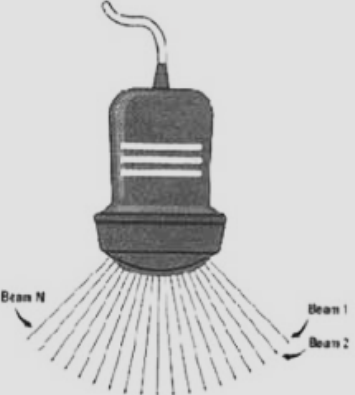
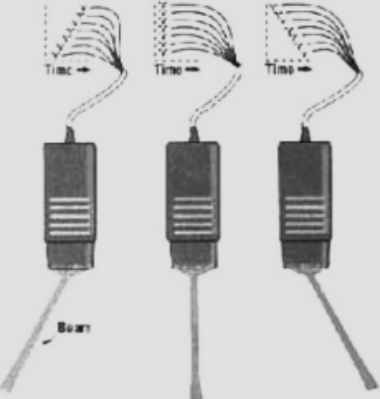
Probe or Transducer (탐촉자)

압전 (piezo-electric) 효과

압전성을 가지는 물질 (압전자, 예)_석영) 결절에 특정한 전압을 가하면 물질이 수축 혹은 확장하면서 용적의 변화 (진동)을 일으키고 그 결과 초음파가 발생하게 됨

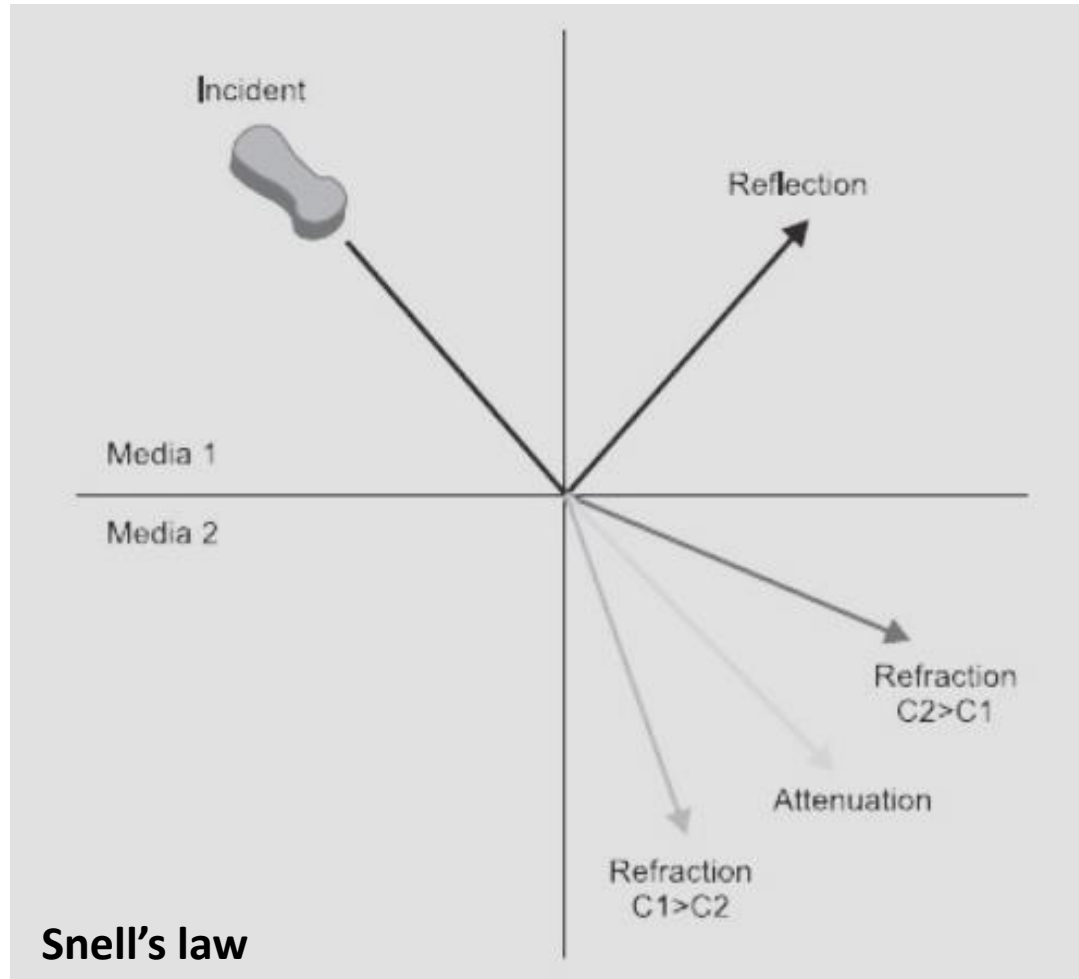




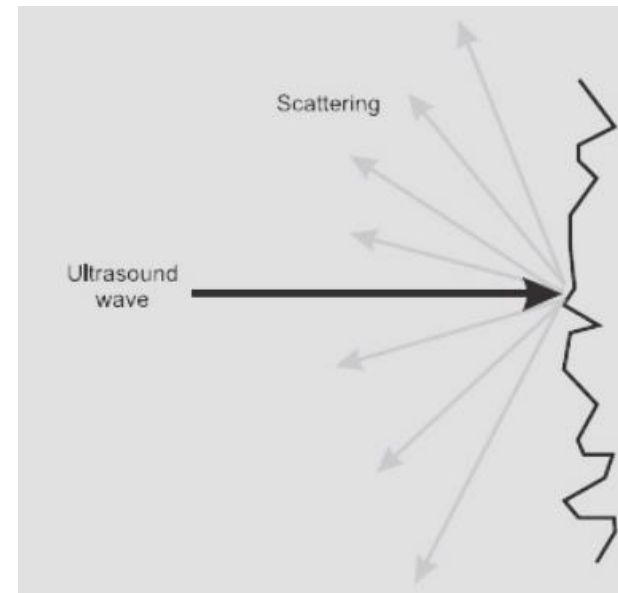
구분	내용	진단 영역
<p data-bbox="698 125 856 154">Linear array</p> 	<ul style="list-style-type: none"> · 한쪽 끝에서 시작해 반대편 끝까지 초음파 하면서 영상 획득 · 최근에는 matrix화하여 훨씬 적은 스캔수로 입체영상 획득 	<p data-bbox="1666 222 1854 291">갑상선, 근골격계, 미세혈관 검사용</p>
<p data-bbox="698 418 871 446">Curved array</p> 	<ul style="list-style-type: none"> · 동작 원리는 Linear array와 동일. 하지만 모양이 부채꼴이기 때문에 영상은 부채꼴 모양. 	<p data-bbox="1691 636 1829 665">복부 검사용</p>
<p data-bbox="698 918 871 946">Phased array</p> 	<ul style="list-style-type: none"> · 모양은 Linear와 같은 직선형이지만 Linear와 Curved 보다 크기가 작음(갈비뼈 사이를 통한 스캔이 가능해 심장 측정 시 유용) · 앞서 두 개와의 차이점은 모든 element*가 동시에 초음파를 발생하여 부채꼴의 영상을 획득 	<p data-bbox="1691 1136 1829 1165">심장 검사용</p>

초음파

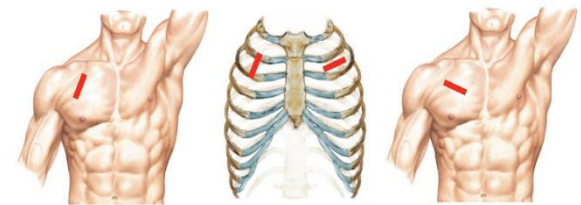20-20,000 Hz 가청 주파수 범위 이상의 높은 주파수를 가지는 음파로, 빛과는 달리 전파를 위한 매개체(매질)가 필요하며, 매개체의 특성에 따라 전달 속도에 차이가 남 (매개체의 density, stiffness, bulk modulus에 따라 전파속도가 차이 남): 공기 < 물 < 뼈



- Transmission (투과)
- Attenuation (감쇠)
- Reflection (반사)
- Absorption (흡수) → 마찰력 & heat
- Refraction (굴절) → artifact
- Scattering (산란)

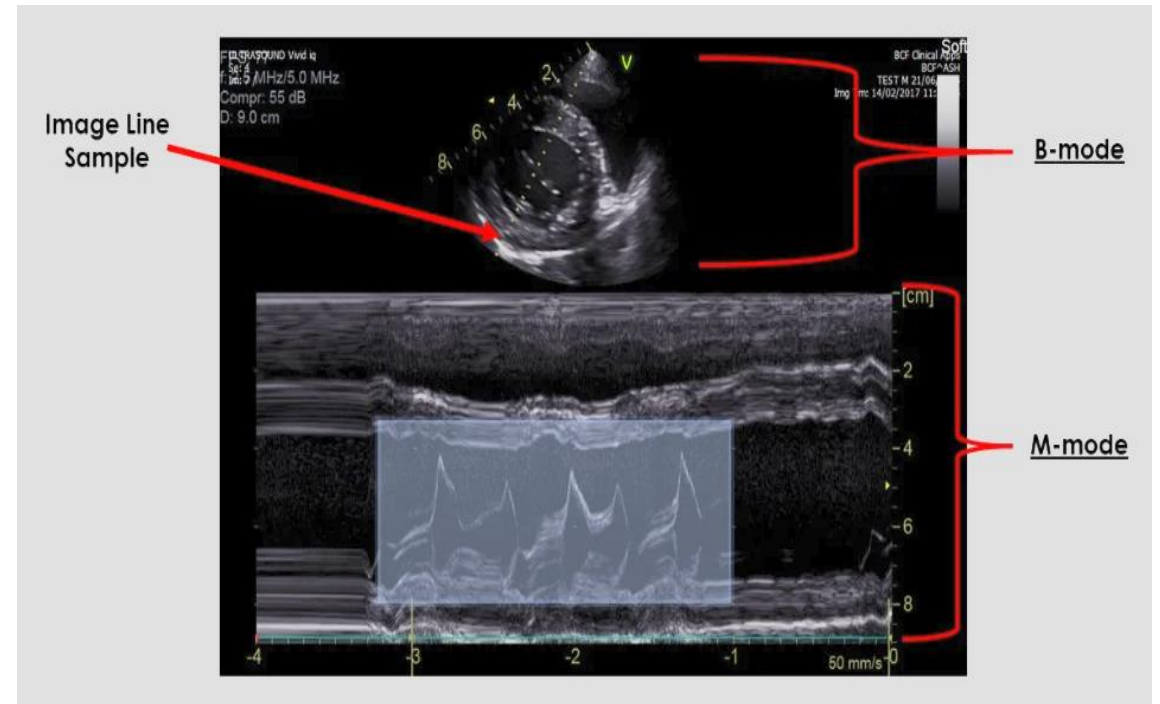
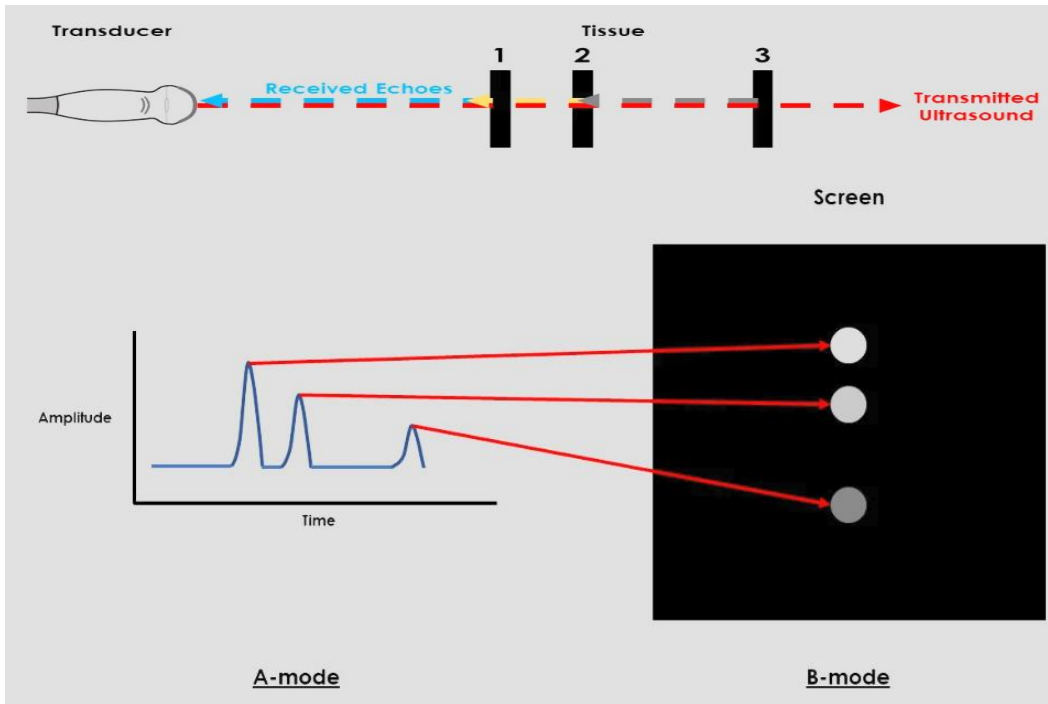


• Longitudinal versus Transverse Scans



Mode

- **Amplitude mode (A mode)** : 거리 축상에 반사음의 강도를 진폭 크기로 표시 (거리)
- **Motion mode (M mode)** : 반사체의 거리를 시간적으로 표시
- **Bright mode (B mode)** : 반사음을 점(dot)의 밝기로 표시하는 방법 (흑색~백색) (영상)

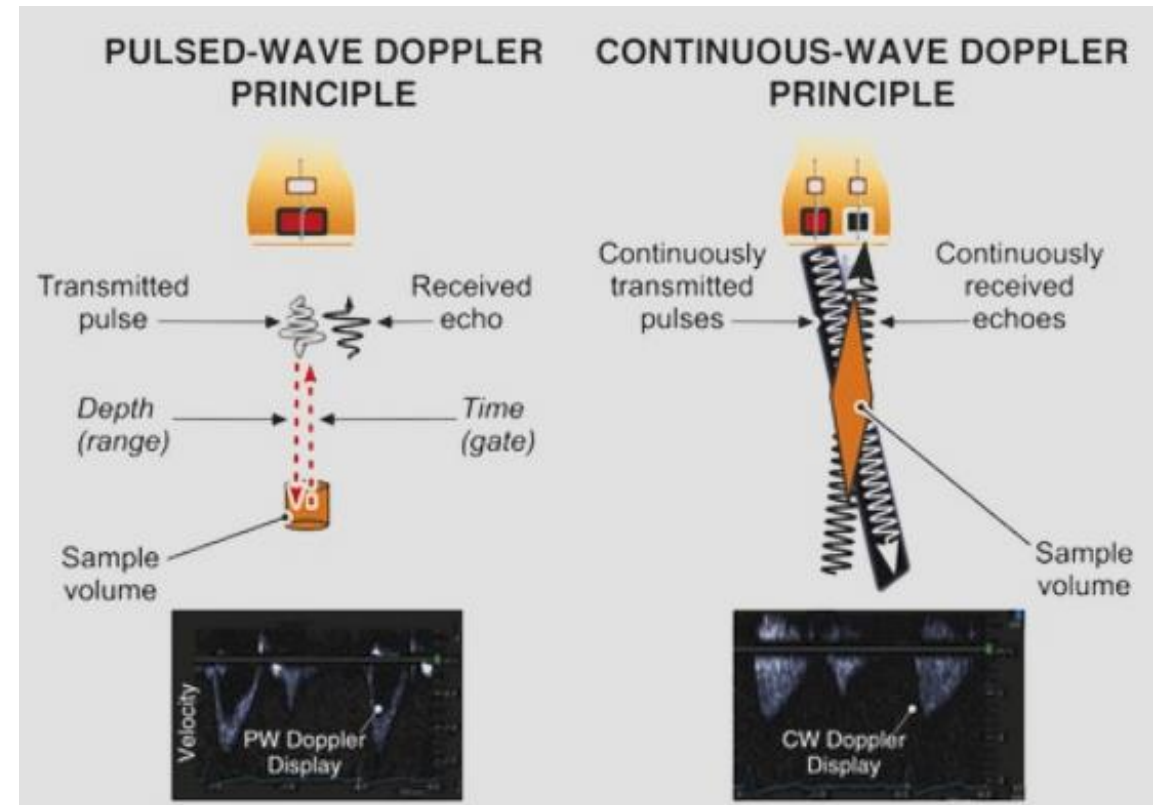
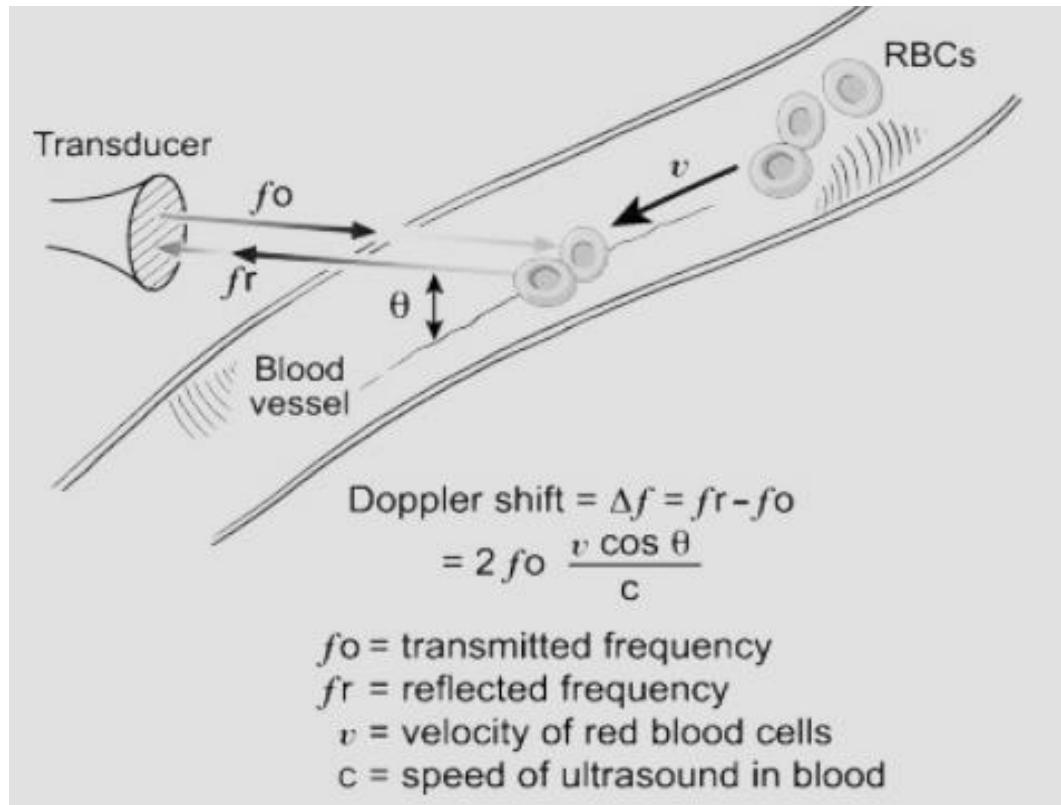


Image

- **Gain (이득)** : 생체로부터의 에코 신호는 스캐너에 의해 전기신호로 변환되지만, 이 상태로는 너무 약하므로 화상이 멎혀지지 않아 전기신호를 강하게 올려주는 것

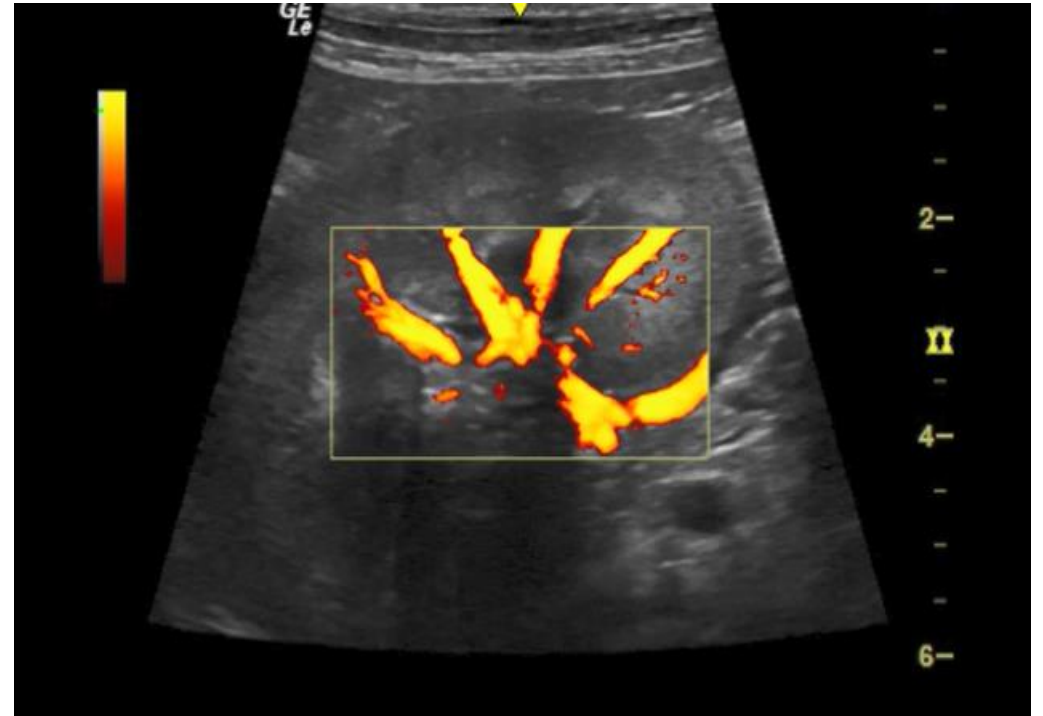
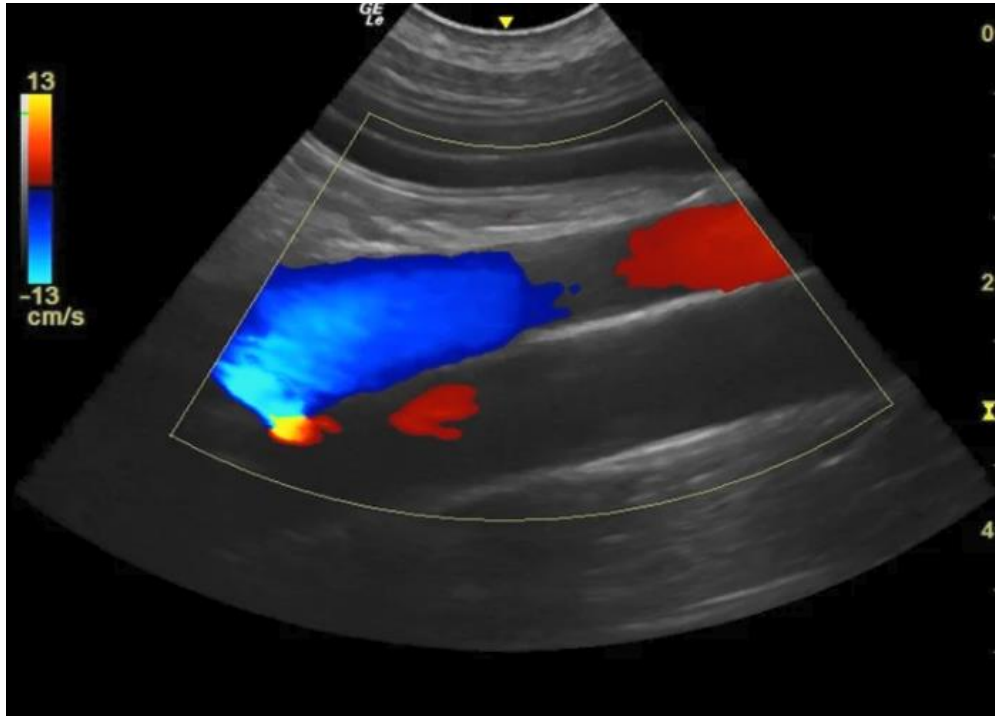
Spectral doppler

- **Pulsed wave Doppler (펄스파 도플러)** : 단일 펄스 초음파 방출/회신, B mode에서 sample gate를 배치, 낮은 유속 / 깊이 측정
- **Continuous wave Doppler (연속파 도플러)** : 연속된 초음파 방출/회신, Beam을 따라 모든 물체 도플러 정보 검출, 높은 유속 / 깊이 측정 불가

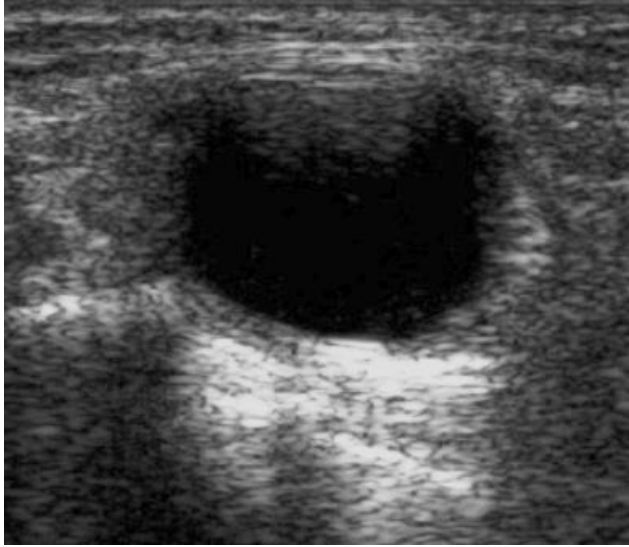


Pulsed doppler

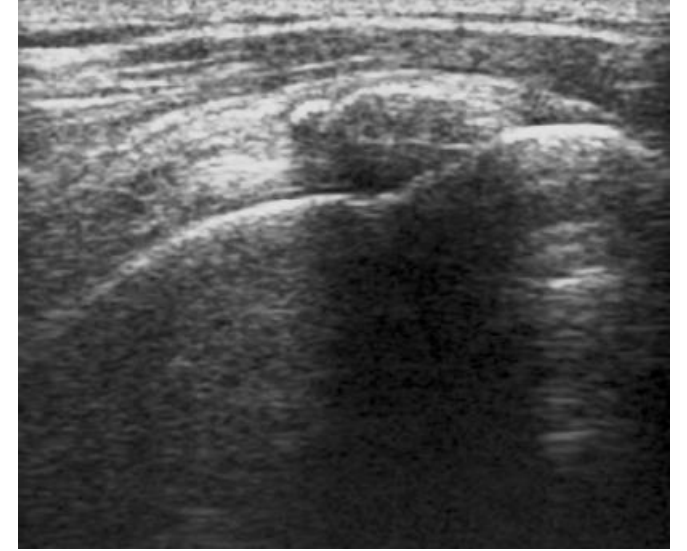
- Color Doppler : 파란색 (초음파 변환기에서 멀어지는 흐름), 빨간색 (초음파 변환기로 가까워지는 흐름) (혈류 유무)
- Power Doppler : 흐름 방향성에 대한 정보는 표시하지 않고, 도플러 신호 강도 전체를 한 가지 색상 음영으로 표시 (흐름에 민감)



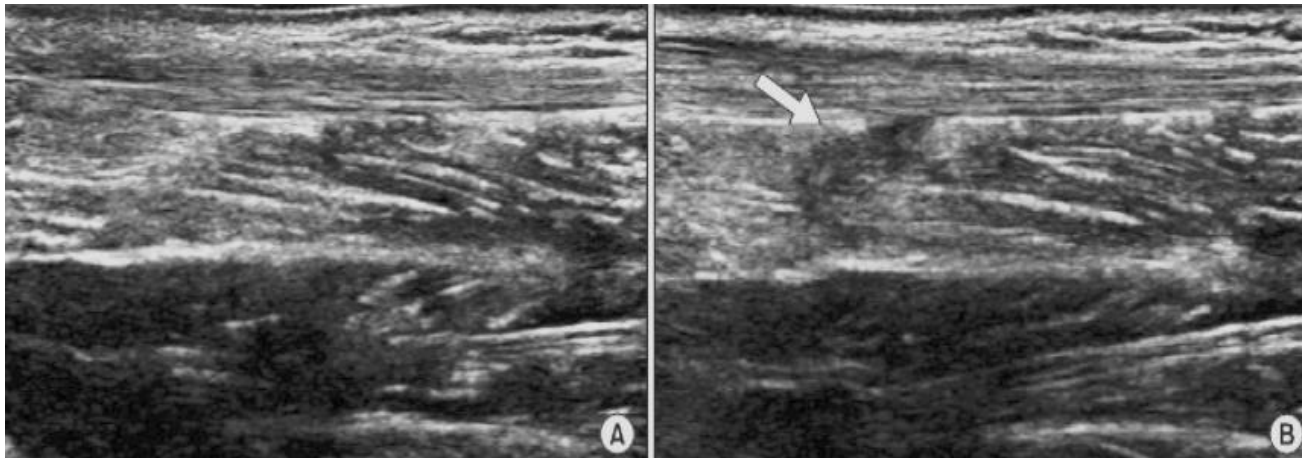
Artifact



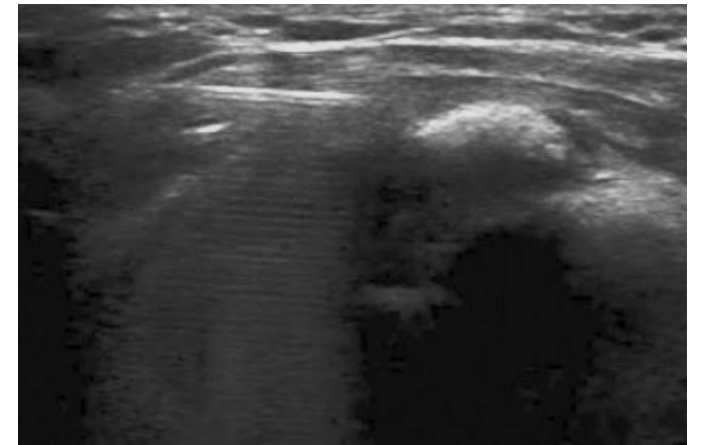
Posterior acoustic enhancement (후방 음영 증강)



Acoustic shadowing (음향 음영)



Anisotropy (이방성)

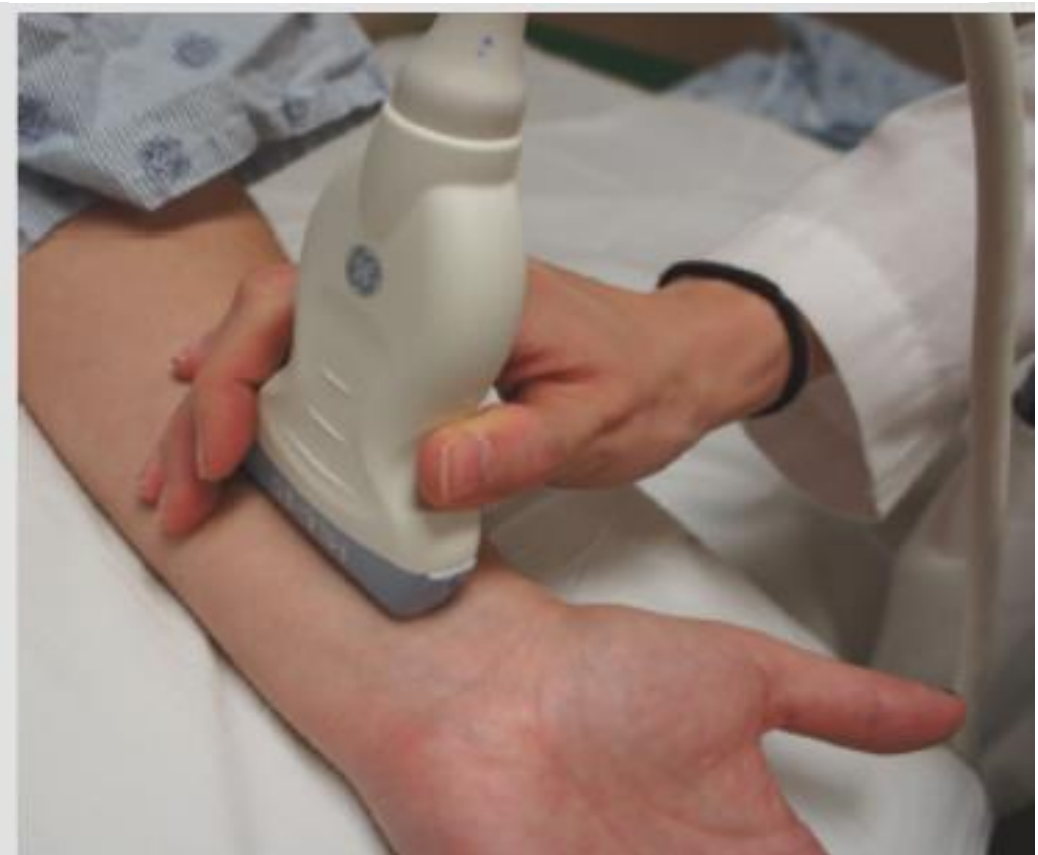
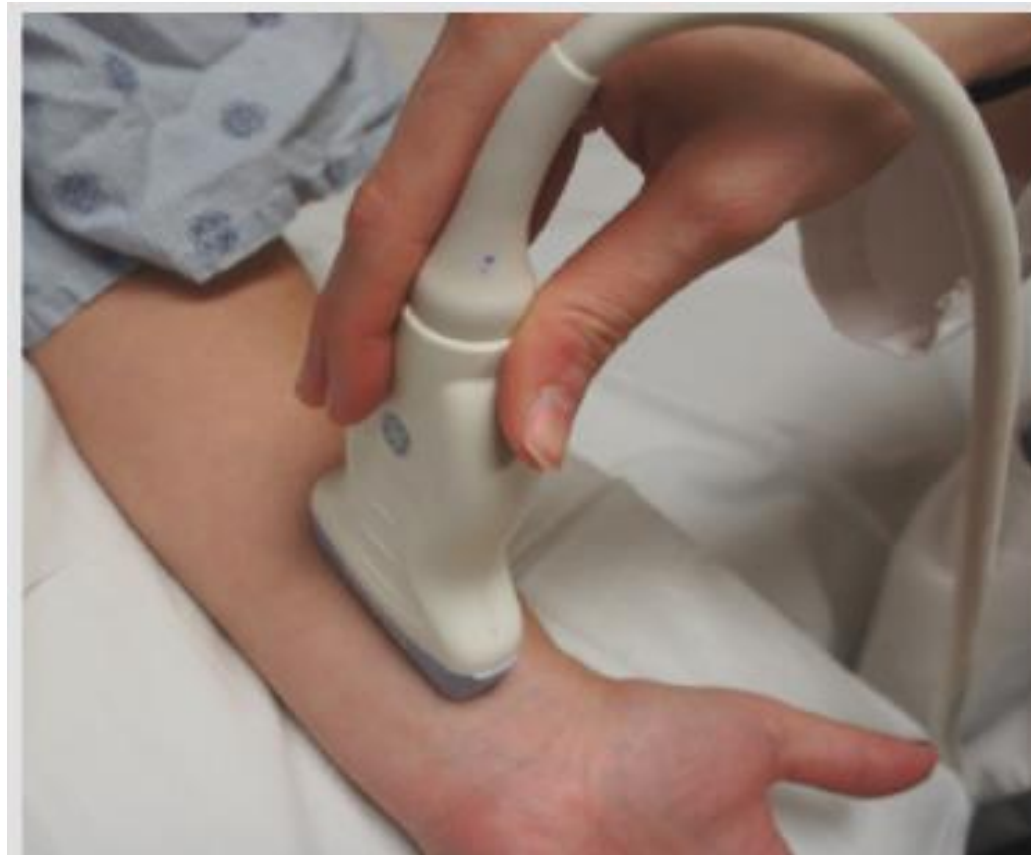
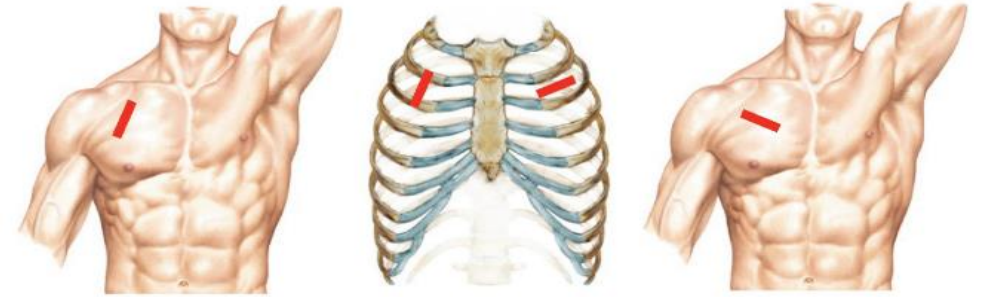Reverberation (다중 반사)

잡는 법



• Longitudinal versus Transverse Scans



Critical care ultrasound

General critical care ultrasound

Critical care Echocardiography

- Pleural
- Lung
- Abdomen
- Vascular – procedure and diagnostic

“B-line & alveolar interstitial syndrome”

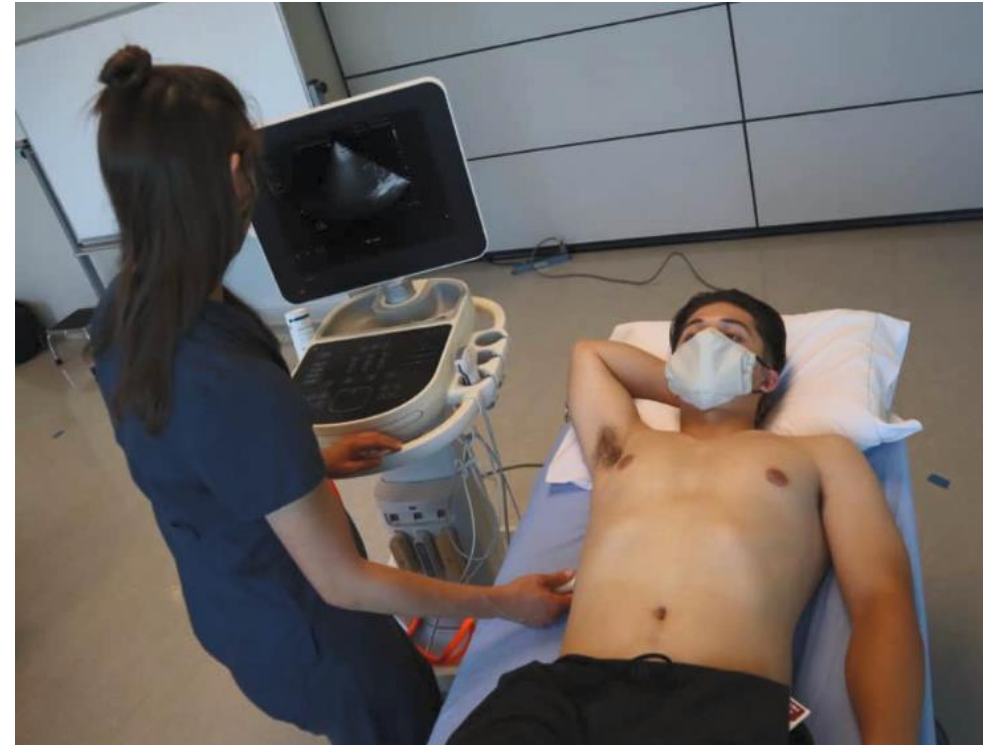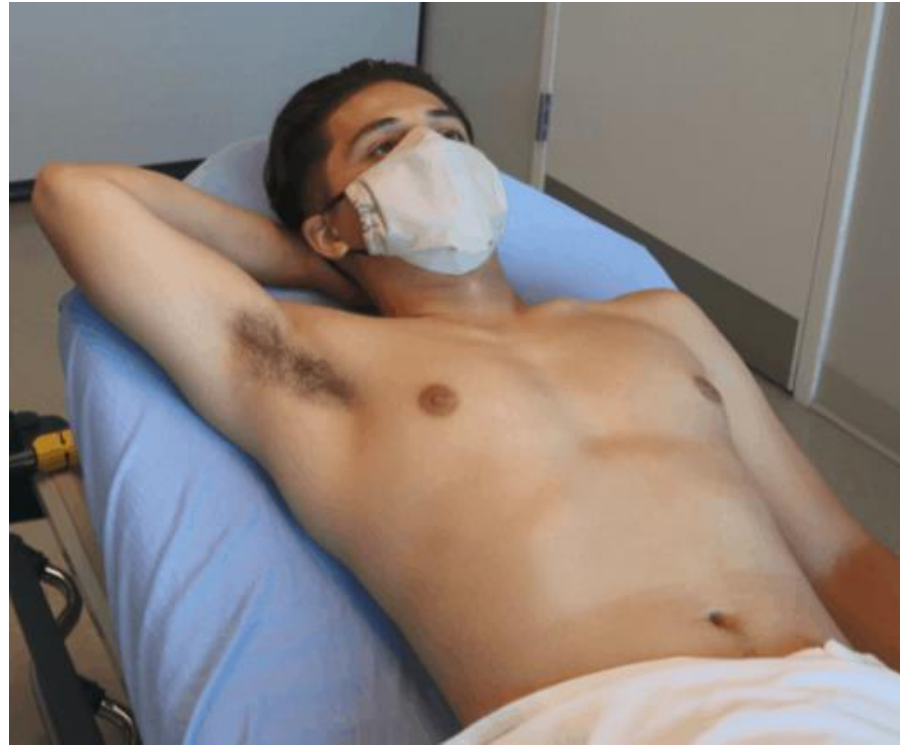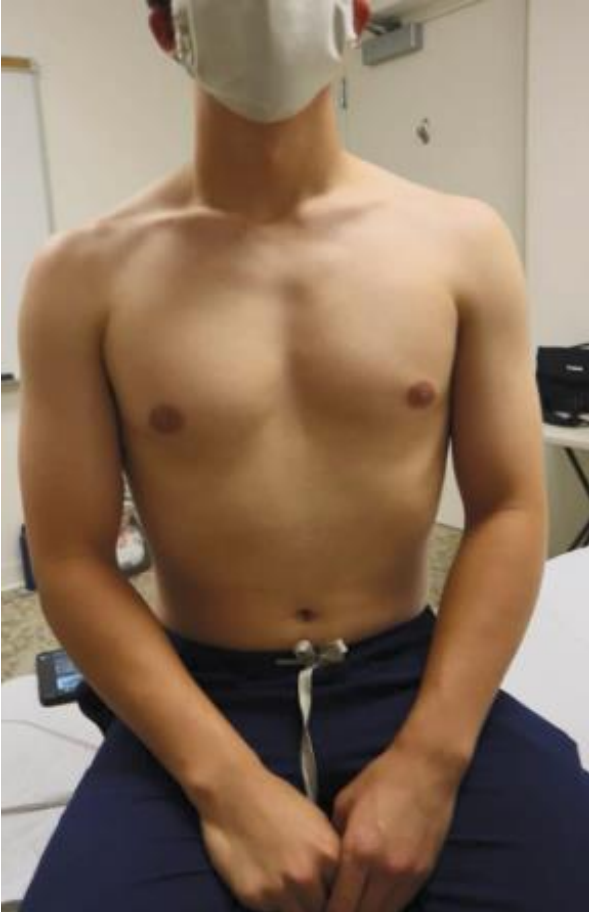- pulmonary edema in acute heart failure or volume overload
 - Non-cardiogenic pulmonary edema
 - Pneumonia
 - Pulmonary embolus
 - Acute lung injury

002

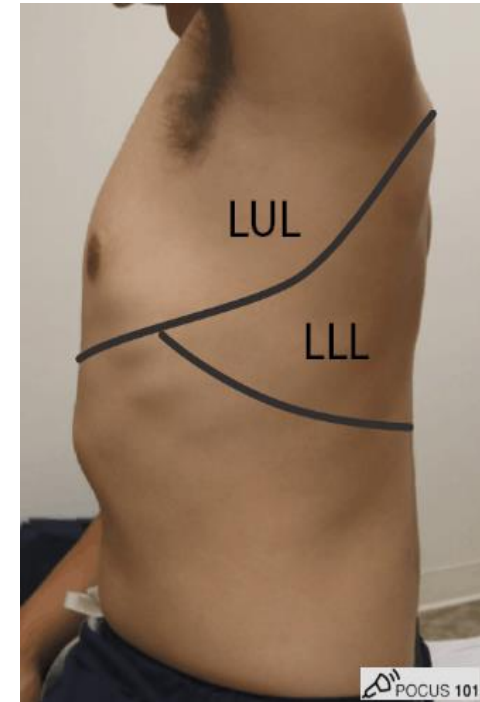
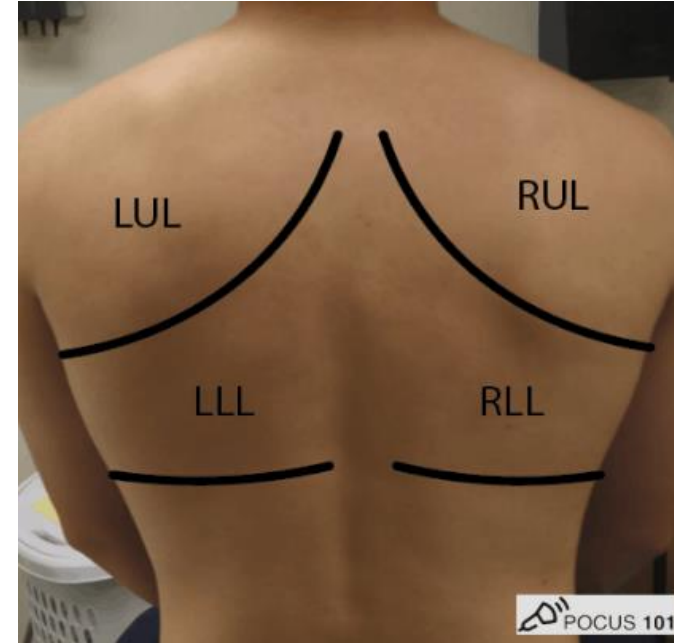
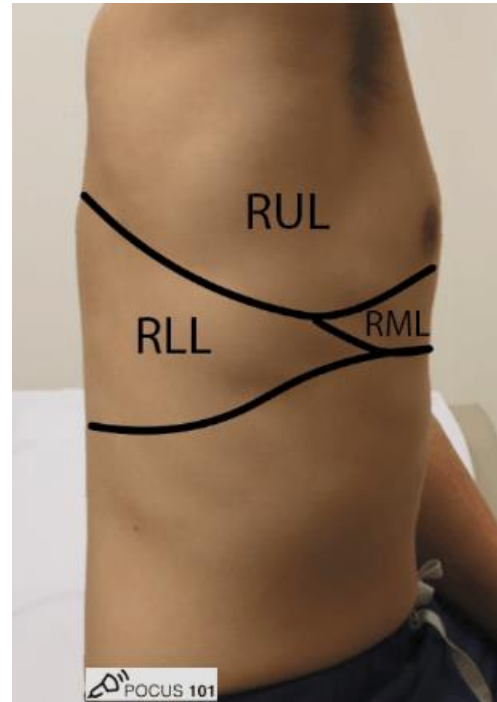
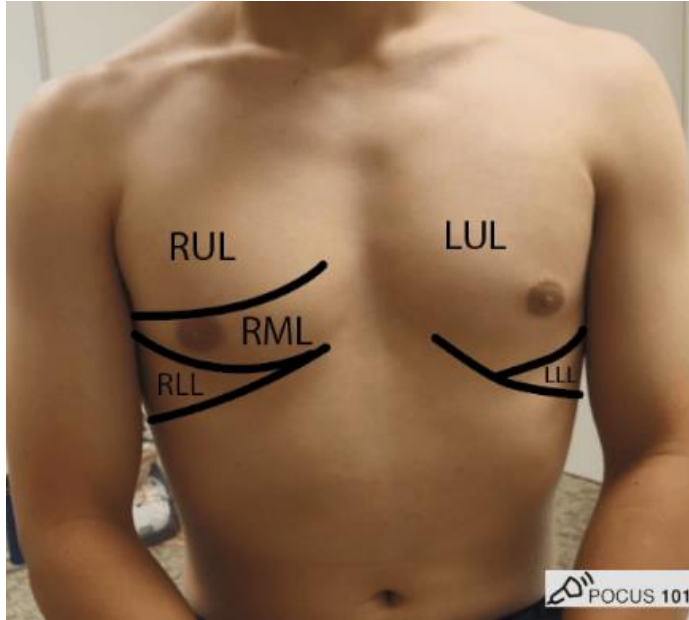
흥부초음파의 적용



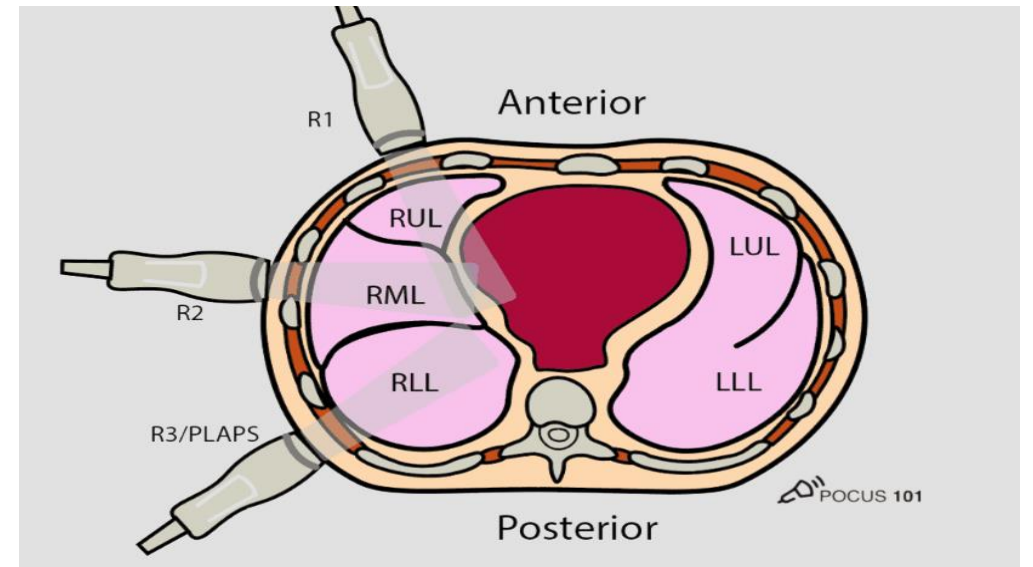
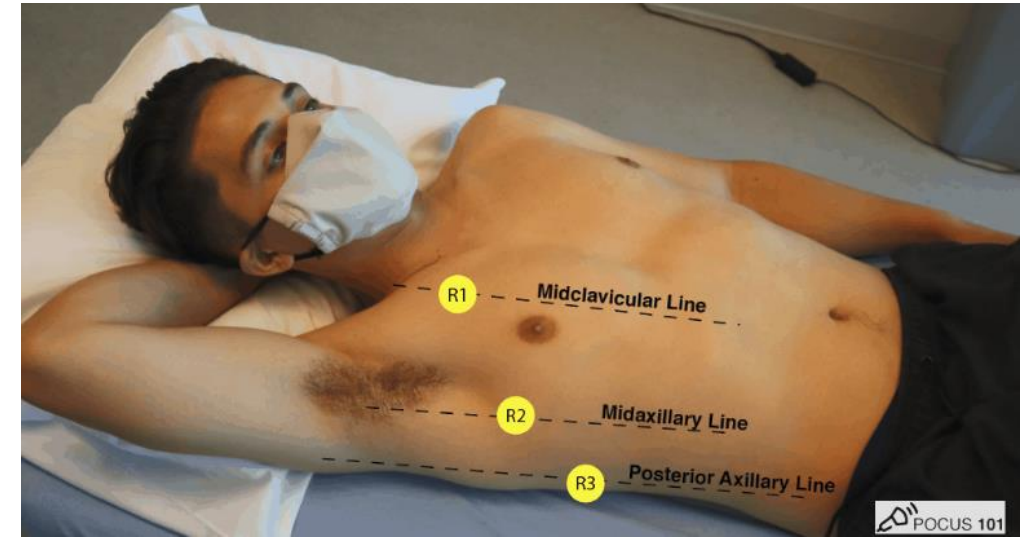
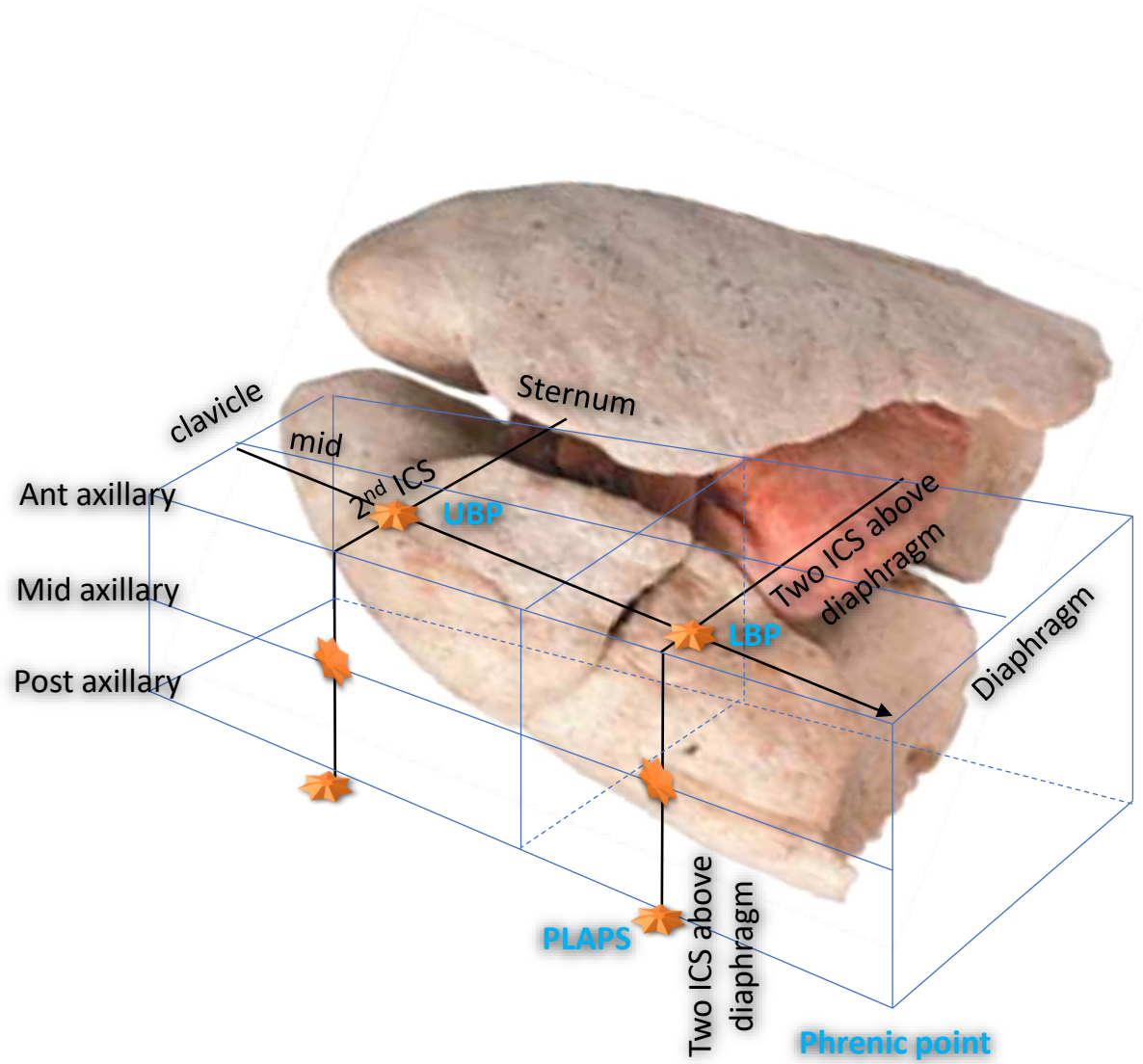
자세



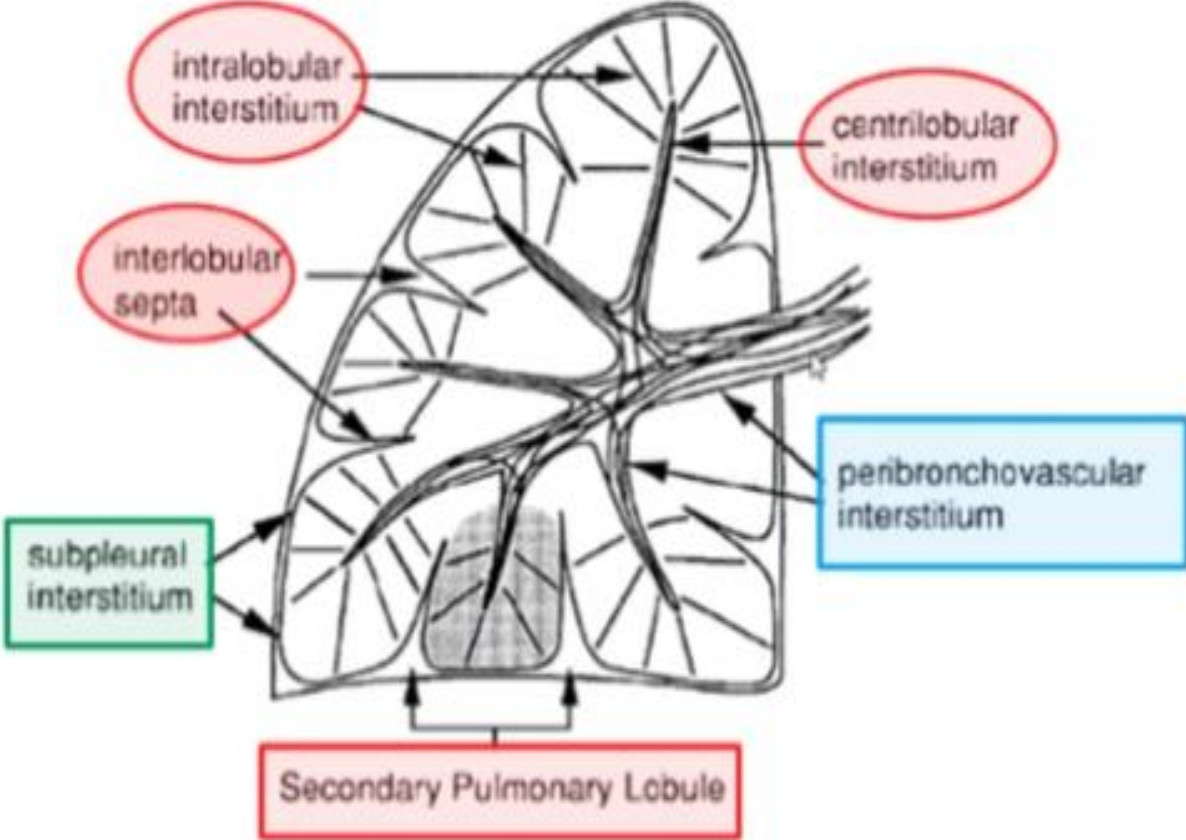
폐 구역



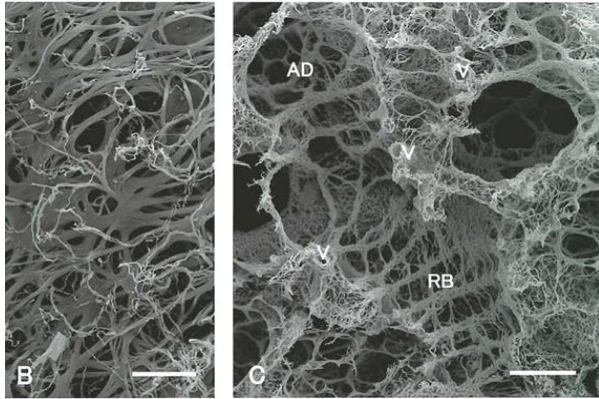

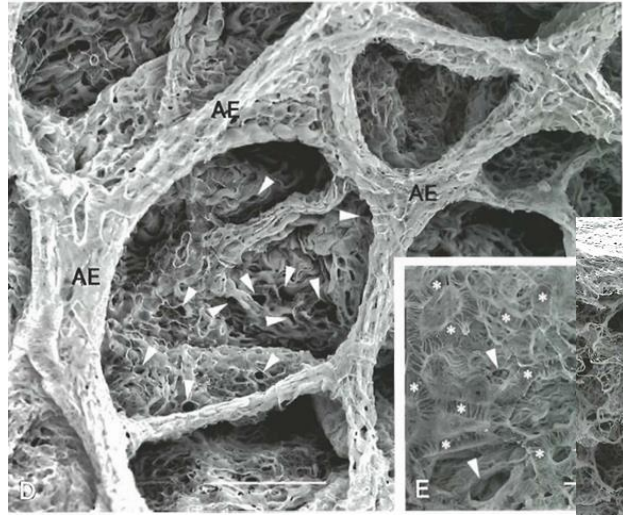
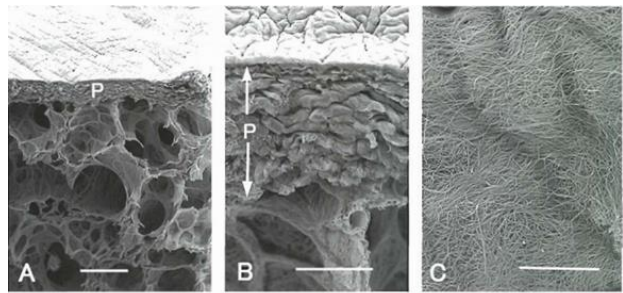
Landmarks



Lung interstitium

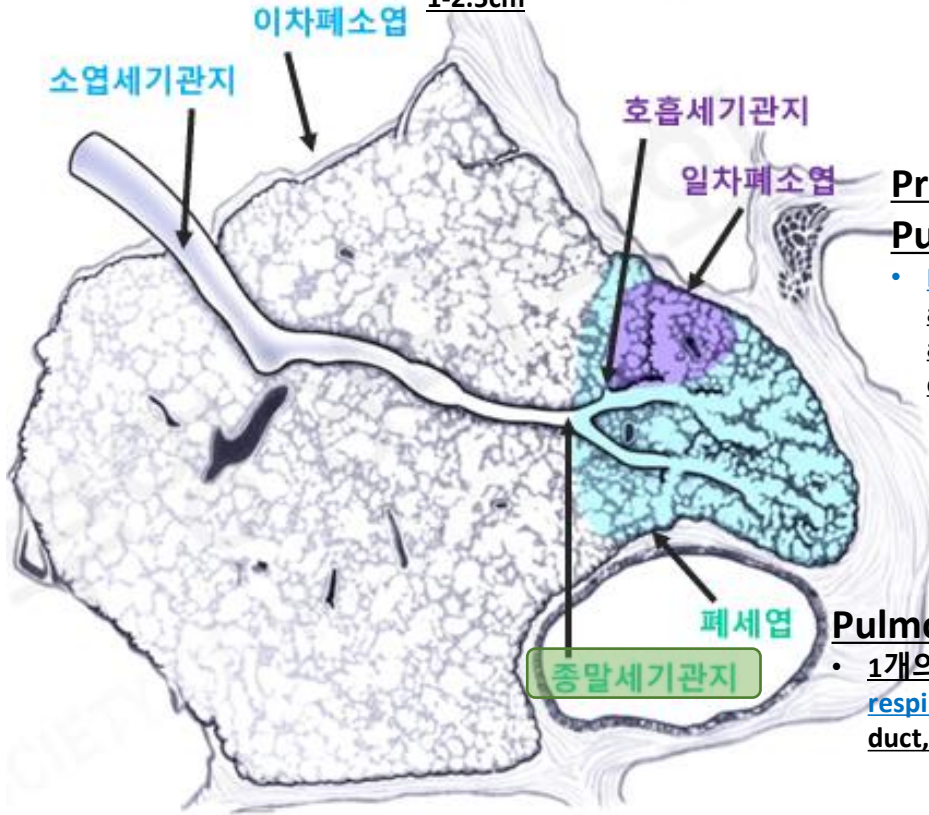


characteristics	Collagen	Elastin
Definition	Three polypeptide chains making up helix of various amino acids	Protein consisting of tropoelastin molecules linked together with hydrophilic acid hydrophobic components
Overall molecular structure	A protein that is compromised of a helix that is made up of three separate component polypeptides	A protein made of several coiled components but no helix is formed
Most numerous amino acids	Proline, hydroxyproline, and glycine as every third residue	Lysine, proline, alanine, and glycine, but glycine is not at every third residue
Flexibility	Not very flexible	Extremely flexible, 1000x more so than collagen
Part of which tissues	Collagen makes up much of the ligaments, tendons, and part of the skin	Connective tissues, especially in the lung and blood vessel walls
Commercial use	It is often used as part of surgical repair of tissues	It is used as part of biomaterials to make structures to repair nerves and blood vessels and even for repair of bones
Formation	In the fibroblast cells	In fibroblasts , chondrocytes, endothelial cells, and smooth muscle cells
Disorders	Ehlers-Danlos syndrome	Supravalvular aortic stenosis, Williams disorder, and some cases of atherosclerosis



Secondary Pulmonary lobule

- ~5-15개 pulmonary acinus 포함
- 1-2.5cm



Primary Pulmonary lobule

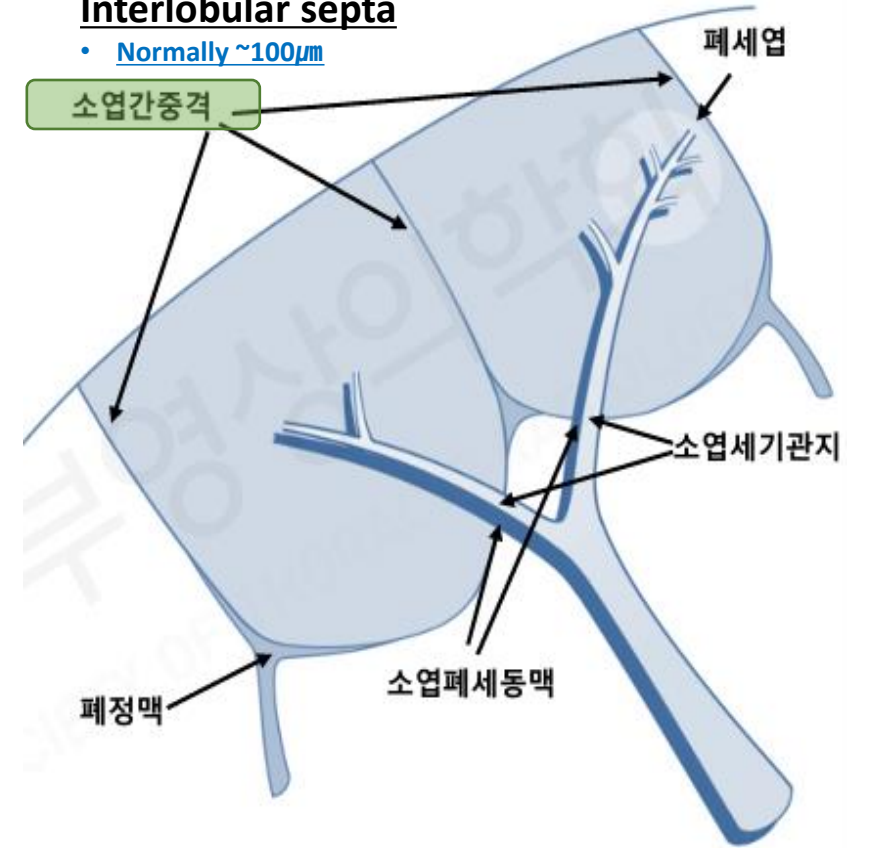
- Respiratory bronchiole 이하 alveolar duct, alveolar sac, alveolus, vessel, nerve, connective tissue로 구성

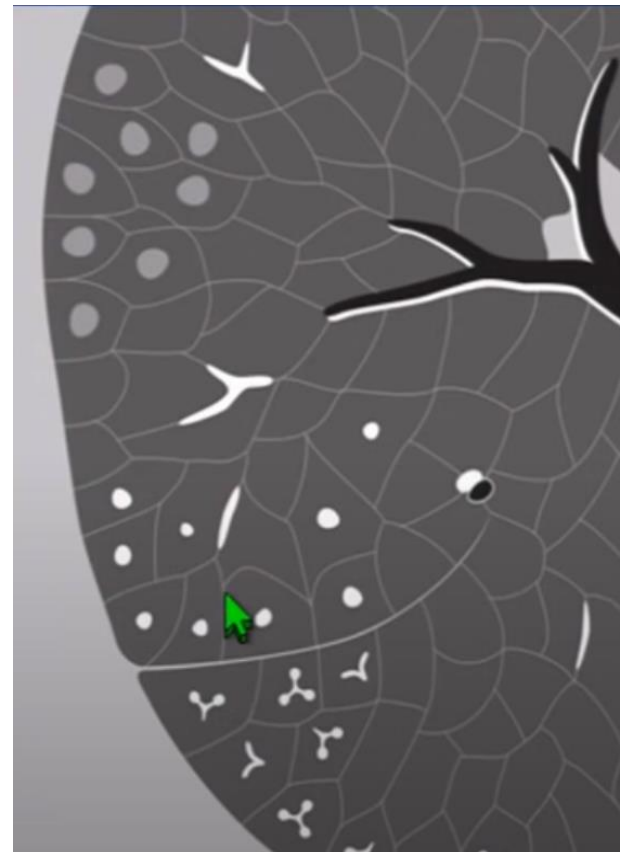
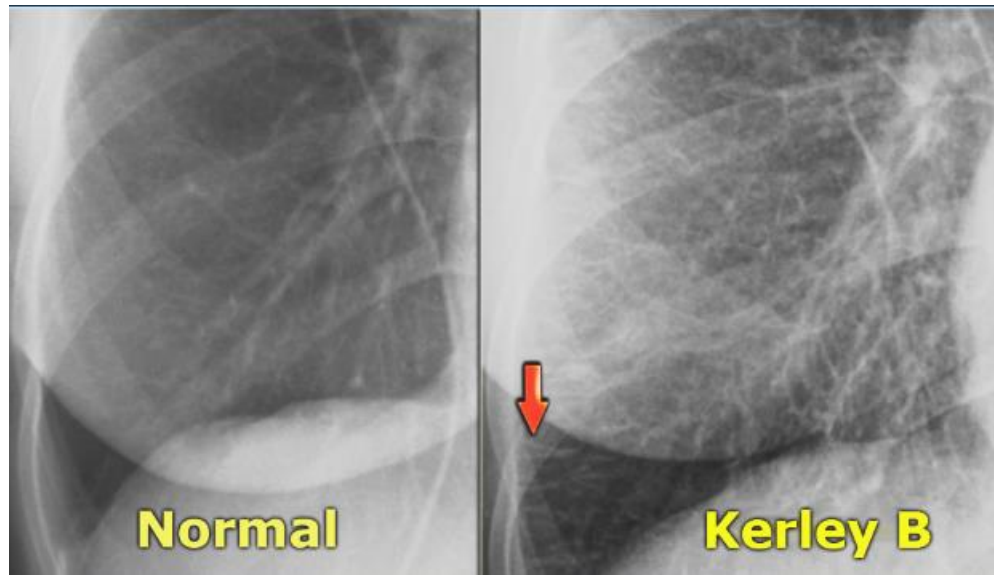
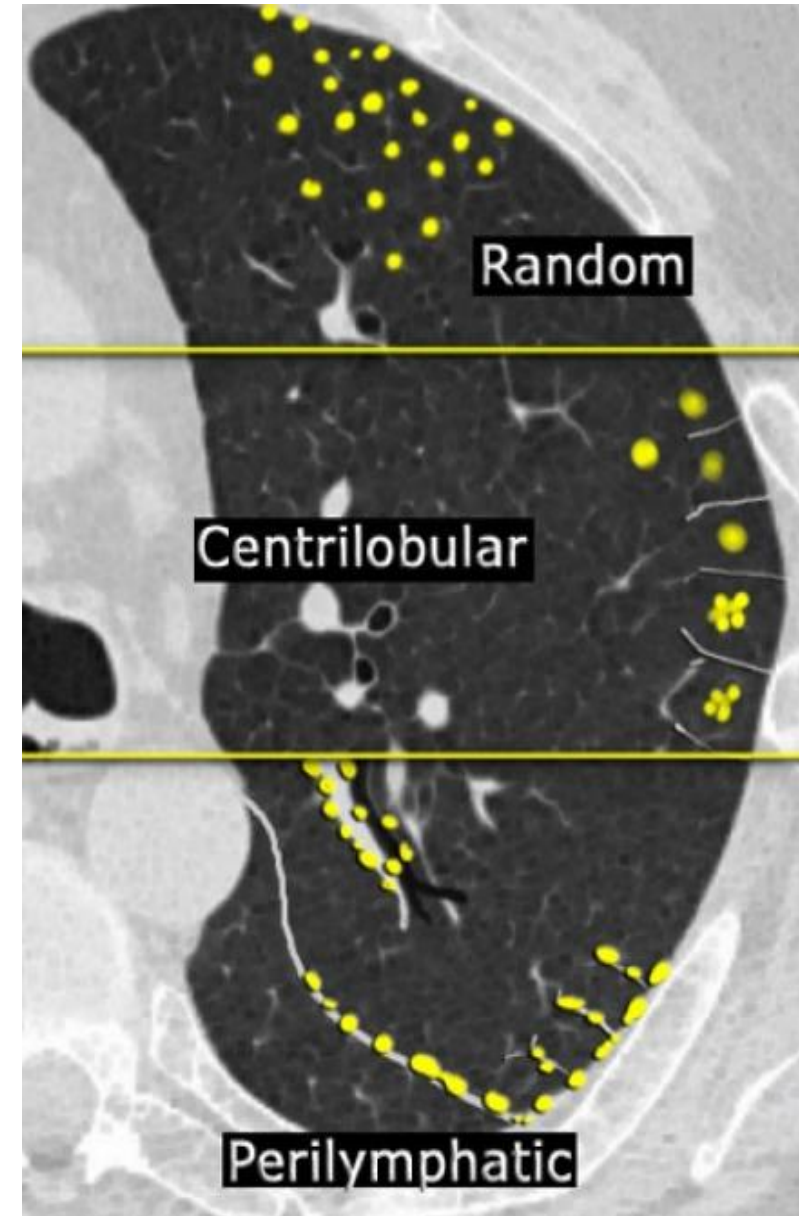
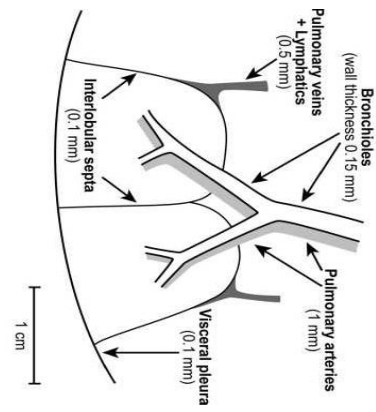
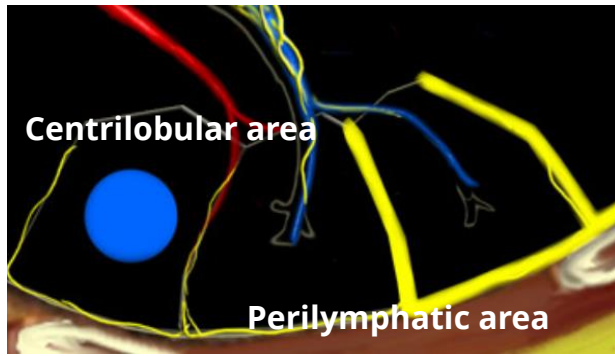
Pulmonary acinus

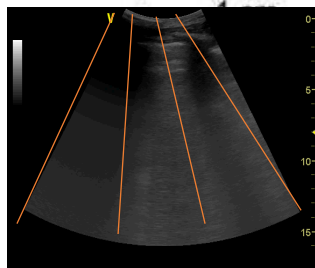
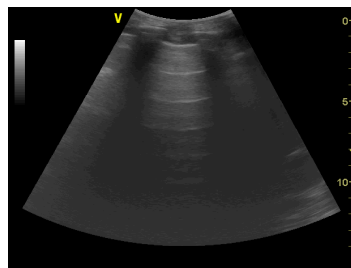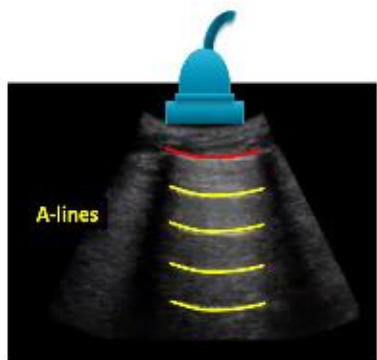
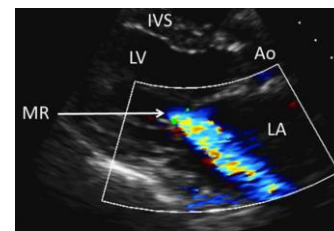
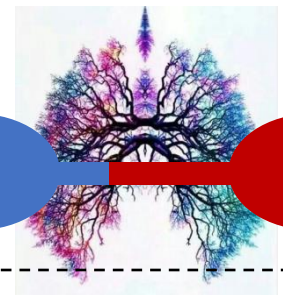
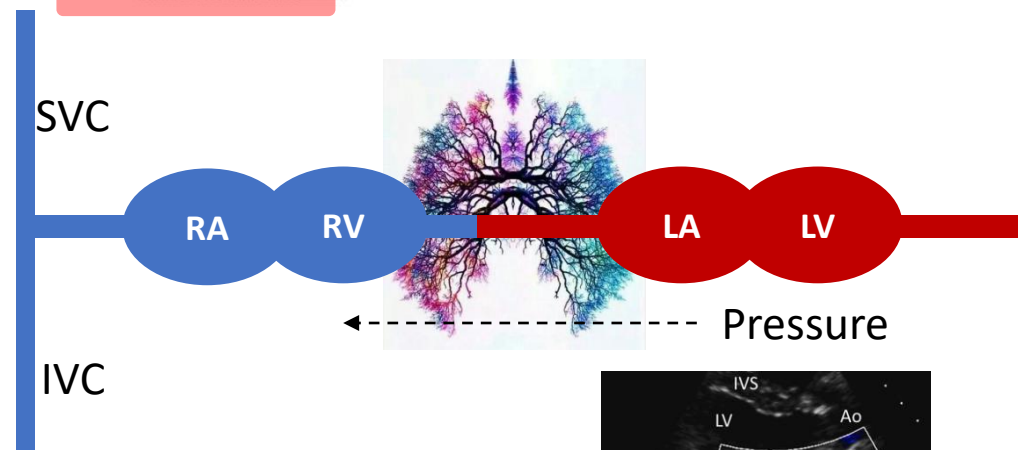
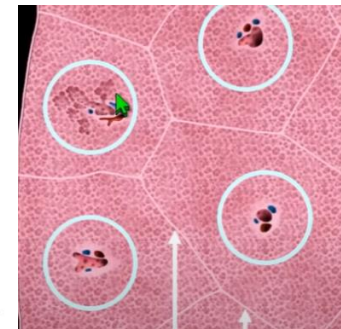
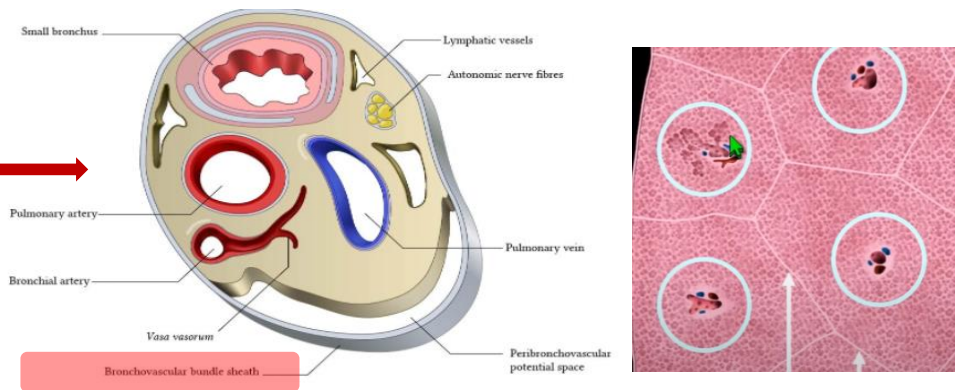
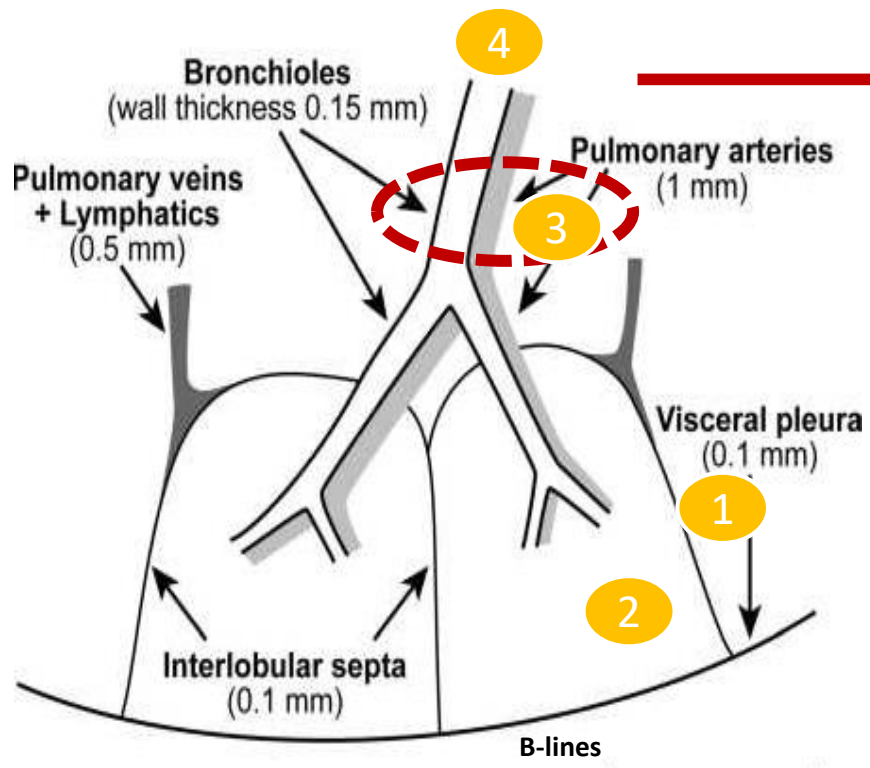
- 1개의 terminal bronchiole 이하 respiratory bronchiole, alveolar duct, alveolar sac, alveolus로 구성

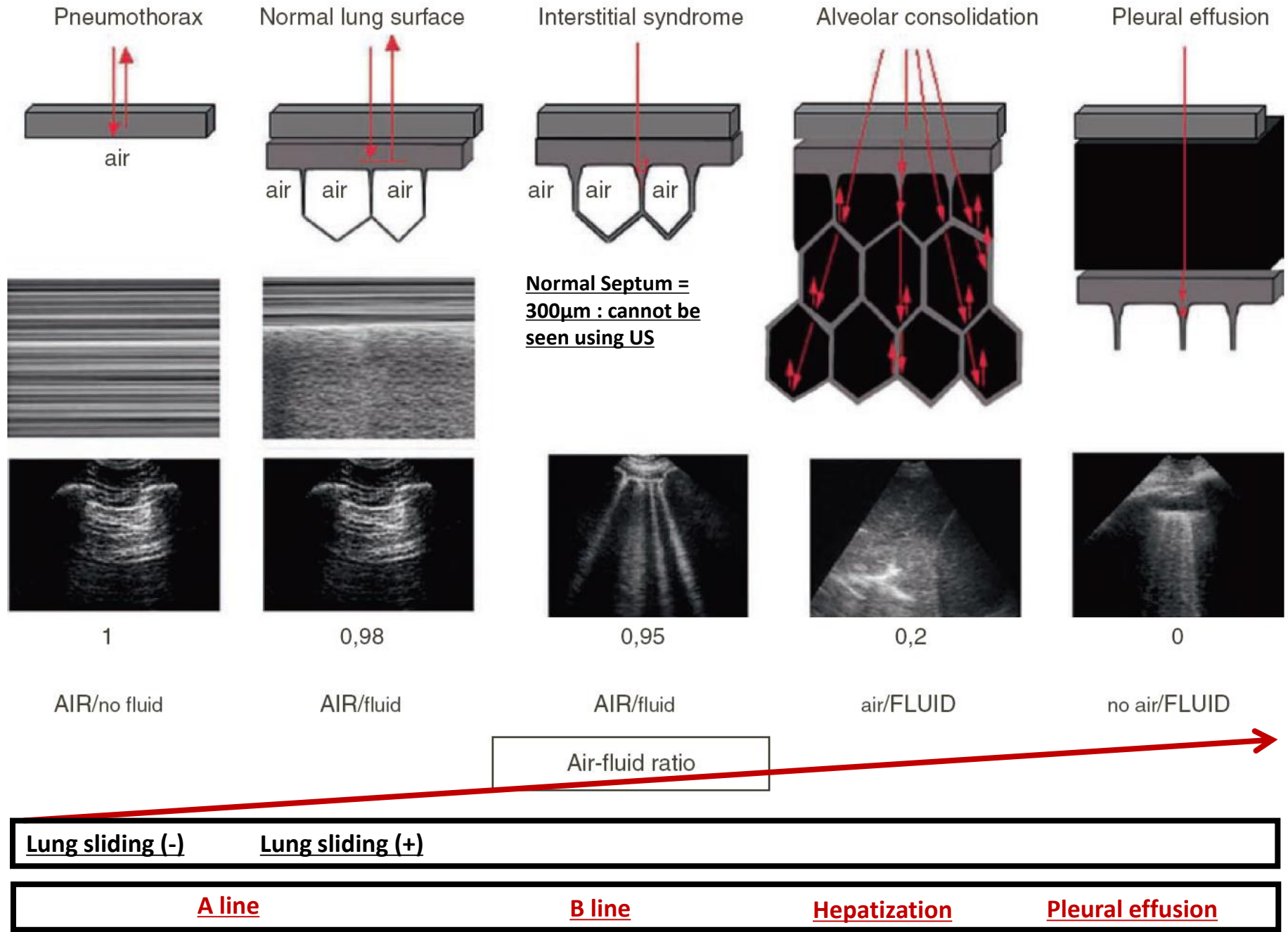
Interlobular septa

- Normally ~100 μ m



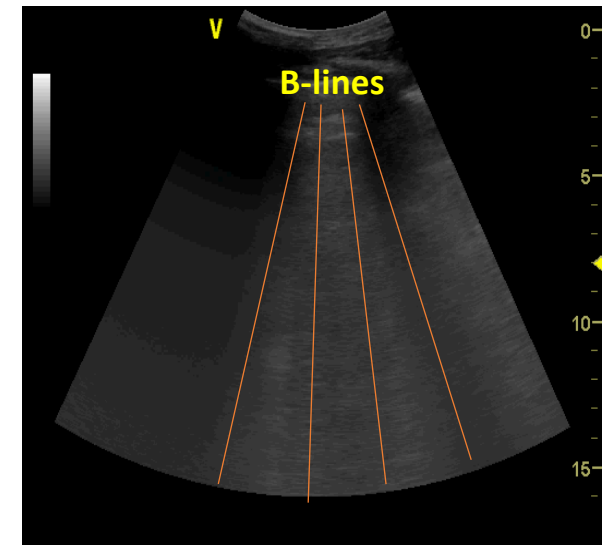
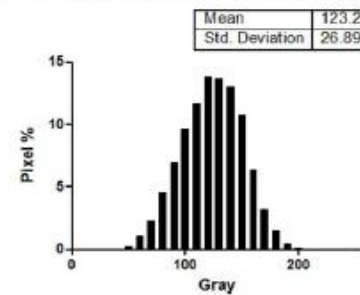
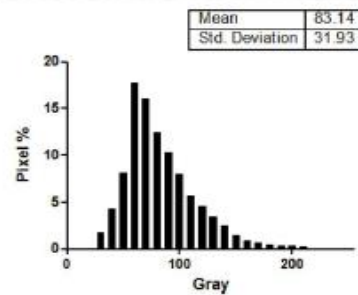
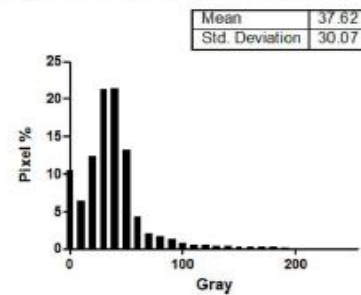
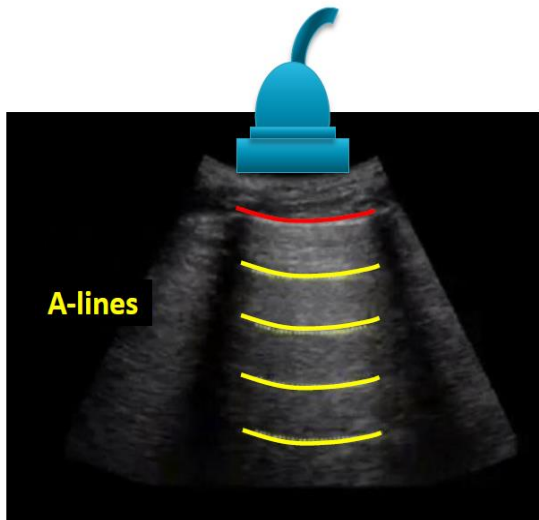
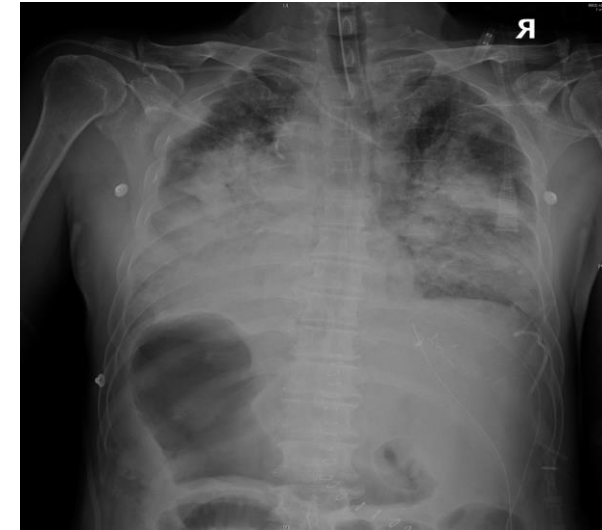
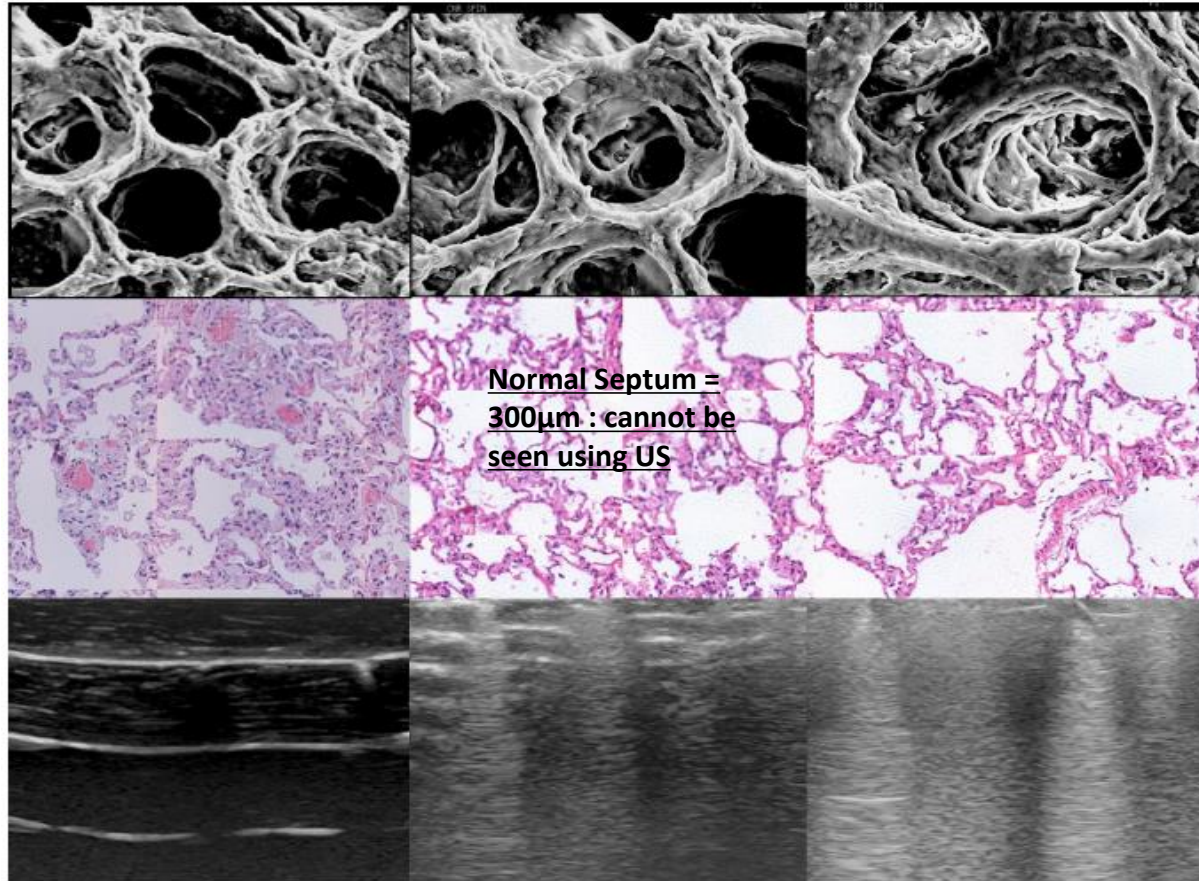
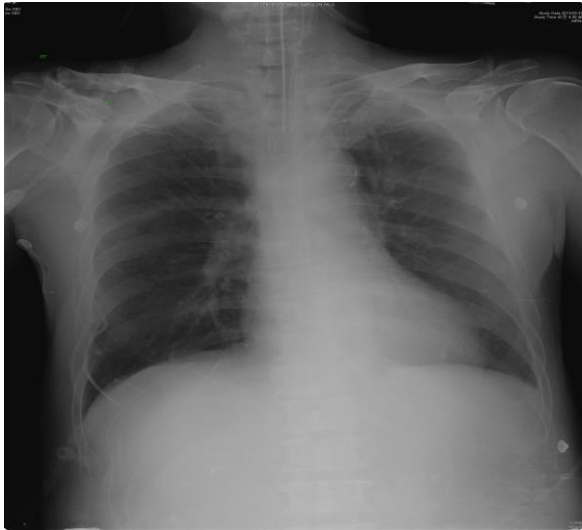






A-line & B-line

Reverberation artifact Air-fluid interface in the interstitial space



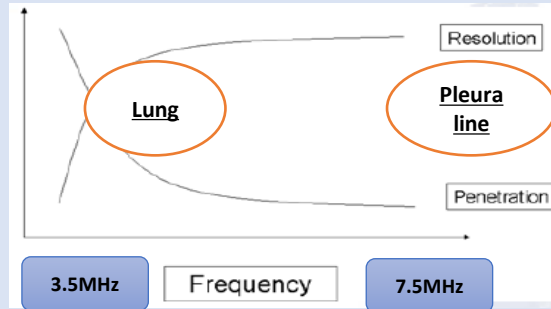
003

흥부 초음파의 기본 해석



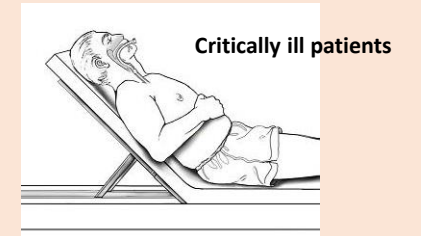
초음파 기계 설정 및 probe 선택

- 기계 설정 : no harmonic (THI ; tissue harmonic imaging)
- Probe (5MHz) : curvilinear probe or phased array probe
- ※ linear for pleura
- Set : Lung or Abdominal
- B-mode / M-mode



환자 자세

- Supine (B-line)
- Reclined at 45 degree (pleural effusion)
- Sitting

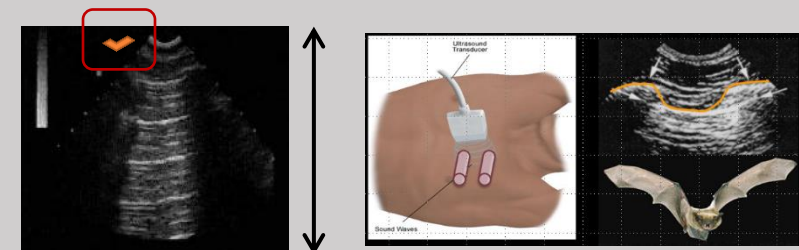
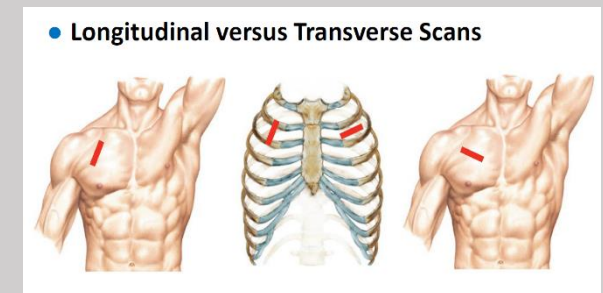


검사 부위

- BLUE point : fast & simple
- Semi-quantitative measure (I & II)

Initial basic view

- Perpendicular to the rib
- Marker to Left of screen
- Depth : 10cm
- Batwing sign

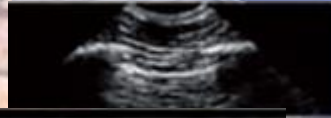

Findings on Lung Ultrasound




Findings on Lung Ultrasound

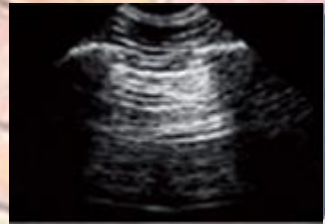Batwing sign



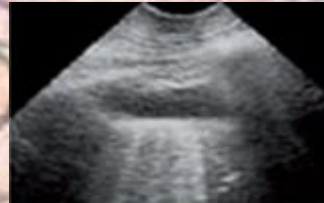
Lung sliding
(lung pulse)



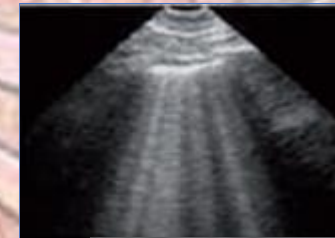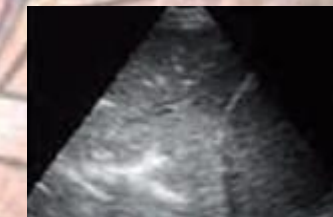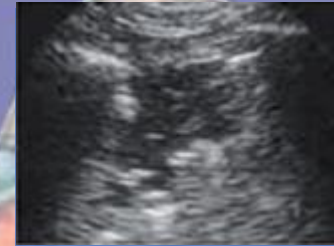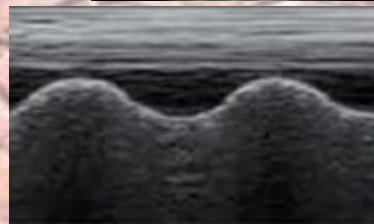A-line



Squad sign



Sinusoid sign



Shred sign

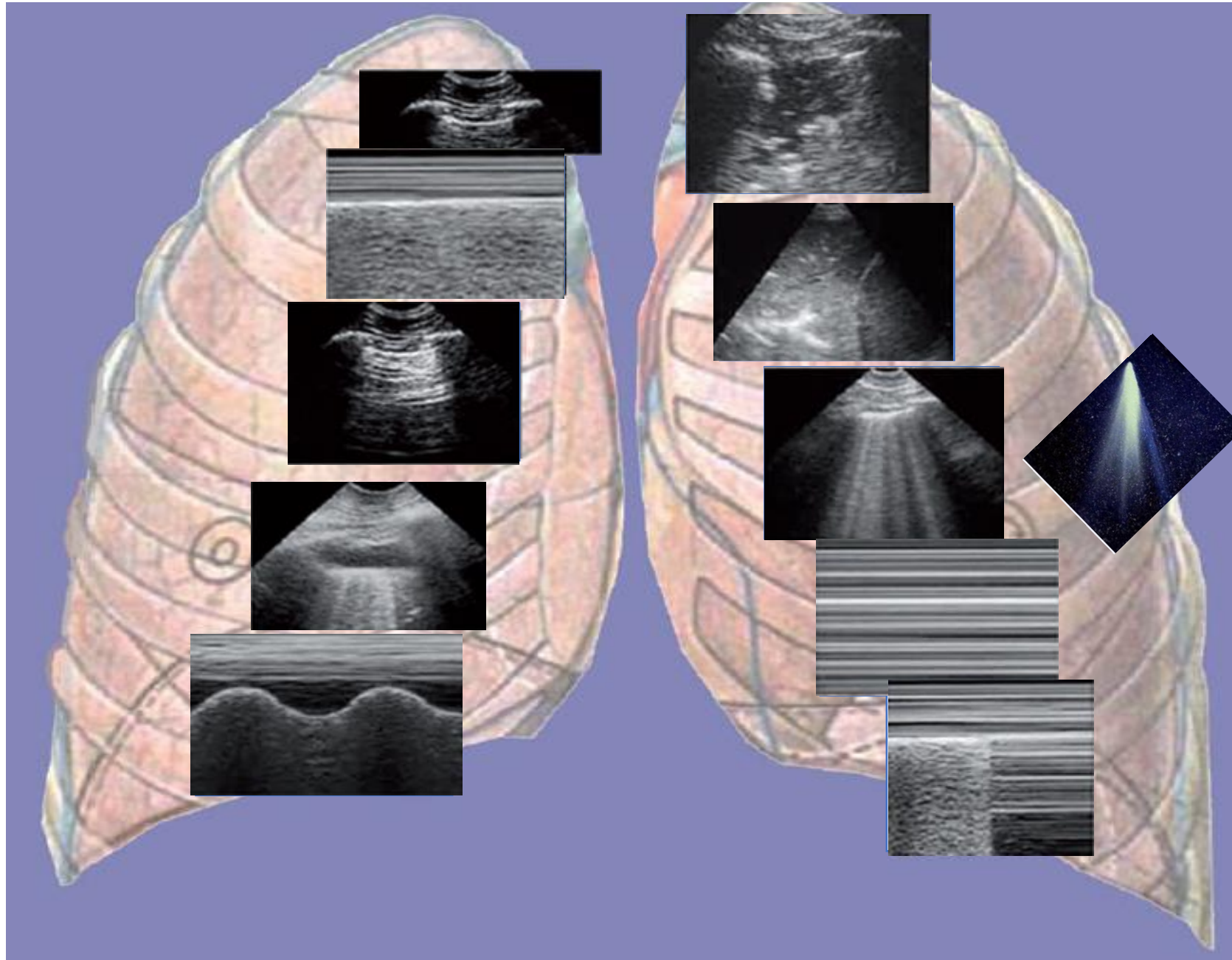

Hepatization

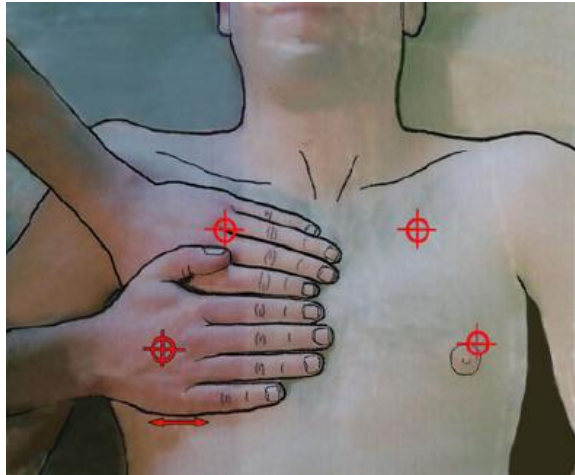
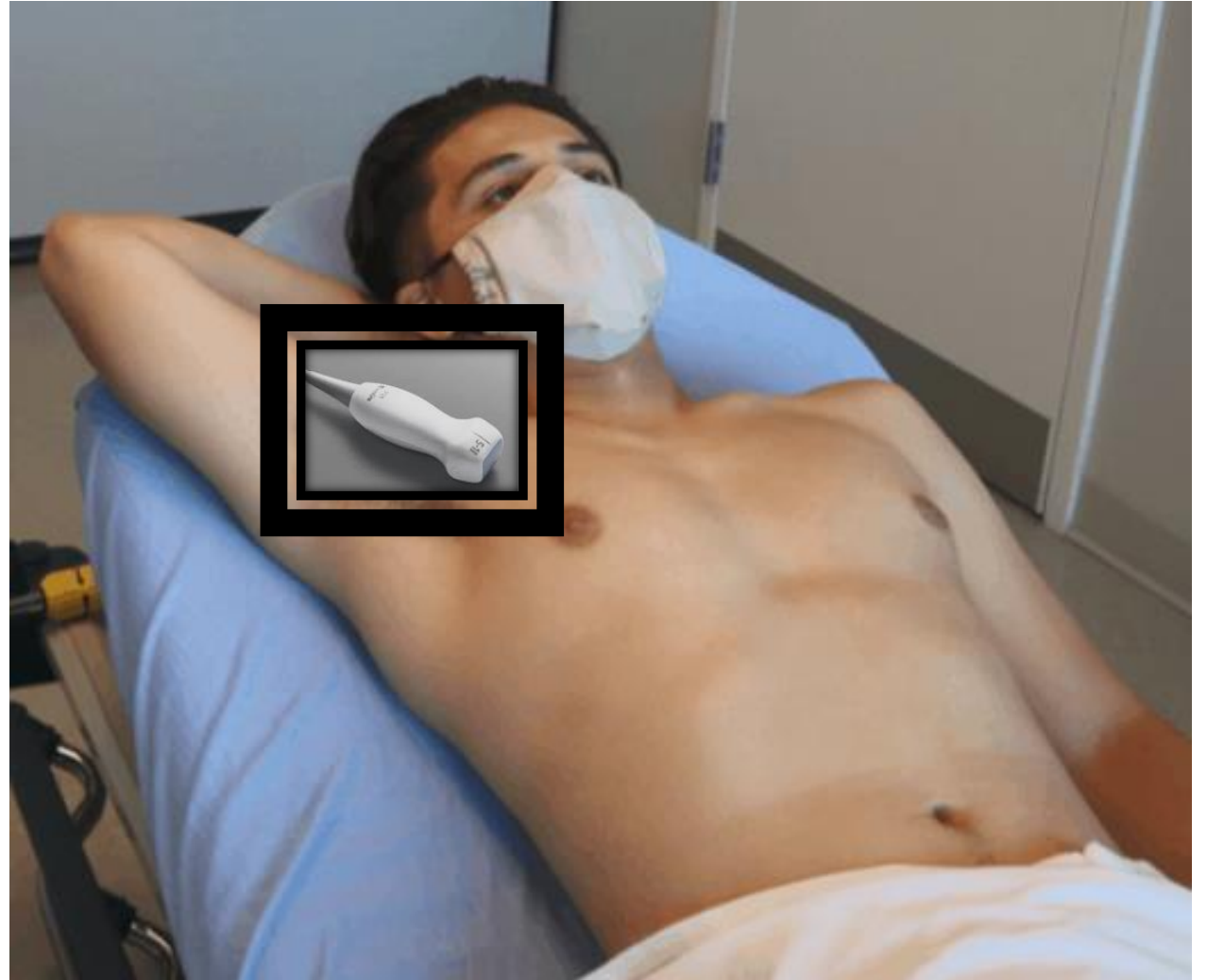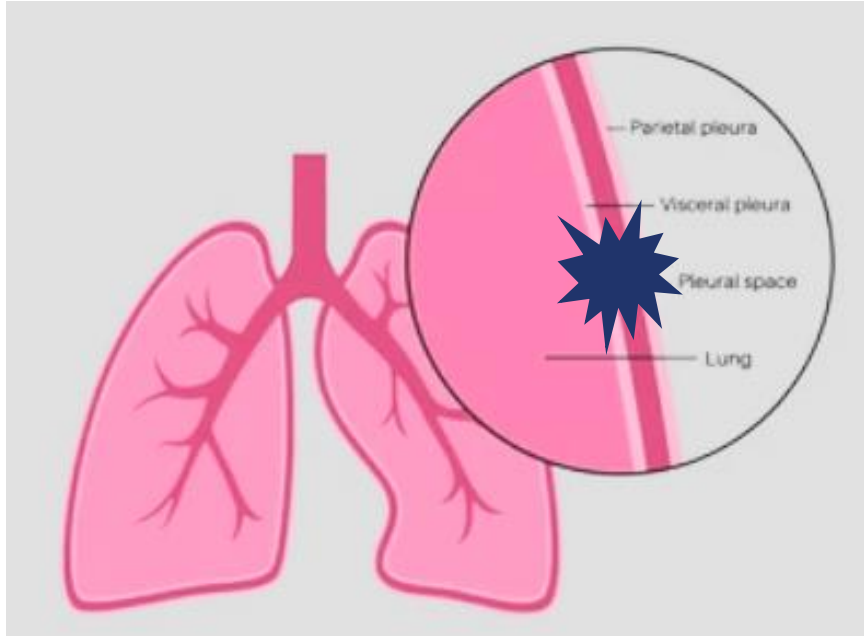
B-line
(comet tail)

Stratosphere sign

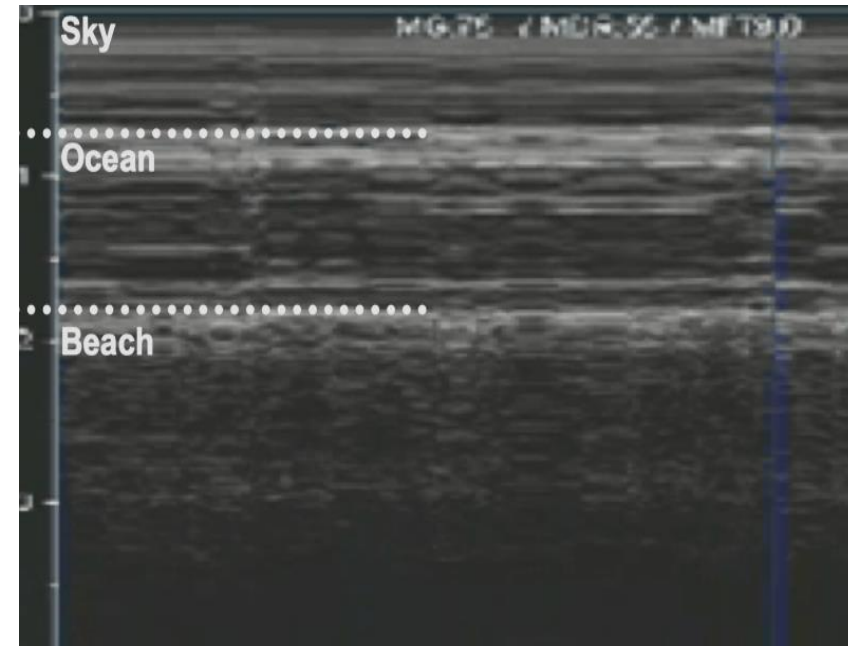
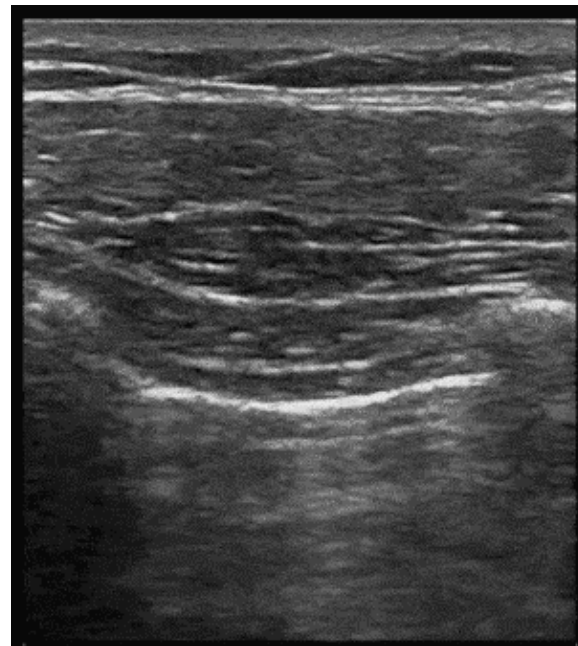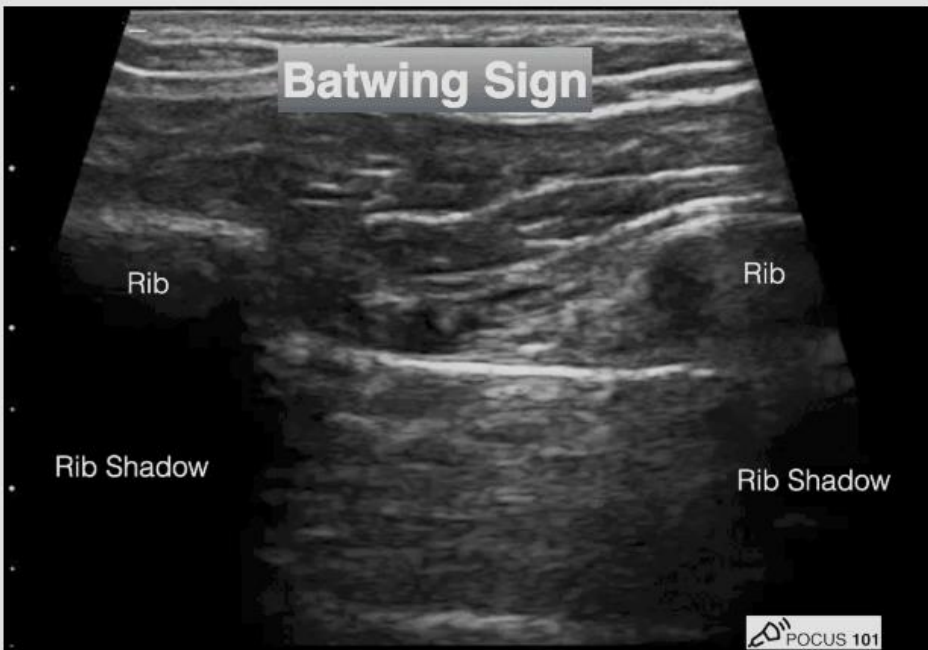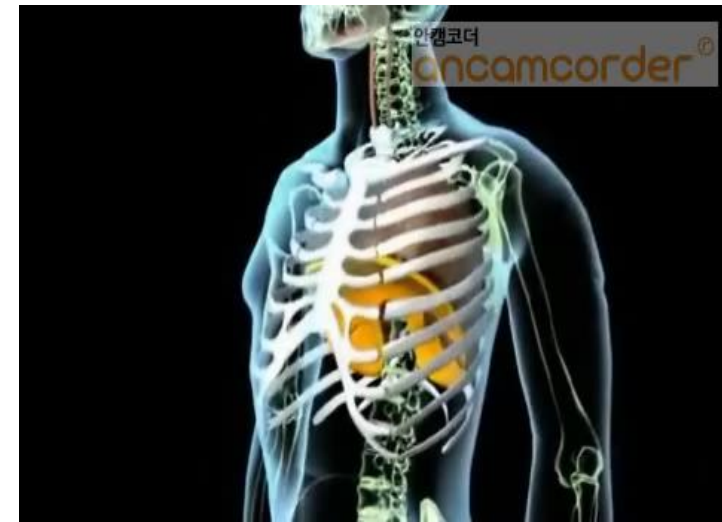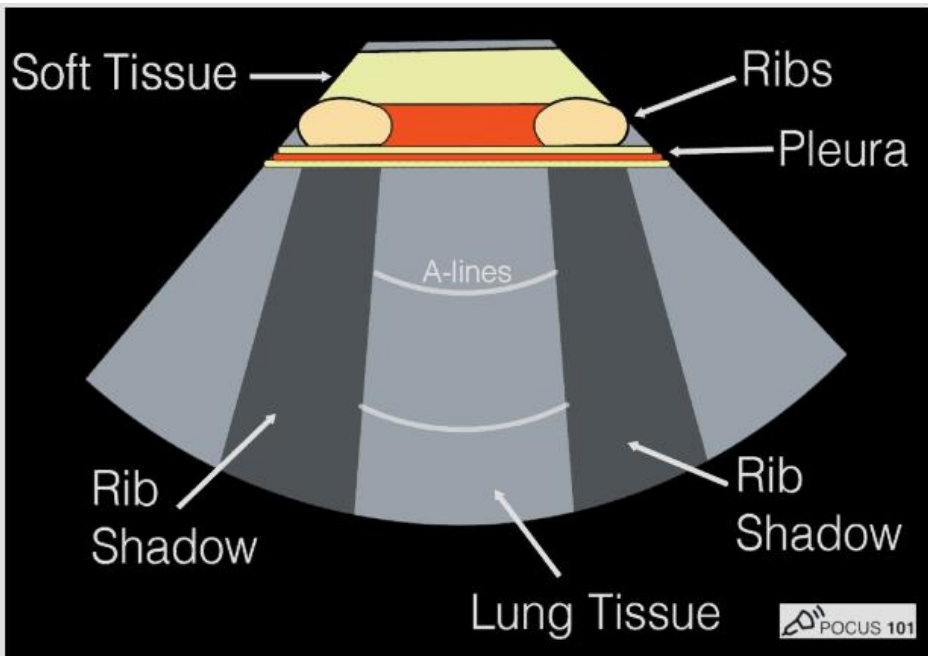


Lung point



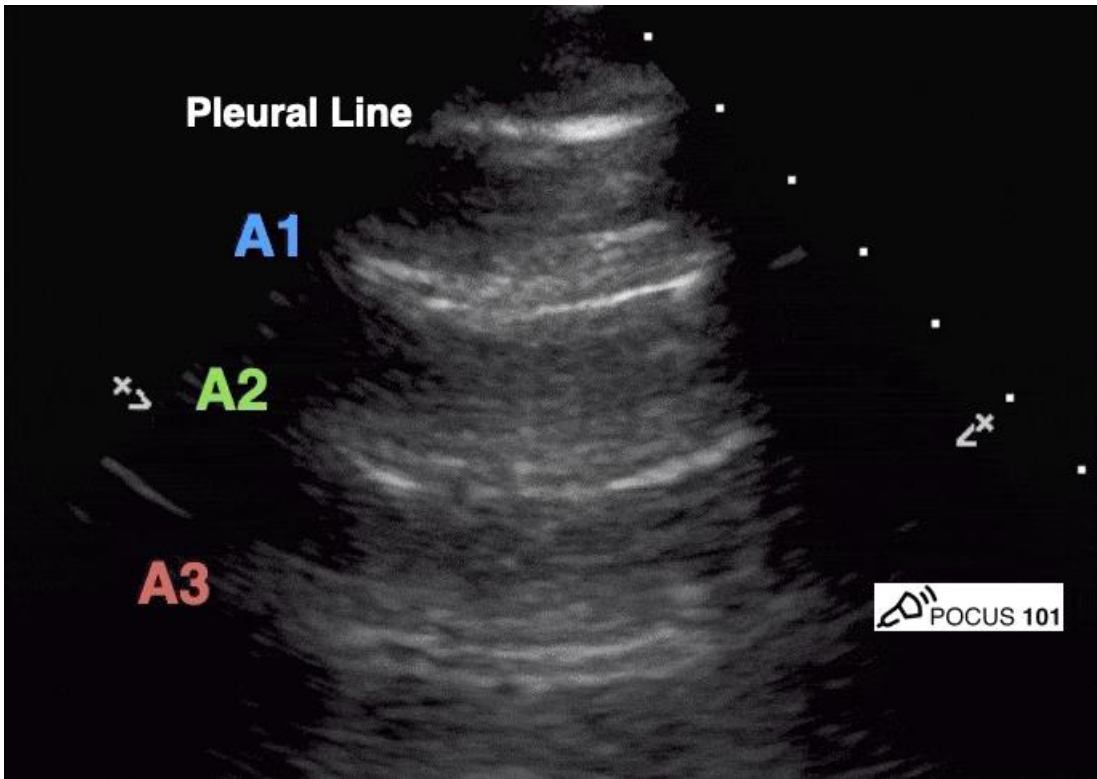
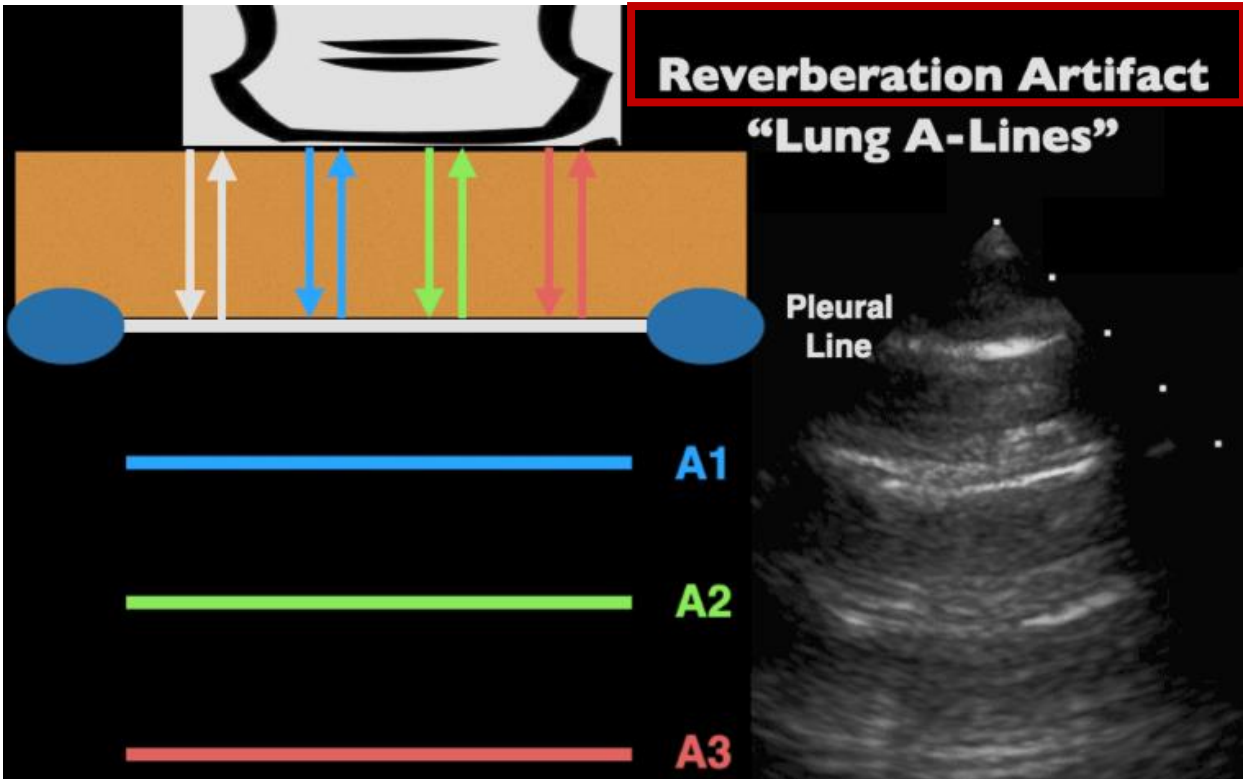


Batwing → A line → lung sliding

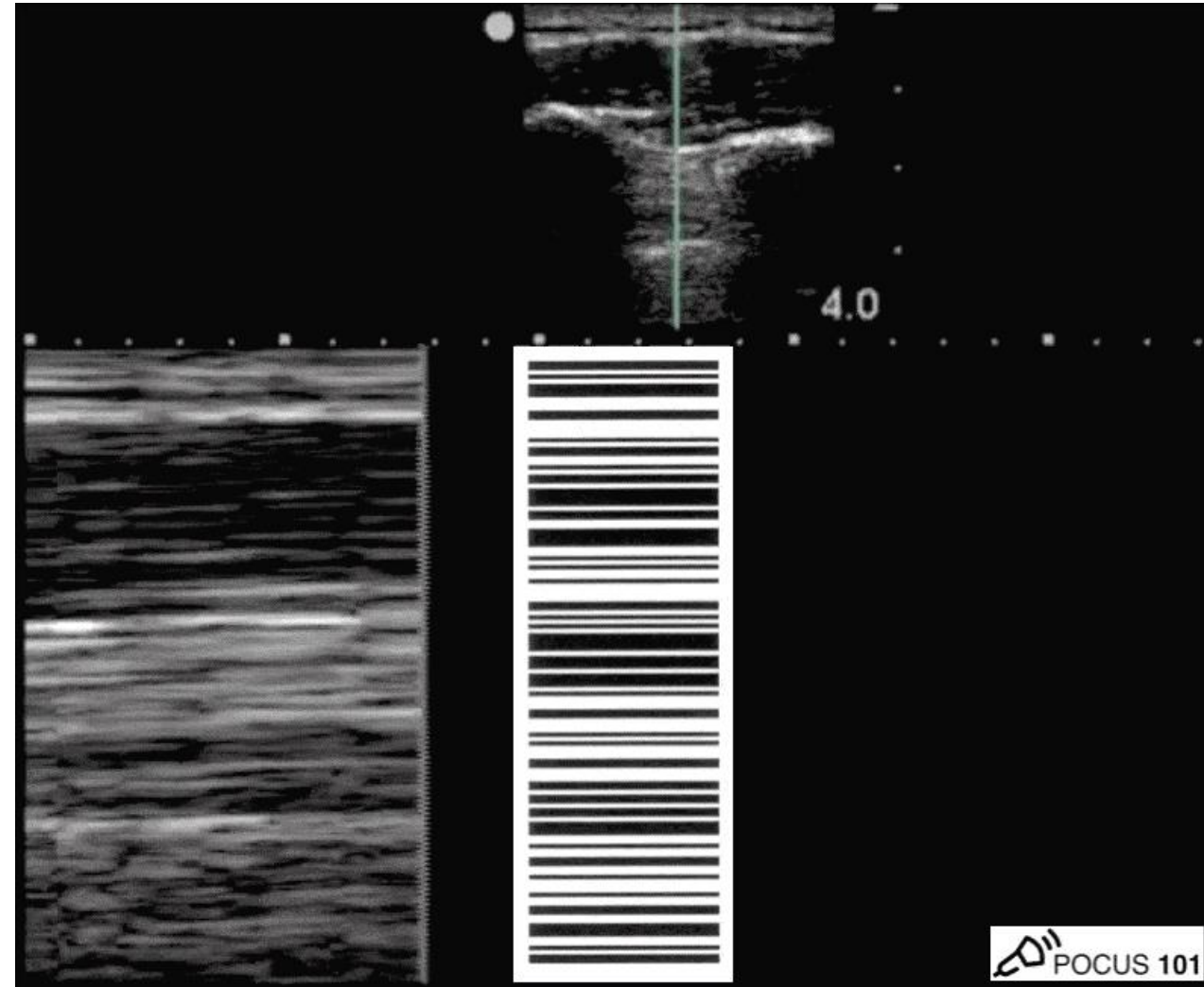
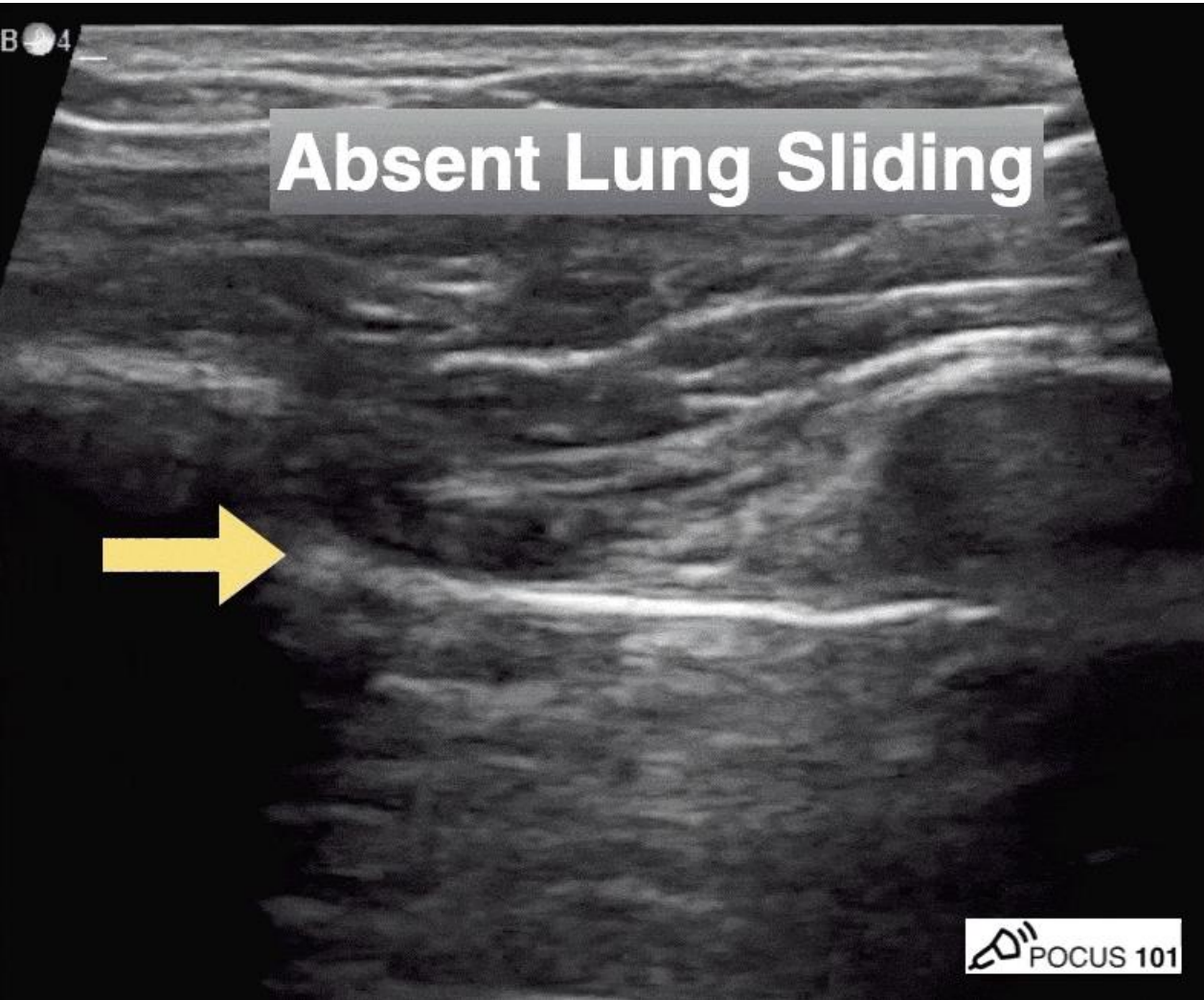


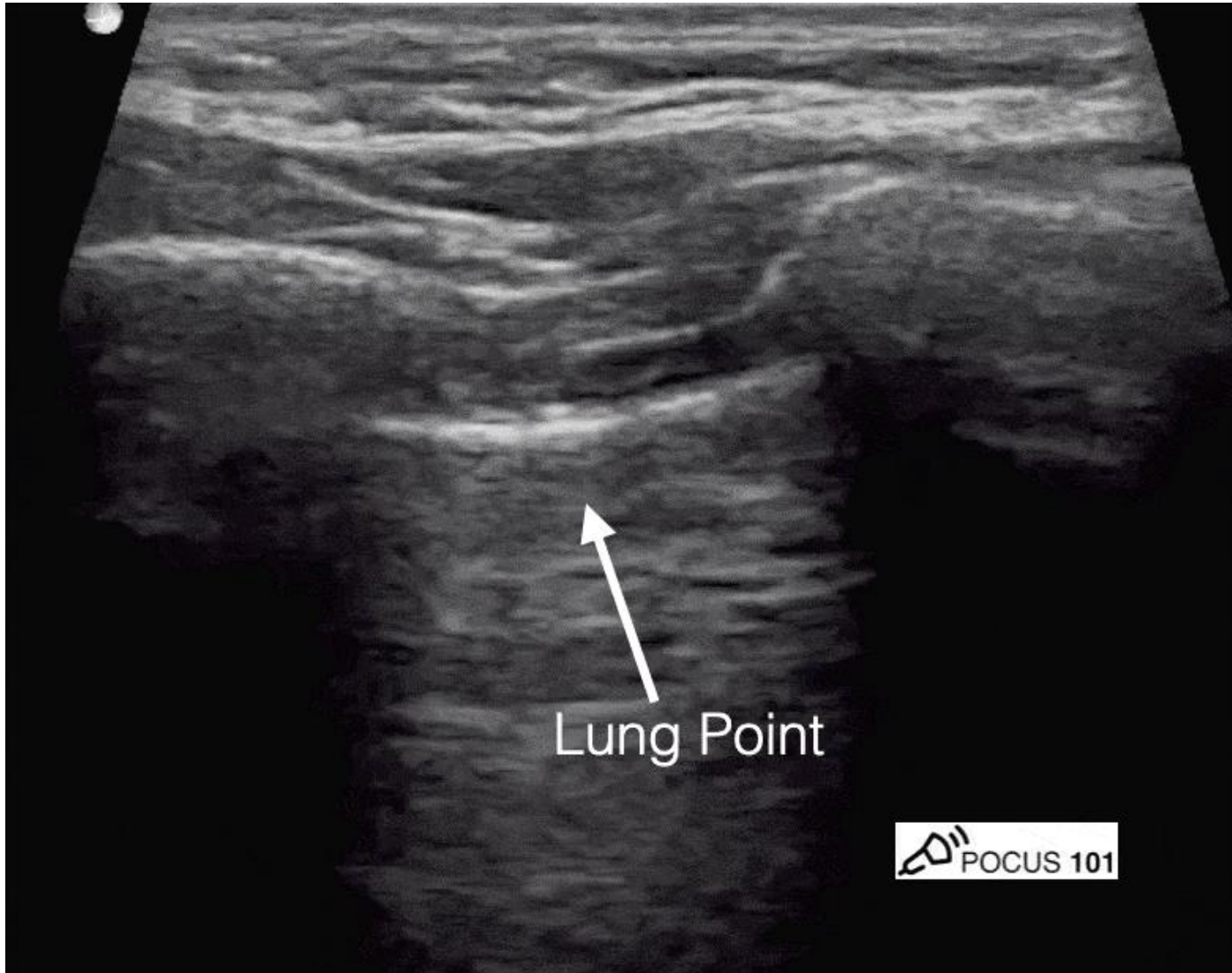
Reverberation Artifact

"Lung A-Lines"

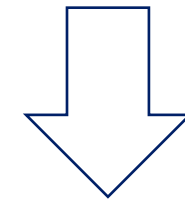


A (B) vs A' (B')



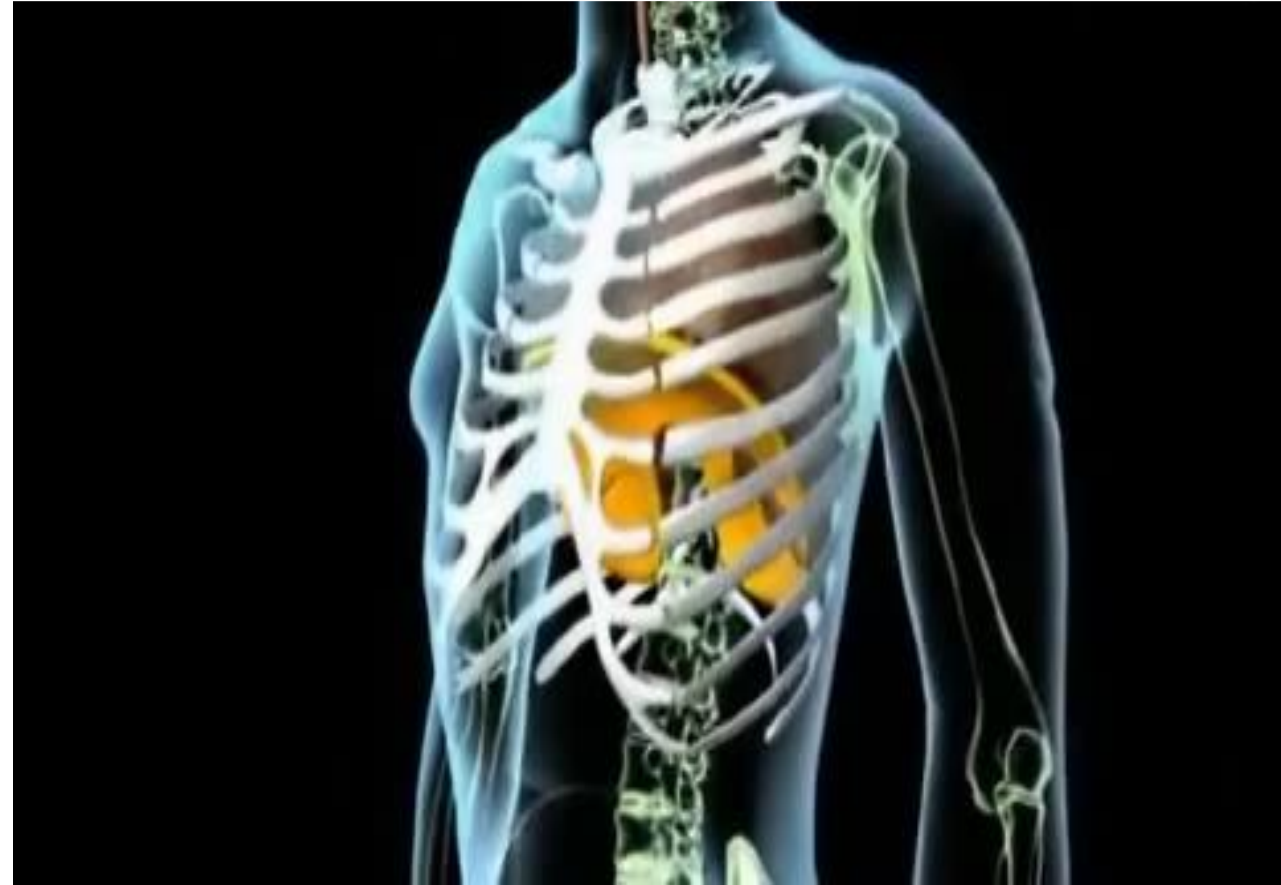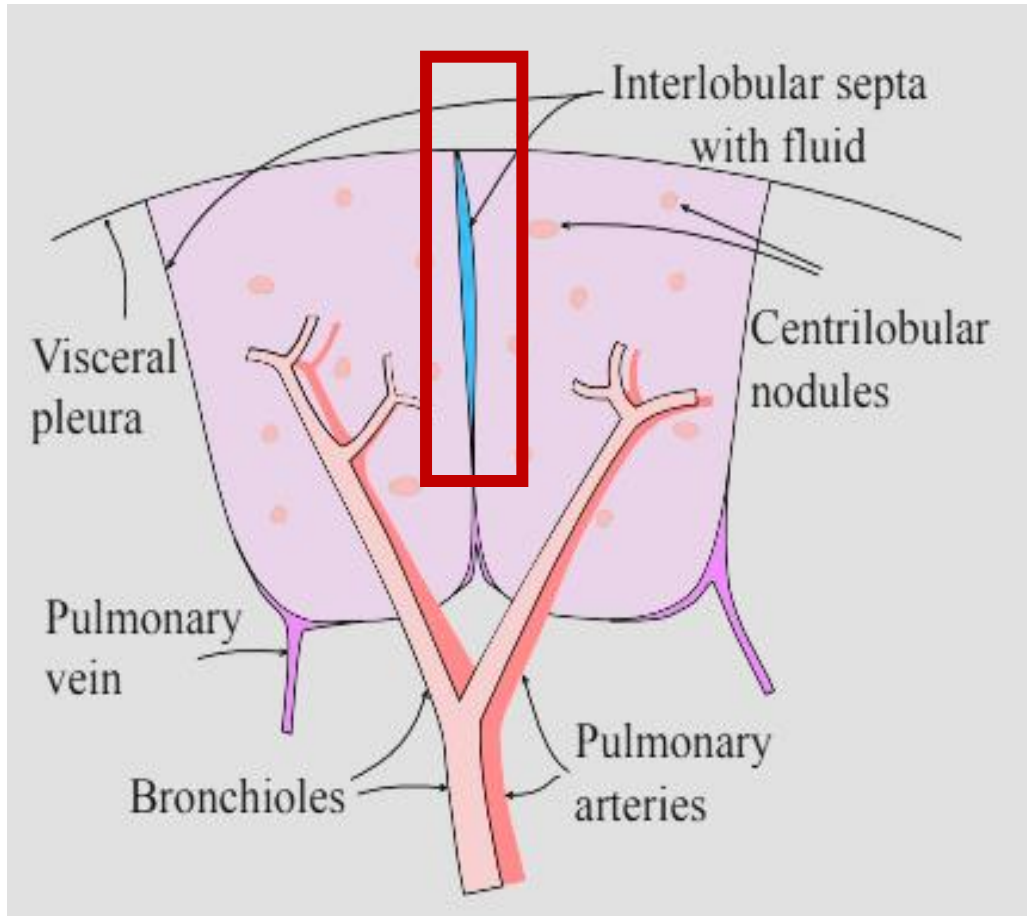


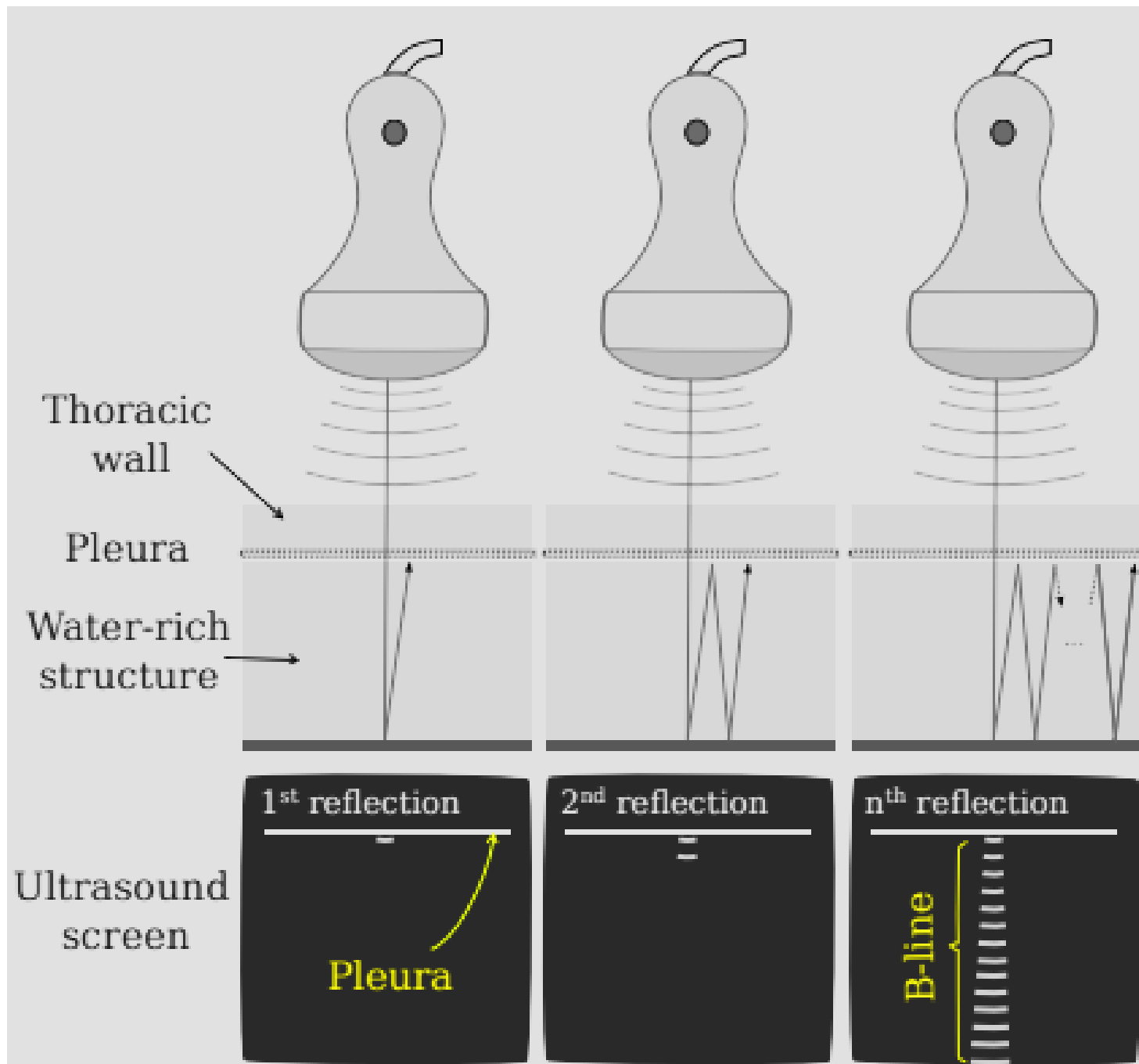
- B line (+)
- Lung pulse (+)
- Definite lung sliding (+)

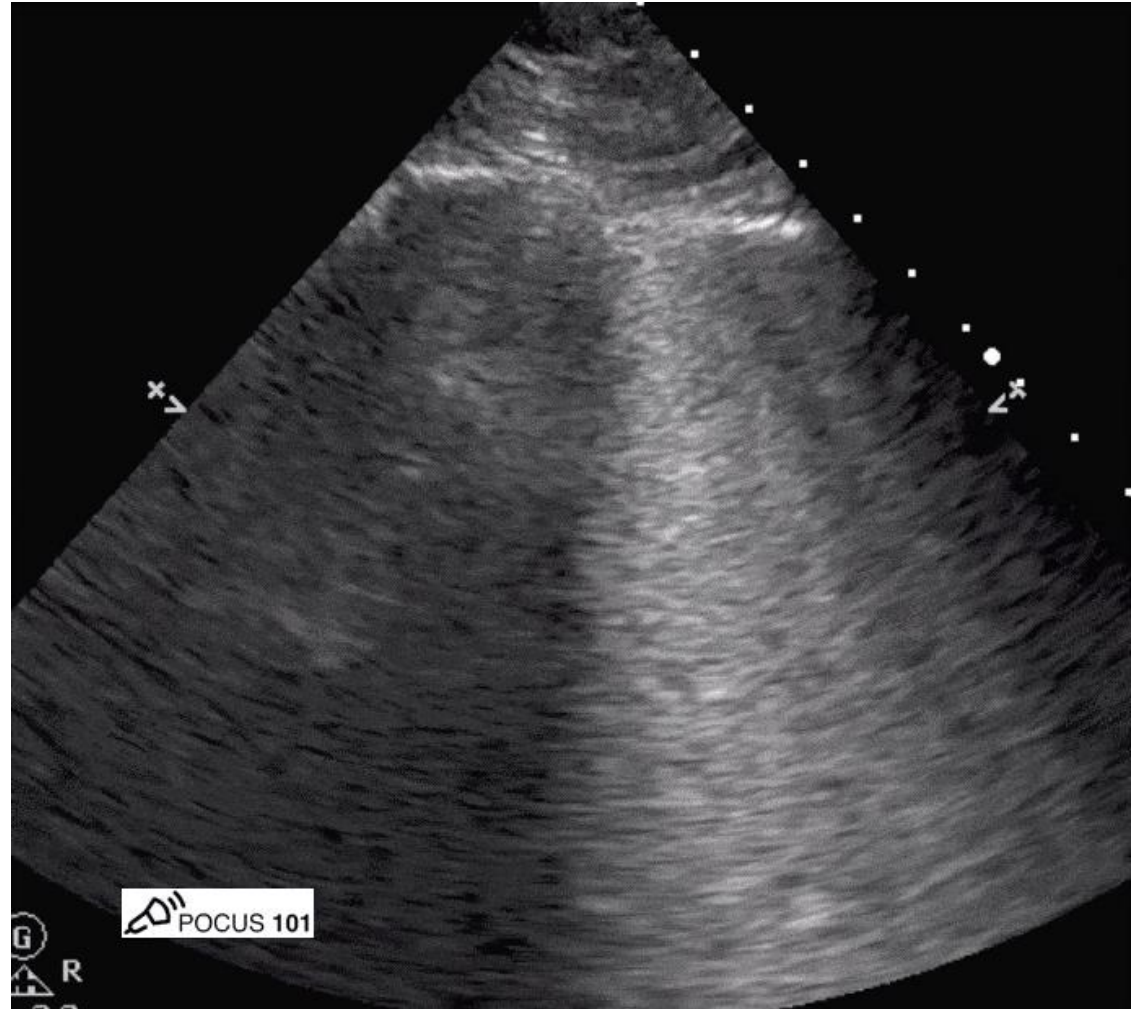
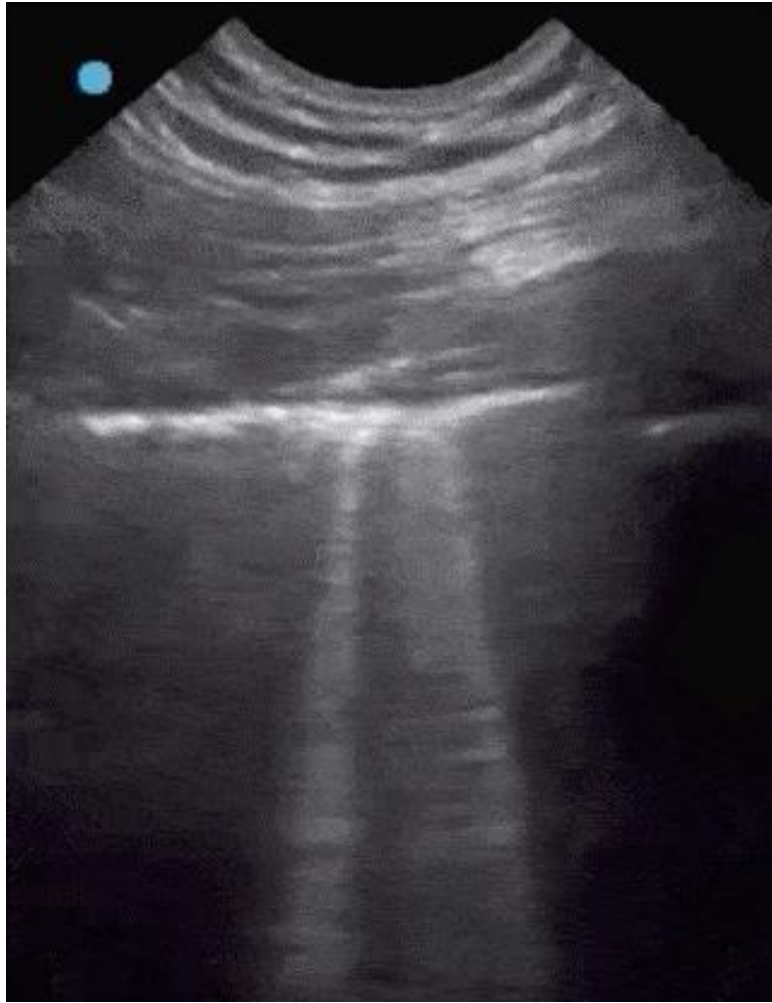

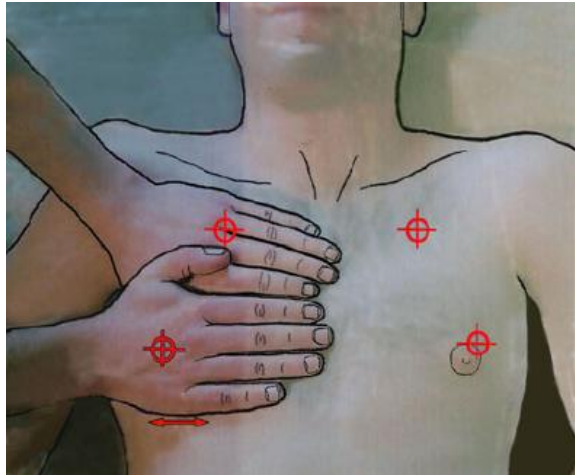
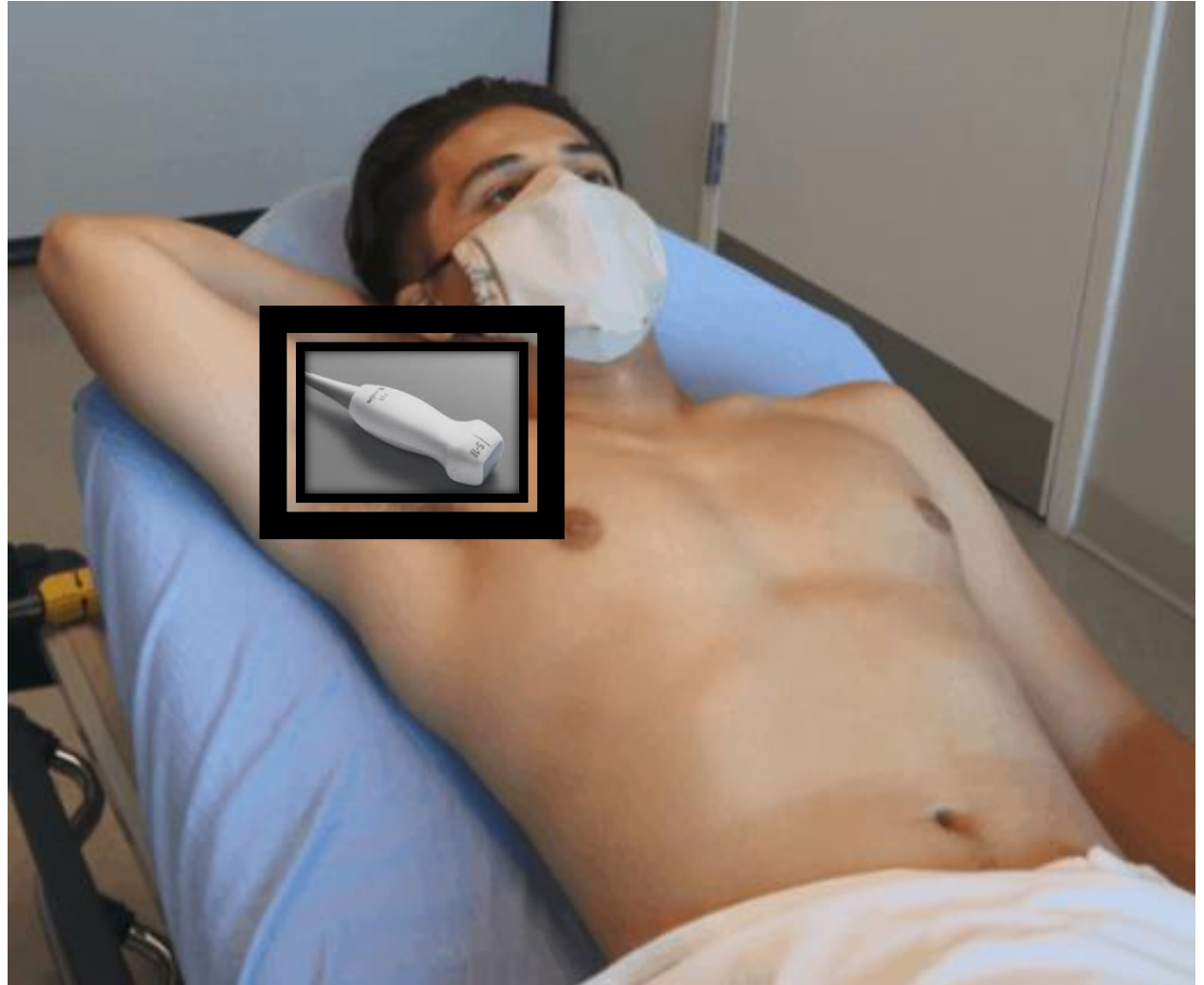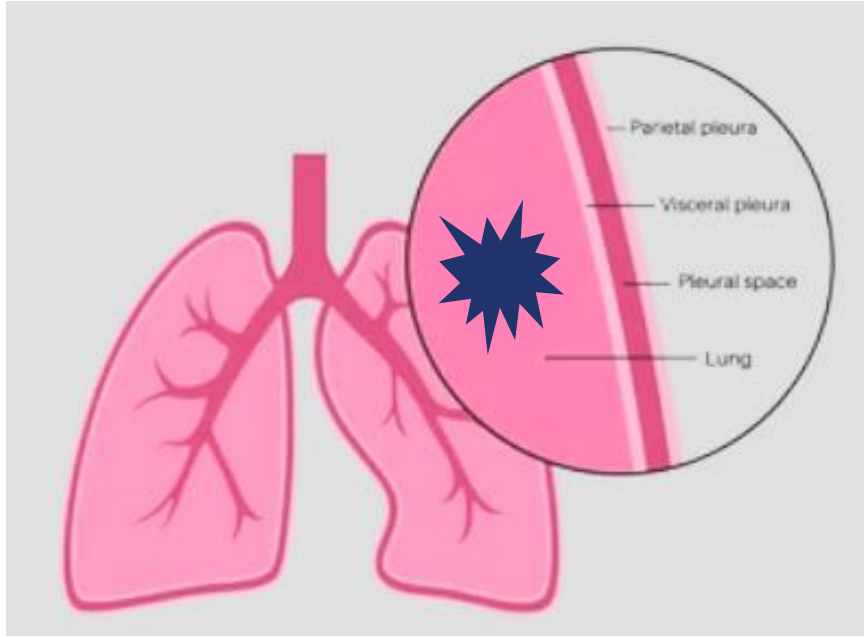
No PNx

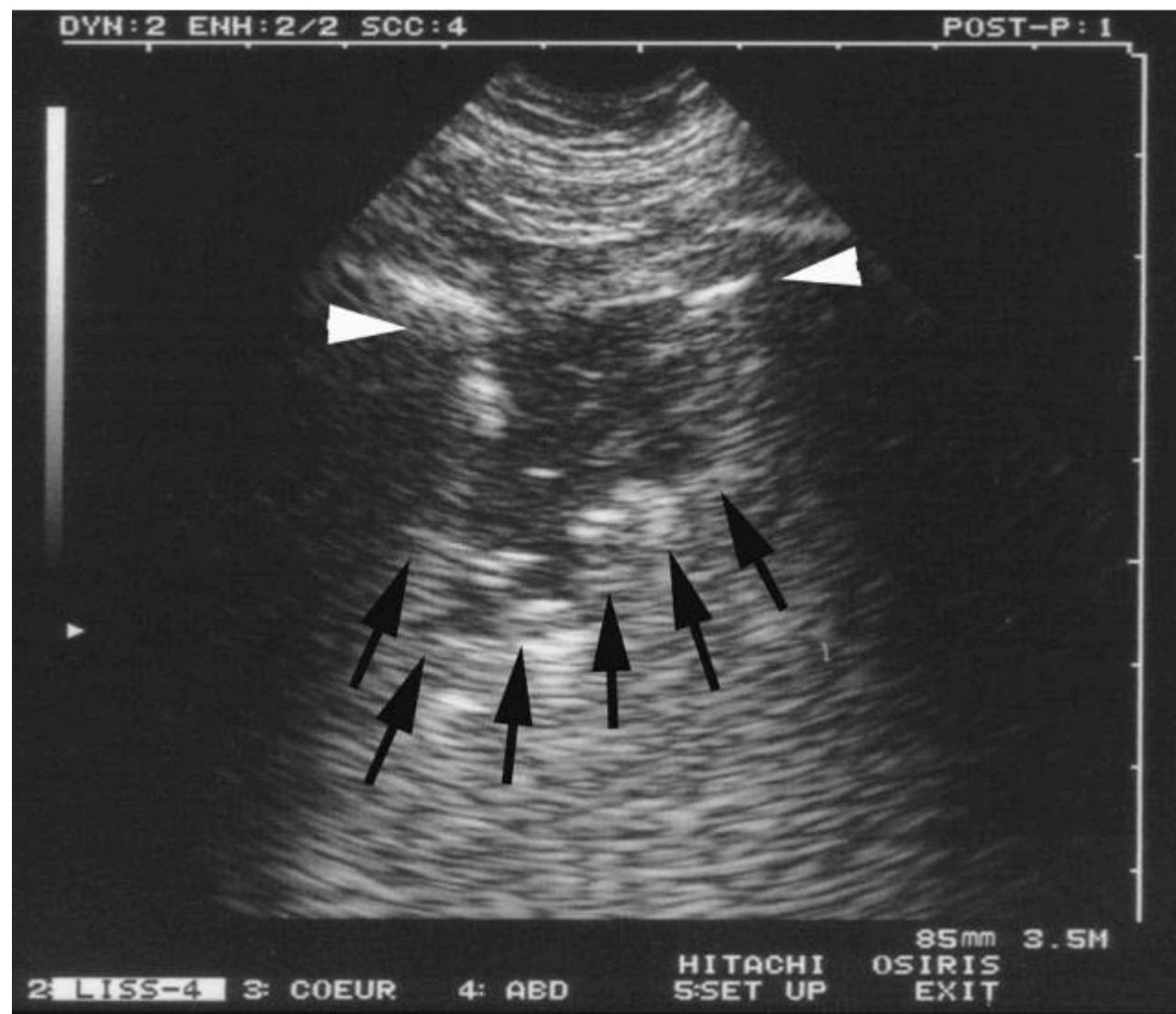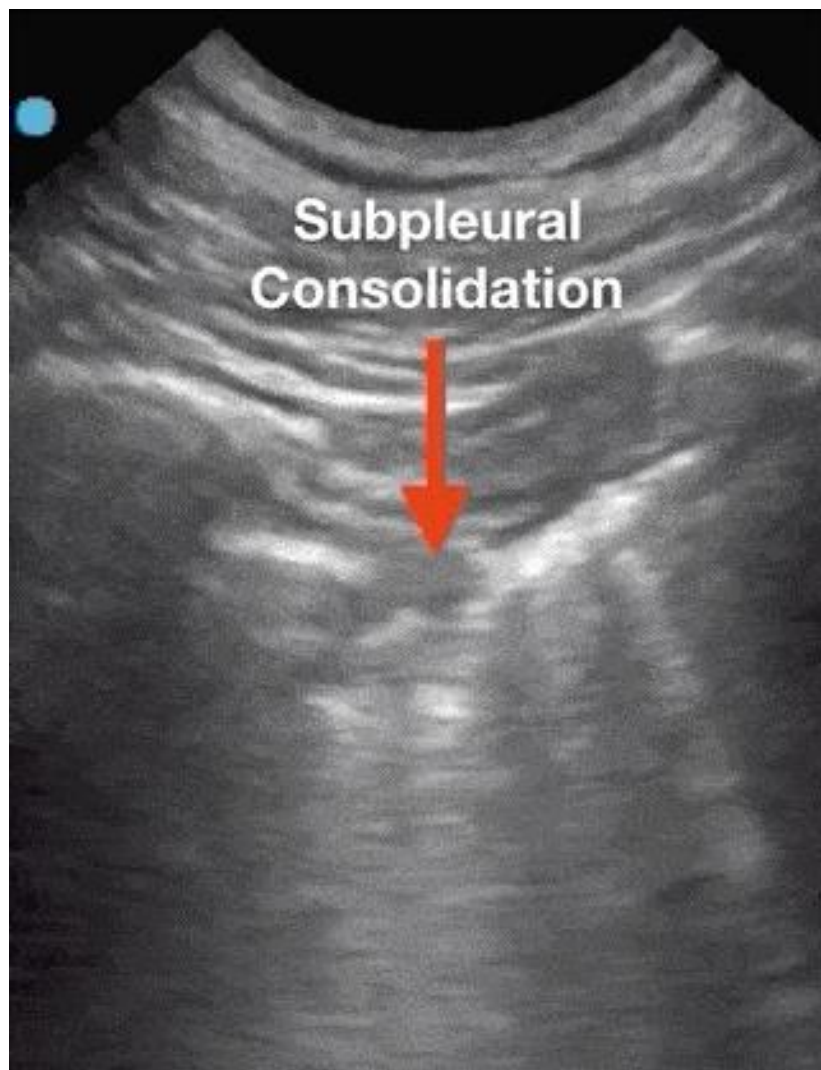
Abnormal : B line $\geq 3 \rightarrow 7\text{mm}$ vs. 3mm apart \rightarrow confluent B line

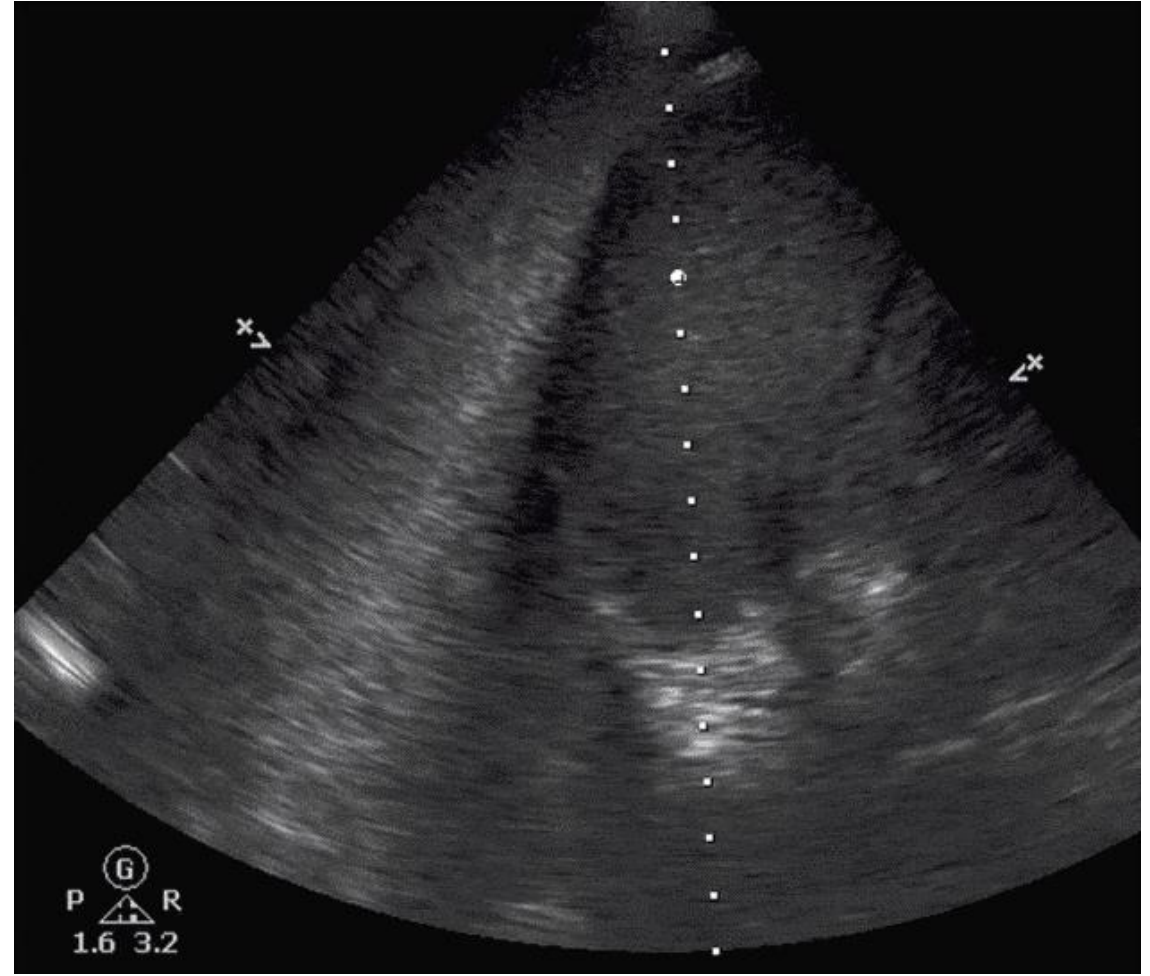
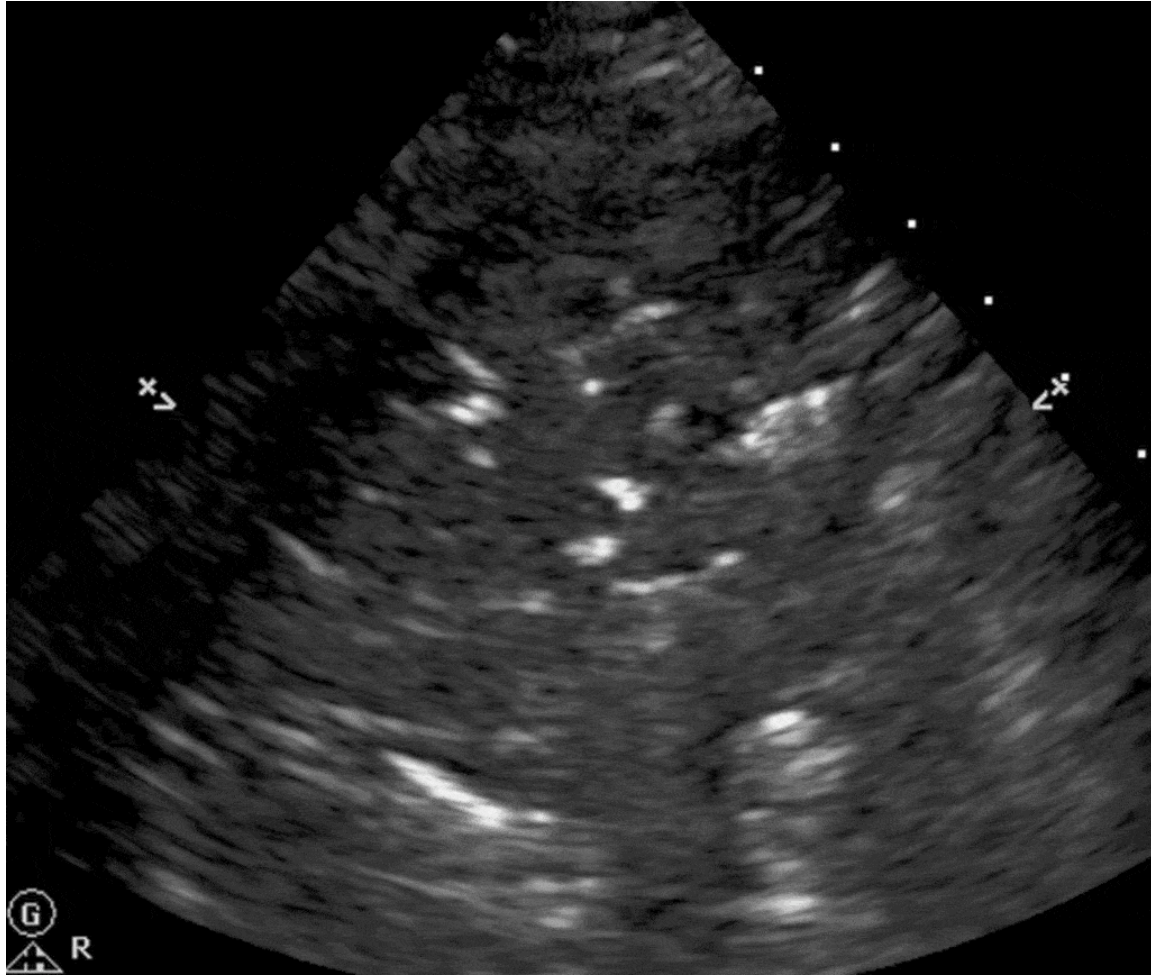


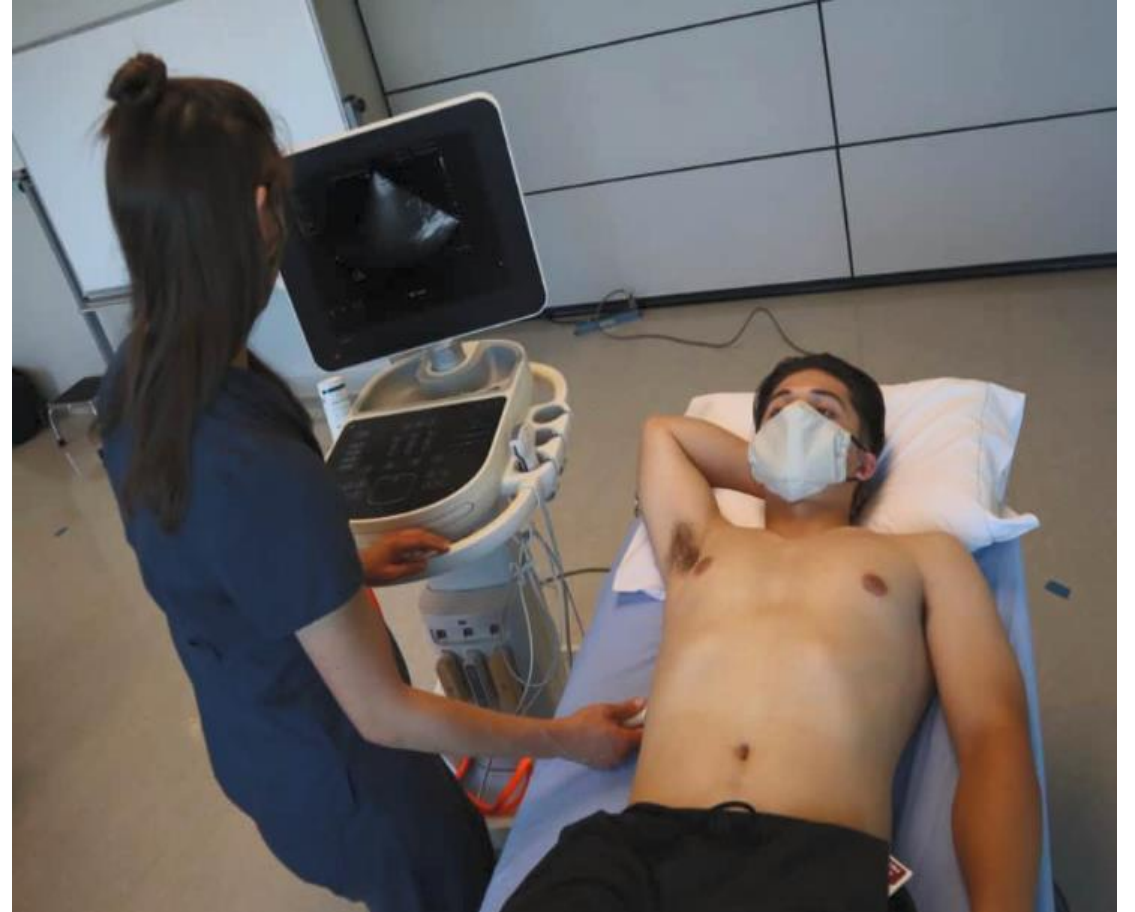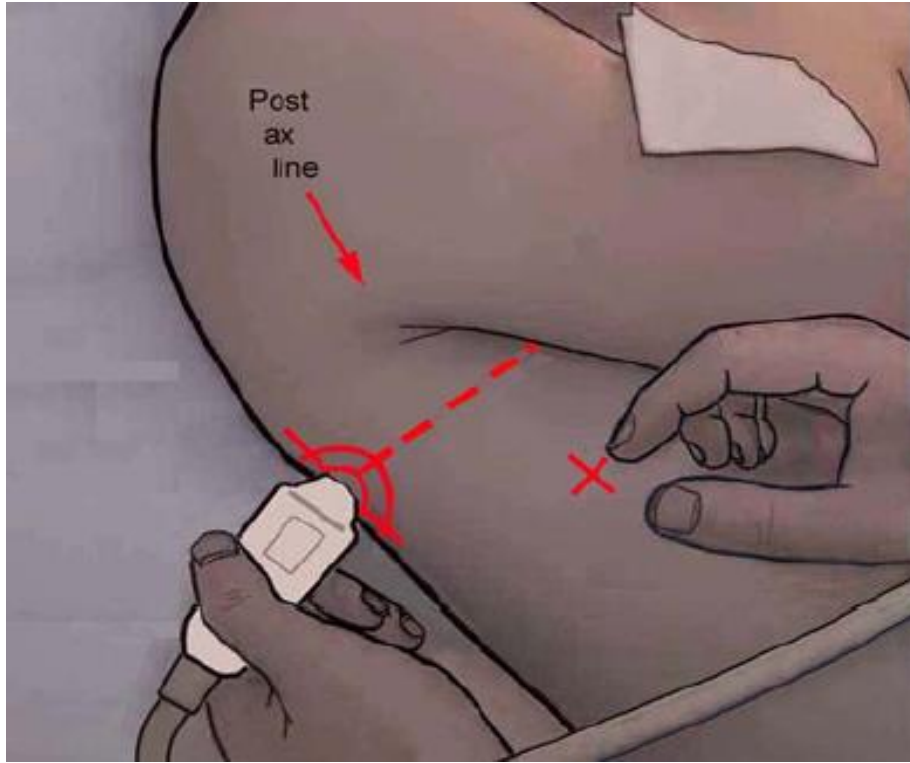


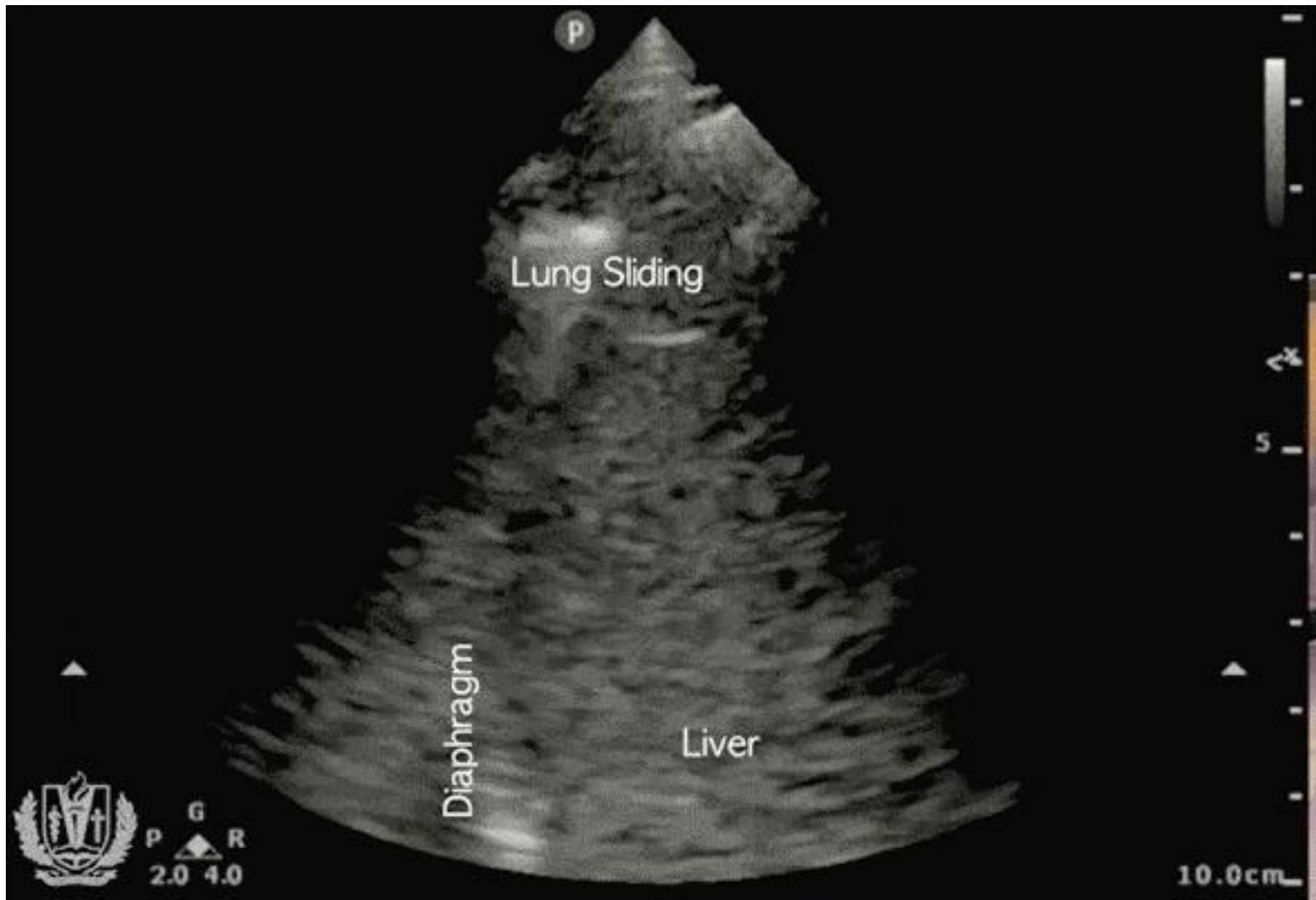




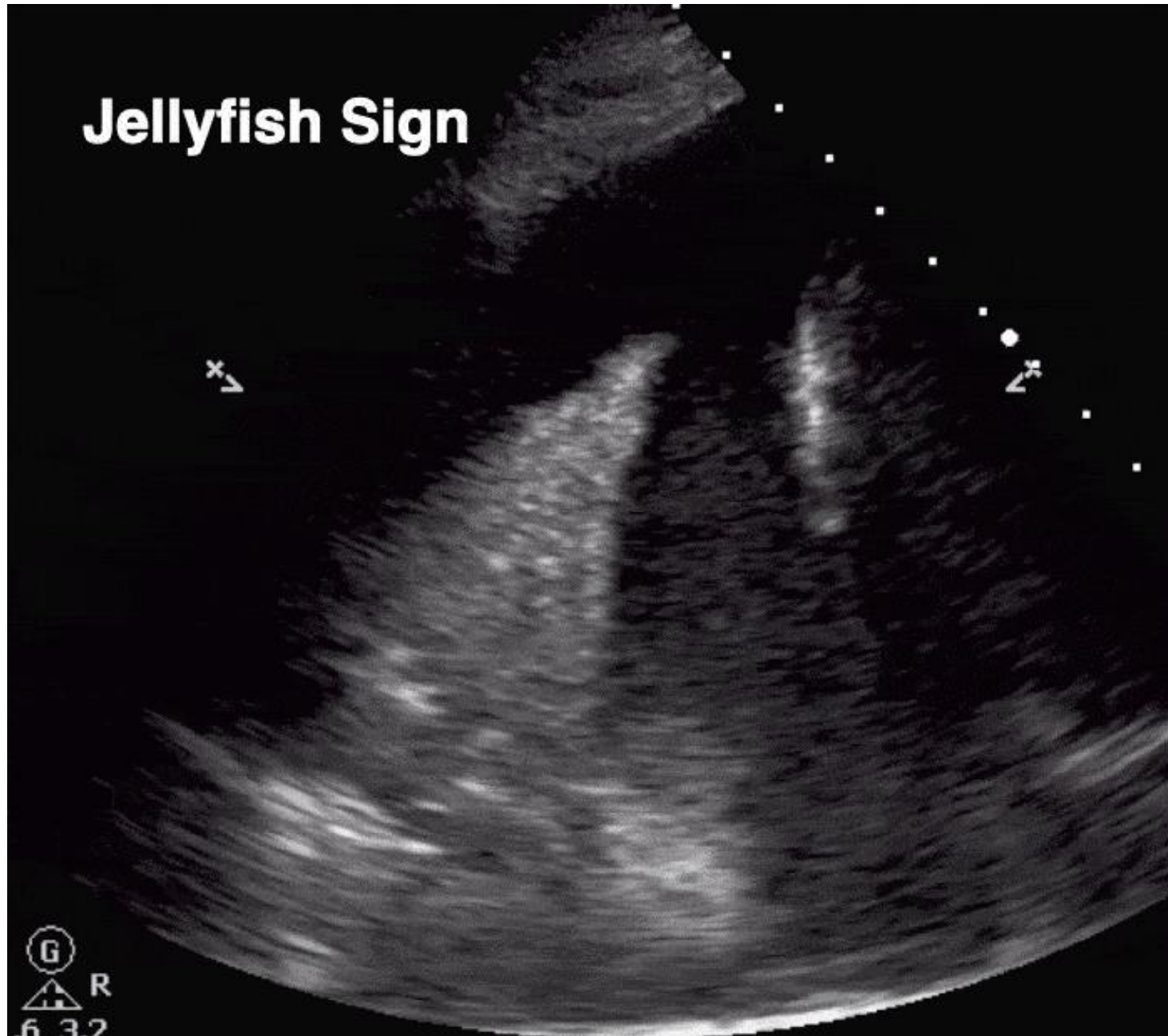




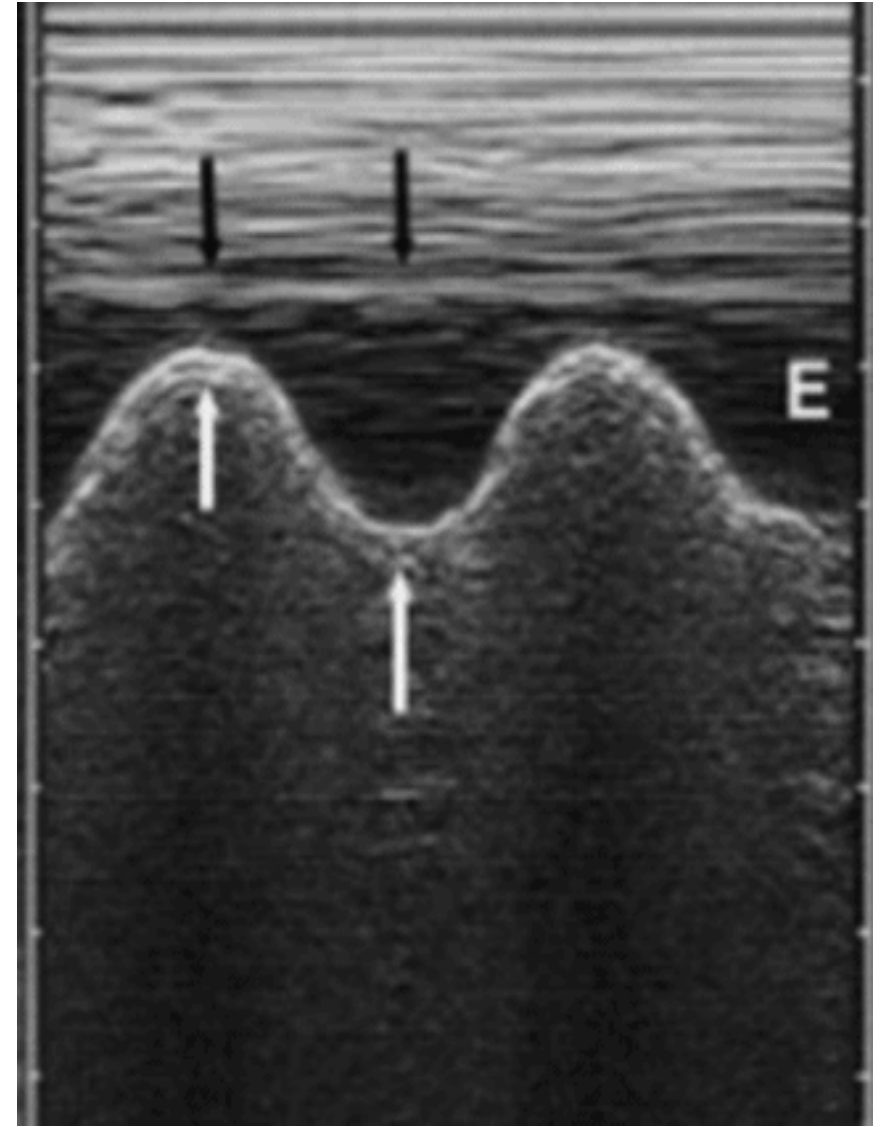
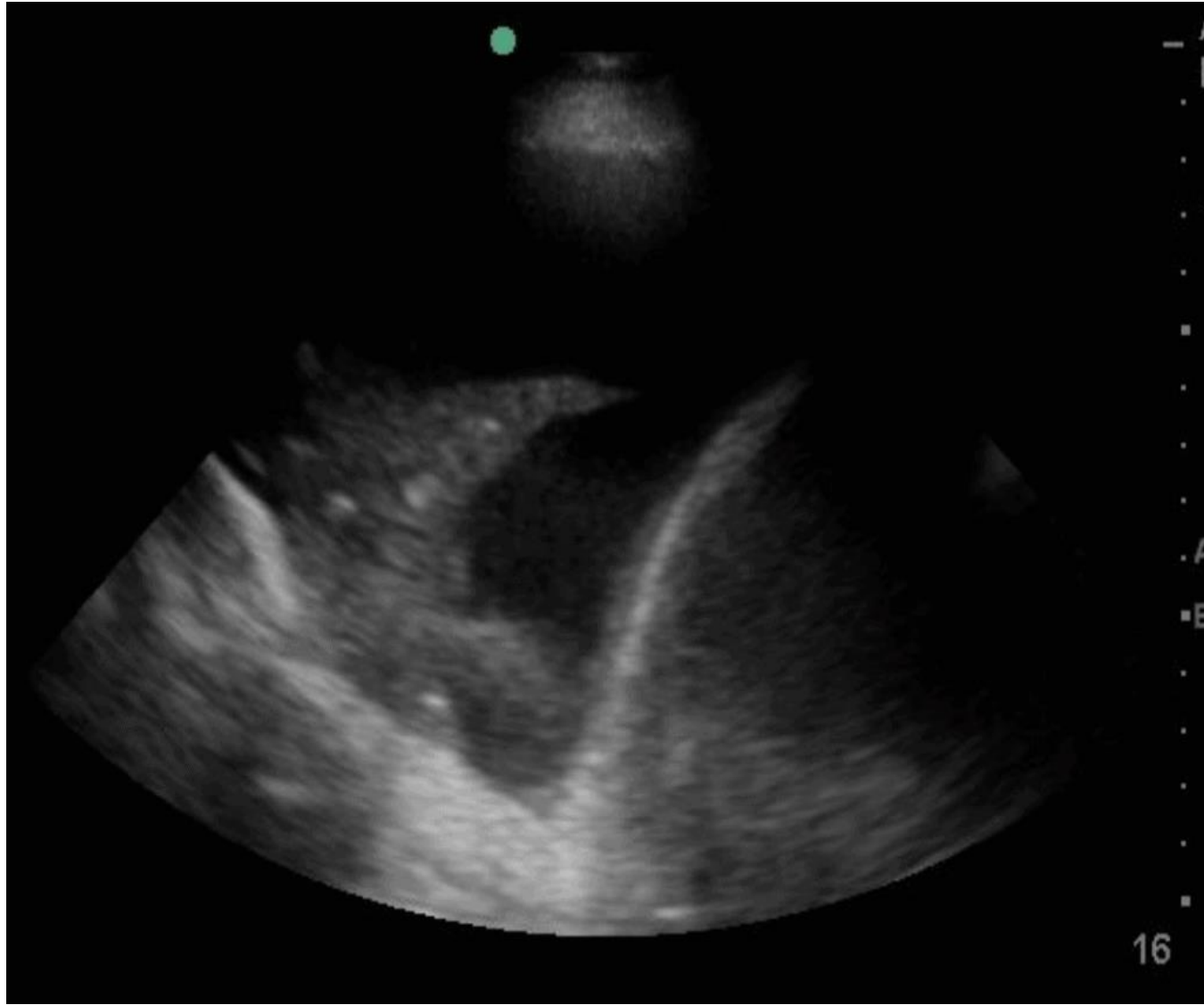


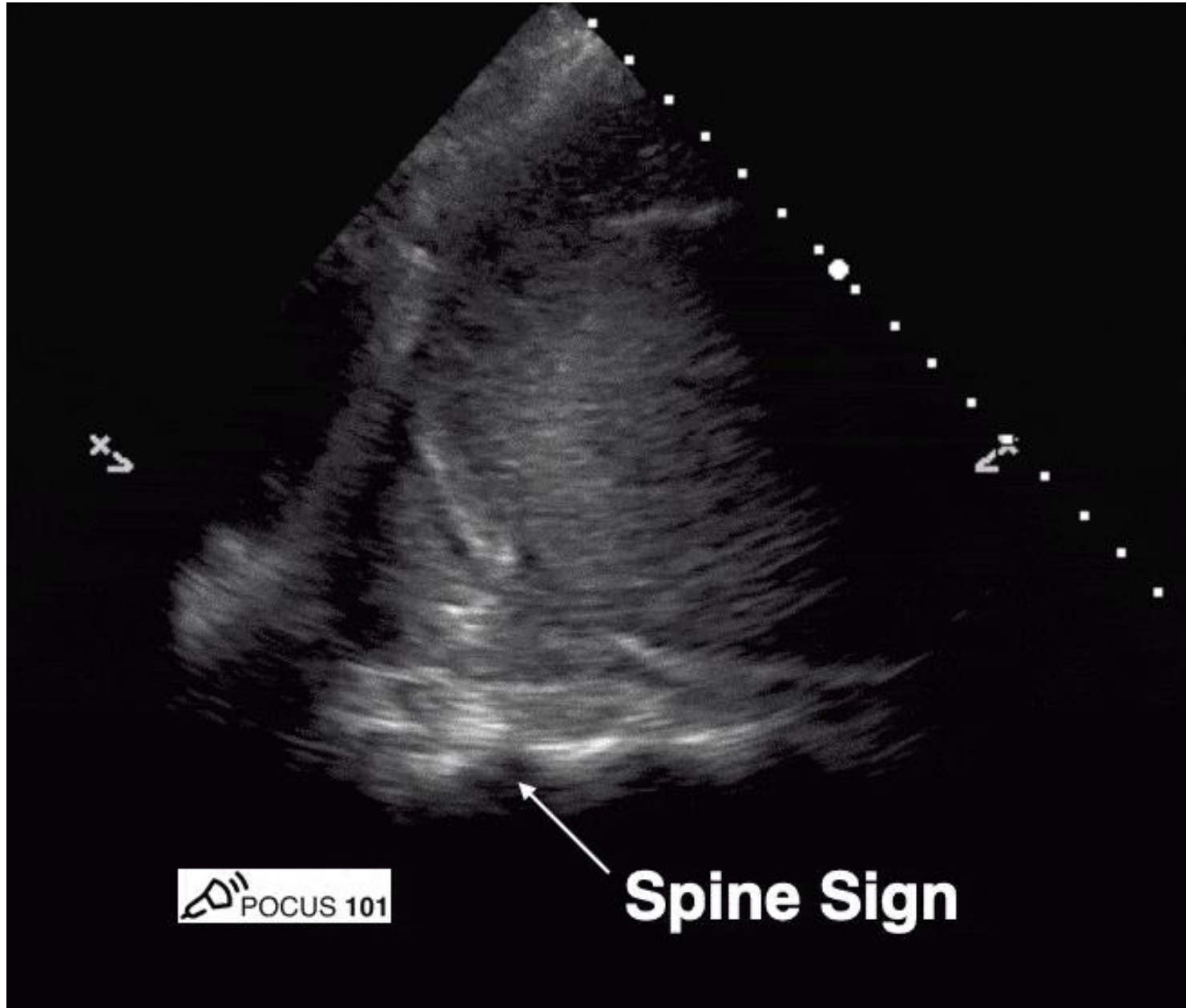


Jellyfish Sign



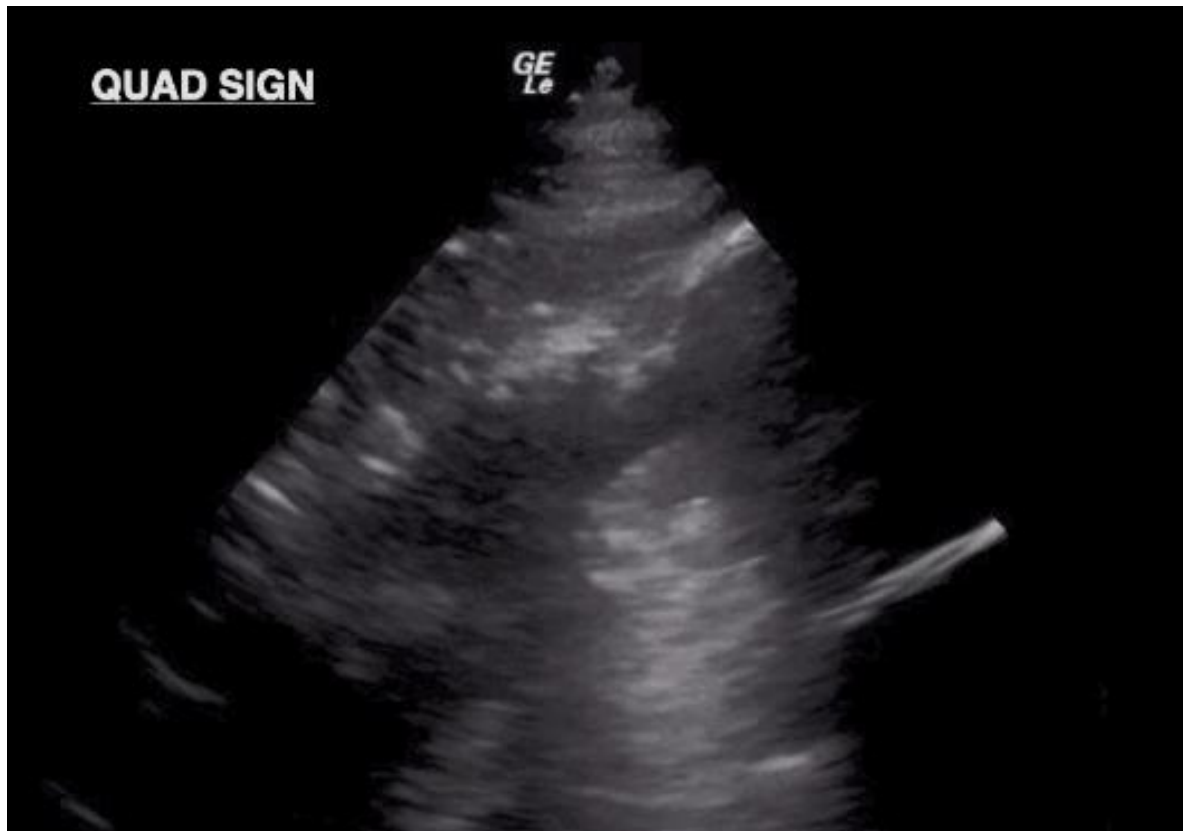
G
R
6.32





QUAD SIGN

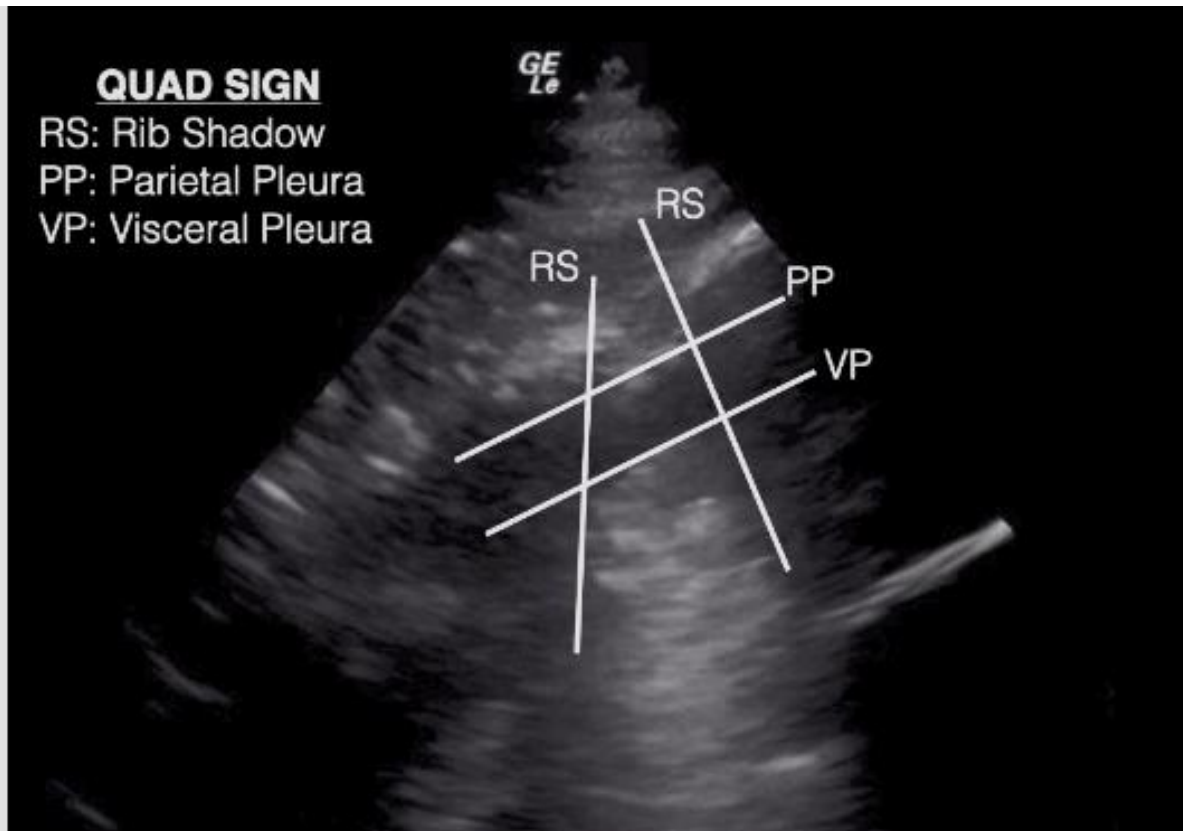
GE
Le



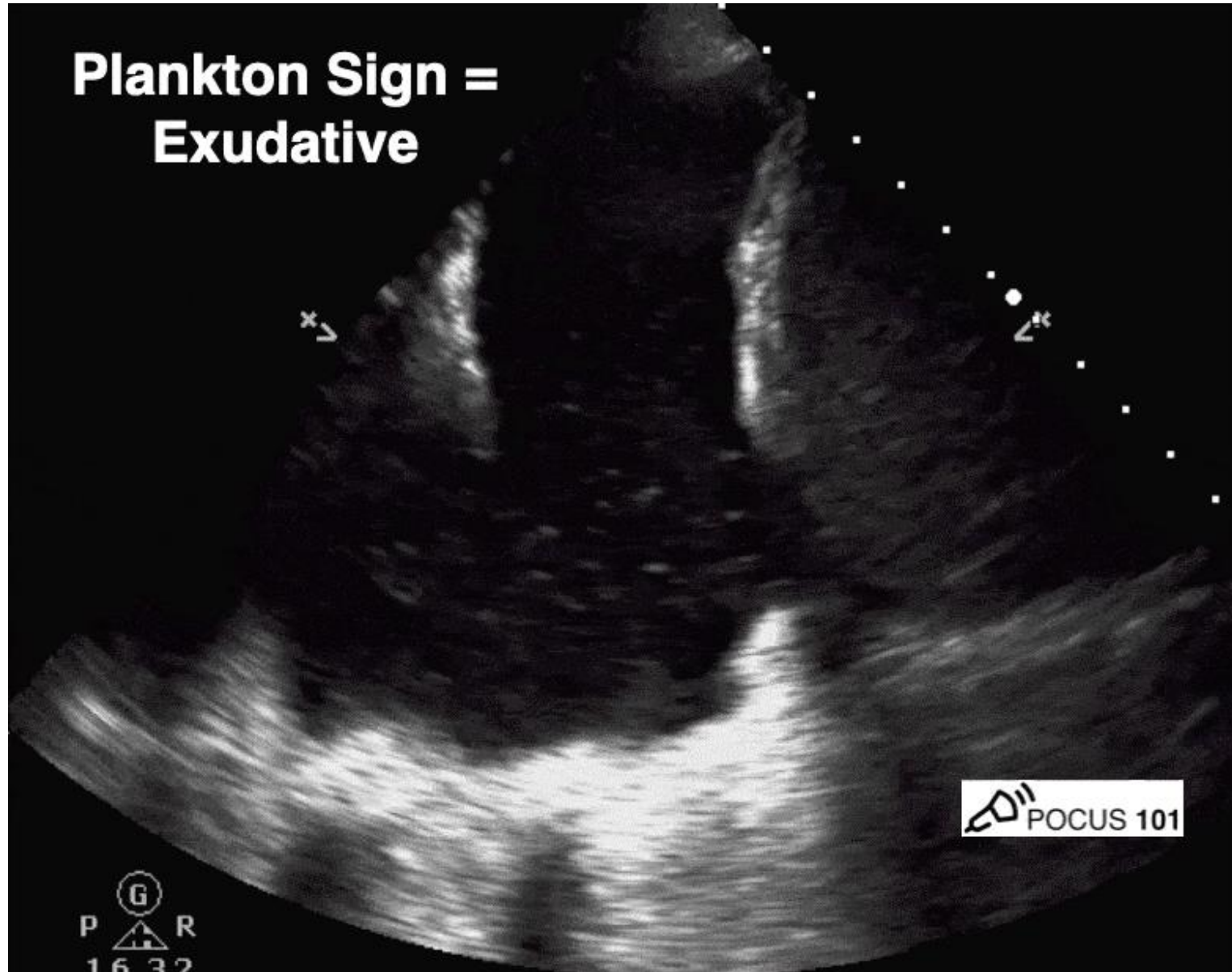QUAD SIGN

RS: Rib Shadow
PP: Parietal Pleura
VP: Visceral Pleura

GE
Le

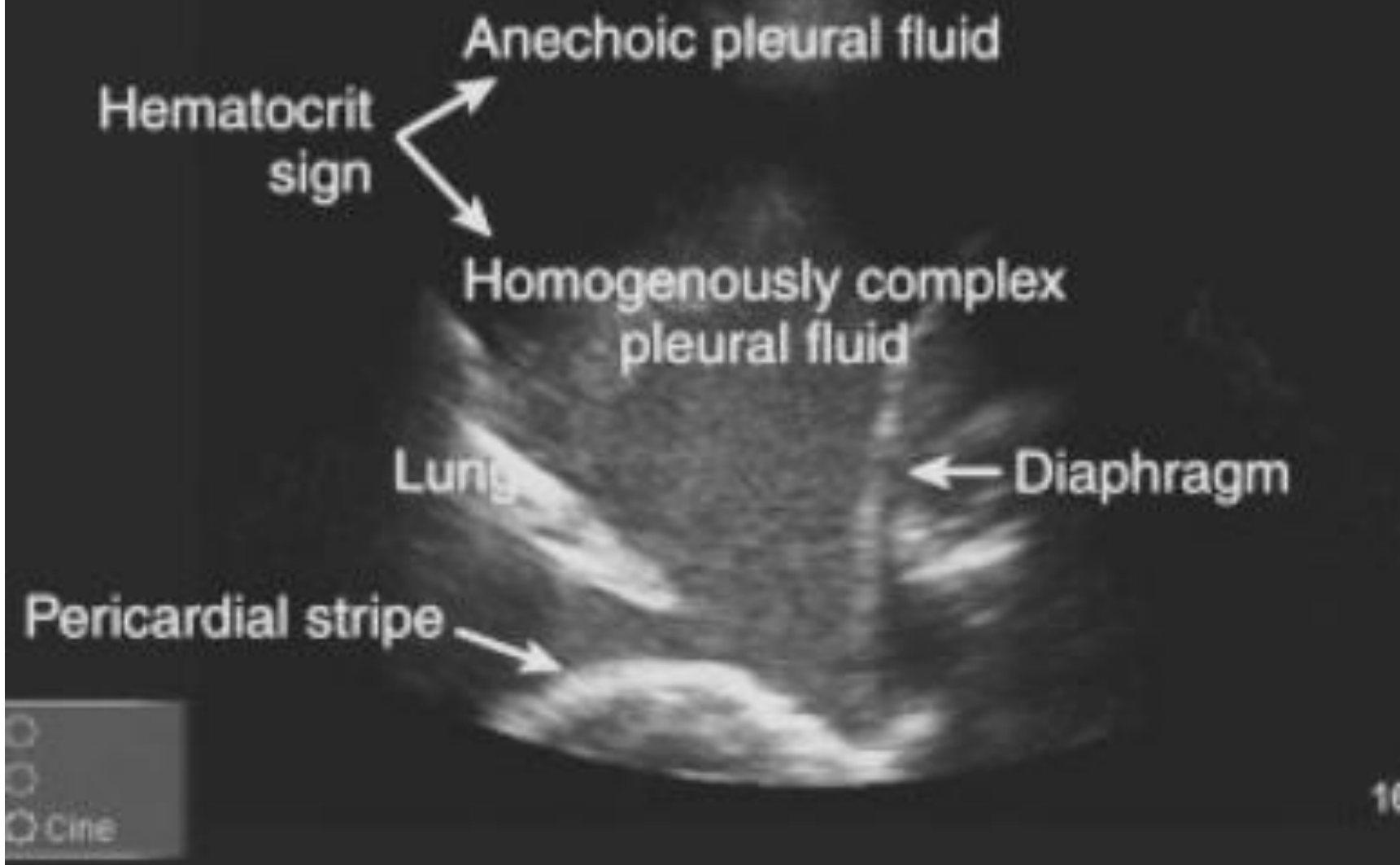


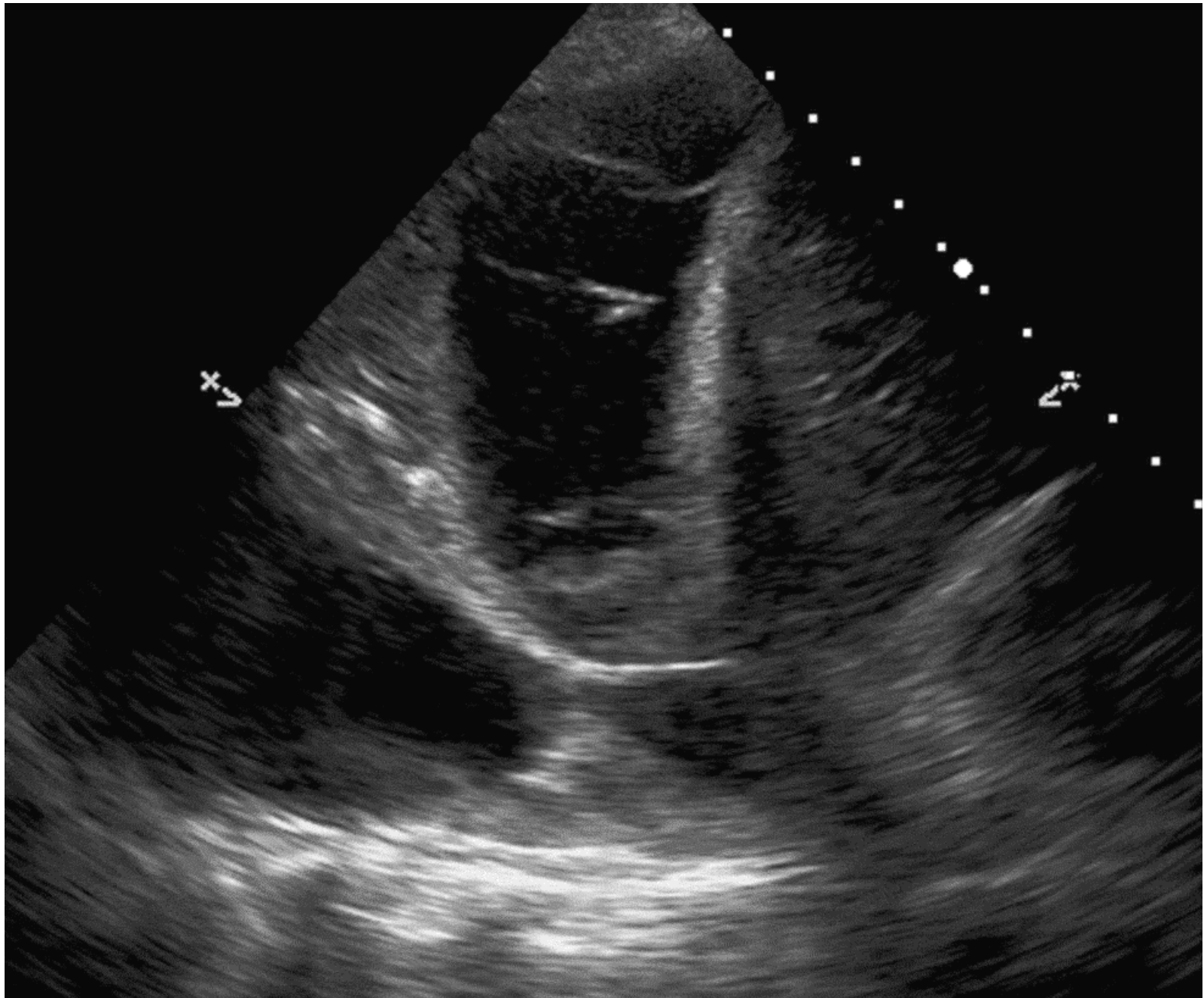
**Plankton Sign =
Exudative**



 POCUS 101

G
P R
16 32





Sample Report

검사이유	<input type="checkbox"/> Dyspnea <input type="checkbox"/> Hypoxemia <input type="checkbox"/> Shock <input type="checkbox"/> Post-procedure <input type="checkbox"/> other ()
	<input type="radio"/> Spontaneous breathing <input type="radio"/> Mechanical ventilation
① - ④ : 필수영상번호 with body marker	

☐ Lung

Right Lung		Left Lung	
① RUB (pleura)	<input type="checkbox"/> A <input type="checkbox"/> B1 <input type="checkbox"/> B2 <input type="checkbox"/> C	④ LUB (pleura)	<input type="checkbox"/> A <input type="checkbox"/> B1 <input type="checkbox"/> B2 <input type="checkbox"/> C
② RLB (pleura)	<input type="checkbox"/> A <input type="checkbox"/> B1 <input type="checkbox"/> B2 <input type="checkbox"/> C	⑤ LUB (pleura)	<input type="checkbox"/> A <input type="checkbox"/> B1 <input type="checkbox"/> B2 <input type="checkbox"/> C
Lung sliding	<input type="radio"/> Yes <input type="radio"/> No	Lung sliding	<input type="radio"/> Yes <input type="radio"/> No
Lung point	<input type="radio"/> Yes <input type="radio"/> No	Lung point	<input type="radio"/> Yes <input type="radio"/> No
Profile	<input type="radio"/> A <input type="radio"/> A' <input type="radio"/> B <input type="radio"/> B' <input type="radio"/> A/B <input type="radio"/> C	Profile	<input type="radio"/> A <input type="radio"/> A' <input type="radio"/> B <input type="radio"/> B' <input type="radio"/> A/B <input type="radio"/> C
③ Rt. PLAPS	<input type="radio"/> Yes <input type="radio"/> No	⑥ Lt. PLAPS	<input type="radio"/> Yes <input type="radio"/> No
Other findings	()		
기호설명	A : Normal pattern B1 : Multiple spaced B-lines (7mm apart) B2 : Coalescent B-lines (3mm apart) C : Consolidation		

☐ Heart

Parasternal long	<input checked="" type="radio"/> EF (visual estimation)	<input type="radio"/> Decreased <input type="radio"/> Normal <input type="radio"/> Hyperactive
	<input checked="" type="radio"/> Pericardial effusion	<input type="radio"/> No <input type="radio"/> Yes () cm
Parasternal short	<input checked="" type="radio"/> Base	()
	<input checked="" type="radio"/> Mid papillary	()
	<input checked="" type="radio"/> Apex	()
IVC	<input checked="" type="radio"/> M-mode	IVC diameter 흡기 () cm Collapsibility index () % IVC diameter 호기 () cm
Other findings	()	

■ Other findings

()

■ Conclusion and recommendation

()

검사자	
만독자	

Lung (총 6개)

Upper blue point = mid clavicle x 2nd ICS [1st ~ 2nd rib] (1)
 Low blue point = mid clavicle x 4th ICS [4th ~ 5th rib] (2).
 PLAPS = post axillary line x extension of low blue point.

RUB		or		or		LUB		or		or	
RLB		or		or		LLB		or		or	
PLAPS		or				PLAPS		or			

Heart (총 6개)

Parasternal long (2개)

Parasternal short (3개)

Base, Mid-papillary, Ape.

④ Base ⑤ Mid ⑥ Apex

IVC (1개)


Limitation of Lung ultrasound

Lung Ultrasound interpretation

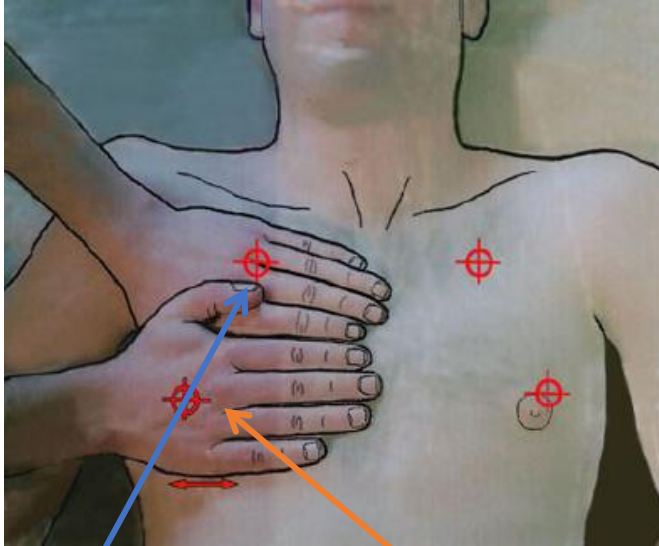
- Subcutaneous emphysema
- Calcification of the pleura
- Large thoracic dressing
- Pleural symphysis & pleurodesis
- Generalized edema
- Overlying lines and tubes
- Obese
- Over-distension of alveoli

Lung Sliding interpretation

- Small Tidal Volume
- Pleural adhesion
- COPD
- Rt. main bronchial intubation & atelectasis
- HFOV

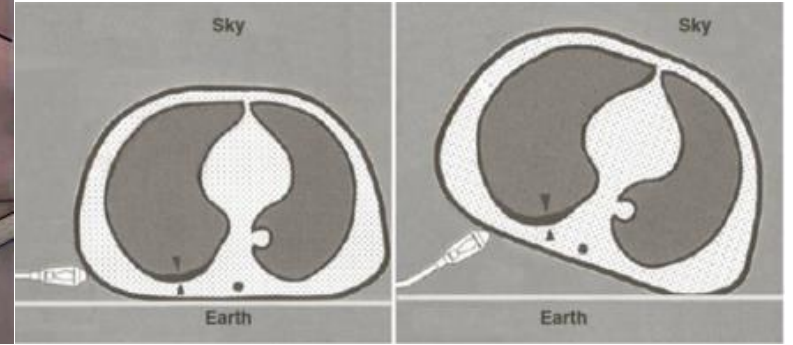
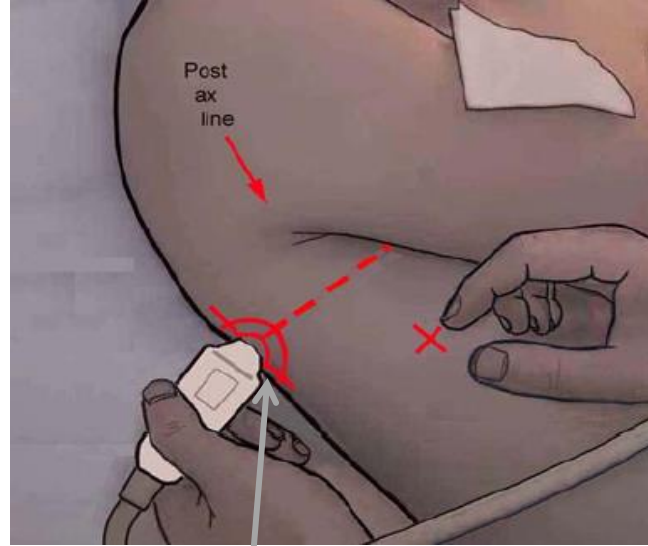


- 검사부위 : **BLUE points** & Quantitative Measure Points



Upper Blue Points

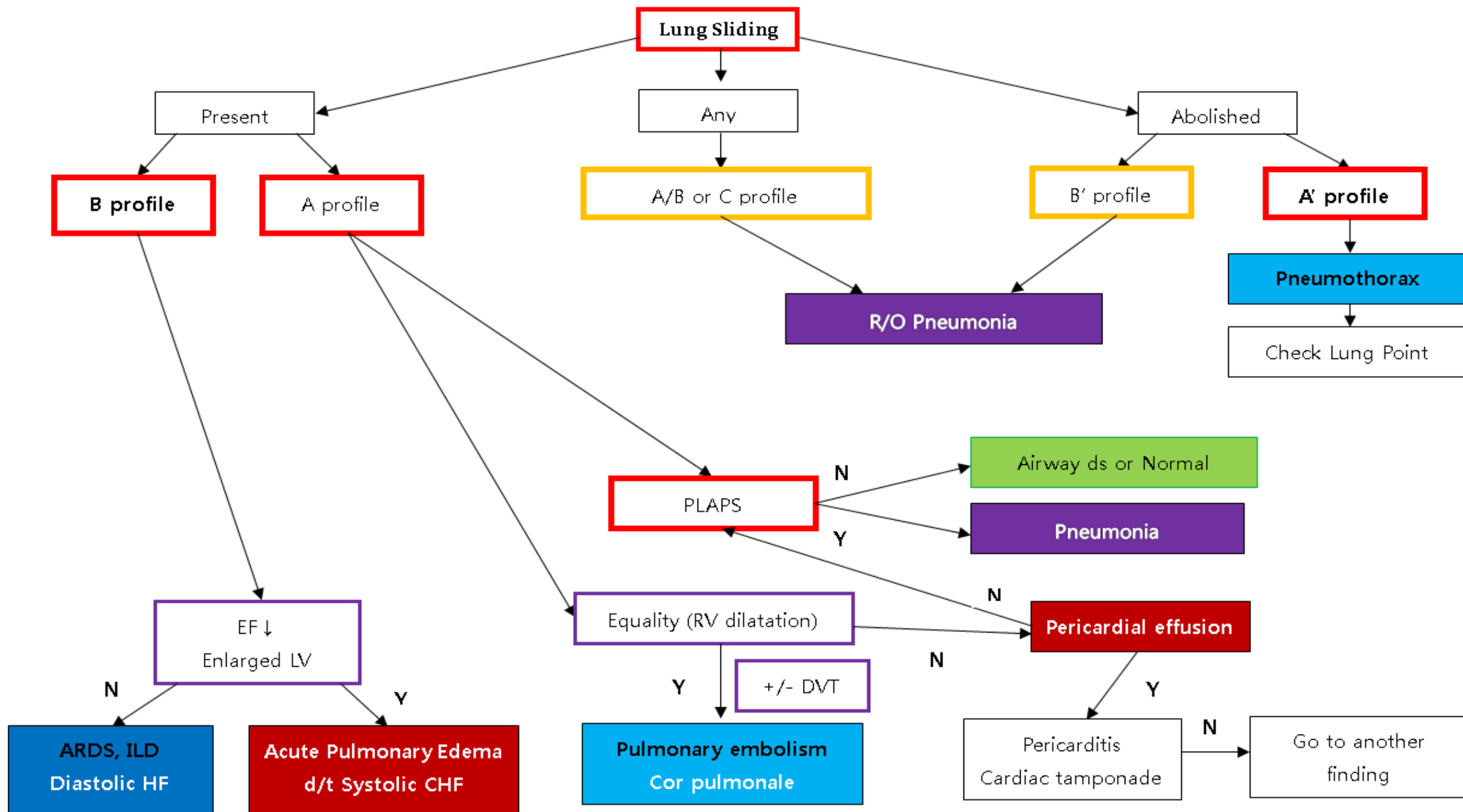
Lower Blue Points



PLAPS (Posterior and/or Lateral, Alveolar and/or Pleural Syndrome)

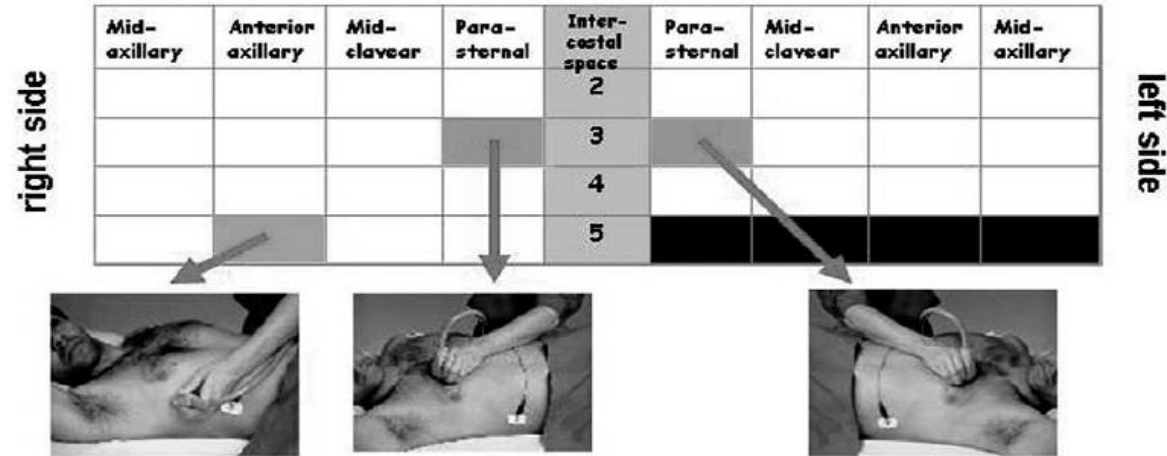
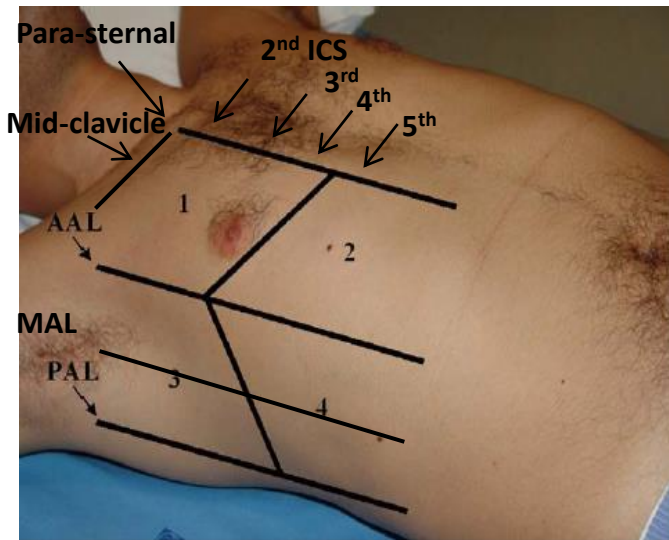
※ BLUE : Bedside Lung Ultrasound in Emergency ; by Lichtenstein

Ultrasonography in Acute Respiratory Failure (Modified BLUE)



- 검사부위 : BLUE points & **Quantitative Measure Points I**

Landmark

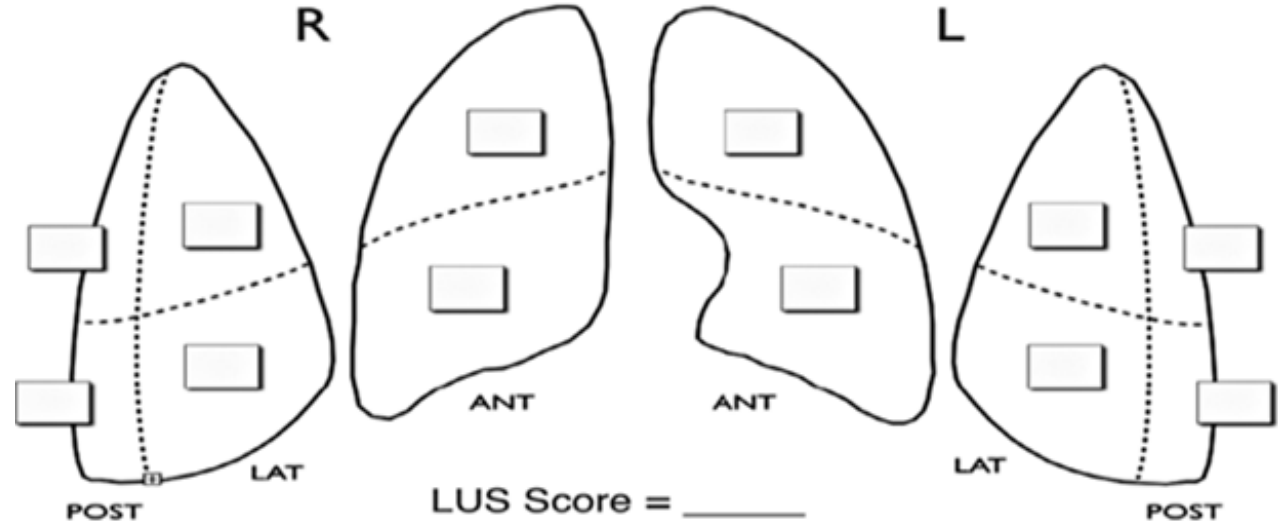
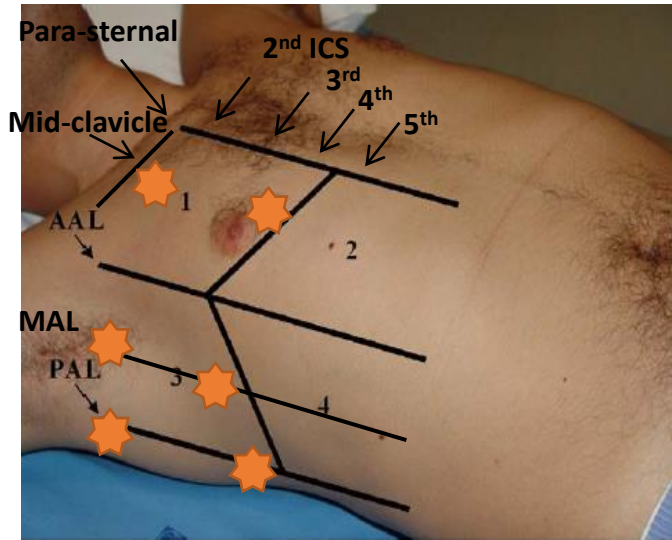


Comet score : overall number of the ultrasound lung comets **B line**


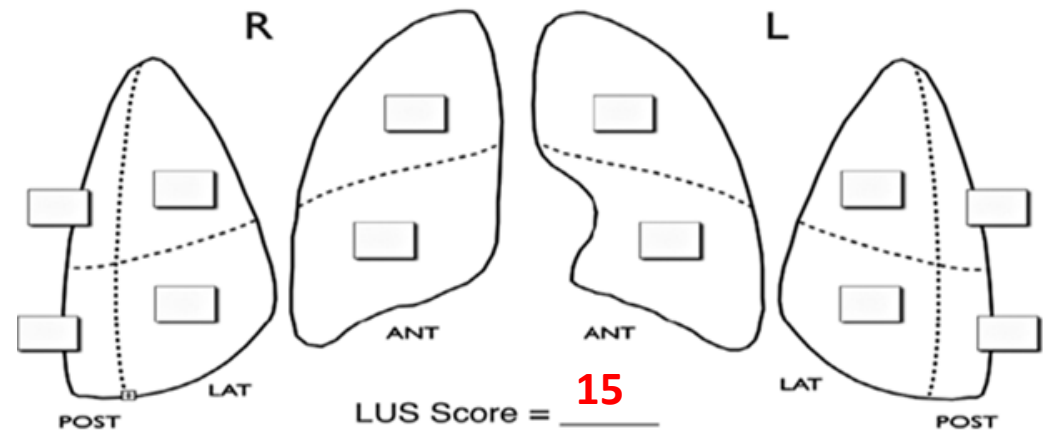
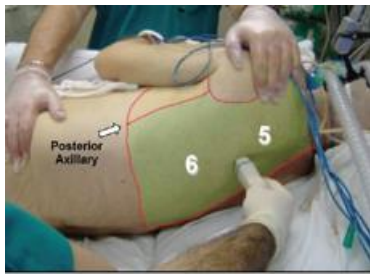
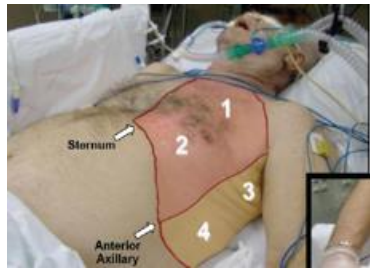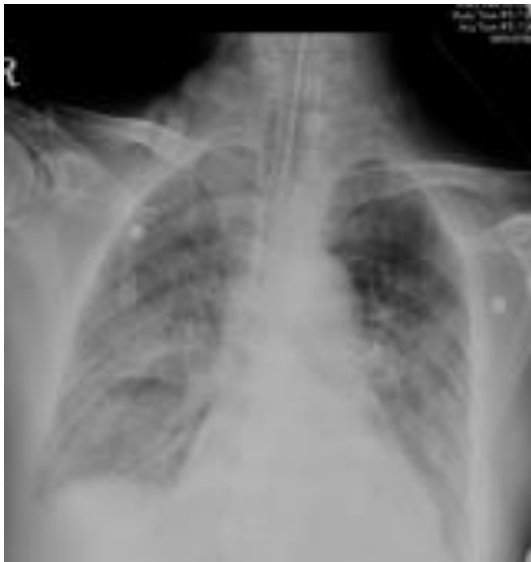
Points	Number of ULCs	Extravascular lung water
0	<5	No signs
1	5-15	Mild degree
2	15-30	Moderate degree
3	>30	Severe degree

- 검사부위 : BLUE points & **Quantitative Measure Points II**

Landmark



Points	Degrees of lung aeration	Patterns
0	Normal aeration	Horizontal A-lines (or no more than two B-lines)
1	Moderate loss of aeration	Multiple B lines , either regularly spaced (7mm apart), or irregularly spaced and even coalescent but only visible in a limited area of the intercostal space
2	Severe loss of aeration	Multiple coalescent B-lines , in prevalent areas of the intercostal spaces and observed in one or several intercostal spaces
3	Complete loss of aeration	Lung consolidation , with or without air bronchograms



Severance

With the Love of God, Free Humankind from Disease and Suffering

